

## Case Report

# Meatal Segment of Facial Nerve and Cavernous Hemangioma

Giuseppe Magliulo<sup>1\*</sup>, Giannicola Iannella<sup>1</sup>, Simone Alessi<sup>1</sup> and Massimo Re<sup>2</sup>

<sup>1</sup>Institute of Organi di Senso, University "la Sapienza", Italy

<sup>2</sup>Institute of Clinical Sciences, Polytechnic University of Marche, Italy

**\*Corresponding author**

Giuseppe Magliulo, M.D., Institute of Organi di Senso, University "la Sapienza", Rome. Via Gregorio VII n.80, Rome 00165, Italy, Tel: 393388622344; Fax : 390649976817; E-mail: giuseppemagliuloorl@yahoo.com

Submitted: 07 August 2014

Accepted: 30 September 2014

Published: 06 October 2014

**Copyright**

© 2014 Magliulo et al.

OPEN ACCESS

**Keywords**

- Cavernous hemangioma
- IAC Lesions
- Facial Nerve

**Abstract**

Cavernous malformations of the internal auditory canal (IAC) are a rare clinical entity. We report a rare case of cavernous hemangioma involving the internal auditory canal and the meatal segment of the facial nerve without any evident lesion to the cerebello-pontine angle and geniculate ganglion. In English language literature several studies have described cavernous malformations of the IAC, but only a few authors have described a facial nerve origin for this type of lesion.

Removal of the entire lesion was achieved via the surgical resection of the facial nerve and facial nerve continuity was restored using a great auricular nerve graft. Optimal postoperative facial function recovery was reported.

**ABBREVIATIONS**

IAC: Internal Auditory; CH: Cavernous Hemangioma; MRI: Magnetic Resonance Imaging; CPA: Cerebellopontine Angle

**INTRODUCTION**

Cavernous malformations of the internal auditory canal (IAC) are a rare clinical entity [1,2].

Several studies reported an incidence of 0.3 to 0.5%, comprising 10 to 20% of all vascular malformations [3,4]. They are composed of large, sinusoidal, thin-walled capillary spaces that in some cases, invade the surrounding neural tissue [5].

In this report, we present a case of cavernous hemangioma (CH) arising from the left facial nerve into the IAC. In English language literature several studies have described cavernous malformations of the IAC, but only a few authors have described a facial nerve origin for this type of lesion [1,2,6-13].

Clinical history, radiological appearance, histological features, surgical pathology and postoperative facial function are discussed

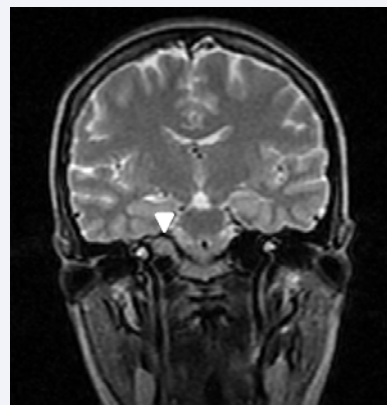
**CASE PRESENTATION**

A 38-year-old woman came to our department with progressive, left-sided hearing loss, tinnitus and dizziness. One year earlier she had presented a grade IV facial nerve paralysis according to the House-Brackmann classification without hospitalization. Otoscopy was normal. Pure-tone audiometry revealed left profound hearing loss. Further investigation with magnetic resonance imaging (MRI) showed a 9-mm mass inside the left IAC with no apparent involvement of the geniculate

ganglion and no extension into the cerebellopontine angle (CPA). Tumor was isointense on T1 images and hyperintense on T2 images, heterogeneously enhancing after contrast administration (Figure 1).

We suspected a vestibular or facial nerve schwannoma involving the IAC and opted for surgical excision (translabyrinthine approach).

Intraoperatively, we observed a reddish soft-tissue and crumbly mass of the IAC which was poorly circumscribed and highly vascularized which encased the facial nerve (Figure 2). Since the tumor infiltrated the facial nerve, it was impossible to



**Figure 1** Preoperative MRI, coronal T2-W images, 9-mm hyperintense mass inside to the left IAC (arrowhead). Heterogeneously enhancing after contrast administration.

remove it and preserve nerve integrity. Following tumor excision, facial nerve continuity was restored using a great auricular nerve graft (Figure 3). As expected, immediate postoperative facial nerve function was evaluated as grade VI according to the House-Brackmann scale evaluation.

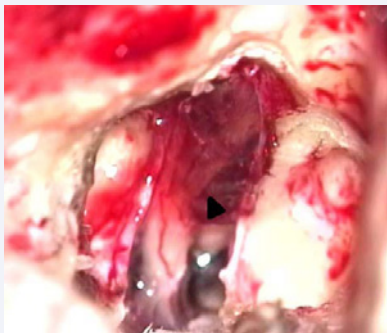Definitive histological examination revealed convoluted, dilated vascular channels lined by a single flat layer of endothelial cells and separated by thick collagenous tissue positive for CD31 and CD34. The collagenous stroma was positive for procollagen immunocytochemical stains, whereas S-100 was negative. All these features were indicative of CH of the facial nerve (Figure 4).

At 1-year follow-up, the patient was apparently tumor-free with improvement of the facial palsy to grade III (Figure 5).

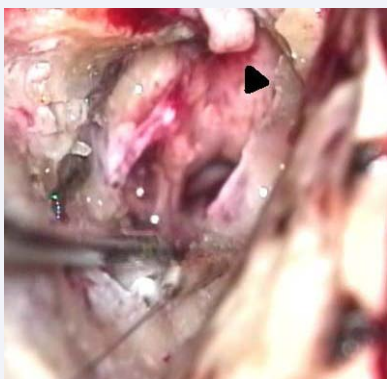## DISCUSSION

Cavernous hemangiomas of the IAC rarely involve the cranial nerves since space-occupying lesions along the course of the cranial nerves are generally schwannomas [1,2]. Their incidence ranges from 0.3 to 0.5% accounting 10 to 20% of all vascular malformations[3,4].

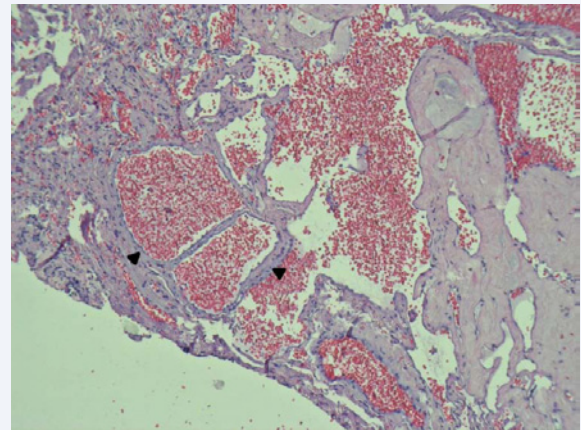
Such lesion was well described in the literature since 1976 when Sundaresan et al. [14] reported the first two cases of cavernous hemangiomas involving the IAC. Since that time, few reports in the literature documented and confirmed the occurrence of internal auditory canal cavernous angiomas [1,2,6-



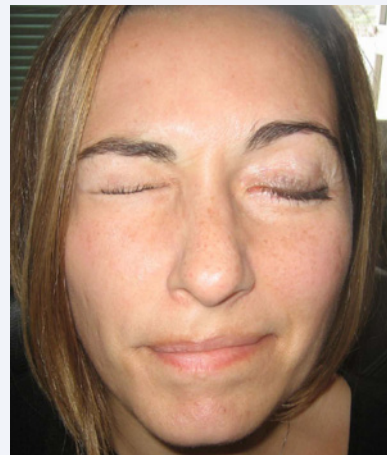**Figure 2** Translabrynthine approach, reddish soft-mass highly vascularized arised from the meatal segment of facial nerve (arrowhead).



**Figure 3** Auricular nerve graft to the distal portion of the facial nerve (arrowhead).



**Figure 4** Dilated vascular spaces with thick collagenous walls lined by a single layer of flat endothelium without atypical endothelial cells (arrowheads). Vessels appear obliterated by thrombosis in different stage of organization. (hematoxylin and eosin, 40x).



**Figure 5** Facial function recovery after 1-year follow-up. Grade III facial palsy according to the House-Brackmann scale of evaluation.

13]. Besides, the exact incidence of facial nerve CH is unknown due to the difficulty of establishing with certainly its nervous involvement. To our knowledge about 43 histologically proven cases [1,2,6-13] described a facial nerve origin for this type of lesion.

The larger series of CH were reported by Pappas et al. [12] that presented a series of seven cavernous hemangiomas limited primarily to the internal auditory canal and Samii et al. [13] that recently showed the clinical and radiological features of other seven patients with cavernous angiomas of the IAC.

It should be noted that in the previously reported cases a simultaneous involvement of the geniculate ganglion was observed. In our patient, both MRI and surgery ruled out this location of the malformative lesion. Therefore our was the first case with involvement of facial nerve meatal segment and geniculate ganglion apparent saving.

The presenting symptoms of this type of injury are most often sensorineural hearing loss, tinnitus, dizziness, and/or facial

nerve weakness, meaning that all often indistinguishable from those caused by the more common acoustic neuromas [1-3].

MRI is considered to be the most sensitive and specific preoperative diagnostic test for the detection of cavernous hemangioma, showing high signal intensity on T1- and T2-weighted images, and often calcification areas [2].

In our case, MRI showed an IAC lesion with no apparent involvement of the geniculate ganglion and no extension into the cerebellopontine angle (CPA), which was subsequently confirmed intraoperatively.

In contrast to cavernous hemangiomas, on MRI acoustic neuromas present with hypointense or isointense signalling on T1 and hyperintense signalling on T2 while meningiomas are typically isointense on T1 and T2 images. Moreover, the postcontrast images of CH show a heterogeneous enhancement pattern, opposed to the homogeneous enhancement pattern usually seen in vestibular schwannomas [1,15]. However, despite the fact that this type of malformation is usually associated with a clear MR characteristics and gadolinium enhancement, in some patients (such as the one described here) the signal characteristics may be not sufficiently specific to allow a correct preoperative diagnosis [2,5].

Facial nerve CH is thought to arise from the vascular plexi supplying or surrounding the facial nerve, whereas the origin of these vascular lesions in the IAC has been postulated to be the rich vascular plexus surrounding Scarpa's ganglion [2,5].

The histological features of facial nerve CH are similar to those presenting in other sites, namely irregularly dilated vascular spaces with thick collagenous walls lined by a single layer of flat endothelium. Immunohistochemistry staining with CD31 and CD34 is useful for showing the vascular endothelial lining, and procollagen stain [1-4]. The histological findings are very distinctive from those seen in the more common acoustic neuromas occurring in this region [16].

Differential diagnoses include vestibular and facial nerve schwannomas, meningiomas, hamartomas and lipomas [2-5].

On the grounds of the relatively slow progression of CH, some authors recommend adopting a wait-and-see policy [1,6,7]. Nevertheless, surgical resection is the preferred treatment for symptomatic lesions since tumor growth and potential bleeding may cause irreversible damage to the cranial nerves [16]. In our case a grade IV facial nerve paralysis according to the House-Brackmann classification was present.

Various surgical approaches including the suboccipital, middle fossa, and translabyrinthine ones have been described for the treatment of this lesion [1,2,6-13]. A translabyrinthine approach was performed in our case in consideration of the preexisting profound hearing loss.

In the case of IAC hemangiomas, a high incidence of facial nerve preservation has been reported when early surgery is performed [5,16]. Nevertheless, nerve resection and graft repairing are often necessary in cases of CH facial nerve origin or infiltration, as occurred in our patient.

In the English language literature, facial nerve reconstruction

was reported in only 2 patients with cavernous haemangiomas of the IAC. Facial function remained unchanged in one case while in the other one it partially recovered [17].

In conclusion, cavernous hemangioma should be taken into consideration for the differential diagnosis of facial nerve neof ormations originating within the internal auditory canal. Good postoperative facial function recovery is possible using a great auricular nerve graft.

## ACKNOWLEDGEMENTS

We would like to Riccardo Valpega di Masino M.D. of the Organi di Senso Department, Sapienza University, Rome, for acquisition and interpretation of data.

## REFERENCES

1. Lenarz M, Durisin M, Kamenetzki P, Becker H, Kreipe HH, Lenarz T. Cavernous hemangioma of the internal auditory canal. *Eur Arch Otorhinolaryngol.* 2007; 264: 569-571.
2. Barrera JE, Jenkins H, Said S. Cavernous hemangioma of the internal auditory canal: a case report and review of the literature. *Am J Otolaryngol.* 2004; 25: 199-203.
3. Rigamonti D, Hadley MN, Drayer BP, Johnson PC, Hoenig-Rigamonti K, Knight JT. Cerebral cavernous malformations. Incidence and familial occurrence. *N Engl J Med.* 1988; 319: 343-347.
4. Itshayek E, Perez-Sanchez X, Cohen JE, Umansky F, Spektor S. Cavernous hemangioma of the third cranial nerve: case report. *Neurosurgery.* 2007; 61: E653.
5. Cotton CA, Beall DP, Winter BJ, Fortman BJ, Kirby AB, Ly JQ. Cavernous angioma of the cerebellopontine angle. *Curr Probl Diagn Radiol.* 2006; 35: 120-123.
6. Capelle HH, Nakamura M, Lenarz T, Brandis A, Haubitz B, Krauss JK. Cavernous angioma of the geniculate ganglion. *J Neurosurg.* 2008; 109: 893-896.
7. Miyashita T, Hoshikawa H, Kagawa M, Mori N. A case report of facial nerve hemangioma. *Auris Nasus Larynx.* 2007; 34: 519-522.
8. Di Rocco F, Paterno V, Safavi-Abbasi S, El-Shawarby A, Samii A, Samii M. Cavernous malformation of the internal auditory canal. *Acta Neurochir (Wien).* 2006; 148: 695-697.
9. Towfighi J, Sheehan J, Isaacson J. Facial nerve neuroma associated with hemangioma of the geniculate ganglion: case report and review of the literature. *J Otolaryngol Head Neck Surg.* 2008; 37: E148-150.
10. Isaacson B, Telian SA, McKeever PE, Arts HA. Hemangiomas of the geniculate ganglion. *Otol Neurotol.* 2005; 26: 796-802.
11. Bhatia S, Karmarkar S, Calabrese V, Landolfi M, Taibah A, Russo A. Intratemporal hemangiomas involving the facial nerve: diagnosis and management. *Skull Base Surg.* 1995; 5: 227-232.
12. Pappas DG, Schneiderman TS, Brackmann DE, Simpson LC, Chandra-Sekar B, Sofferan RA. Cavernous hemangiomas of the internal auditory canal. *Otolaryngol Head Neck Surg.* 1989; 101: 27-32.
13. Samii M, Nakamura M, Mirzai S, Vorkapic P, Cervio A. Cavernous angiomas within the internal auditory canal. *J Neurosurg.* 2006; 105: 581-587.
14. Sundaresan N, Eller T, Ciric I. Hemangiomas of the internal auditory canal. *Surg Neurol.* 1976; 6: 119-121.
15. Omojola MF, al Hawashim NS, Zuwayed MA, al Ferayan A. CT and MRI features of cavernous haemangioma of internal auditory canal. *Br J Radiol.* 1997; 70: 1184-1187.

16. Sade B, Lee DK, Prayson RA, Hughes GB, Lee JH. Intraosseous cavernous angioma of the petrous bone. *Skull Base*. 2009; 19: 237-240.
17. Hanamitsu M, Okumura K, Yazawa Y, Fukui J, Suzuki M. Cavernous

haemangioma of the internal auditory canal: a case report. *J Clin Neurosci*. 2004; 11: 337-340.

**Cite this article**

Magliulo G, Iannella G, Alessi S, Re M (2014) Meatal Segment of Facial Nerve and Cavernous Hemangioma. *Ann Otolaryngol Rhinol* 1(1): 1004.