

# TMJ inferior compartment arthroplasty procedure through a 25-year follow-up (functional arthroplasty)

Piero Cascone<sup>1</sup>  
 Valerio Ramieri<sup>1</sup>  
 Paolo Arangio<sup>1</sup>  
 Valentino Vellone<sup>1</sup>  
 Achille Tarsitano<sup>2</sup>  
 Claudio Marchetti<sup>2</sup>

<sup>1</sup>Unit of Maxillofacial Surgery, Policlinico Umberto I, Sapienza University of Rome, Italy

<sup>2</sup>Department of Biomedical and Neuromotor Sciences, Section of Maxillofacial Surgery, University of Bologna, Policlinico S. Orsola, Bologna, Italy

## Corresponding author:

Valentino Vellone  
 Unit of Maxillofacial Surgery, Policlinico Umberto I, Sapienza University of Rome  
 Via del Policlinico  
 04100 Latina, Italy  
 E-mail: valentino.vellone@gmail.com

## Summary

**Objective.** The purpose of this study was to assess the outcomes of temporomandibular joint (TMJ) “functional arthroplasty” on the inferior compartment and disc reposition as a surgical treatment for internal derangement (ID).

**Patients and methods.** By retrospective chart review, all patients who had TMJ surgery on the inferior compartment for TMJ ID from 1985 to 2010 were identified. Their charts were reviewed and subjective data as well as objective data was collected.

**Results.** The chart review yielded 352 patients treated through this approach for a total of 696 joints involved. Analysis of the data showed that there was a good health improvement. The mid VAS about pre surgical TMJ pain was 58.3, after surgery 7.7.

About headache and cervical pain the pre surgery mid VAS was 47.7, after surgery 16.7.

**Conclusions.** Outcome data presented show that TMJ surgery on the inferior compartment and disc reposition could be an effective and successful surgical treatment of TMJ ID. This success has been seen and maintained also in long term follow up in this specific patient population. For this reason, we propose to call this procedure “functional arthroplasty”.

**Key words:** TMJ, internal derangement, TMJ surgery, functional arthroplasty.

## Introduction

TMD (temporo-mandibular joint disorder) is a collective term used to describe a number of related disorders affecting the temporo-mandibular joint (TMJ), masticatory muscles and associated structures, with a variety of common symptoms such as pain and limited mouth opening (1). TMDs are a common cause of persistent facial pain, headaches, jaw clicking, and jaw locking. Internal Derangement (ID) is one of the most common type of disorder affecting the TMJ (2). Internal derangement can be classified by 5 stages of dysfunction according to Wilkes (3). The reciprocal clicking of the joint, considered as the early stage of ID, is common, affecting about 40% of the general population (4-7). Whereas, later stages such as disc displacement without reduction and TMJ degenerative changes are less frequent (8-10). Procedures involving the temporo-mandibular joint, including open surgery and arthroscopy have been used to correct either position or structural problems of the disc, articular eminence and the condyle. Open surgery is still considered to be the “last chance” for patients affected by chronic recurrent TMD for which other therapies have failed to improve signs and symptom, preferring minimally invasive surgical techniques. Some studies (11) have indicated that nonsurgical treatment can eliminate ID signs and symptoms in patients with TMD, considering it as a self-limiting pathology. Although these studies might demonstrate the therapeutic prevalence of nonsurgical treatments compared with surgery ones, they seem to have not statistical significance and sufficient follow-up period (12). Main role of IDs surgical correction has been described as relief of symptoms and pain (13). In 1994, Dolwick and Dimitroulis (14) stated that the indications for performing surgery could be divided into relative and absolute. Absolute indications were TMJ tumors, ankylosis and condyle growth abnormalities. Relative indications were usually ascribed to those pathologies in which surgery appears to have a less defined role, such as internal derangement with abnormal disc position and arthritic changes. Inauspiciously, the failure of non-surgical therapy appears to suffer from misdiagnosis or incomplete diagnosis of TMDs, which could account for about 20% of failed cases (15, 16). Some studies (17, 18) have demonstrated that more the patient can define and localize their symptoms, more effective the surgery and out-

comes can be. The Authors propose a logical approach to internal derangement with an early minimally invasive technique, that could result in an immediate effective and long-lasting reduction in patient's symptoms such as atypical orofacial pain, neck pain and headaches. The Authors present a 25-year- retrospective study and a different technique in treating ID with an open surgery called "functional arthroplasty".

## Patients and methods

In this study the Authors performed a retrospective analysis of all patients with a diagnosis of internal derangement who underwent to "functional arthroplasty" with the same surgeon (P.C), from 1985 to 2010 for a total number of 565 patients. Inclusion criteria were as follows: the patients must have had internal derangement according to Wilkes criteria II or higher (3); no other TMJ operations performed in the past; a minimum follow-up period of 5 years whether by phone or in person.

Every patient included in the study had been evaluated in the following issues:

- a) internal derangement and laterality
- b) chief complaint as pertaining to the TMJ
- c) localization and laterality of pain associated with each joint
- d) headache and cervical pain.

The Authors adopted a Visual Analogue Scale (VAS) ranging from 0 to 100 to evaluate pain. All values had been approximated to the closest whole number. In relation to symptom the Authors have divided the sample before and post surgery in condyle luxation, only pain, crepitus, disc displacement with reduction and disc displacement without reduction. These conditions were very often associated with temporomandibular pain according to Wilkes stages.

VAS was used to evaluate pain. The patient were grouped values into 5 main classes before and post surgery: Class I absence of pain, Class II pain ranging from 1 to 25, Class III pain ranging from 25 to 50, Class IV pain ranging from 50 to 75 and Class V pain ranging from 75 to 100. The issue "Headache and cervical pain" has been investigated before and post surgery with the VAS considering the same classes of values.

## Surgical technique

Open surgery. A pre-auricular post-tragal incision was performed with a bevelled 45° inclination, approximately 1.5 cm long. The temporal vessels are then isolated and ligated with 3-0 silk suture. Dissection was then carried down to the TMJ capsule, with special care given not to damage the facial nerve. The aim is to preserve as much as possible the TMJ biomechanics. A diagnostic arthroscopy was then carried out in the superior compartment to check for perforations in the disc and adhesions and 200 cc

ringer lactate lavage was performed. The inferior compartment was then access by using a 15 blade cutting through the lateral ligaments of the disc. After entering the inferior compartment care was taken to protect the disc, retrodiscal tissues and medial aspect of the capsule by placing three retractors on the head of the condyle. A high condylectomy (about 1-2 mm) was then accomplished by using a straight fissure bur or piezo surgery. After removal of this piece and smoothing off the edges, the joint and retrodiscal tissues were evaluated from the inferior compartment for perforations, adhesions, or anomalies. After correcting any perforations with suture or freeing any adhesions, the lateral ligaments of the disc were sutured in a posterior lateral fashion. The last step was a washing of the inferior compartment using lactated ringer solution (200 cc) and the surgical site closed using two layers. Patients are closely followed up during the first weeks to restore the correct function.

## Results

Out of the inner sample of 565 patients only 352 (62.3%) satisfied inclusion criteria. 337 patients had diagnosis of bilateral internal derangement (in this case diagnosis was given in relation to the worse TMJ pathology) and 22 had monolateral involvement for a total number of 696 treated joints. The sample was composed by 299 females (85%) and 53 males (15%). In relation to age, the lowest value observed was of 16 years to the highest of 68 with a mean value of 32. Long-term follow up was accomplished in every patient from the smallest value of 5 years to the highest of 27 with a mean value of 12.5 years.

In relation to symptom 5% suffered from condyle luxation, 6% only pain, 24% crepitus, 30% click, 35% lock (Fig. 1) while after surgery 77% of patients reported no symptoms, 9% presented with click, 2% lock and 12% crepitus (Fig. 2).

These conditions were very often associated with temporomandibular pain according to Wilkes stages (Stages I and II 82.3%; III and IV 97.1%; V 100%).

VAS was used to evaluate pain. The patients were grouped values into 5 main classes: Class I absence of pain, Class II pain ranging from 1 to 25, Class III pain ranging from 25 to 50, Class IV pain ranging from 50 to 75 and Class V pain ranging from 75 to 100.

Before surgery 6% of patients was classified in VAS group ranged from 1-25, 11% in 25-50 VAS, 13% no pain, 31% 50-75 VAS, 39% 75-100 VAS) (Fig. 3).

After surgery 78% of patient reported no pain, 10% were classified in VAS group ranged from 1-25, 6% in VAS group 25-50, 4% in VAS group 50-75 while only 2% in VAS group 75 to 100 (Fig. 4).

The issue "Headache and cervical pain" has been investigated before surgery with the VAS considering the same classes of values as shown in Chart 3 (13% 1-25 VAS, 17% 25-50 VAS, 18% no pain, 23% 50-75 VAS, 29% 75-100 VAS) (Fig. 5).

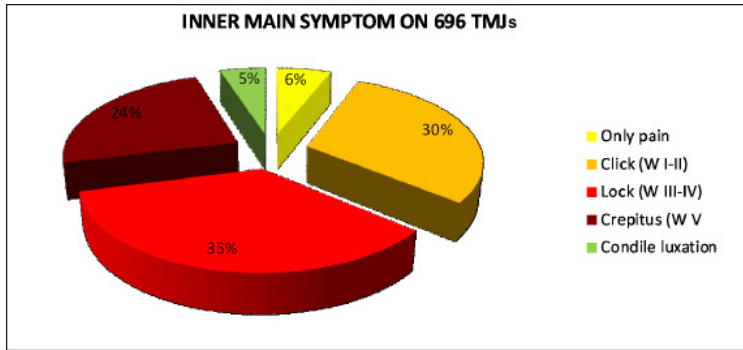


Figure 1. Evaluation of presurgical main symptom.

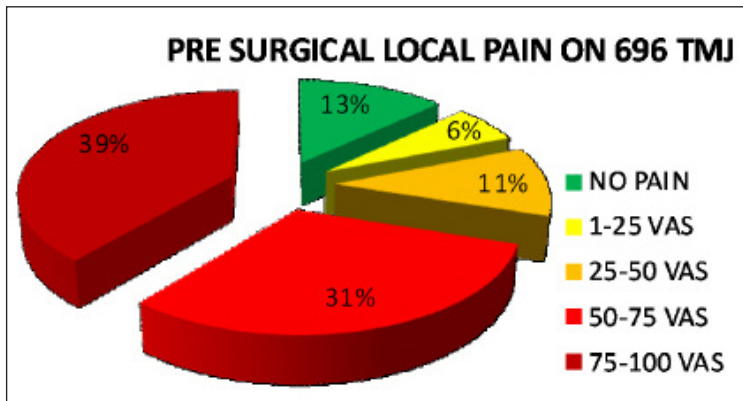


Figure 2. Evaluation of postsurgical main symptom.

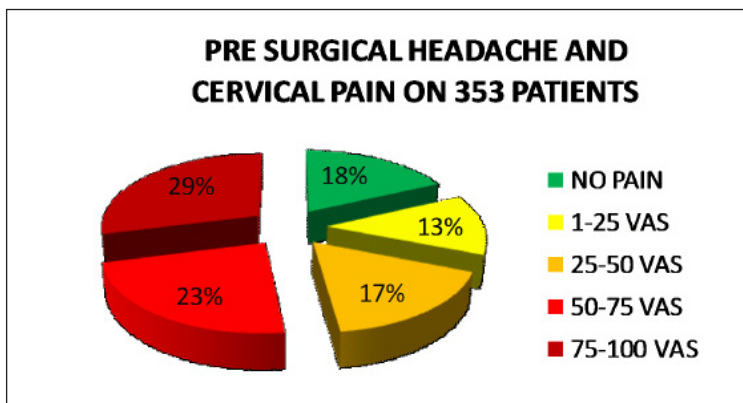


Figure 3. Evaluation of presurgical pain.

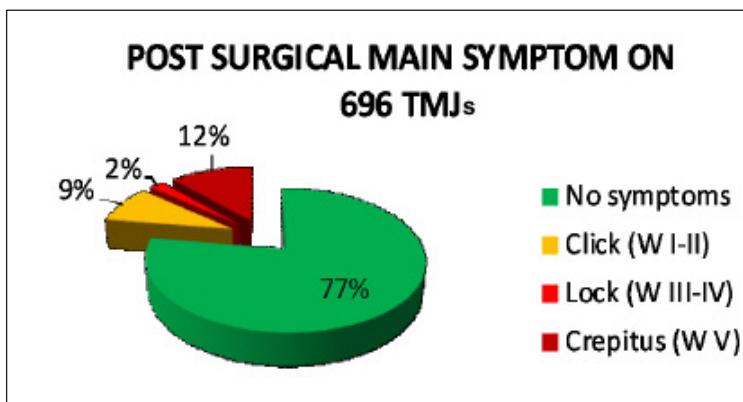


Figure 4. Evaluation of postsurgical pain.

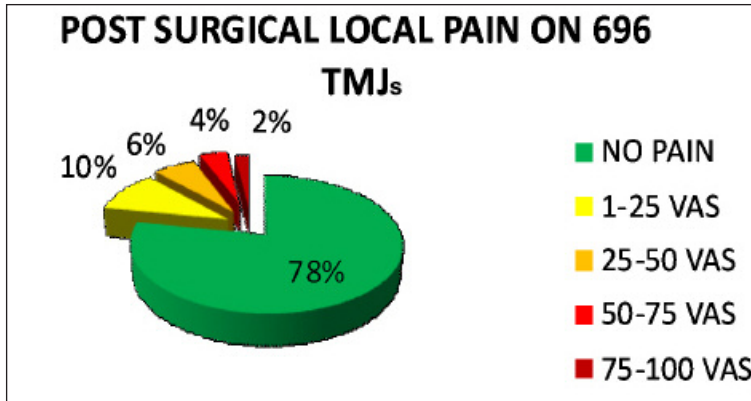


Figure 5. Evaluation of presurgical headache.

After surgery 54% of patient reported no headache and cervical pain, 22% was classified in VAS group ranged from 1-25, 11% in VAS group 25-50, 6% in VAS group 50-75, while 7% in VAS group 75 to 100 (Fig. 6).

### Discussion

To date there is no agreement about when to do an open surgery of the TMJ. Several approaches in the past have shown a variety of results with poor long term outcome.

Moreover, there are not adequate comparative studies (19) and an unique classification is not widely recognized. Many surgical strategies, such as discectomy or articular prosthesis, mainly deal with patient referred pain and don't take into account the anatomical and morphological issues (20-22). Other strategies aimed to restore the anatomy, however they have not seen long lasting results such as those that have used proplast-teflon substitution of the disc (23, 24). From the 1985, when was first approached this surgery, impressive outcomes were seen and since then the surgical technique has never been changed in its basic principles: high condylectomy, disc repositioning and reconstruction of

the lateral ligament most of the time bilateral surgical treatment. As pertaining to the high condylectomy it is Authors' opinion that, essentially, it brings the following results: a) eliminates condylar disparities which are always observed in case of long lasting disc displacement; b) it widens the articular space which has been reduced by the vertical height loss; c) creates scar adhesions between disc and condyle thus leading to a greater after surgical stability. Performing the surgery bilaterally bring a better result because ID affects most of the time both joints in a variety of pathology. It was interesting to observe some patients had crepitus after surgery especially if they were affected by chronic lock. A complete crepitus resolution was observed in patients with a previous diagnosis of crepitus. This particular phenomenon has to be referred to the physiological sliding of the malformed disc. It was felt that this treatment worked because it restored balance to the TMJs bilaterally, created space for the disc and condyle to function once again in harmony, and made it possible for the patient to once again have normal range of motion of their mandible. This procedure respects anatomy and biomechanical function and restriction that guides TMJ movements. For this reason, we would like to call this surgery "functional arthroplasty".

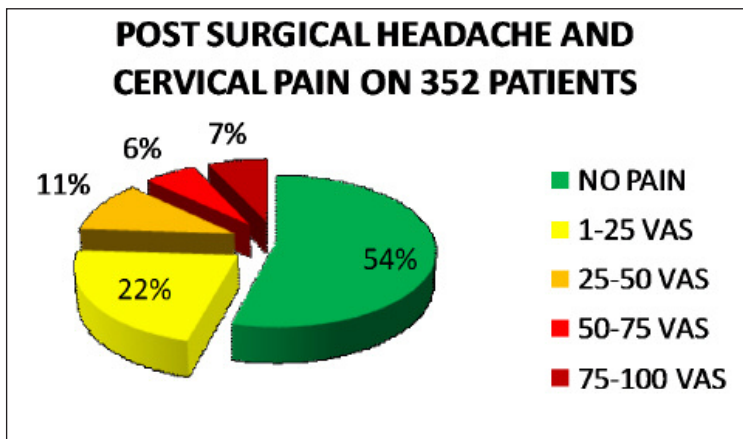


Figure 6. Evaluation of postsurgical headache.

## Conclusions

This study adds to previously reported successful results (25) and encourages surgeons to pursue open technique respecting TMJ anatomy and biomechanical functional restriction.

The outcome data showed that “functional arthroplasty” on the inferior compartment with disc repositioning could be an effective and successful surgical treatment option for patients with TMJ ID especially those who have problems bilaterally. In conclusion, “functional arthroplasty” on the inferior compartment is an effective and successful surgical treatment for TMJ ID in our specific patient population. This success has been continued for over 25 years.

## Conflict of interest

The Authors declare that there is no conflict of interest in publishing this paper.

## Funding

This research did not receive any specific grant from funding agencies in the public, commercial, or not-for-profit sectors.

## References

1. Dimitroulis G. Temporomandibular disorders: a clinical update. *BMJ*. 1998;317:190-194.
2. Friction JR, Look JO, Schiffman E, Swift J. Long-term study of temporomandibular joint surgery with alloplastic implants compared with nonimplant surgery and nonsurgical rehabilitation for painful temporomandibular joint disc displacement. *J Oral Maxillofac Surg*. 2002;60:1400-1411.
3. Wilkes CH. Internal derangements of the temporomandibular joint: pathological variations. *Arch Otolaryngol Head Neck Surg*. 1989;115:469.
4. Schiffman EL, Friction JR, Haley DP, Shapiro BL. The prevalence and treatment needs of subjects with temporomandibular disorders. *J Am Dent Assoc*. 1990;120:295.
5. Gross A, Gale EN. A prevalence study of the clinical signs associated with mandibular dysfunction. *J Am Dent Assoc*. 1983;107:932.
6. Solberg WK, Woo MW, Houston JB. Prevalence of mandibular dysfunction in young adults. *J Am Dent Assoc*. 1979;98:25.
7. Helkimo M. Studies on function and dysfunction of the masticatory system: IV. Age and sex distribution of symptoms of dysfunction of the masticatory system in Lapps in the north of Finland. *Acta Odontol Scand*. 1974;32:255.
8. Wilkes CH. Structural and functional alterations of the temporomandibular joint. *Northwest Dent*. 1978;57:287.
9. Stegenga B, de Bont LG, Boering G. Osteoarthritis as the cause of craniomandibular pain and dysfunction: A unifying concept. *J Oral Maxillofac Surg*. 1989;47:249.
10. Stegenga B, de Bont LG, Boering G, van Willigen JD. Tissue responses to degenerative changes in the temporomandibular joint: a review. *J Oral Maxillofac Surg*. 1991;49:1079.
11. Dimitroulis G. The role of surgery in the management of disorders of the temporomandibular joint: a critical review of the literature. Part 1. *Int J Oral Maxillofac Surg*. 2005;34:107-113.
12. Murakami K, Kaneshita S, Kanoh C, Yamamura I. Ten-year outcome of nonsurgical treatment for the internal derangement of the temporomandibular joint with closed lock. *Oral Surg Oral Med Oral Pathol Oral Radiol Endod*. 2002;94(5):572-5.
13. Pedullà E, Meli GA, Garufi A, Mandalà ML, Blandino A, Cascone P. Neuropathic pain in temporomandibular joint disorders: case-control analysis by MR imaging. *AJNR Am J Neuroradiol*. 2009;30(7):1414-8.
14. Dolwick MF, Dimitroulis G. Is there a role for temporomandibular joint surgery? *Br J Oral Maxillofac Surg*. 1994;32:307-313.
15. Dimitroulis G. The role of surgery in the management of disorders of the temporomandibular joint: a critical review of the literature. Part 2. *Int J Oral Maxillofac Surg*. 2005;34:231-237.
16. Nitzan DW, Dolwick MF, Martinez GA. Temporomandibular joint arthrocentesis: a simplified treatment for severe, limited mouth opening. *J Oral Maxillofac Surg*. 1991;49(11):1163-1167.
17. Cascone P. Terapia chirurgica della lussazione anteriore del menisco. *Dental Cadmos*. 1987;11:17-12.
18. Cascone P, Ungari C, Paparo F, Marianetti TM, Ramieri V, Fatone M. A new surgical approach for the treatment of chronic recurrent temporomandibular joint dislocation. *J Craniofac Surg*. 2008;19(2):510-2.
19. Politi M, Sembronio S, Robiony M, Costa F, Toro C, Undt G. High condylectomy and disc repositioning compared to arthroscopic lysis, lavage, and capsular stretch for the treatment of chronic closed lock of the temporomandibular joint. *Oral Surg Oral Med Oral Pathol Oral Radiol Endod*. 2007;103:27-33.
20. McKenna SJ. Discectomy for the treatment of internal derangements of the temporomandibular joint. *J Oral Maxillofac Surg*. 2001;59:1051-1056.
21. Mercuri LG. The Christensen prosthesis. *Oral Surg Oral Med Oral Pathol*. 1996;81:134-135.
22. Wolford LM, Dingworth DJ, Talwar RM, Pitta MC. Comparison of 2 temporomandibular joint total joint prosthesis systems. *J Oral Maxillofac Surg*. 2003;61:685-690.
23. Henry CH, Wolford LM. Treatment outcomes for temporomandibular joint reconstruction after proplast-teflon implant failure. *J Oral Maxillofac Surg*. 1993;51:352-358.
24. Cascone P, Di Paolo C, Leonardi R, Pedullà E. Temporomandibular disorders and orthognathic surgery. *J Craniofac Surg*. 2008;19(3):687-692.
25. Abramowicz S, Dolwick MF. 20-year follow-up study of disc repositioning surgery for temporomandibular joint internal derangement. *J Oral Maxillofac Surg*. 2010;68:239-242.