



Evaluation of wound healing and postoperative pain after oral mucosa laser biopsy with the aid of compound with chlorhexidine and sodium hyaluronate: a randomized double blind clinical trial

Gaspare Palaia¹ · Gianluca Tenore¹ · Luca Tribolati¹ · Claudia Russo¹ · Gianfranco Gaimari¹ · Alessandro Del Vecchio¹ · Umberto Romeo¹

Received: 23 May 2018 / Accepted: 23 October 2018
© The Author(s) 2018

Abstract

Objectives The aim of this study is to evaluate secondary intention healing process and postoperative pain of oral soft tissues after laser surgery with the use of a compound containing chlorhexidine and sodium hyaluronate.

Materials and methods This double-blind, randomized clinical study included 56 patients affected by benign oral lesions and subjected to excisional biopsy with diode laser and randomly divided into three groups. Study group (SG) received 0.2% chlorhexidine digluconate and 0.2% sodium hyaluronate treatment; control group (CG) received 0.2% chlorhexidine digluconate; and placebo group (PG) followed the same protocol, taking a neutral solution having the same organoleptic characteristics. Wound healing was evaluated using percentage healing index (PHI). Numeric rating scale (NRS) was used to evaluate postoperative pain.

Results PHI (T1 = 7 days) was 67.25% for SG, 58.67% for CG, and 54.55% for PG. PHI (T2 = 14 days) was 94.35% for SG, 77.79% for CG, and 78.98% for PG. A statistically significant difference was between the groups for PHI at T2 $p = 0.001$. No difference was detectable for pain index.

Conclusions A solution containing sodium hyaluronate and chlorhexidine is a good support to increase wound healing by secondary intention after laser biopsy, but no differences were in postoperative perception of pain.

Clinical relevance The use of the tested solution can be recommended after laser oral biopsies, to achieve a healing without suture. About the postoperative pain, the compound has not showed the same results and did not have measurable effects.

Keywords Sodium hyaluronate · Wound healing · Postoperative pain · Laser · Oral biopsy · Chlorhexidine digluconate

Introduction

Oral biopsy is a standard procedure for the diagnosis of oral mucosa lesions. It is a surgical treatment that can provoke secondary effects like pain and inflammation, depending on the degree of the tissue damage produced [1].

Thanks to its features, laser is often used to perform oral biopsies. In fact, it carries out several advantages to daily surgical procedures for the operator and patient, comprehending a partial decontamination of the surgical field, less bleeding, thanks to the laser-hemoglobin interaction, with greater visibility and the possibility to execute surgery in

✉ Gaspare Palaia
gaspare.palaia@uniroma1.it

Gianluca Tenore
gianluca.tenore@uniroma1.it

Luca Tribolati
luca.tribolati@gmail.com

Claudia Russo
claudia.russo@uniroma1.it

Gianfranco Gaimari
gianfranco.gaimari@uniroma1.it

Alessandro Del Vecchio
alessandro.delvecchio@uniroma1.it

Umberto Romeo
umberto.romeo@uniroma1.it

¹ Department of Oral and Maxillo-Facial Sciences, "Sapienza" University of Rome, via Caserta 6, 00162 Rome, Italy

patients with coagulation disorders, in particular using the diode laser [2–4]. Furthermore, it consents to have less post-operative pain, inflammation, and as one of the best benefits, wound healing by secondary intention thanks to the coagulation capacity [5–7]. Oral biopsy performed by laser permits to not use suture that can delay healing by plaque increasing [8].

Healing by primary intention provides a mechanism with deposition of proteoglycans, collagen, and proteins to form a connective extracellular matrix instead of healing by secondary intention permits a heal by contraction, with tissue movement from the margin to the center of wound. This healing is based on a complex mechanism between contractile fibroblast and extracellular matrix [9]. A wound generally heals into four phases, characterized by specific markers and condition comprehending, hemostasis, inflammation, proliferation, and remodeling phases. The healing starts at the moment of an injury with hemostasis, where the platelets release clotting factors, growth factors, and cytokines. In the next phase, neutrophils begin the phagocytosis and remove bacteria, damaged tissue, and foreign materials with the aid of macrophages. Afterwards, fibroblasts migrate and deposit new extracellular matrix recovering structure and function to the tissue, a characteristic of proliferative phase. During this phase, the predominant cell is fibroblast that produces collagen and glycosaminoglycans like ialuronic acid. The last phase is the remodeling one, where collagen matrix begins to be organized [10].

Hyaluronic acid (HA) is a molecule introduced to promote wound healing [11], found in many tissues [12]. It has got numerous properties bringing advantages for wound healing such as granulation tissue formation, inhibition of destructive inflammation, and promotion of angiogenesis and reepithelization [11, 13]. HA is used in numerous medical disciplines; it is devoid of toxicity and for topical oral use is available in gel or liquid preparation [12, 14].

In literature, it has been shown that wound healing can be facilitated and accelerated by the application of sodium hyaluronate stimulating fibroblasts, increasing the production of growth factors and the biosynthesis of different types of collagen [15].

Romeo et al. [16] evaluated in a randomized clinical study, the healing of soft tissue after laser surgery, with or without the use of a gel based on amino acids and sodium hyaluronate. Patients have been divided into a study group, where amino acid and sodium hyaluronate-based gel was administered and in a control group, in which no substance was applied on the wound. The results showed a rate of better healing and more rapid tissue repair of the wounds in the study group.

Another study conducted by Mariggio' et al. [15] evaluated the effects induced by the high molecular weight of HA and a pool of amino acids on the proliferation of human fibroblasts and deposition of collagen I and III. It has been also studied the action on the production of growth factors involved in angiogenesis, deposition of extracellular matrix proteins and

expression of pro-inflammatory cytokines fundamental for the recall of macrophages, and proliferation of keratinocytes.

In many cases, post-operative instructions after oral biopsy involving the use of chlorhexidine have been considered a good prophylactic against postoperative infection, also due to the fact that patients cannot maintain good oral hygiene [17–19].

In virtue of this, the application of CURASEPT®ADS020 TRATTAMENTO RIGENERANTE (CURADEN HEALTHCARE), a solution composed of chlorhexidine digluconate 0.2% and sodium hyaluronate 0.2%, has been recommended to treat the symptoms and the wound healing of oral laser biopsy lesions with different etiologies.

Biopsy is necessary to obtain a definitive diagnosis of oral lesions, so it is important to reduce postoperative pain, decrease the healing time, and have a clear understanding of post-operative course associated to this procedure and to better support patients during the postoperative course.

The aim of the present study was to evaluate the efficacy of rinses with a solution of sodium hyaluronate and chlorhexidine digluconate, in improving laser wound healing and pain experienced by patients after oral mucosa biopsy, comparing it with the use of only chlorhexidine or placebo solution.

Material and methods

This randomized double-blind clinical study was performed at the Complex Operative Unit of Stomatology of the Department of Oral and Maxillo-Facial Sciences, “Sapienza” University of Rome, Italy, from October 2014 to May 2017. According to the Declaration of Helsinki (2008), all patients participating at the study were properly informed about its features, and before starting the clinical section, they had to read and sign a written informed consent. Moreover, the study protocol was approved by the Ethics Committee of the “Sapienza” University of Rome (protocol reference: CE 4011).

The inclusion criteria consisted in the presence of a benign lesion (Fig. 1), like fibromas, mucocelles, and HPV lesions, in different areas of the oral cavity, such as the buccal mucosa, tongue, and lips, requiring histopathologic analysis for diagnostic purposes. Patients affected by systemic diseases, problems of hemostasis, and coagulation, with poor oral hygiene and with an allergy or hypersensitivity to the used products, were excluded from the study.

To determine the sample size, a power of 80% was considered, with beta-value of 0.20, a confidence level of 95% and a confidence interval of 5. A sample size calculator made by Creative Research Systems was used and indicated 47 patients to validate the study.

Before each intervention, patients were randomly allocated from a computer-generated list of random numbers into one of

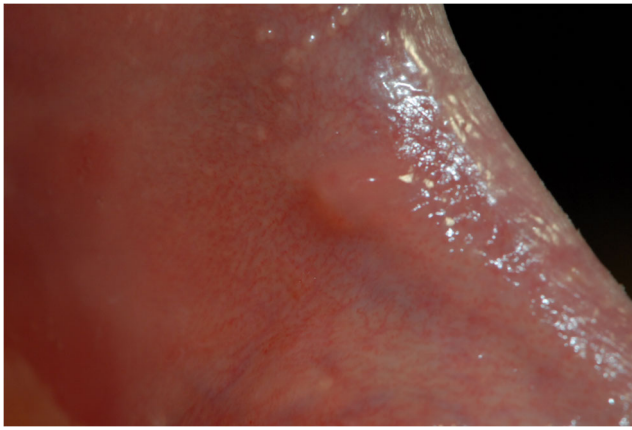


Fig. 1 Benign oral lesions, which histological examination was found to be focal fibrous hyperplasia

three groups (Study Group or SG, Control Group or CG, Placebo Group or PG) (Fig. 2).

Allocation concealment was achieved through the provision, by professionals not involved in patient enrollment, of a numbered sequence of opaque and sealed envelopes containing the assignment code. The list remained inaccessible, and the envelopes were opened, sequentially, after enrolling the patient and obtaining consent.

Oral biopsies have been performed using a diode laser (980 nm, 2.5 W in CW, fluence 1990 J/cm², with a fiber diameter of 400 μ m, LEONARDO®, DMT s.r.l.—20851 Lissone (MB)—Italy) by the same operator in order to minimize differences due to operator variability. Local anesthesia, with 1.8 mL of mepivacaine solution (MEPIVACAINA PIERREL®, 30 mg/ml, injection solution 1.8 ml, Pierrel Spa, Milan, Italy), was administered before the beginning of each surgical intervention, and after surgery, all samples have been sent to the pathologist for histological evaluation and diagnosis.

No sutures have been applied to obtain wound healing by secondary intention (Fig. 3).



Fig. 2 Various mouthwashes that can be assigned through randomization

After biopsy:

- SG had to make a rinse with one plug of 0.2% chlorhexidine digluconate and 0.2% sodium hyaluronate (CURASEPT® ADS020 TRATTAMENTO RIGENERANTE), for 1 min, immediately after surgery and two times daily for 2 weeks, after routine meals and after regular oral care procedures at home.
- CG had to follow the same protocol as SG, but using 0.2% chlorhexidine digluconate (CURASEPT® ADS020).
- PG following the same protocol as SG and CG received a neutral solution, predisposed by CURADEN HEALTHCARE, having the same organoleptic characteristics.

The mouthwashes were provided to the patient by our unit. Each of them had an X, Y, and Z code according to the compound used. X represented the SG, Y the CG, and Z the PG.

The patient and the operator were unaware of the contents of the mouthwash (double-blind study).

Furthermore, instructions have been given to patients in order to not take any liquid or solid foods and to abstain from rinsing their mouths for at least 30 min after the application of the compound to obtain a good distribution and absorption. No other medications (such as antibiotics or FANS) have been prescribed thanks to laser advantage in decreasing postoperative pain [2, 3]. Wound healing evaluation has been performed using digital photographic controls taken immediately after surgery (T0), 7 days after surgery (T1), and 14 days after surgery (T2). Pictures have been taken with a digital camera (NIKON D200®, Nikon Corporation, Tokyo, Japan) through the use of an L-shaped graph paper benchmark (with 1-mm intervals) (Fig. 4), put on the sides of the treated area. The obtained high-resolution pictures were edited using graphics software (ADOBE PHOTOSHOP CC®, Adobe Systems, San Jose, CA). After having delimited the lesion edges and set 1 mm value with benchmark, the area has been calculated in square millimeters (Fig. 5) to obtain three different values: the

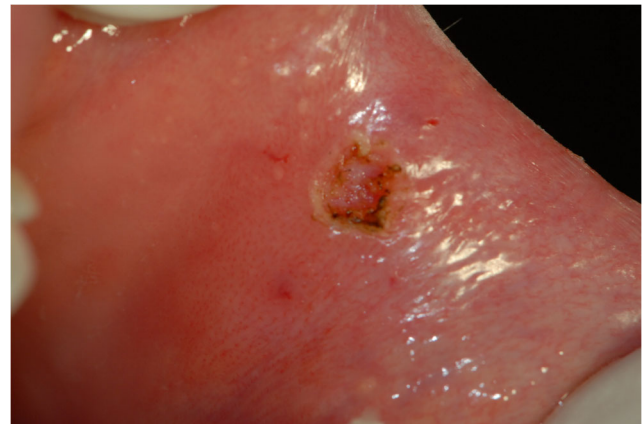


Fig. 3 Removal of the lesion by the laser and the residual injury

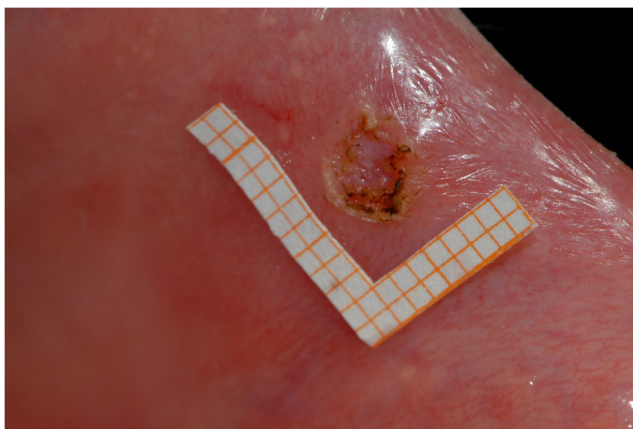


Fig. 4 Wound area with an L-shaped graph paper benchmark (with 1-mm intervals)

wound area at T0, the wound area at T1, and the wound area at T2. The resulting values have been examined to calculate a percentage value, called percentage healing index (PHI) at T1 and T2. First, the T1 area was divided by the T0 area before it was multiplied by 100, and then, the same procedure with T2 divided by T0. The obtained value, also called percentage unhealed index (PUI), represented the percentage of the lesion that did not heal over a 7-day period or 14-day period. The complementary value to this percentage was defined as the PHI at T1 and PHI at T2 (e.g., $PUI = T1/T0 \cdot 100 = 16.6 \text{ mm}^2/50.2 \text{ mm}^2 \cdot 100 = 33.06\%$; $PHI = 100 - PUI = 100 - 33.06 = 66.94\%$).

Numeric rating scale (NRS) was used to evaluate the severity of pain. This NRS consisted in a 100-mm horizontal line, using a 10-point, anchored at one end with the words “no pain” or value 0 and at the other end with the words “worst pain imaginable” or value 10, with intermediate values from 1 to 9. Each patient was instructed how to use the scale and asked to mark the intensity of pain at 2, 4, 6, 8, 12, and 24 h after biopsy, and daily for the next 6 days. The measurements were recorded by patients at home always at 12:00 p.m. and after 7 days from biopsy they have been visited (Fig. 6).

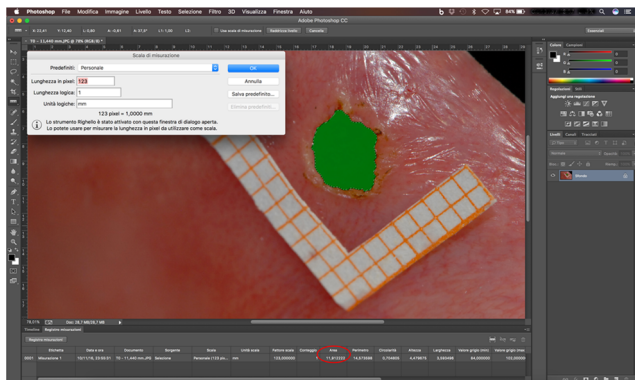


Fig. 5 Use of graphics software (ADOBE PHOTOSHOP CC®, Adobe Systems). After having delimited the lesion edges and set 1 mm value with benchmark, the area has been calculated in square millimeters

After this clinical section, patients’ age and gender, biopsy site, PHI at T1, PHI at T2, and pain felt have been collected and statistically analyzed.

Statistical analysis

Data were statistically described in terms of mean, standard deviation (SD), median and range, or frequencies (number of cases) and percentages when appropriate. For comparing categorical data, chi-square test was performed. Comparison of PI between the groups for any interval time and comparison of PHI between the groups was done using Kruskal-Wallis test with multiple post hoc two-group comparisons. Exact test was used instead when the expected frequency is less than 5. *p*-values less than 0.05 were considered statistically significant. All statistical calculations were done using computer program GraphPad 7 (GraphPad Software, La Jolla, CA) for Mac Os.

Results

A total of 56 patients, 37 female and 19 male, were included, with a drop out of 16% for a total of 47 patients.

All the data about sex, age, and biopsy site in every group are reported in Table 1.

The study resulted to be properly randomized.

The statistical analysis showed a *p* value of 0.844 for gender and a *p* value of 0.611 for anatomical area, while for age test showed a *p* value of 0.137, with no statistically significant difference between three groups.

The test for the wound areas in the three groups showed that there was no statistically significant difference ($p = 0.427$) between the average wound area at T0 in all of them.

The mean area value was also calculated, resulting 50.92 mm^2 in SG (SD = 41.1) with a range of 6.52 to 154.9, for CG was 60.98 mm^2 (SD = 38.41) with range of 5.91 to 129.5, while in PG was 42.44 mm^2 (SD = 22.08) (Figs. 7 and 8). The CONSORT flowchart of the study is reported in Fig. 9.

PHI values at T1 of SG, CG, and PG are reported in Table 2. The difference between SG and CG was 8.58%, while a difference of 12.7% between SG and PG was observed. Testing the difference between the three groups with Kruskal-Wallis test revealed a nonsignificant difference ($p = 0.260$) for PHI at T1. The multiple comparison test shows a nonsignificant difference.

PHI values at T2 of SG, CG, and PG are reported in Table 2 too. A difference of 16.56% between SG and CG and a difference of 15.37% between SG and PG was observed.

The Kruskal-Wallis test revealed a significant difference ($p = 0.001$) for PHI at T2 between three groups. The multiple comparison test of SG with CG shows a significant difference ($p = 0.010$), same thing for SG with PG ($p = 0.002$), while the

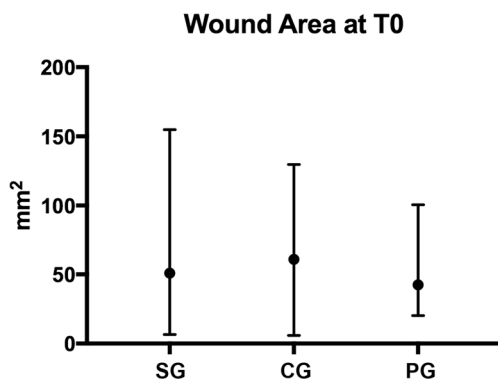


Fig. 7 The graph is mean with range ($p = 0.427$)

maximum reduction of 0.4 point between time point was shown from 12 to 24 h.

Finally, statistical analysis did not find a significant difference in any time interval between the three considered groups.

Discussions

This randomized double-blind clinical study, was performed to evaluate the efficacy of a solution composed by sodium hyaluronate and chlorhexidine digluconate comparing it with a chlorhexidine digluconate solution and a placebo solution in secondary intention healing process and postoperative suffered pain, after excisional biopsy of the oral mucosa.

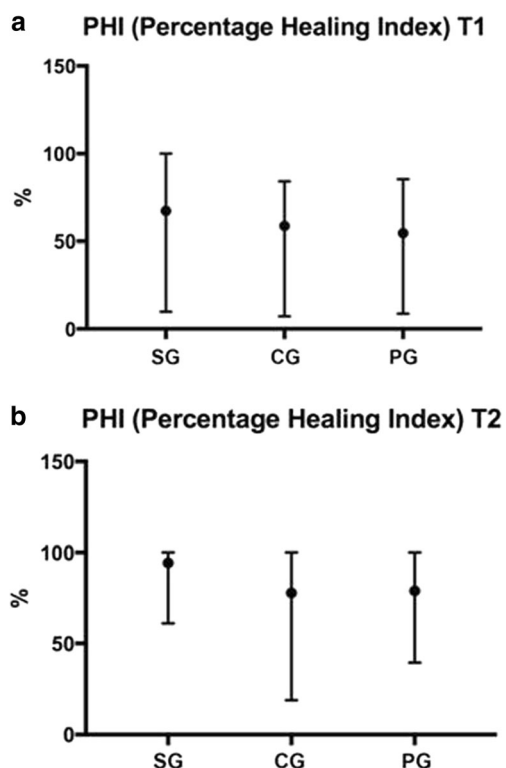


Fig. 8 a, b The graph is mean with range ($p = 0.260$ and $p = 0.001$)

A three-group RCT was planned instead of a two-group because of the evaluation of the efficacy of chlorhexidine alone or in combination with sodium hyaluronate. A placebo group was fundamental especially to evaluate pain perception.

The management of post-surgical wounds aims to wound healing as soon as possible, obtaining a smooth surface, without scars or retracting injury and minimizing pain and discomfort for the patient. An improvement of repair process and reduction of pain may increase the postoperative comfort of the patients. Tissue repair can be adversely affected by many factors such as infections, hypoxia, metabolic disorders such as diabetes mellitus, and presence of necrotic tissue [20].

The presence of a greater or lesser amount of hyaluronic acid affects the clinical response of healing processes. That is to say, the difference in the response depends on the levels and the concentrations of hyaluronic acid [21].

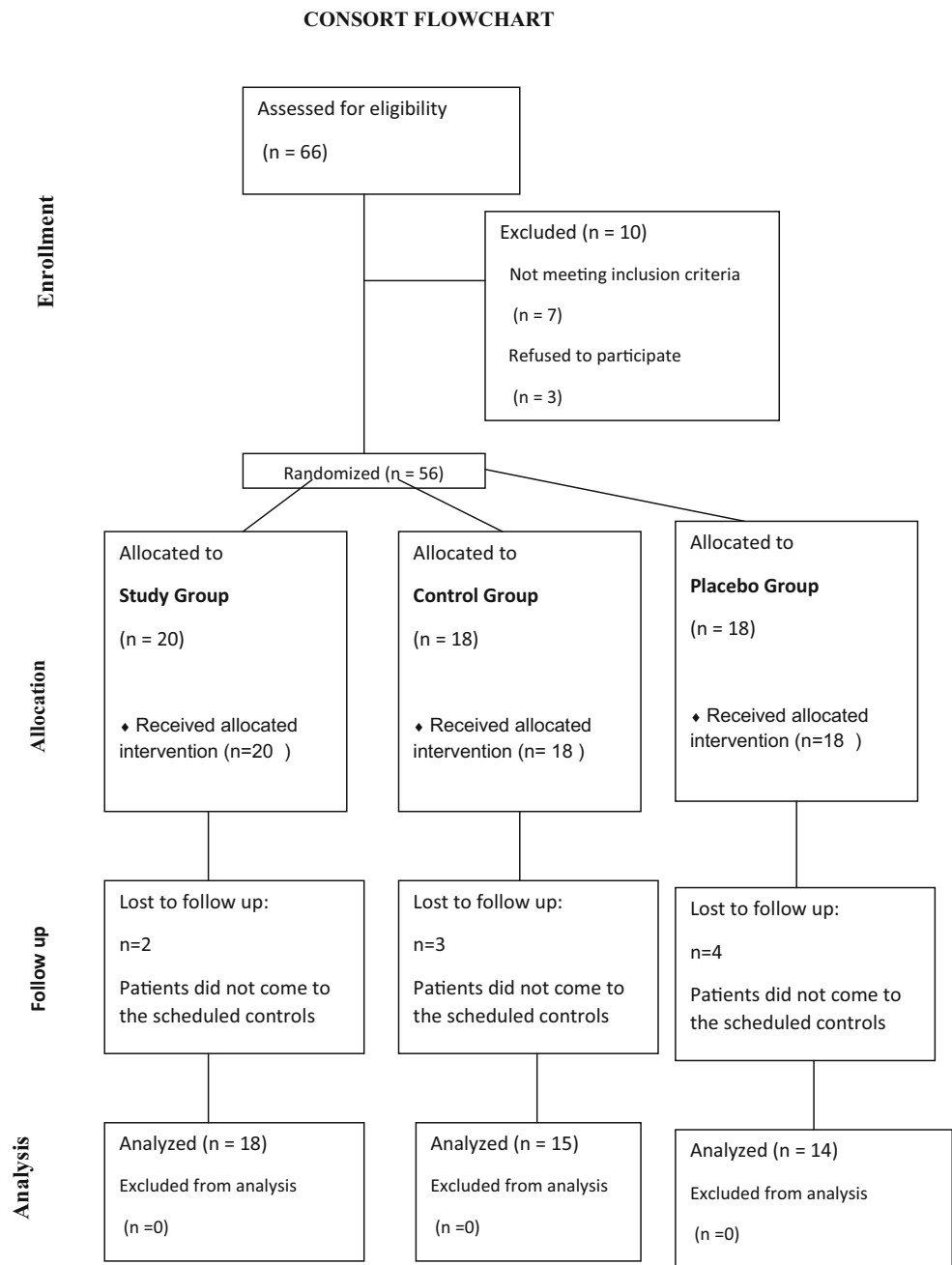
From these clinical evidence, it is clear that, during the healing of tissues, to have hyaluronic acid gives the fabric a constant supply of a risk factor for the reconstitution of the original tissue architecture [22].

Due to the role that hyaluronic acid have in faster resolution of post-surgical wound, a solution with chlorhexidine digluconate and sodium hyaluronate has been recently and systematically used with clear protocols in order to check the real benefits that it can lead both about the timing of the pathology resolution and the correct and less traumatic as possible post-operative course. The used compound contains purified water, xylitol, propylene glycol, Peg-40 hydrogenated castor oil, ascorbic acid, chlorhexidine digluconate, sodium hyaluronate, aroma, poloxamer 407, sodium metabisulfite, sodium citrate, and citric acid.

According to wound healing, it has been shown that after 7 days from laser surgery, in the SG, the average percentage of healing was higher than compared to the CG, treated only with chlorhexidine, and PG treated with a neutral solution, with nonsignificant difference between the groups. Moreover, after 14 days, the results showed even more marked differences between the SG and the remaining two groups and a healing rates close to 100%, with a statistically significant difference ($p = 0.001$).

The effect of the compound, especially for the presence of sodium hyaluronate, seems to show a greater efficacy in the late stage of the wound healing, probably due to the fact that the fibroblasts and their products are involved in the third phase of wound healing, defined proliferation. Therefore, in the study group, where patients have been subjected to the administration of the compound with sodium hyaluronate and chlorhexidine, there was a more rapid healing of the surgical wound, thanks to its chemical-physical and biological characteristics in promoting the process wounds repair, in terms of fibroblast proliferation, granulation tissue formation, deposition of collagen, and stimulation of the production of

Fig. 9 CONSORT flowchart



growth factors involved in the deposition of the extracellular matrix and in the vasculature.

The results obtained in this study are generally in line with those described in the literature, where sodium hyaluronate action has been well shown.

Colella et al. [23, 24] have studied and analyzed the mechanisms involved in wound healing and the molecular changes induced in keratinocytes and fibroblasts through the use of sodium hyaluronate alone or in combination with synthetic amino acids, concluding that the HA is able to induce changes in expression of genes related to the migratory phenotype of the keratinocytes and promote the

activity of fibroblasts by promoting re-epithelialization and wound closure. As reported by other studies [25], the application of gel with sodium hyaluronate and amino acids in wound healing of soft tissue and hard tissue after tooth extraction showed a higher average percentage of healing with regard to both soft and hard tissue.

In this study, the wound area treated only with chlorhexidine (CG) showed a higher PHI than the PG at T1, while at T2 (14 days) showed an average of percentage healing index lower than PG with nonsignificant difference in multiple comparison test. This is probably due to the effect of chlorhexidine both on bacterial load in the early stage of wound healing,

Table 2 PHI values at T1 and T2

Group	PHI (T1)	PHI (T2)
SG	67.25% (SD = 26.94, 95%CI between 56.25 and 80.65) with a range from 9.84 to 100%	94.35% (SD = 10.18, 95%CI between 89.29 and 91.41) with a range from 61.09 to 100%
CG	58.67% (SD = 21.7, 95%CI between 46.63 and 70.67) with a range from 7.14 to 84.24%	PHI at T2 of 77.79% (SD = 22.55, 95%CI between 65.30 and 90.28) with a range from 18.88 to 100%
PG	PG showed an average PHI at T1 of 54.55% (SD = 24.18, 95%CI between 40.59 and 68.51) with a range from 8.63 to 85.46%	78.98% (SD = 15.5, 95%CI between 70.03 and 87.93) with range from 39.48 to 100%

particularly in inflammatory phase, and on fibroblasts more present in a late stage, particularly in the proliferation phase.

In fact, the use of chlorhexidine during wound healing is based on the concept that it is able to reduce the bacterial load of the wound area. The role of bacteria in delaying wound healing has been established [26]. Wound infection interferes with the normal wound healing process [27, 28]; conversely, a low bacterial load can positively influence wound healing, accentuating the inflammatory reaction, essential for tissue healing [29].

In addition to this, there are several studies about the use and the capability of chlorhexidine showing important contradiction on its effect on wound healing. Different *in vitro* studies showed that chlorhexidine negatively affected fibroblast and keratinocyte proliferation in a degree concentration and time dependent [30–33]. On the other side, only few *in vivo* studies showed a negative effect of chlorhexidine [34, 35]. This contradiction can be explained because of the different cellular and molecular interactions happening *in vitro* and *in vivo*.

In particular, in the oral cavity, the chlorhexidine primarily binds to bacteria and an additional amount of applied chlorhexidine is precipitated by proteins [36, 37]. Therefore, the remaining chlorhexidine, addressed to bind cells in the wound area, is reduced [38].

Kozlovsky et al. [38] found that chlorhexidine enhanced wound healing significantly at the histological level but not at the clinical level. Another study on wound healing in rats revealed that wound healing was disturbed by a 0.5% chlorhexidine and delayed with a concentration of 0.1% and 0.2% [34].

In order to measure wound healing, the traditional digital photograph assessment was performed. Nowadays, this is the most used method, although other techniques using laser-assisted wound measurement (LAWM) device were reported in literature [39].

Furthermore, considering the pain as a subjective feeling, the response to painful stimuli depends on personal, cultural, and social factors [40]. This study uses a subjective evaluation of postoperative pain, reported by the patient through a NRS, a simple method of self-rating subjective sensations that is considered a valid method of pain evaluation [41, 42].

A pilot study from Vescovi et al. [43] showed that a compound of amino acids and sodium hyaluronate gel based

promotes not only an improvement in the healing process but also a lower and thus better perception of pain in the immediate postoperative period. These authors performed biopsies of benign oral lesions with the laser, subdividing patients into two groups. A better algic response was shown in patients to whom was administered and recommended the application of a basis of amino acids and sodium hyaluronate gel.

In our study results, the perceived pain considerably varies. In fact, the use of the compound showed a similar pain reduction into the three groups. However, the values do not appear to be statistically significant among these.

Therefore, the evaluation of postoperative pain perception tends to differ, depending not only on the used compound but also on the individual perception, on the location of the lesion in the oral cavity and on the size of the lesion, which can have a big impact on the perception.

The limitations of our study mainly concern the number of samples and the comparison of wound healing in various oral anatomical areas. Each site of the oral cavity may have different healing times, depending on the type of epithelium and the type of function, so large numbers are required to make a definitive assessment.

Conclusions

The results of the study showed that the application of a solution with a compound of sodium hyaluronate and chlorhexidine digluconate on surgical wounds after oral mucosa laser biopsy can significantly improve the healing process and then wound healing. So, the use of this compound can be recommended in all cases where laser surgical procedures are needed, in order to better achieve a healing by secondary intention. Therefore, even if the followed protocol showed the effectiveness and validity of the product with excellent properties in tissue repair, more cases are needed to better minutely investigate its action.

Funding This research has been financially supported by CURADEN HEALTHCARE. The protocol and data presented have been carried out by the authors.

Table 3 Incidence and severity of pain during 7 days

Interval after biopsy	Study group SH + CHX			Control group CHX			Placebo group Neutral			<i>p</i> value
	Mean	Range	Pain reduction from peak	Mean	Range	Pain reduction from peak	Mean	Range	Pain reduction from peak	
2 h	2	(0-7)	^a	1.2	(0-4)	^a	1.2	(0-7)	^a	
4 h	2.1 (SD=2.2)	(0-6)	Max peak	1.3 (SD=1.6)	(0-5)	Max peak	1.8 (SD=2.2)	(0-7)	Max peak	0.644
6 h	1.8 (SD=1.9)	(0-6)	-0.3	1 (SD=1.5)	(0-5)	-0.3	1.8 (SD=2.3)	(0-7)	0	0.404
8 h	1.8 (SD=2)	(0-6)	-0.3	0.6 (SD=1)	(0-3)	-0.7	1.8 (SD=2.5)	(0-7)	0	0.130
12 h	1.5 (SD=1.7)	(0-5)	-0.6	0.6 (SD=1)	(0-3)	-0.7	1.5 (SD=2.2)	(0-7)	-0.3	0.138
24 h	1.3 (SD=1.7)	(0-5)	-0.8	0.4 (SD=0.9)	(0-3)	-0.9	1.2 (SD=2.0)	(0-7)	-0.6	0.133
2 d	1.1 (SD=1.6)	(0-5)	-1	0.4 (SD=0.7)	(0-2)	-0.9	0.9 (SD=1.6)	(0-6)	-0.9	0.519
3 d	1.1 (SD=1.5)	(0-5)	-1	0.4 (SD=0.9)	(0-2)	-0.9	0.6 (SD=1.1)	(0-4)	-1.2	0.339
4 d	0.8 (SD=1.4)	(0-4)	-1.3	0.3 (SD=0.7)	(0-3)	-1	0.6 (SD=0.9)	(0-3)	-1.2	0.653
5 d	0.6 (SD=1.2)	(0-4)	-1.5	0.3 (SD=0.5)	(0-2)	-1	0.5 (SD=0.8)	(0-3)	-1.3	0.802
6 d	0.5 (SD=0.9)	(0-3)	-1.6	0.3 (SD=0.7)	(0-3)	-1	0.3 (SD=0.6)	(0-2)	-1.5	0.751
7 d	0.4 (SD=0.8)	(0-4)	-1.7	0.2 (SD=0.5)	(0-2)	-1.1	0.2 (SD=0.5)	(0-2)	-1.6	0.782

Data presented as mean, with range in parentheses

SH sodium hyaluronate, CHX chlorhexidine

^a It is supposed that this value is still suffering from the effect of anesthesia

Compliance with ethical standards

Conflict of interest Gaspare Palaia has received a research grant from “Sapienza” University of Rome. The funds have been provided by CURADEN HEALTHCARE.

Gianluca Tenore has no conflict of interest.

Luca Tribolati has no conflict of interest.

Claudia Russo has no conflict of interest.

Gianfranco Gaimari has no conflict of interest.

Alessandro Del Vecchio has no conflict of interest.

Umberto Romeo has no conflict of interest.

Ethical approval All procedures performed in studies involving human participants were in accordance with the ethical standards of the institutional and/or national research committee and with the 1964 Helsinki declaration and its later amendments or comparable ethical standards.

Informed consent Informed consent was obtained from all individual participants included in the study.

Open Access This article is distributed under the terms of the Creative Commons Attribution 4.0 International License (<http://creativecommons.org/licenses/by/4.0/>), which permits unrestricted use, distribution, and reproduction in any medium, provided you give appropriate credit to the original author(s) and the source, provide a link to the Creative Commons license, and indicate if changes were made.

References

- Kearns HPO, McCartan BE, Lamey PJ (2000) Patients' pain experience following oral mucosal biopsy under local anaesthesia. *Br Dent J* 190:33
- Romeo U, Russo C, Palaia G, Lo Giudice R, Del Vecchio A, Visca P, Migliau G, De Biase A (2014) Biopsy of different oral soft tissues lesions by KTP and diode laser: histological evaluation. *ScientificWorldJournal* 2014:761704. <https://doi.org/10.1155/2014/761704>
- Palaia G, Del Vecchio A, Impellizzeri A, Tenore G, Visca P, Libotte F, Russo C, Romeo U (2014) Histological ex vivo evaluation of peri-incisional thermal effect created by a new generation CO2 superpulsed laser. *ScientificWorldJournal* 2014:345685. <https://doi.org/10.1155/2014/345685>
- Romeo U, Libotte F, Palaia G, Del Vecchio A, Tenore G, Visca P, Nammour S, Polimeni A (2012) Histological in vitro evaluation of the effects of Er:YAG laser on oral soft tissues. *Lasers Med Sci* 27(4):749–753. <https://doi.org/10.1007/s10103-011-0969-z>
- Pick RM, Colvard MD (1993) Current status of lasers in soft tissue dental surgery. *J Periodontol* 64:589–602
- Goharkhay K, Moritz A, Wilder-Smith P, Schoop U, Kluger W, Jakolitsch S, Sperr W (1999) Effects on oral soft tissue produced by a diode laser in vitro. *Lasers Surg Med* 25:401–406
- Romanos GE, Pelekanos S, Strub JR (1995) Effects of Nd:YAG laser on wound healing processes: clinical and immunohistochemical findings in rat skin. *Lasers Surg Med* 16:368–379
- Romanos GE, Pelekanos S, Strub JR (1995) A comparative histological study of wound healing following Nd:YAG laser with different energy parameters and conventional surgical incision in rat skin. *J Clin Laser Med Surg* 13:11–16
- Tomasek JJ, Gabbiani G, Hinz B, Chaponnier C, Brown RA (2002) Myofibroblasts and mechano-regulation of connective tissue remodelling. *Nat Rev Mol Cell Biol* 3:349–363
- Clark RA (2001) Fibrin and wound healing. *Ann N Y Acad Sci* 936:355
- Hammad HM, Hammad MM, Abdelhadi IN, Khalifeh MS (2011) Effects of topically applied agents on intra-oral wound healing in a rat model: a clinical and histomorphometric study. *Int J Dent Hyg* 9:9–16
- Chen WY, Abatangelo G (1999) Functions of hyaluronan in wound repair. *Wound Repair Regen* 7:79–89
- Gontiya G, Galgali SR (2012) Effect of hyaluronan on periodontitis: a clinical and histological study. *J Indian Soc Periodontol* 16:184–192
- Moseley R, Waddington RJ, Embery G (2002) Hyaluronan and its potential role in periodontal healing. *Dent Update* 29:144–148
- Mariggio MA, Cassano A, Vinella A et al (2009) Enhancement of fibroblast proliferation, collagen biosynthesis and production of growth factors as a result of combining sodium hyaluronate and aminoacids. *Int J Immunopathol Pharmacol* 22:485–492
- Romeo U, Libotte F, Palaia G, Galanakis A, Gaimari G, Tenore G, Del Vecchio A, Polimeni A (2014) Oral soft tissue wound healing after laser surgery with or without a pool of amino acids and sodium hyaluronate: a randomized clinical study. *Photomed Laser Surg* 32(1):10–16. <https://doi.org/10.1089/pho.2013.3509>
- Ford SJ (2008) The importance and provision of oral hygiene in surgical patients. *Int J Surg* 6:418–419
- Hita-Iglesias P, Torres-Lagares D, Flores-Ruiz R, Magallanes-Abad N, Basallote-Gonzalez M, Gutierrez-Perez JL (2008) Effectiveness of chlorhexidine gel versus chlorhexidine rinse in reducing alveolar osteitis in mandibular third molar surgery. *J Oral Maxillofac Surg* 66:441–445
- Jones CG (1997) Chlorhexidine: is it still the gold standard? *Periodontol* 15(55):55–62
- Hirsch T, Spielmann M, Zuhaili B, Koehler T, Fossum M, Steinau HU, Yao F, Steinstraesser L, Onderdonk AB, Eriksson E (2008) Enhanced susceptibility to infections in a diabetic wound healing model. *BMC Surg* 8:5
- Deed R, Rooney P, Kumar P, Norton JD, Smith J, Freemont AJ, Kumar S (1997) Early response gene signalling is induced by angiogenic oligosaccharides of hyaluronan in endothelial cells. Inhibition by non-angiogenic, high-molecular weight hyaluronan. *Int J Cancer* 71(2):251–256
- Favia G, Mariggio MA, Maiorano F, Cassano A, Capodiferro S, Ribatti D (2008) Accelerated wound healing of oral soft tissue and angiogenic effect induced by a pool of aminoacids combined to sodium hyaluronate (AMINOGAM). *J Biol Regul Homeost Agents* 22(2):109–116
- Colella G, Vicidomini A, Soro V, Lanza A, Cirillo N (2012) Molecular insights into the effects of sodium hyaluronate preparations in keratinocytes. *Clin Exp Dermatol* 37(5):516–520
- Colella G, Vicidomini A, Cirillo N, Gaeta GM, D'Amato S (2009) Aminoacid-enriched sodium hyaluronate enhances keratinocyte scattering, chemotaxis and wound healing through integrin beta1-dependent mechanism. *J Stomatol Invest* 3(1):21–29
- Romeo U, Tenore G, Buschini M, Lerario F, Palaia G (2016) Evaluation of post-extraction sites healing through the application of a gel based on amino acids and sodium hyaluronate. *Dental Cadmos* 84(4):249–260
- Robson MC, Hegggers JP (1984) Quantitative Bacteriology and Inflammatory mediators in soft tissue. *Soft and hard tissue repair*. Praeger, New York
- Penhallow K (2005) A review of studies that examine the impact of infection on the normal wound healing process. *J Wound Care* 14:123–126
- Tenenhaus M, Bhavsar D, Rennekampff HO (2007) Diagnosis and surgical management in wound bacterial burden. In: Granick MS, Gam-elli RL (eds) *Surgical wound healing and management*. Informa Healthcare USA, Inc, New York, pp 29–37

29. Ha inen L, Uitto VJ, Larjava H (2000) Cell biology of gingival wound healing. *Periodontol* 24:127–152
30. Damour O, Hua SZ, Lasne F, Villain M, Rousselle P, Collombel C (1992) Cytotoxicity evaluation of antiseptics and antibiotics on cultured human fibroblasts and keratinocytes. *Burns* 18:479–485
31. Pucher JJ, Daniel JC (1992) The effects of chlorhexidine digluconate on human fibroblasts in vitro. *J Periodontol* 63:526–532
32. Mariotti AJ, Rumpf DA (1999) Chlorhexidine-induced changes to human gingival fibroblast collagen and non-collagen protein production. *J Periodontol* 70:1443–1448
33. Hidalgo E, Dominguez C (2001) Mechanisms underlying chlorhexidine-induced cytotoxicity. *Toxicol in Vitro* 15:271–276
34. Bassetti C, Kallenberger A (1980) Influence of chlorhexidine rinsing on the healing of oral mucosa and osseous lesions. *J Clin Periodontol* 7:443–456
35. Salami A, Imosemi I, Owoye O (2006) A comparison of the effect of chlorhexidine, tap water and normal saline on healing wounds. *Int J Morphol* 24:673–676
36. Schiott CR, Lo e H, Jensen SB, Kilian M, Davies RM, Glavind K (1970) The effect of chlorhexidine mouthrinses on the human oral flora. *J Periodontal Res* 5:84–89
37. Hjeljord LG, Rolla G, Bonesvoll P (1973) Chlorhexidine-protein interactions. *J Periodontal Res Suppl* 12:11–16
38. Kozlovsky A, Artzi Z, Hirshberg A, Israeli-Tobias C, Reich L (2007) Effect of local antimicrobial agents on excisional palatal wound healing: a clinical and histomorphometric study in rats. *J Clin Peri-odontol* 34:164–171
39. Fisher SE, Frame JW, Rout PG, McEntegart DJ (1988) Factors affecting the onset and severity of pain following the surgical removal of unilateral impacted mandibular third molar teeth. *Br Dent J* 164:351–354
40. Constantine RS, Bills JD, Lavery LA, Davis KE (2016) Validation of a laser assisted wound measurement device in a wound healing model. *Int Wound J* 13(5):614–618. <https://doi.org/10.1111/iwj.12328>
41. Seymour RA, Meechan JG, Bair GS (1985) An investigation into post-operative pain after third molar surgery under local anaesthesia. *Br J Oral Maxillofac Surg* 23:410–418
42. Melzak R (1975) The McGill pain questionnaire: major properties and scoring methods. *Pain* 1:277–299
43. Vescovi P, Manfredi M, Sarraj A, Meleti M, Merigo E et al (2011) Gestione del dolore postoperatorio dopo chirurgia laser. Studio preliminare sull'impiego dell'Aminogam gel. *Laser Tribune Italian Edition* 3(2):14–17