

Assessment and therapeutic choice in septic arthritis of the hip in an intravenous drug abuser: case report at 14 years follow-up and review of literature

P. Persiani¹, F.M. Ranaldi¹, O. Mazza², A. Calistri¹, M. Bove¹, M. Crostelli², C. Villani¹

¹ Department of Anatomical, Histological, Forensic Medicine and Musculoskeletal System Sciences - Sapienza University of Rome;

² IRCCS Bambino Gesù Pediatric Hospital- Palidoro (Roma)

Abstract

Introduction. Osteoarticular infections are found frequently in drug addicted individuals, representing one of the main reasons for their hospitalization. Through inoculation, the pathogenic agents can enter the individual's system directly through the skin or parenterally, transmitted, that is, through syringes and other objects used during such practice.

In these particular conditions, or when the medical history is vague, a warranted suspicion and the execution of targeted research can help in the diagnosis of high-risk patients such as addicts.

Discussion. With this paper, the Authors are presenting a case of septic arthritis in the hip joint, in a drug addicted patient with the habit of injecting narcotics into the femoral vein, in correspondence of the anatomical region known as the triangle of Scarpa. Following an examination of the bacterial culture samples taken by arthrocentesis, the *S. Aureus* infection was identified and a targeted antibiotic therapy (coxacillin and aminoglycosides) was prescribed.

After one year, with clinical examination and medical scans resulting negative for infection, there was a remaining deformity of the femoral head and, therefore, a total hip arthroplasty (THA) was performed. The 14 year post-operative clinical examination and medical scan check-up showed a complete articular functionality and recovery of normal daily and work related activities. *Clin Ter* 2017; 168(1):e8-13. doi: 10.7417/CT.2017.1975

Key words: Hip arthroplasty, Septic Hip Arthritis, Intravenous Drug abuser, Heroin Addiction

Introduction

Intravenous drug abuse has caused an increase of hematogenous infections such as abscesses, phlebitis, endocarditis and osteomyelitis. The pathogen could be present in the substance injected, in the syringe or on the needle. The pathogens responsible for the infections in the addict population are the *S. Aureus* in 41.5%, the *P. Aeruginosa* in 36.8%, the *Streptococcus* spp. in 8.3%, the *S. Marcescens* in the 5% and other Gram-negative bacteria in 2.3% (1, 2, 3, 4, 5, 6, 7, 8, 9, 10, 11, 12).

The patient's skin is considered the most likely source of infection, due to the micro-lesions resulting from the direct penetration of the needle into a vein. In fact, although the *S. Aureus* pathogen is not present in significant concentrations in the samples of "street" heroin and on used syringes, it is present on the skin (20%) and at the mucosal level (30%) in significantly higher concentration in drug addicts than in the population of reference (13). In addition, the substances injected in the cutaneous sites cause alterations of the antimicrobial capacity of the phagocytes, promoting the formation of biofilms, which is the starting point of progressive sepsis (14, 15).

The habits or rituals of the addict, such as the exchange and/or use of non-sterile syringes, and the use of tap water or saliva to dissolve the drug, are undoubtedly additional risk factors for infection.

The most frequent septic arthritides, in drug addicted individuals who inject narcotic substances intravenously, are at the level of the sterno-costal (10.6%), sterno-clavicular (18.5%), sacroiliac (30.9%), pubic symphysis (8.8%), hip (7.4%), knee (18.5%), shoulder and ankle (17.5%) articulations (13, 16). Moreover, in a revision by Munoz-Fernandez (1993), out of a total of 567 drug addicted patients who used intravenously (Intravenous Drug Abusers - IVDA), of which 482 HIV-positive and 85 HIV negative, the osteoarticular infections were at the level of the hip (26%), sacroiliac (22%), sterno-costal (19%), and knee (13%) articulations. The pathogens that caused these infections were *S. Aureus* (55%), *C. Albicans* (19%), *M Tuberculosis* (6%) and other pathogens (19%) (17).

Drug addicts are also at risk of epiphyseal aseptic bone necrosis (especially of the femoral head), due to the obliteration of the epiphyseal arteries, a mechanism that is both hemolytic and thrombotic. The first seems due to the self-administration of solutions capable of inducing hemolysis, such as distilled or saline water. The second mechanism, the thrombotic one, depends from the release in the circulation of inert corpuscular substances (talc, chalk, marble dust) with which the heroin is cut (18, 19, 20). Drug abuse can cause hepatic disease, which represents one of the possible

Correspondence: Filippo Maria Ranaldi, P.le Aldo Moro, 5 – 00185 Rome (Italy). Tel.: +393381998818.

E-mail: filippom.ranaldi@gmail.com

etiological factors in the cause of osteonecrosis (21). In fact, studies conducted by Jacobs, already back in 1978, led the Author to place the only case of septic osteonecrosis observed in a heroin addict in the section about hepatic diseases. This connection between hepatic diseases and avascular necrosis of the femoral head (ANFH) was later confirmed by other authors (22, 23).

The humoral or cell-mediated immunity defects, typical of this population, also need to be considered (24, 25, 26).

Clinical case

On February of 1999, a 32-year old Hepatitis C Virus (HCV) positive drug addict, with an intravenous heroin drug habit since 1983, was hospitalized in the Department of Anatomical, Histological, Forensic and Locomotive System Sciences of the Sapienza University of Rome, due to functional impairment and widespread pain. The patient reported that for the past 5 months he was experiencing back pain, which propagated acutely throughout the lower left limb, exacerbated by walking and active/passive movements of the hip. The medical history referred of another hospitalization in another structure, due to a left side thigh pain, which was unsuccessfully treated with a medical therapy.

Clinically, the patient appeared agitated and not very cooperative, forcibly lying down on his right side with his left hip adducted. Objectively, no signs of lumbar radiculopathy were detected. Violent pain was evident in changes of position and when testing the articulation of the left hip. There was fibrosis present in the groin area, precisely in the site where, by his own admission, the patient injected the heroin.

The haematochemical values (blood sedimentation, C-reactive protein, Leucocytes) indicated an ongoing infectious process.

The radiographic examination of the pelvis showed a reduction in the local bone mineralization, a diastasis of the joint line and areas of bone resorption at the level of the proximal epiphysis of the femur (Fig. 1).

The ultrasound, performed in proximity of the fibrotic area, showed a femoral vein with a fibrotic pattern and an articular effusion. A sample of the purulent-serum material was obtained by arthrocentesis and sent for cultural examination, and an empirical broad spectrum antibiotic therapy was started.

While waiting for the cultural examination, a hip MRI with contrast (gadolinium) was performed, axial and coronal background planar scans, which showed an intra-articular effusion, with a distension of the joint capsule and a severe remodelling of the femoral head (Fig. 2).

Lastly, a labelled leukocytes scintigraphy (Fig. 3) showed an area of specific concentration at the root of the left thigh.

Based on the cultural examination, which isolated the *S. aureus* pathogen, the patient was prescribed a targeted antibiotic therapy with vancomycin (20 mg/kg i.v. twice a day) and rifampicin (450 mg i.v. twice a day) for 6 weeks.

At 3 months, the clinical picture showed improvement with negative blood serum tests and diagnostic imaging.

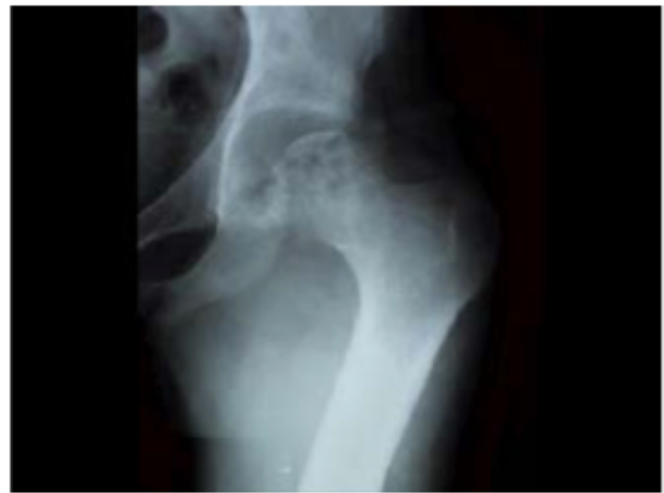

Fig. 1. Hip X-ray at the moment of diagnosis, showing lesser bone mineralization, opening of the joint surfaces and bone turnover areas on proximal femoral epiphysis.

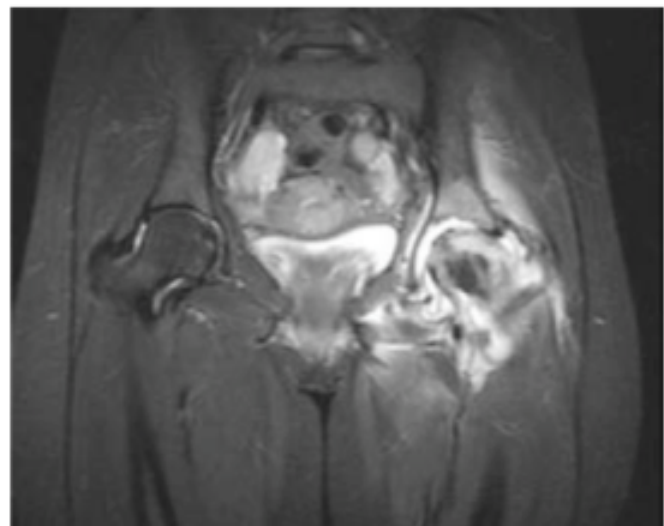


Fig. 2. MRI with gadolinium contrast showing intrarticular stiffness of the hip joint, with severe bone turnover on femoral head.

After a year, the patient was declared cured of the infectious process, but had pain in his left hip, which did not respond to NSAID therapy, a limited range of motion (ROM), was walking with canadian crutches and unable to perform normal daily activities. X-rays (Fig. 4), showed an osteonecrosis of the femoral head.

The patient consequently, after an ulterior labelled leukocytes scintigraphy that came back negative and informed of the possible risks of reactivation of the infectious process, underwent a cementless Total Hip Arthroplasty (THA), with a hydroxyapatite-coated, ceramic on ceramic, anatomic medullary locking stem (Fig. 5). At the 14 year post-operative follow up, the patient recovered and maintained full range of motion, was walking without pain and had correct trophic muscle tone, without radiographic

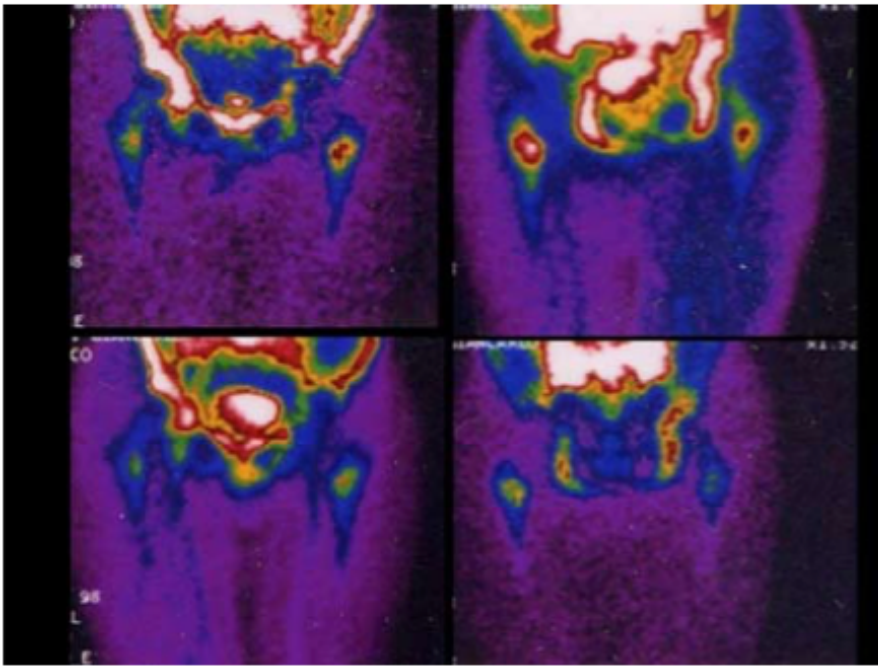


Fig. 3. In-labeled leukocyte scintigraphy: a specific isotope concentration area was marked on the proximal side of the left thigh.

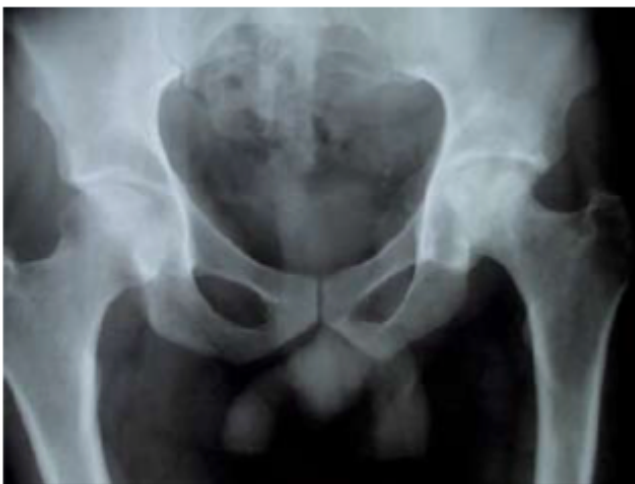

Fig. 4. Hip X-ray 1 year after treatment shows the femoral head necrosis due to the septic arthritis.

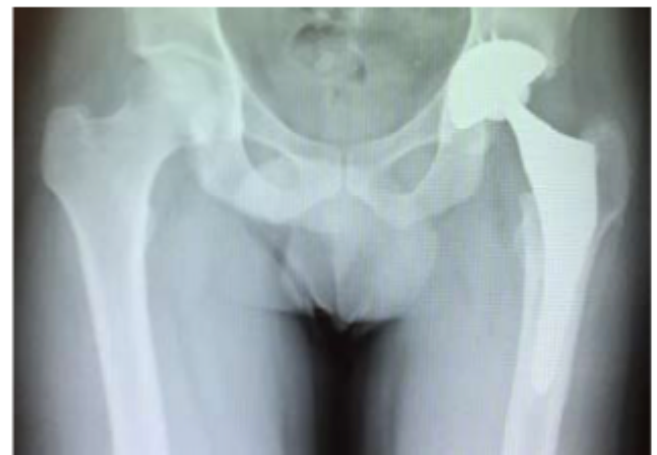

Fig. 5. Hip X-ray in anterior-posterior projection, after total hip arthroplasty surgical treatment.

signs of calcification, areas of peri-implant bone resorption, osteolysis or loosening (Fig. 6, Fig. 7, Fig. 8). There was a persisting lower limb quadriceps circumference of 2.5 cm shorter when compared to the left lower limb. He has been working regularly for the past 9 years and has recovered from the addiction, and is continuing to take medication for the Hepatitis C virus. At his last check-up, in the absence of symptoms and radiographic peculiarities, a squeaking (or creaking) sound was perceived, caused by some friction between the ceramic components of the prosthesis, audible in the movements of flexion-extension of the hip (27). The patient described such noise, which began a few months prior, as an unpleasant subjective sensation that made him apprehensive, leading him to immediately stop or slow down any physical activity. For this reason, he remains under close clinical and radiographic control every six months.

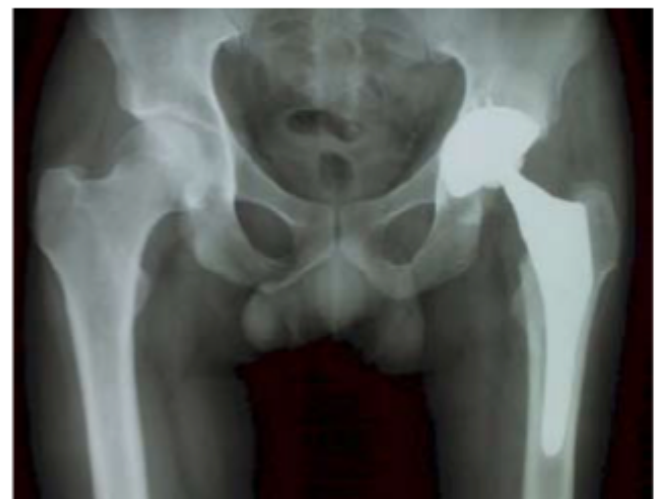

Fig. 6. Hip X-ray in anterior-posterior projection, showing the excellent result on follow up at 14 years.

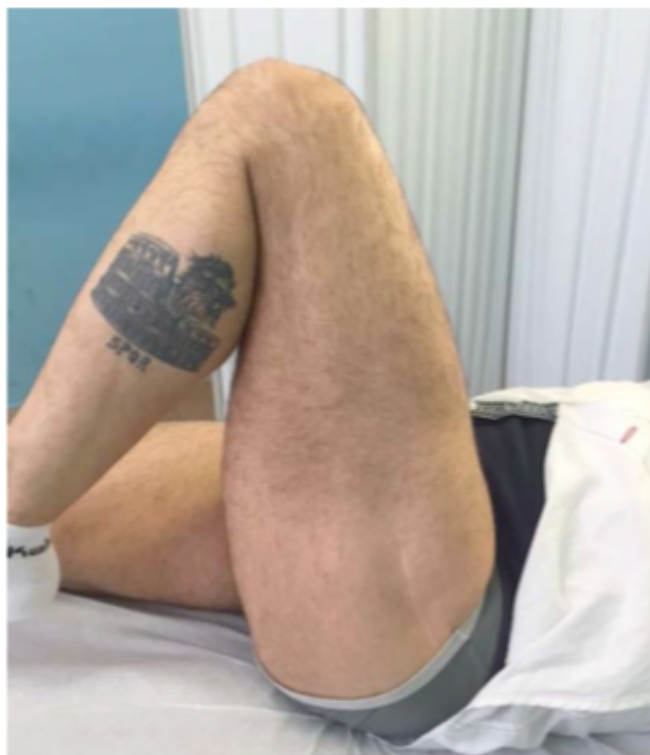

Fig. 7. Clinical evaluation 14 years after treatment shows the complete hip ROM recovery.

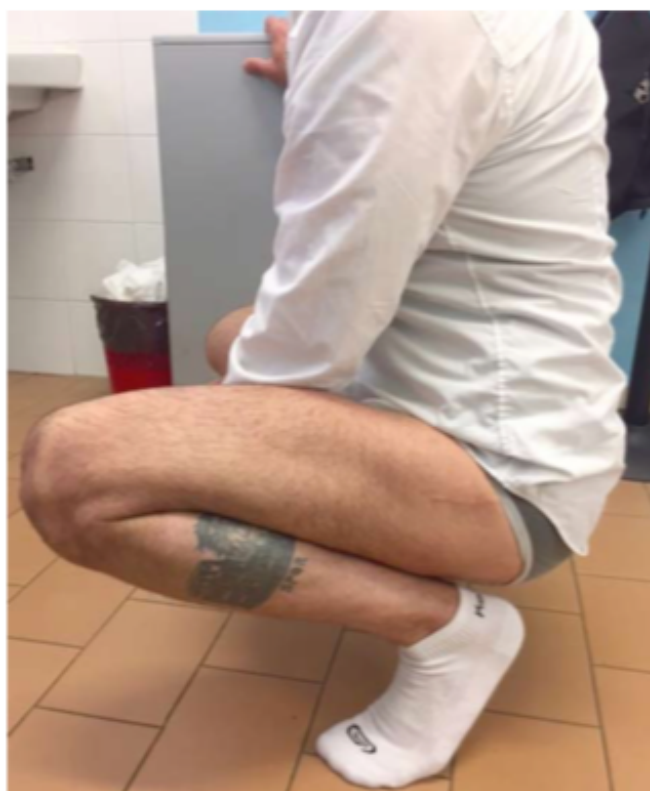

Fig. 8. Clinical evaluation 14 years after treatment shows that the patient is able to squat completely, without any pain or limitation to hip ROM.

Discussion

The complications caused by heroin use have gained increasing attention in the last decades, in particular with regard to the morbidity and mortality due to infections. These are even more common in intravenous drug users compared to HIV-positive patients (28). 70% of the hospitalizations of addicts are due to infectious complications such as endocarditis, hepatitis, thrombophlebitis, pulmonary embolism and pneumopathies (29, 30).

The cutting agents or the contaminated drugs are contagion vectors (31), but also the use of non-sterile needles and syringes play an important role in an infection caused by the *S. Aureus* pathogen.

Bone and joint infections, in the drug addicted population, have been frequently and increasingly reported since their first description in the 70's (32, 33, 34, 35, 36, 37) and are often identified as secondary manifestations of distant primitive infectious processes, such as endocarditis.

In the case presented by the authors, the patient injected himself in the groin area, thus creating the high risk of contagion, initially in the periarticular soft tissues, followed by the hip joint with septic necrosis (38, 39, 40).

The practice of injecting in the femoral vein has been described by various authors over the past five years, in various parts of the world. The choice of such an area, by part of most addicts, is justified as being an injecting site that is still easily accessible after chronic abuse. Another reason is because this is an "unconventional" area or, in some cases, quicker and more convenient to reach (41, 42, 43).

In literature, septic hip arthritides are treated with specific antibiotic therapy, according to the antibiogram developed after the isolation and identification of the pathogen (44). Drug users are generally hepatopathic immunocompromised patients and have a certain susceptibility to pathogenic infections that are multi-antibiotic resistant. This fact is supported by studies that state that drug users, in order to prevent infections due to the injecting practice, are accustomed to abusing antibiotics, especially anti-staphylococcal ones, or to mix a certain amount of antibiotics to their dose in order to prevent infection (8, 45, 46). Therefore, establishing a valid antibiotic therapy for such patients is a difficult task. In the case of osteonecrosis of the femoral head, should be always planned an articular prosthetic replacement. The long term follow up of those patients after surgery could be very difficult and unsuccessful, due to their bad compliance to physical therapy, their immunological deficiency and their social habits, which could compromise together the surgical treatment. In case of surgical revision of the hip prosthesis, it is important to consider and preserve as much as possible the bone stock of the patient, because a higher bone quality is directly connected to best results concerning the functional and radiographic outcome and the low risk of implant loosening (47).

The surgical treatment, however, cannot ignore the correct eradication of the pathogen in the acute phase. Furthermore, the patient needs social and psychological assistance, which has the aim of successfully and permanently freeing him/her from their addiction, thus preventing the replacement artificial hip from getting infected again, something that in patients who are still prone to drug addic-

tion, or are immunocompromised, is highly likely and could prove more difficult to eradicate, as the prosthetic material is typically inert and does not provide a valid systemic immune response.

Conclusions

The risk of joint infection must always be considered in complex patients such as addicts. Early detection, isolation of the pathogen and a targeted therapy for the septic arthritis allows, motivated and cooperative patients, to resolve their infection status. The patient's management should also take into account the treatment of joint outcomes. The therapeutic option with THA should be considered no earlier than one year and only once any infectious process has been totally eradicated with certainty. In this specific case, the therapeutic choice has guaranteed a complete recovery of function and allowed the patient to follow a detox program, and to recover a normal social life as was seen at his 14 years post op check up.

Acknowledgements

The Authors would like to thank Miss Tracy Caputo in quality of translator for her assistance and contribution in translating and improving linguistically the text of the article.

References

- Chandrasekar Pranatharathi H, Narula Amrit P. Bone and joint infections in intravenous drug abusers. *Review of Infectious Diseases*, 1986; 8.6: 904-11
- Lopez-Longo FJ, et al. Primary septic arthritis in heroin users: early diagnosis by radioisotopic imaging and geographic variations in the causative agents. *The Journal of rheumatology*, 1987; 14.5:991-4
- Brancós María A, et al. Septic arthritis in heroin addicts. In: *Seminars in arthritis and rheumatism*. WB Saunders, 1991; 81-7
- Belzunegui J, et al. Musculoskeletal infections in intravenous drug addicts: report of 34 cases with analysis of microbiological aspects and pathogenic mechanisms. *Clinical and experimental rheumatology*, 1999; 18.3:383-6
- Shirliff Mark E, Mader Jon T. Acute septic arthritis. *Clinical microbiology reviews*, 2002; 15.4:527-44
- Kak Vivek, Chandrasekar Pranatharathi H. Bone and joint infections in injection drug users. *Infectious disease clinics of North America*, 2002; 16.3:681-95
- Allison Daniel C, et al. Microbiology of bone and joint infections in injecting drug abusers. *Clinical Orthopaedics and Related Research*, 2010; 468.8:2107-12
- Peterson Todd C, et al. Septic arthritis in intravenous drug abusers: a historical comparison of habits and pathogens. *The Journal of emergency medicine*, 2014; 47.6:723-8
- Dubost JJ, et al. No changes in the distribution of organisms responsible for septic arthritis over a 20 year period. *Annals of the rheumatic diseases*, 2002; 61.3:267-9
- Atkinson SR, et al. The emergence of methicillin-resistant *Staphylococcus aureus* among injecting drug users. *Journal of Infection*, 2009; 58.5:339-45
- Abdissa Senbeta Guteta. Tip of the iceberg: infective endocarditis in an intravenous drug user. *Ethiopian medical journal*, 2015; 53.1:39-42
- Tung Matthew KY, et al. Evolving epidemiology of injecting drug use associated infective endocarditis: A regional centre experience. *Drug and alcohol review*, 2015; 34.4:412-7
- Miro JM, et al. Estudio de la tasa de portadores cutaneomucosos de estafilococos en heroinomanos del area de Barcelona y de las características microbiológicas de la heroína y material de inyección. *Med Clin (Barc)*, 1984; 83:620-3
- Tuazon Carmelita U, Sheagren John N. Staphylococcal endocarditis in parenteral drug abusers: source of the organism. *Annals of internal medicine*, 1975; 82.6:788-90
- Mihu Mircea Radu, et al. Methamphetamine Alters the Antimicrobial Efficacy of Phagocytic Cells during Methicillin-Resistant *Staphylococcus aureus* Skin Infection. *mBio*, 2015; 6.6: e01622-15
- Andersen Kirsten, Bennedbaek FN, Hansen BL. [Septic arthritis in intravenous drug abuse]. *Ugeskrift for laeger*, 1994; 156.26:3876-80
- Munoz-Fernandez S, et al. Osteoarticular infection in intravenous drug abusers: influence of HIV infection and differences with non drug abusers. *Annals of the rheumatic diseases*, 1993; 52.8:570-4
- Boetcher William G, et al. Non-traumatic necrosis of the femoral head. *J Bone Joint Surg Am*, 1970; 52.2:312-21
- Ozkunt Okan, et al. Bilateral avascular necrosis of the femoral head due to the use of heroin: A case report. *International journal of surgery case reports*, 2015; 17:100-2
- Wu Dengke, et al. Avascular necrosis of the femoral head due to the bilateral injection of heroin into the femoral vein: A case report. *Experimental and therapeutic medicine*, 2013; 6.4:1041-3
- Gil-Orbezo F, et al. Nontraumatic causes of bilateral avascular necrosis of the femoral head: link between hepatitis C and pegylated interferon. *Acta Ortopédica Mexicana*, 2015; 29.3: 172-5
- Seamon Jesse, et al. The pathogenesis of nontraumatic osteonecrosis. *Arthritis*, 2012
- Naranje Sameer M, Cheng Edward Y. Epidemiology of osteonecrosis in the USA. In: *Osteonecrosis*. Springer Berlin Heidelberg, 2014; 39-45
- Yombi Jean-Cyr, et al. Osteonecrosis of the femoral head in patients with type 1 human immunodeficiency virus infection: clinical analysis and review. *Clinical rheumatology*, 2009; 28.7: 815-23
- Ríos-olivares Eddy, et al. Impaired cytokine production and suppressed lymphocyte proliferation activity in HCV-infected cocaine and heroin ("speedball") users. *Drug and alcohol dependence*, 2006; 85.3:236-43
- Saviola G, et al. Multifocal osteonecrosis in a patient with anamnestic ulcerative colitis. Is there a relationship with the disease and the use of glucocorticoids twenty years before? A brief review of the literature. *Clin Ter* 2016; Jul-Aug;167(4): 121-3.
- Jarrett Christopher A, et al. The squeaking hip: a phenomenon of ceramic-on-ceramic total hip arthroplasty. *The Journal of Bone & Joint Surgery*, 2009; 91.6:1344-9
- Covelli M, et al. Isolated sternoclavicular joint arthritis in heroin addicts and/or HIV positive patients: three cases. *Clinical rheumatology*, 1993; 12.3:422-5

29. Verdaguer A, et al. Estudio de los procesos patológicos en 176 ingresos de heroinómanos en un hospital general. *Med Clin (Barc)*, 1984, 82: 9-12
30. White Abraham G. Medical disorders in drug addicts: 200 consecutive admissions. *Jama*, 1973; 223.13:1469-71
31. Smolyakov R et al. Streptococcal septic arthritis and necrotizing fasciitis in an intravenous drug user couple sharing needles. *IMAJ-RAMAT GAN-*, 2002; 4.4: 302-3
32. Briggs JH, et al. Severe systemic infections complicating "mainline" heroin addiction. *The Lancet*, 1967; 290.7528: 1227-31
33. Holzman Robert S, Bishko Frederic. Osteomyelitis in heroin addicts. *Annals of internal medicine*, 1971; 75.5:693-6
34. Grau D, et al. [Infectious adverse events related to misuse of high-dose buprenorphine: a retrospective study of 42 cases]. *La Revue de medecine interne/fondee... par la Societe nationale francaise de medecine interne*, 2010; 31.3:188-93
35. Kanellakopoulou K, et al. Chronic bone infections Due to *Enterobacter cloacae*: Current therapeutic trends and Clinical Outcome. *Journal of Chemotherapy*, 2009; 21.2:226-8
36. Etchepare F, et al. [Enterobacter cloacae spondylodiscitis through misuse of high-dose intravenous buprenorphine]. *Presse medicale (Paris, France)*, 2005; 34.10:725-7
37. Okhtiarkina VV, Novoselov PN. [The medical social characteristics of patients with joint tuberculosis and HIV-infection]. *Problemy sotsial'noi gigieny, zdravookhraneniia i istorii meditsiny/NII sotsial'noi gigieny, ekonomiki i upravleniia zdravookhraneniem im. NA Semashko RAMN; AO" Assotsiatsiia 'Meditsinskaia literatura'.*, 2011; 5: 9-12
38. Backstein D, Hutchison C, Gross A. Septic arthritis of the hip after percutaneous femoral artery catheterization. *The Journal of arthroplasty*, 2002; 17.8:1074-7
39. Hope VD, et al. Not in the vein: 'missed hits', subcutaneous and intramuscular injections and associated harms among people who inject psychoactive drugs in Bristol, United Kingdom. *International Journal of Drug Policy*, 2015
40. Irish Charles, et al. Skin and soft tissue infections and vascular disease among drug users, England. *Emerging infectious diseases*, 2007; 13.10:1510-2
41. Hope VD, et al. Going into the groin: injection into the femoral vein among people who inject drugs in three urban areas of England. *Drug and alcohol dependence*, 2015; 152: 239-45
42. Ti Lianping, et al. Groin injecting among a community-recruited sample of people who inject drugs in Thailand. *Substance abuse treatment, prevention, and policy*, 2014; 9.1: 1
43. Maliphant J, Scott J. Use of the femoral vein ('groin injecting') by a sample of needle exchange clients in Bristol, UK. *Harm Reduction Journal*, 2005; 2.1:1
44. Sharff Katie A, Richards Eric P, Townes JM. Clinical management of septic arthritis. *Current rheumatology reports*, 2013; 15.6:1-9
45. Crane Lawrence R, et al. Bacteremia in narcotic addicts at the Detroit Medical Center. I. Microbiology, epidemiology, risk factors, and empiric therapy. *Review of Infectious Diseases*, 1986; 8.3: 364-73
46. Sheagren JN. Endocarditis complicating parenteral drug abuse. *Current clinical topics in infectious diseases*, 1981; 2: 211-33
47. Di Giorgio L, et al. [Prosthetic hip revision: relationship between bone stock and quality of life in aseptic loosening of the femoral component]. *Clin Ter*, 2013; 164(1):e 11-5