European Radiology
https://doi.org/10.1007/s00330-017-5237-6

MAGNETIC RESONANCE

To evaluate the feasibility of magnetic resonance imaging in predicting unusual site ectopic pregnancy: a retrospective cohort study

Gabriele Masselli[1] · Martina Derme[2] · Maria Grazia Piccioni[2] · Vincenzo Spina[3] · Francesca Laghi[1] · Gianfranco Gualdi[1] · Marialuisa Framarino-dei-Malatesta[2]

Received: 29 July 2017 / Revised: 7 November 2017 / Accepted: 4 December 2017

Abstract

Objective To evaluate the accuracy of pelvic MRI in the diagnosis of unusual ectopic pregnancy (EP), when ultrasound (US) examination is inconclusive.

Methods We retrospectively reviewed the medical records of 150 patients with suspected EP. Clinical, US and MRI features of 15 unusual EPs were analysed. Two radiologists independently reviewed each case resolving by consensus any diagnostic discrepancy. Interobserver agreement was assessed using the Cohen κ test.

Results MRI displayed a gestational sac-like structure surrounded by a thick wall in all cases. The thick wall displayed hyperintensity in 41 %, isointensity in 35 % and hypointensity in 24 % of cases on T1-weighted images. Diffusion- and fat saturation T1-weighted images were the most accurate sequences, as they enabled identification of 15/15 and 14/15 patients, respectively. Although US was false negative in detecting cervical and uterine infiltration underlying the caesarean scar, MRI was able to identify the invasion. Interobserver agreement was very good for all sequences (κ=0.892–1.0).

Conclusions MRI plays an important role in the early diagnosis of unusual EP. It should be considered after negative US findings, providing accurate evaluation of the site and the possible infiltration of these lesions, which help in the management of these patients.

Key Points

- *MRI is being increasingly used as a problem-solving modality in ectopic pregnancy.*
- *MRI plays an important role in early diagnosis of unusual ectopic pregnancy.*
- *Knowledge of MRI features in EP is essential to determinate appropriate management.*

Keywords Ultrasonography · Magnetic resonance imaging · Ectopic pregnancy · Gestational sac · Early diagnosis

Abbreviations

BMI	Body mass index
EP	Ectopic pregnancy
GE	Gestational age
GS	Gestational sac
hCG	Human chorionic gonadotropin
ICSI	Standard intracytoplasmic sperm injection
IUD	Intrauterine device
MRI	Magnetic resonance imaging
MTX	Methotrexate
SD	Standard deviation
SPSS	Statistical Package for the Social Sciences
TV	Transvaginal
US	Ultrasound
WI	Weighted image

✉ Gabriele Masselli
gabrielemasselli@libero.it

[1] Radiology Dea Department, Umberto I Hospital, Sapienza University of Rome, Viale del Policlinico 155-00161, Rome, Italy

[2] Department of Gynaecological, Obstetrical and Urological Sciences, Umberto I Hospital, Sapienza University of Rome, Viale del Policlinico 155-00161, Rome, Italy

[3] Department of Obstetrics and Gynaecology, Sandro Pertini Hospital, Via dei Monti Tiburtini 385/389-00157 Rome, Italy

Introduction

The implantation of a fertilized ovum outside the uterine cavity, so-called ectopic pregnancy (EP), occurs in 11 per 1,000

Published online: 18 January 2018

pregnancies [1]. It is most commonly located in the ampullary portion of the fallopian tube (80 %) and less commonly in unusual sites such as the interstitial portion of the fallopian tube (2 %), cervix (< 1 %), Caesarean scar (6 %) among women with a prior Caesarean delivery, anomalous rudimentary horn of the uterus (0.2–2 %) and peritoneal abdominal cavity (0.9–1.4 %) [2].

A marked increase of these extra-tubal EPs has been observed due to the widespread use of Caesarean sections and assisted reproductive technology [1] and their correct differentiation is crucial for management planning in these stable patients [3].

The mortality associated with EP has decreased significantly over the past two decades due to the advancements in early diagnosis and treatment. When the EP is detected in early stages with a small gestational sac (GS), a conservative treatment is possible with methotrexate (MTX) or salpingostomy instead of total salpingectomy.

In this setting ultrasound (US) is an accurate imaging modality in evaluating the site of pregnancy implantation. However, US is an operator-dependent assessment and interference by bowel gas, heavy haemorrhage or coexistence of an ovarian mass results in non-visualization of the implantation site of the EP in up to 15–35 % of the patients [3].

In these situations, magnetic resonance imaging (MRI) is being increasingly used as a problem-solving imaging modality in association with US. Further, MRI provides additional information for complicated forms of EP, when diagnosis is unclear or US is equivocal, in particular for unusual implantation sites [4, 5].

MRI offers different potential advantages with respect to US in the evaluation of EP, including a higher soft tissue contrast, a wider field of view and the ability to depict and distinguish the blood from other fluid collections.

To date we have found few observational studies [6–10] and several case reports [11–15] that focused on MRI for the diagnosis of tubal EP, without a clear assessment about its role for the unusual implantation sites.

We retrospectively reviewed the medical records of 150 patients whose clinical, laboratory and US findings were suspicious for EP who were admitted to our Gynaecology and Obstetrics Department. The purpose of this study was to evaluate the usefulness of pelvic MRI in the diagnosis of unusual EP, when US examination is inconclusive.

Materials and methods

Patients

We retrospectively reviewed the medical records of 150 patients who attended our Department of Gynaecology and Obstetrics between January 2011 and July 2017.

Clinical, laboratory and US findings were suspicious for EP. Nine of 150 patients (6 %) with unstable haemodynamic status underwent US examination only. In 126 out of 141 patients (89.4 %) US detected tubal EP, while in 15 out of 141 patients (10.6 %) transvaginal (TV) and abdominal US showed an empty uterine cavity; in particular US findings were completely negative (n=2 patients) or inconclusive without identifying the certain site of EP implantation (n=13). Pelvic MRI was performed in these patients in order to clarify the diagnosis.

The mean±standard deviation (SD) age of the patients was 34.2±3.57 years. A spontaneous pregnancy was reported in all cases, except for one patient who underwent standard intracytoplasmic sperm injection (ICSI) for primary infertility. Fourteen patients were nulliparous and one patient had two previous Caesarean sections. Mean estimated gestational age (GA)±SD at diagnosis (based on the last menstrual period) was 8.3±1.39 weeks. On admission, all patients were haemodynamically stable and complaining of mild to moderate abdominal or pelvic pain and vaginal bleeding. The serum β-human chorionic gonadotropin (hCG) value ranged from 2,943 to 55,679 mIU/ml, mean±SD: 28,578.7±13,177.17 mIU/ml (Table 1).

In these patients written informed consent for MRI was obtained. The institutional review board approved this study, and consent for the retrospective analysis was waived by the board.

No patient had contraindications to MRI, such as an intrauterine device (IUD), implantation of cardiac pacemaker or metal prosthesis, severe renal dysfunction, epilepsy, asthma and/or claustrophobia.

Table 1 Clinical and laboratory findings of 15 unusual ectopic pregnancy patients

Patient	Age (years)	GA at diagnosis (weeks)	Serum β-hCG at diagnosis (mIU/ml)
1	40	7	2,943
2	35	11	37,634
3	31	7	25,000
4	38	6	5,314
5	34	8	21,041
6	29	9	25,750
7	39	7	55,679
8	35	8	27,550
9	38	9	34,780
10	36	8	28,970
11	32	7	35,600
12	30	10	40,730
13	35	9	23,340
14	31	10	37,100
15	30	8	27,250

GA gestational age, *β-hCG* β- human chorionic gonadotropin

The indications for MRI in patients with suspected EP were as follows: (1) the patient was β-hCG positive, haemodynamically stable and intrauterine pregnancy was excluded without massive bloody ascites on US; (2) the patient wanted fertility preservation and preferred conservative treatment to maximally preserve fertility; (3) the diagnosis of EP was inconclusive with US.

The contraindications were as follows: (1) the patient was hypotensive with massive vaginal bleeding and severe abdominal pain indicative of EP rupture, which required emergency surgery; (2) the patient had general contraindications to the MR examination, such as implantation of cardiac pacemaker or metal prosthesis, or claustrophobia.

MRI techniques

MR imaging was performed on a 1.5-T unit (Magnetom Avanto; Siemens Medical Solutions, Malvern, PA, USA) equipped with high-performance gradients and phased-array coils. Patients were imaged supine, with their feet entering into the magnet bore first to minimize feelings of claustrophobia. Steady-state sequence (FISP-true fast imaging with steady-state precession) in axial, sagittal and coronal planes were acquired. T2-weighted fast spin-echo images were obtained in sagittal, coronal and transverse planes, and T1-weighted fast spin-echo images were obtained with and without fat saturation in the axial plane (Table 2). Gadolinium was not administered in any case.

Diffusion-weighted images (WIs) were obtained in the axial plane by using a multisection fast spin-echo echoplanar sequence. Apparent diffusion coefficient maps were automatically generated with software (Leonardo, Siemens Medical Solutions).

MRI image analysis

Two radiologists (with 12 and 3 years of body MRI experience, respectively), blinded to the clinical and surgical results, assessed the images using a picture archiving and communication system (Carestream, 5.3 sp1.1; Kodak, Rochester, NY, USA).

To minimize recall bias two reading sessions was performed 4 weeks from each other and MR images (T2- and T1-WIs and diffusion-WIs) were randomly analysed during the different sessions. Patient information was removed from all images. During each imaging analysis, the readers were asked to determine the presence and location of extrauterine EP.

Moreover, after 3 weeks, during a third interpretation, the two readers resolved discrepancies in consensus and determined the diagnoses that were compared with the reference standard diagnoses; recorded the signal intensity characteristics of the haematoma with the different sequences (the signal intensity was defined hyper-, iso- or hypointense in comparison with the signal of the skeletal muscle) [16]; the diffusion-weighted MR images obtained with a b-value of 800 s/mm2 were used for this evaluation.

The MRI findings were categorized as: extrauterine GS-like structure (size and shape, wall and content, signal intensities) and presence of blood ascites (area of high signal intensity on T1-WIs with fat suppression and of mixed signal intensity on T2-WIs). The extrauterine GS-like structure was defined as a sac-like cystic structure surrounded by a thick wall, which was similar to that observed via sonography.

The different EPs were classified based on the following MRI findings: *interstitial EP*, by demonstrating a GS lateral to the cornua and surrounded by T2-hypointense myometrium and an intact junctional zone between the uterine cavity and the GS; *angular pregnancy*, by demonstrating a GS eccentrically located and predominantly surrounded by T2-hyperintense endometrium; *cervical* pregnancy, by demonstrating a heterogeneous mixed signal intensity lobulated mass occupying the cervix, with a normal endometrial stripe; *ovarian pregnancy*, by demonstrating a GS-like structure within the ovary, with normal fallopian tubes; *Caesarean scar pregnancy*, by demonstrating the absence of thinning myometrium between the bladder wall and the GS on T2-

Table 2 Magnetic resonance protocol

Imaging parameters	True FISP		T2-weighted TSE		T1-weighted TSE	DWI
	Axial	Coronal	Axial and axial fat sat	Coronal/sagittal	Axial and axial fat sat	Axial
Repetition time ms/echo time ms	4.3/2.2	4.3/2.2	3,500/130	3,500/130	450/15	2,200/66
Flip angle (degrees)	50	50	150	150	10	10
Field of view (mm)	320-400	320-400	320	320	320	320
Matrix	256x224	256x224	320x240	320x240	320x240	144x192
Parallel imaging factor	2	2	2	2	2	2
Section thickness (mm)	5	4	5	5	5	5
No. of signals acquired	1	1	4	4	4	6
Receiver bandwidth (Hz)	125	125	62.5	62.5	62.50	1,930

WIs with evidence of a GS formation in the anterior part of the lower uterine segment; *abdominal pregnancy*, by demonstrating the GS associated with hematoma implanted in the peritoneal cavity.

Statistical analysis

We used the Statistical Package for the Social Sciences (SPSS) version 23.0 for data description and analysis. Descriptive and inferential statistics described the basic features of our data. We calculated the mean and SD of different variables at diagnosis (age, gestational age, serum β-hCG value) and of different MRI features, like the size of the GS-like structure.

The interobserver agreement in the detection of EP at MR imaging as well the inter-rater agreement between each MR imaging sequence were calculated using the Cohen κ pairwise inter-test for nominal scales [17].

The strength of agreement was considered poor for κ values < 0.20, fair for κ values of 0.21–0.40, moderate for κ values of 0.41–0.60, good for κ values of 0.61–0.80, and very good for κ values of 0.81–1.00 [17].

Reference standard

All patients underwent a surgical procedure to treat EP and the final diagnosis was histopathologically confirmed.

Results

The US and MRI diagnoses and the type of surgery are summarized in Table 3. The final implantation site of the 15 EPs included in this series was tubal (three cases), interstitial (four cases), abdominal (two cases), angular (two cases), cervical (two cases), Caesarean scar (one case) and ovarian (one case).

Ultrasound findings

In all the patients, TV US clearly demonstrated an empty uterine cavity with endometrial thickness ranging from 10 to 12 mm. In 13 patients US found 14 GSs, as two tubal GSs were present in one patient. The GSs were round in seven cases and dysmorphic in seven cases, showing a maximum diameter ranged from 10–40 mm. In four patients, no embryos and/or yolk sacs were identified in the GSs, while in nine patients GSs contained an embryo with cardiac activity and a crown-rump length consistent with the GE. In two patients US was not able to find any GS. Colour Doppler flow imaging was used to evaluate the possible presence of vascularization in the implantation site and infiltration of uterine wall.

MRI findings

The MRI features of the 15 patients with EP are summarized in Table 4.

Table 3 Ultrasound (US) and magnetic resonance imaging (MRI) diagnoses and type of treatment of 15 unusual ectopic pregnancy patients

Patient	US diagnosis	MRI diagnosis	Treatment	Complications
1	Twin tubal pregnancy	Triplet tubal pregnancy	Laparoscopic salpingectomy	None
2	Cervical pregnancy. No evidence of cervical stroma infiltration	Cervical pregnancy. Evidence of deep cervical stroma infiltration	Systemic MTX+ laparotomic hysterectomy	Blood transfusion
3	Interstitial/angular pregnancy	Interstitial pregnancy	Laparoscopic cornuostomy	None
4	Angular pregnancy	Tubal pregnancy	Laparoscopic Salpingectomy	None
5	Interstitial/angular pregnancy	Angular pregnancy	Laparotomic hysterectomy	Blood transfusion
6	Ovarian pregnancy	Tubal pregnancy	Laparoscopic Salpingectomy	None
7	Cervical pregnancy. No evidence of myometrial infiltration	Cesarean scar pregnancy. Evidence of myometrial infiltration	Laparotomic hysterectomy	None
8	Negative	Abdominal pregnancy	Laparoscopy	None
9	Angular pregnancy	Interstitial pregnancy	Laparoscopic cornuostomy	None
10	Negative	Abdominal pregnancy	Laparoscopy	None
11	Spontaneous abortion in progress	Cervical pregnancy	Dilatation and curettage+ hysteroscopic resection	None
12	Angular pregnancy	Interstitial pregnancy	Laparoscopic cornuostomy	None
13	Interstitial/angular pregnancy	Angular pregnancy	Laparoscopic cornuostomy	None
14	Interstitial/angular pregnancy	Interstitial pregnancy	Laparoscopic cornuostomy	None
15	Tubal pregnancy	Ovarian pregnancy	Laparoscopic oophorectomy	None

MTX methotrexate

Table 4 Magnetic resonance imaging features of 15 unusual ectopic pregnancies

Features	
Size of GS-like structures (mm)	12-41 (21±11.2)
Shape of GS-like structures	
-Round	5/17 (29 %)
-Oval	12/17 (71 %)
Wall of GS-like structures	
Signal intensity on T1-WI	
-Hyper	7/17 (41 %)
-Iso	6/17 (35 %)
-Hypo	4/17 (24 %)
Thickness of GS wall (mm)	2-6 (4±2)
Contents of GS-like structures	
Four Types:	
-Nonspecific liquid	3/17 (18 %)
-Dot-like or treelike solid components	8/17 (47 %)
-Blood	6/17 (35 %)
Ascites	
-Bloody	5/15 (33 %)
-Nonspecific liquid	10/15 (67 %)

GS gestational sac, *T1-WI* T1-weighted images

Extrauterine GS-like structure

MRI displayed 17 similar cystic sac structures surrounded by a thick wall in all 15 patients. The patient with two GSs on US actually showed three GSs on RMI. Three types of GS-like structure contents were found: three GSs (18 %) exhibited nonspecific liquid with hypo-signal intensity on T1-WIs and hyper-signal-intensity on T2-WIs; eight GSs (47 %) exhibited papillary solid components representing embryo tissues with iso-signal intensity on T2-WIs and marked enhancement; and six GSs (35 %) exhibited hyper-signal intensities on both T1- and T2-WIs, indicating fresh blood or a fluid-fluid level resulting from blood degradation without a visible solid component.

EP trophoblastic infiltration

MR images were able to identify EP trophoblastic infiltration into the cervical stroma and placental invasion into the myometrium underlying the caesarean scar (Fig. 1).

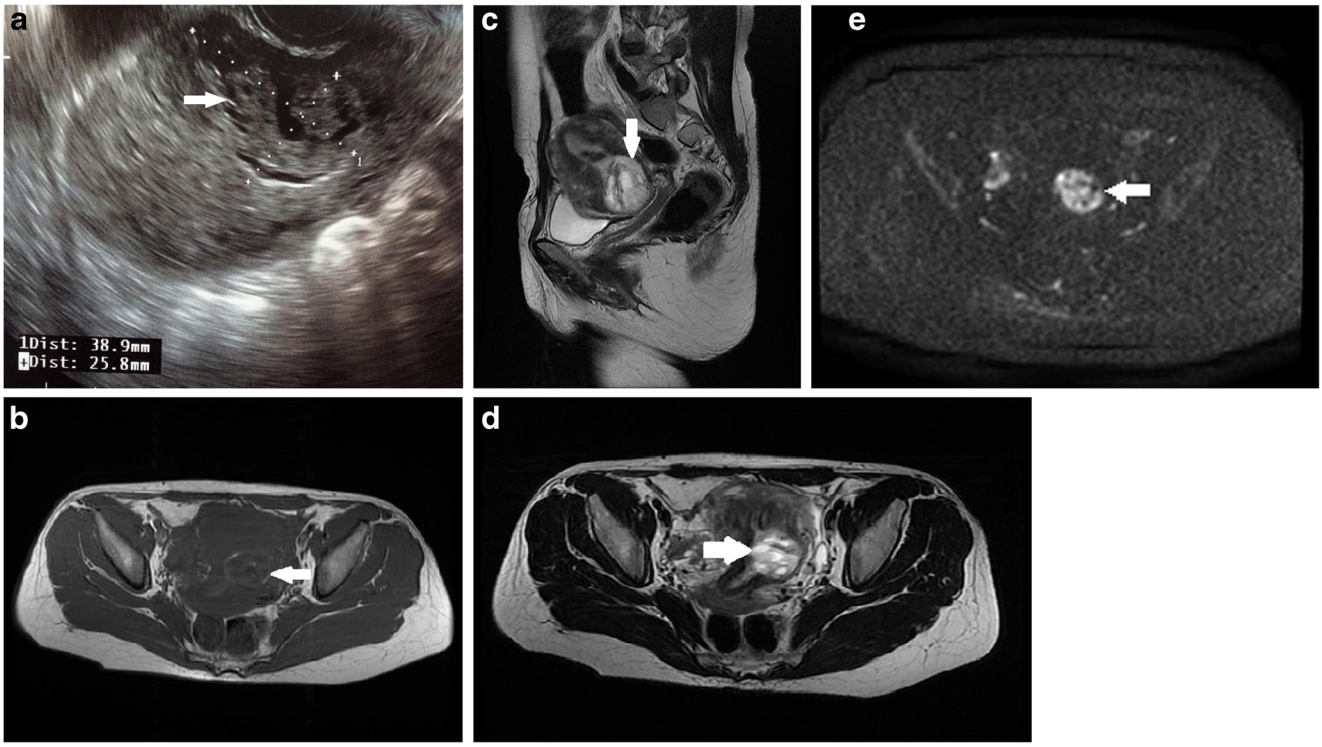

Fig. 1 Caesarean scar pregnancy in a 39-year-old woman at 7 weeks' gestation. Transvaginal US (**A**) showed the presence of a dysmorphic gestational sac (GS) (39 × 26 mm) (white arrow), containing a fetal pole without cardiac activity, in the cervical region. Axial T1- (**B**), sagittal T2- (**C**) and axial T2-weighted imaging (WI) (**D**) MR scans showed a GS-like structure within the lower segment of the anterior uterine wall, indicating a Caesarean scar pregnancy rather than a cervical pregnancy (white arrow). Diffusion-WI (**E**) clearly demonstrates the presence of a lesion of restricted diffusion (arrow) at level of the Caesarean section scar (Fig. 1 corresponds to case 7 in Table 3)

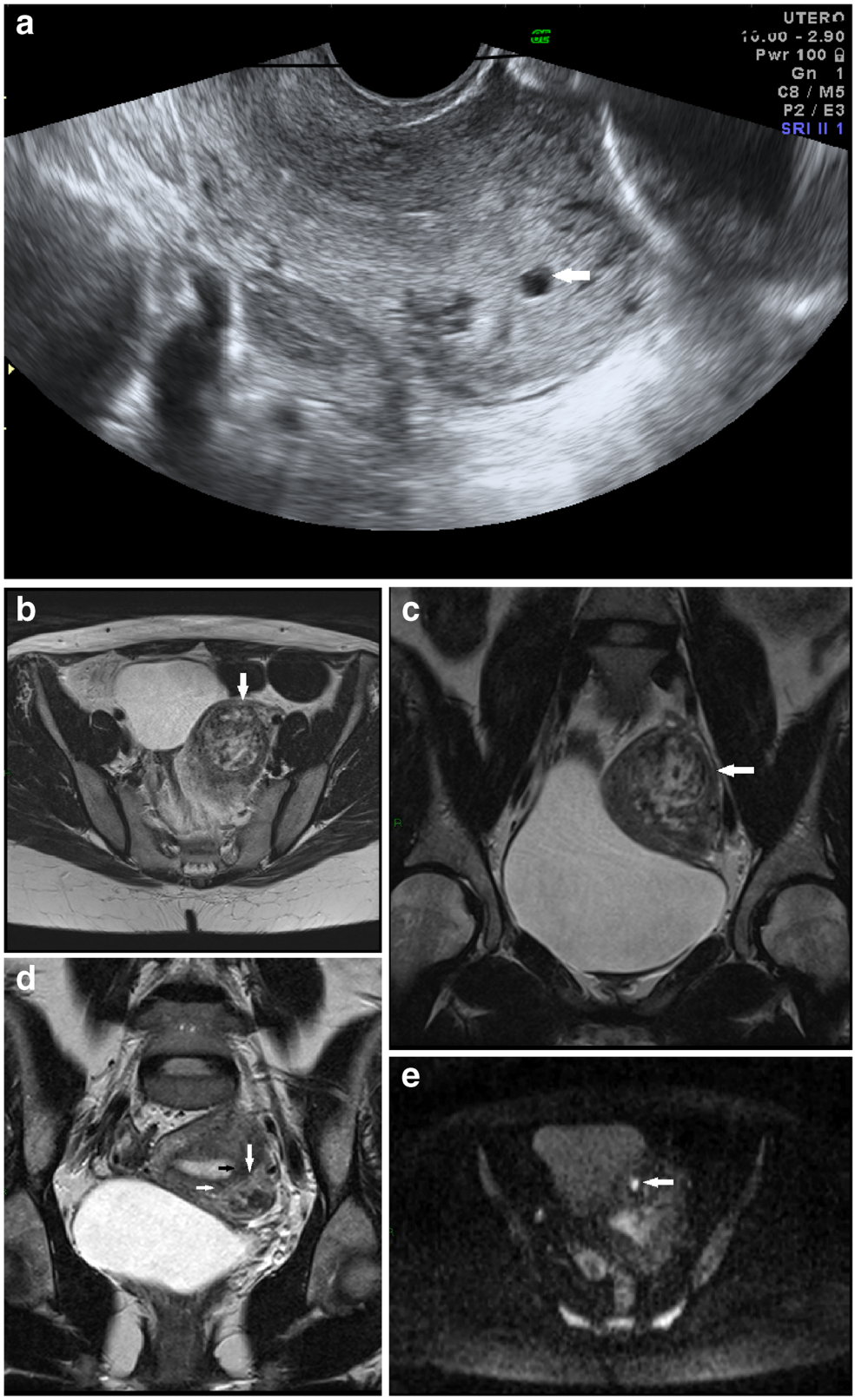

Interstitial or angular pregnancy

MRI was able to clarify the US dilemma between interstitial and angular pregnancy.

In the first case, T2-WIs displayed a superior left uterine heterogeneous mass (high T2-hyperintense) surrounded by (relatively T2-hypointense) myometrium and intact (extremely T2-hypointense) junctional zone between the mass

◀ **Fig. 2** Interstitial pregnancy in a 31-year-old woman at 7 weeks' gestation. Transvaginal US (**A**) showed an eccentrically located gestational sac (GS) (20 × 25 mm) (arrow), without embryo, on the left side of the uterine fundus, without distinguishing between angular and interstitial pregnancy. Axial (**B**) and coronal (**C**) T2- weighted imaging (WI) displayed a superior left uterine heterogeneous mass (high T2-hyperintense) (white arrow). (**D**) shows the uterine mass (big white arrow) surrounded by myometrium (small white arrow) (relatively T2-hypointense) and intact junctional zone (black arrow) (extremely T2-hypointense) between the mass and the endometrium, supporting the diagnosis of an interstitial pregnancy. Diffusion-WI (**E**) shows a structure with restricted diffusion at the level of the uterine fundus (arrow), clearly demarcated from the endometrium (Fig. 2 corresponds to case 3 of Table 3)

and the endometrium, supported the diagnosis of an interstitial pregnancy (Fig. 2).

In the second case, MRI showed a superior left uterine mass predominantly surrounded by T2 hyperintense endometrium, suggesting the diagnosis of an angular pregnancy (Fig. 3).

Angular or tubal pregnancy

MRI identified a tubal pregnancy, confirmed by surgery, while TV US had shown an angular pregnancy (Fig. 4). The correct diagnosis was fundamental for choosing the best treatment.

Abdominal pregnancy versus negative US exam

In two patients TV US examination was negative, while MRI was able to identify abdominal EP.

After an unremarkable US, MRI detected an abdominal pregnancy close to right wall of the uterus, along the pelvic peritoneum; in particular, DWIs revealed the presence of a round lesion with restricted diffusion, whereas T1 and T2 sequence were false negative since the EPs were incorrectly interpreted as ileal small bowel (Fig. 5).

During the second reading session, diffusion- and fat saturation T1-WIs were the most accurate, as they enabled identification of the GS in 15/15 (100 %) and 14/15 (90 %) patients, respectively. Sensitivity and specificity of different MRI sequences to individualize the ectopic GS are reported in Table 5.

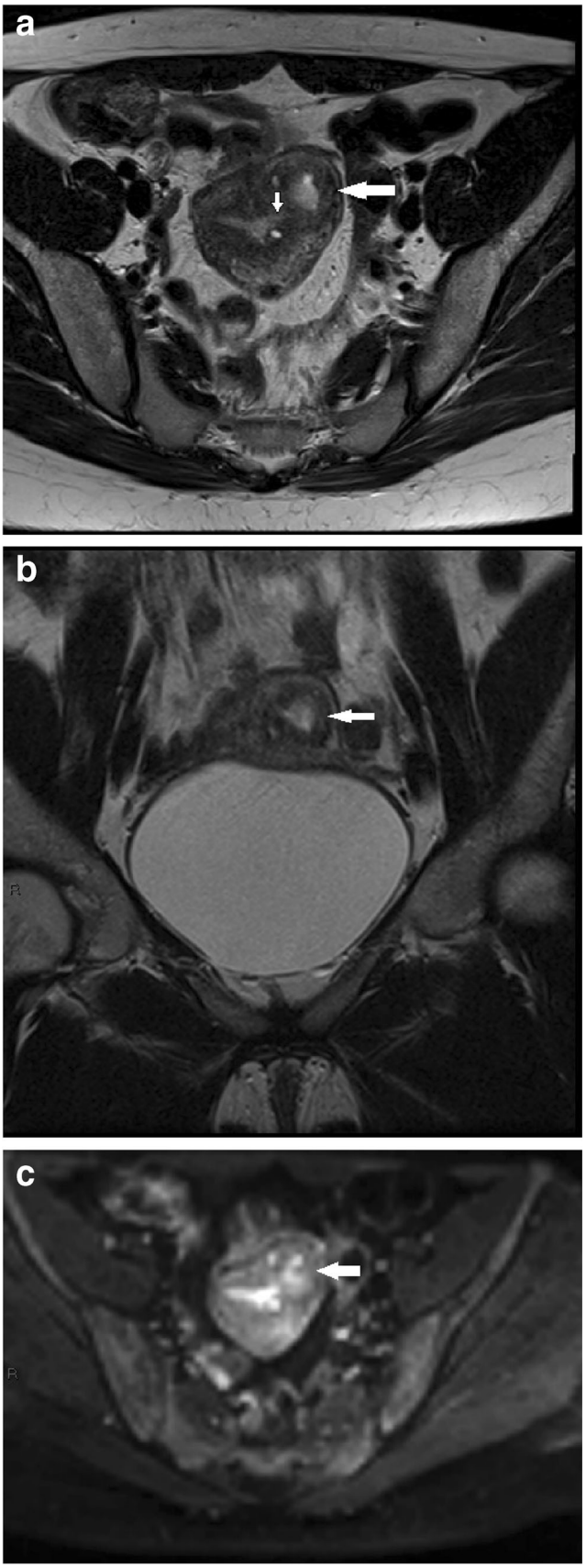

Fig. 3 Angular pregnancy in a 34-year-old woman at 8 weeks' gestation. ▶ Axial (**A**) and coronal (**B**) T2- weighted imaging (WI) show a superior left heterogeneous uterine mass (big arrow) predominantly surrounded by T2 hyperintense endometrium (small arrow), suggesting the diagnosis of an angular pregnancy. Diffusion-WI (**C**) demonstrates the presence of a restricted diffusion structure at the left uterine cornu (arrow), surrounded by endometrium (Fig. 3 corresponds to case 5 in Table 3)

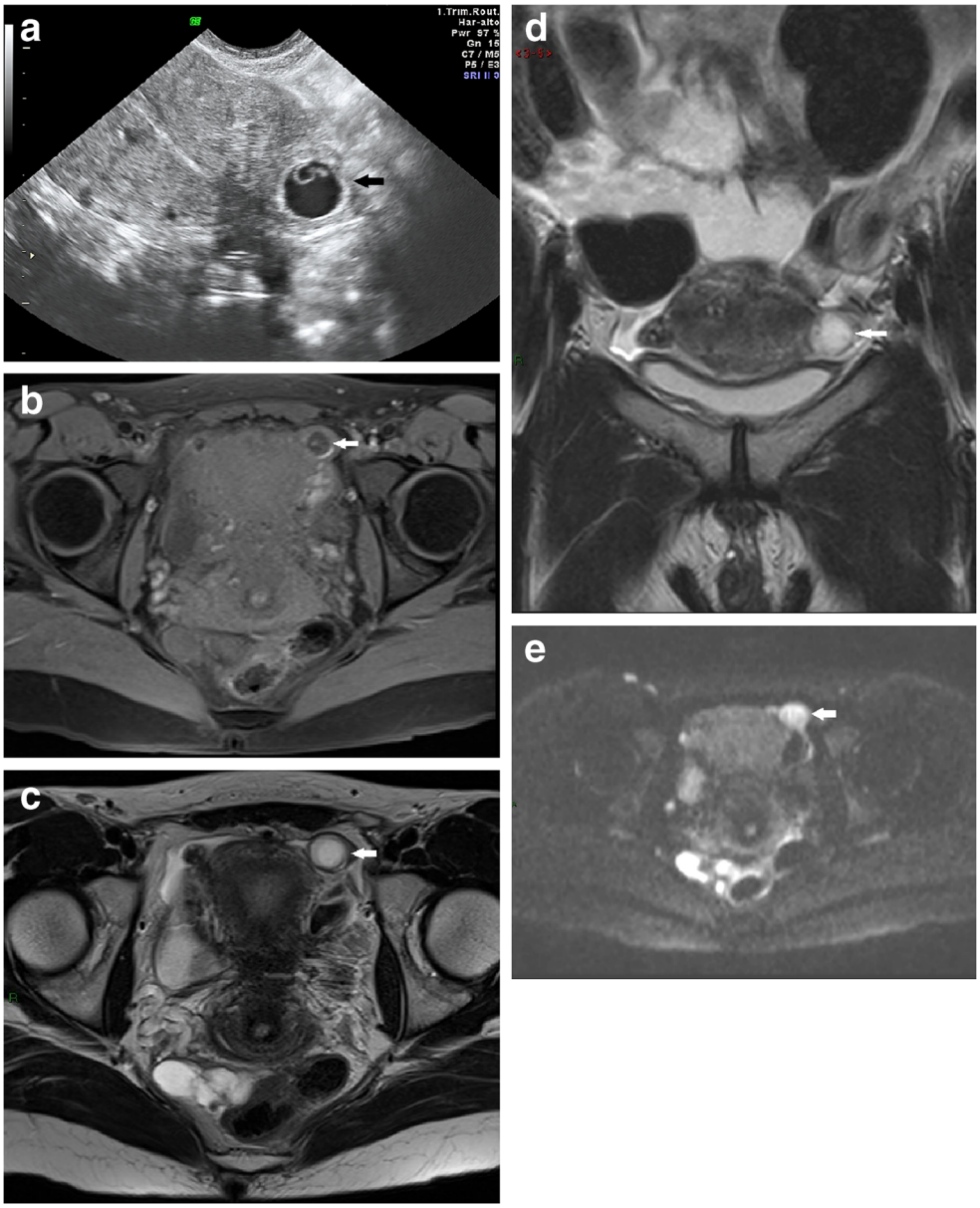

Fig. 4 Left tubal pregnancy in a 38-year-old woman at 6 weeks' gestation. Transvaginal US (**A**) was suggestive of an angular pregnancy with a gestational sac (GS) (28 × 32 mm) containing the embryo and the yolk sac (arrow). Axial fat saturation T1-weighted imaging (WI) (**B**), axial (**C**) and coronal (**D**) T2-WIs revealed a cystic GS-like structure in the left adnexa. Diffusion-WI (**E**) clearly demonstrates the presence of a restricted diffusion lesion in the left Fallopian tube (arrow) (Fig. 4 corresponds to case 4 in Table 3)

Interobserver agreement for the MR imaging detection of EP was very good (κ = 0.957; 95 % confidence interval (CI): 0.859–1.000).

Discussion

EP is a well-known acute condition, and is associated with a 9–14 % mortality rate [6]. The decision to institute medical therapy versus surgery requires accurate characterization of a suspected EP. US remains the initial imaging modality for evaluating patients with suspected EP. Since US is unable to identify blood products, US may fail to detect extra-uterine GS in the presence of haematoma, hematosalpinx or hemoperitoneum, and it is less accurate in detecting extra-tubal implantation [18, 19]. MRI offers the benefits of multi-planar imaging, lack of ionizing radiation, excellent soft-tissue contrast and more-specific characterization of tissues and fluids [20, 21].

In this study, MRI was accurate in detecting unusual site EP and the accurate localization and detailed assessment of GS are particularly important for choosing the correct treatment (conservative/radical surgery, medical or expectant therapy); in addition, the multiplanar imaging capability of MRI may be helpful in orienting the surgeon.

In our series MRI helped to choose the correct treatment. Laparoscopy was the most widely used surgical technique, according to other previous studies (laparoscopic salpingectomy for tubal pregnancies; laparoscopic cornuostomy for interstitial pregnancies and laparoscopic

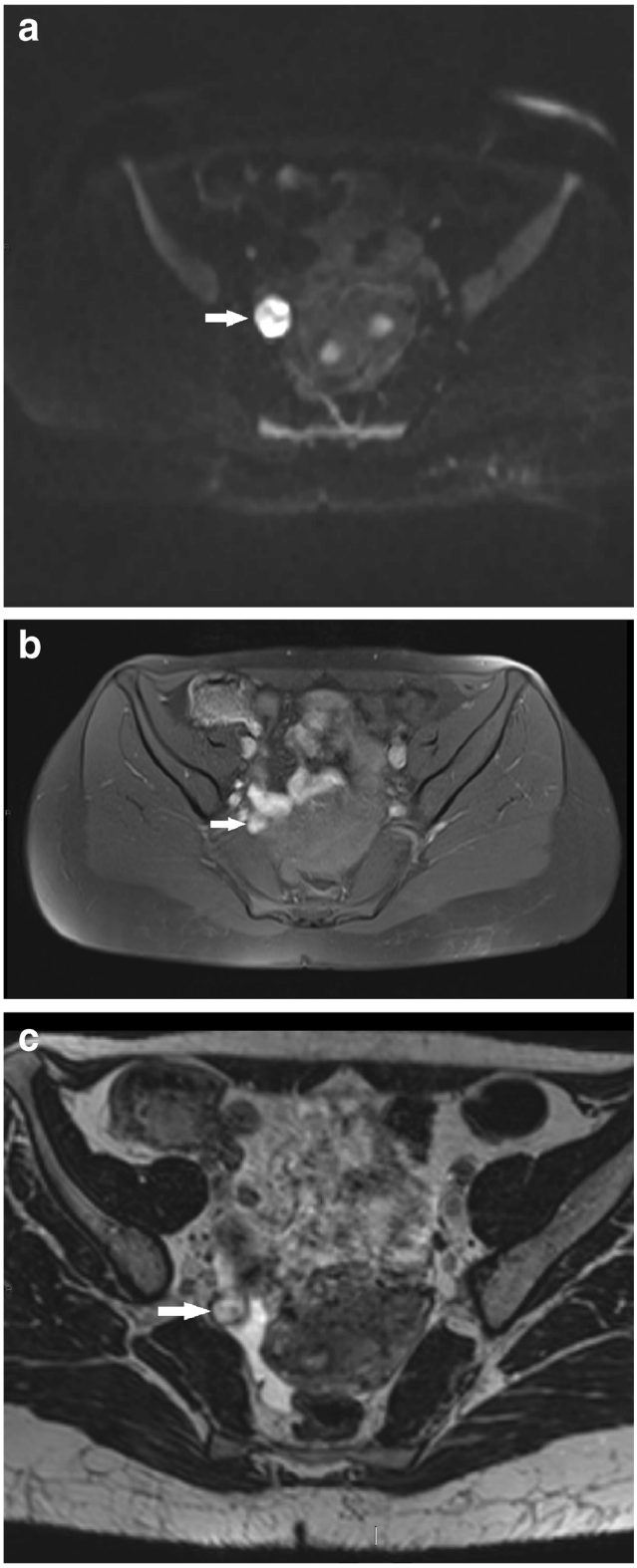

◀ **Fig. 5** Abdominal pregnancy in a 35-year-old woman at 8 weeks' gestation. Negative US examination. Axial diffusion-weighted imaging (WI) (**A**) detected the presence of a restricted diffusion suggestive of gestational sac (GS)-like structure (arrow), closed to right wall of the uterus, along the pelvic peritoneum (arrow). Axial fat saturation T1-WIs (**B**) and axial T2-WIs (**C**) were false negative, since the EP was incorrectly interpreted as ileal small bowel (arrows) (Fig. 5 corresponds to case 8 in Table 3)

removal of abdominal pregnancies) [22]. Laparotomic hysterectomy was performed in one cervical pregnancy due to failed previous medical treatment. Hysteroscopic resection after dilatation and curettage was used to treat the second reported case of cervical pregnancy. One angular pregnancy needed laparotomic hysterectomy due to important vaginal bleeding. Laparoscopic cornuostomy was used in the other angular pregnancy.

Further characterization of EP using MRI after initial ultrasonography has been shown to be helpful in differential diagnosis between angular and interstitial pregnancy, since the management and the outcomes differ between them. Failure to diagnose interstitial pregnancy may be disastrous, because the rupture is generally late and vary haemorrhagic, whereas angular pregnancy can be carried to term [23].

US may not distinguish whether the GS is surrounded by a thin myometrial layer (like an interstitial pregnancy) or by endometrium with an adjacent thicker myometrial layer (like an angular pregnancy); due to its greater soft tissue contrast MRI is accurate in this evaluation and in our study correctly defined the location of the GS in four interstitial pregnancies and in two angular pregnancies. MRI can also evaluate possible placental invasion into the myometrium, which was observed in our study in one patient with angular pregnancy [24].

Although TV US is the reference standard for diagnosis of Caesarean scar pregnancies, with a reported 86.4 % sensitivity [25, 26], MRI is useful when US is equivocal or inconclusive before intervention or therapy. If this abnormal implantation is unrecognized, it may result in devastating complications including placenta accreta, life-threatening maternal haemorrhage and uterine rupture. In our series MRI was able to clarify both the site of implantation and the myometrial infiltration.

In cervical EP the incremental role of MRI is emerging due to its larger field of view and improved soft tissue contrast for delineation of the placenta and in evaluating the presence of irregular placentation invading the cervix that may be clinically relevant because it indicates a greater risk of bleeding; in our series, US failed to detect cervical infiltration.

Table 5 Sensibility and specificity of different magnetic resonance imaging (MRI) sequences to individualize the ectopic gestational sac

Type of MRI sequence	Sensibility	Specificity
T1-WI	(12/15) 80%	(15/15) 100%
Fat saturation T1-WI	(14/15) 90%	(15/15) 100%
T2 fast spin echo WI	(11/15) 70%	(15/15) 100%
Diffusion-WI	(15/15) 100%	(15/15) 100%

WI weighted imaging

Abdominal pregnancy refers to a pregnancy that has implanted in the peritoneal cavity, external to the uterine cavity and fallopian tubes. It is difficult to differentiate it from tubal EP in early gestation when it implants near the adnexa. MRI is a sensitive, specific and accurate method for evaluating EP and may help in surgical planning. In two of our patients US was negative, while MRI was able to identify abdominal EP.

In our series the patient with a triplet tubal pregnancy, a rare condition with only nine cases reported in the literature [27–35], presented with a body mass index (BMI) of 32 kg/m^2, making US examination very difficult to perform. MRI was able to better define the number of the GSs.

Moreover, our results show that diffusion-WI is an excellent sequence for detecting extra-uterine haemorrhagic lesions and should be included in the MR protocol for patients with suspected EP. Blood breakdown products cause susceptibility effects and can be accurately demonstrated with the diffusion-weighted sequence. In our study, the diffusion- and fat saturation T1-WIs were more accurate than the T1- and T2-WI sequences in the detection of the ectopic GS.

Our non-contrast protocol was accurate in detecting all the cases of EP, and our results support not using contrast enhancement sequences. According to other authors, gadolinium should not be administered in this clinical scenario, especially if a viable intrauterine pregnancy has not been conclusively ruled out, because it crosses the placenta and is relatively contraindicated in pregnancy [18, 22, 23].

A possible limitation of MR imaging in the diagnosis of EP could be the need for advanced training for skilled image interpretation. In order to improve the diagnosis, we obtained an excellent interobserver agreement between two readers with different proficiency in pelvic MR imaging.

Moreover, MRI is also useful for differential diagnosis. Theca lutein cyst is the most frequent differential diagnosis of EP in a pregnant patient. The imaging clues for making a correct diagnosis are symmetrically enlarged ovaries, thin wall and absence of acute haemorrhage. Another less common differential diagnosis of EP is endometriotic cysts with decidual changes. On MR imaging, decidualized endometrial tissues can be observed as mural nodules or solid-like lesions on the wall of an endometriotic cyst [36].

Our study has several limitations. First, it was a retrospective study and included a relatively small sample size of EP, but our study focused on the evaluation of MRI in the case of extra-tubal EP, a rare condition reported only in case reports. Second, we excluded 9/150 patients (6 %) because MRI can only be performed with stable haemodynamic status. The suspicion of tubal rupture more often depends on the clinical setting, including acute severe abdominal pain, guarding and rebound tenderness at physical examination, haemodynamic instability, and a dropping haematocrit. Finally, the possibility of a recall bias in the serial evaluation of the different MR imaging sequences should also be considered, although we attempted to reduce this bias.

In order to confirm the diagnostic accuracy of MRI features and statistical significance, future multicentre studies are recommended.

In conclusion, our results show that in cases of inconclusive US, MRI can play an important role in the early diagnosis of extra-tubal pregnancy, providing accurate evaluation of the site and the possible infiltration of the lesion, which help the management of these patients [6].

Funding The authors state that this work has not received any funding.

Compliance with ethical standards

Guarantor The scientific guarantor of this publication is Dr. Masselli Gabriele.

Conflict of interest The authors of this manuscript declare no relationships with any companies whose products or services may be related to the subject matter of the article.

Statistics and biometry No complex statistical methods were necessary for this paper.

Informed consent Written informed consent was obtained from all subjects (patients) in this study.

Ethical approval Institutional Review Board approval was obtained.

Methodology
- retrospective
- observational
- performed at one institution

References

1. Royal College of Obstetricians and Gynaecologists. Diagnosis and management of ectopic pregnancy. Available via https://www.rcog.org.uk/en/guidelines-research-services/guidelines/gtg21/. Published: 4 Nov 2016
2. Parker VL, Srinivas M (2016) Non-tubal ectopic pregnancy. Arch Gynecol Obstet 294:19–27
3. Levine D (2007) Ectopic pregnancy. Radiology 245:385–397
4. Köroğlu M, Kayhan A, Soylu FN et al (2013) MR imaging of ectopic pregnancy with an emphasis on unusual implantation sites. Jpn J Radiol 31:75–80
5. Kao LY, Scheinfeld MH, Chernyak V, Rozenblit AM, Oh S, Dym RJ (2014) Beyond ultrasound: CT and MRI of ectopic pregnancy. AJR Am J Roentgenol 202:904–911
6. Si MJ, Gui S, Fan Q et al (2016) Role of MRI in the early diagnosis of tubal ectopic pregnancy. Eur Radiol 26:1971–1980
7. Takahashi A, Takahama J, Marugami N et al (2013) Ectopic pregnancy: MRI findings and clinical utility. Abdom Imaging 38:844–850
8. Tamai K, Koyama T, Togashi K (2007) MR features of ectopic pregnancy. Eur Radiol 17:3236–3246
9. Yoshigi J, Yashiro N, Kinoshita T, O'uchi T, Kitagaki H (2006) Diagnosis of ectopic pregnancy with MRI: efficacy of T2*-weighted imaging. Magn Reson Med Sci 5:25–32

10. Kataoka ML, Togashi K, Kobayashi H, Inoue T, Fujii S, Konishi J (1999) Evaluation of ectopic pregnancy by magnetic resonance imaging. Hum Reprod 14:2644–2650
11. Io S, Hasegawa M, Koyama T (2015) A Case of Ovarian Pregnancy Diagnosed by MRI. Case Rep Obstet Gynecol 2015:143031
12. Wu R, Klein MA, Mahboob S, Gupta M, Katz DS (2013) Magnetic resonance imaging as an adjunct to ultrasound in evaluating cesarean scar ectopic pregnancy. J Clin Imaging Sci 3:16
13. Renfroe S, Dajani NK, Pandey T, Magann EF (2013) Role of serial MRI assessment in the management of an abdominal pregnancy. BMJ Case Rep. https://doi.org/10.1136/bcr-2013-200495
14. Tu J, Wang E, Shen J (2016) Primary Hepatic Ectopic Pregnancy: A Case Report. J Reprod Med 61:175–178
15. Bourdel N, Roman H, Gallot D et al (2007) Interstitial Pregnancy. Ultrasonographic diagnosis and contribution of MRI. A case report. Gynecol Obstet Fertil 35:121–124
16. Forstner R, Thomassin-Naggara I, Cunha TM et al (2017) ESUR recommendations for MR imaging of the sonographically indeterminate adnexal mass: an update. Eur Radiol 27:2248–2257
17. Cohen J (1960) A coefficient of agreement for nominal scales. Educ Psychol Meas 20:37–46
18. Gupta R, Bajaj SK, Kumar N et al (2016) Magnetic resonance imaging - A troubleshooter in obstetric emergencies: A pictorial review. Indian J Radiol Imaging 26:44–51
19. Masselli G, Brunelli R, Parasassi T, Perrone G, Gualdi G (2011) Magnetic resonance imaging of clinically stable late pregnancy bleeding: beyond ultrasound. Eur Radiol 21:1841–1849
20. Singh AK, Desai H, Novelline RA (2009) Emergency MRI of acute pelvic pain: MR protocol with no oral contrast. Emerg Radiol 16: 133–141
21. Masselli G, Derchi L, McHugo J et al (2013) Acute abdominal and pelvic pain in pregnancy: ESUR recommendations. Eur Radiol 23: 3485–3500
22. Alalade AO, Smith FJE, Kendall CE, Odejinmi F (2017) Evidence-based management of non-tubal ectopic pregnancies. J Obstet Gynaecol 20:1–10
23. Parker RA, Yano M, Tai AW, Friedman M, Narra VR, Menias CO (2012) MR imaging findings of ectopic pregnancy: a pictorial review. Radiographics 32:1445–1460
24. Arleo EK, DeFilippis EM (2014) Cornual, interstitial, and angular pregnancies: clarifying the terms and a review of the literature. Clin Imaging 38:763–770
25. Rotas MA, Haberman S, Levgur M (2006) Cesarean scar ectopic pregnancies: etiology, diagnosis, and management. Obstet Gynecol 107:1373–1381
26. Osborn DA, Williams TR, Craig BM (2012) Cesarean scar pregnancy: sonographic and magnetic resonance imaging findings, complications, and treatment. J Ultrasound Med 31:1449–1456
27. Krusen W (1902) Triple ectopic gestation. Amer J Med 3:18
28. Diamant Z (1914) Ein Fall von Drillingsschwangerschaft in demselben Eileiter. Zbl Gynaek 3:128
29. Plyler CO, Freeman WH, Johnson JM (1956) Unilateral triplet tubal pregnancy. N Carolina Med J. 17:170
30. Forbes DA, Natale A (1968) Unilateral tubal triplet pregnancy: Report of a case. Obstet Gynecol 31:360
31. Schmitt R, Heinen K (1972) Unilateral ectopic pregnancy of triplets. Geburtshilfe Frauenheilkd 32:136–137
32. Am S, Chin VP (1992) Unilateral triplet ectopic pregnancy. A case report. J Reprod Med 37:187–188
33. Tsai HD, Chang CC, Hsieh YY, Chang CC, Yang TC, Chen CM (1998) Sonographic diagnosis of triplet tubal pregnancy after in vitro fertilization and embryo transfer. J Clin Ultrasound 26: 159–162
34. Nwanodi O, Berry R (2006) Spontaneous Triplet, Tubal Ectopic Gestation. J Natl Med Assoc 98:963–964
35. Berkes E, Szendei G, Csabay L, Sipos Z, Joo JG, Rigo J (2008) Unilateral triplet ectopic pregnancy after in vitro fertilization and embryo transfer. Fertil Steril 90:2003.e17–2003.e20
36. Srisajjakul S, Prapaisilp P, Bangchokdee S (2017) Magnetic resonance imaging in tubal and non-tubal ectopic pregnancy. Eur J Radiol 93:76–89