



Case Report

Splenic hamartoma associated with abdominal discomfort and pain: Case report

Giulio Illuminati^{a, *}, Giampaolo Prezioso^a, Giulia Pizzardi^a, Rocco Pasqua^a, Bruno Perotti^a, Chiara Amatucci^a, Ludovica De Vincentiis^b

^a The Department of Surgical Sciences, The University of Rome "La Sapienza", Rome, Italy

^b The Department of Pathology, The University of Rome "La Sapienza", Rome, Italy

ARTICLE INFO

Article history:

Received 19 June 2018

Received in revised form

11 July 2018

Accepted 12 July 2018

Available online 21 July 2018

Keywords:

Splenic hamartoma

Splenic tumor

Case report

ABSTRACT

Hamartomas are benign splenic neoplasms asymptomatic in most of the cases. Symptoms, when present, may either be related to the growth of the mass with abdominal discomfort and pain or be related to a hypersplenism syndrome. Certain preoperative diagnosis cannot be made with current diagnostic imaging. Splenectomy is therefore indicated in order to obtain histological diagnosis, rule out malignancy or achieve regression of symptoms. We report the case of a 39-year-old woman referred for a splenic hamartoma causing pain located on the upper abdominal quadrant. She underwent splenectomy through a left subcostal access followed by complete resolution of symptoms.

Resection of splenic masses is indicated to complete diagnosis, achieve cure and, when present, relieve symptoms.

© 2018 The Authors. Published by Elsevier Ltd on behalf of Surgical Associates Ltd. This is an open access article under the CC BY-NC-ND license (<http://creativecommons.org/licenses/by-nc-nd/4.0/>).

1. Introduction

Hamartomas are rare, benign tumors of the spleen [1,2] and their exact, preoperative diagnosis is difficult [3]. They are asymptomatic in most of the cases, nonetheless, as they may hide a malignant lesion or progress towards symptoms of compression on other structures, pain, hypersplenism or rupture, their resection is usually warranted [4].

In line with the SCARE criteria [5], we now report the case of a splenic hamartoma associated with left upper quadrant abdominal pain, treated by splenectomy followed by resolution of symptoms.

2. Presentation of case

A 39-year-old woman presenting a non-specific left upper quadrant pain lasting since a month underwent an abdominal ultrasound examination (US) which disclosed a 4 cm diameter, hypoechoic mass of the upper pole of the spleen with inner blood flow at Power Doppler. She was, then, addressed to our Department for treatment. At physical examination the lower pole of the spleen was palpable and non-tender. Laboratory examinations were all

within normal limits. CT-scan revealed a 4.5 cm diameter, round mass of the upper pole of the spleen, iso-dense at non-contrast CT (Fig. 1), with homogeneous contrast enhancement on the arterial phase and mild, late enhancement on the portal phase (Fig. 2). The spleen with the mass appeared to compress the posterior wall of the stomach and the anterior surface of the kidney without infiltration (Fig. 3). On 3-D reconstructions, the mass appeared well round and fed by an upper hilar branch of the splenic artery, almost mimicking an aneurysm (Fig. 4). A selective, splenic artery angiogram showed the main trunk of the splenic artery dividing at the hilum with an upper and an inferior branch. The mass was fed by the upper branch but also by multiple, collateral feeding vessels thus hindering a satisfactory and complete embolization of the mass without massive necrosis of the spleen (Fig. 5). The decision was to proceed with a splenectomy, after obtaining patient's informed consent for open surgery. The operation was performed by the senior author (GI), through a left subcostal incision and was carried on in a standard fashion, with separate ligation of the splenic artery and vein (Fig. 6). The mass was well capsulated and arose in a context of splenomegaly, with a major axis of the spleen of 15 cm (Fig. 7).

Postoperative course was uneventful and the patient was discharged home on postoperative day 5. At one-month follow-up, left upper quadrant abdominal pain completely regressed.

Histology on the resected specimen was consistent with the diagnosis of splenic hamartoma (Fig. 8).

* Corresponding author. Via Vincenzo Bellini 14, 00198, Rome, Italy.

E-mail address: giulio.illuminati@uniroma1.it (G. Illuminati).

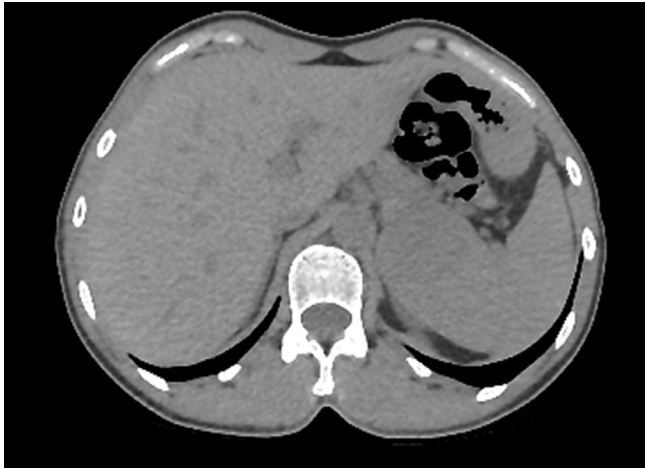

Fig. 1. CT-scan of the abdomen showing an iso-dense mass of the upper pole of the spleen.

3. Discussion

Hamartomas are rare benign tumors of the spleen consisting of aberrant splenic tissue [4] and were first reported by Rokitsky in 1861 [6]. They may arise from the splenic pulp, lymphoid splenic tissue or may have a mixed pattern of origin [4]. Their frequency in

splenectomy specimens ranges from 0.015 to 2.7% [4] and 0.024–0.13% in autopsy specimens [7]. Overall, slightly less than 200 cases should have been reported so far [2,8] They may affect any age group, with equal incidence in men and women [1], although women may tend to have larger lesions than men, probably due to hormonal factors [1,9]. When affecting children they usually become symptomatic when associated with multiple hamartomatosis or isolated and still of a smaller diameter compared to adults [10–14]. In most of the cases they are asymptomatic and may be detected at abdominal US examinations performed for search of other conditions. However, sometimes and usually when reaching large diameters of around 8 cm and more in adults or when multiple, they may exhibit symptoms of hypersplenism with thrombocytopenia, anemia and pancytopenia [1,8]. They may also be associated with multiple hamartomatosis, tuberous sclerosis and with Wiskott-Aldrich-like syndromes and Kasbach-Merritt syndrome [8,15]. They may also cause symptoms of abdominal discomfort and pain due to compression on adjacent organs or simply to mass effect as in the reported case or cause rupture of the splenic capsule and bleeding [8].

As an exact preoperative diagnosis can seldom be established [2], their resection is usually always indicated, as they may turn out to be malignant lymphomas or Hodgkin's disease [4]. Further differential diagnosis with other benign and malignant conditions affecting the spleen include vascular tumors such as hemangioma, hemangiopericytoma, lymphangioma, angiosarcoma and thrombosed hilar aneurysm of the splenic artery [1,16,17]. Hamartomas should also be

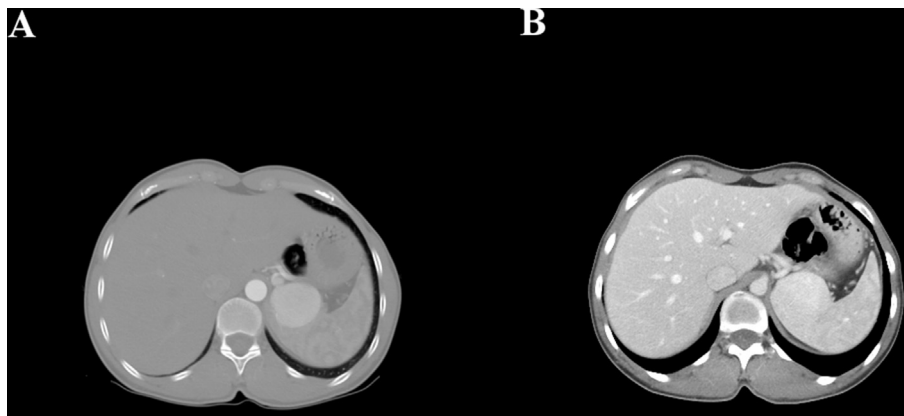


Fig. 2. CT-scan of the abdomen: after contrast injection the splenic mass presents a homogeneous enhancement on the arterial phase (A) and a light enhancement on the portal phase (B).

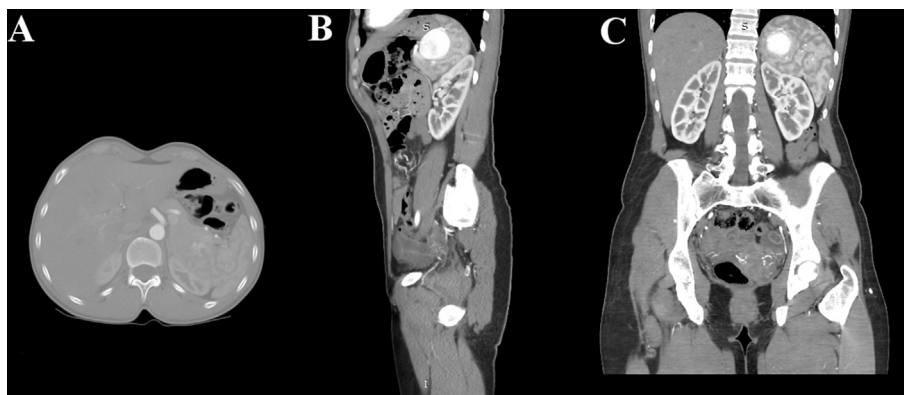


Fig. 3. CT-scan of the abdomen. On both transverse (A), lateral sagittal (B) and anterior sagittal (C) reconstruction splenomegaly and mass compress the anterior face of the upper pole of right kidney and posterior wall of the stomach without infiltration.

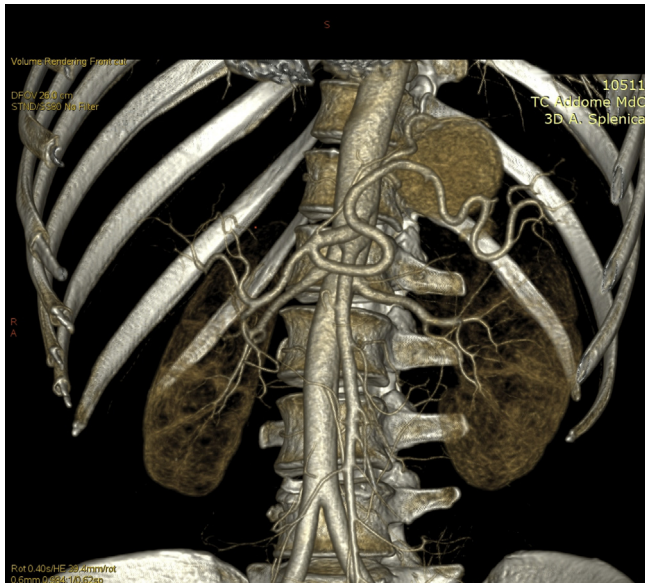


Fig. 4. CT-scan of the abdomen. On arterial reconstruction the round mass, mimicking an aneurysm, is placed over the bifurcation of the splenic artery.

differentiated from other solid lesions of the spleen as inflammatory tumors, metastatic neoplasms and sarcoidosis [1,9,18].

Imaging of splenic hamartomas may not be specific. At abdominal ultrasound they usually appear as solid, homogeneous hypoechoic masses [8,19] with positive vascularization at color Doppler [19,20]. Cystic degeneration or calcifications may be due ischemia or hemorrhage [8]. At CT-scan they usually appear as iso-dense masses with rapid homogeneous enhancement on arterial phase and light enhancement on the portal phase [3,21]. At MRI hamartomas are isointense on T1 weighted images and hyperintense on T2 weighted images, with heterogeneous enhancement after gadolinium administration [3,22]. However these imaging patterns are not specific only of hamartomas, thus making preoperative diagnosis uncertain [8]. Angiography does not add any more information to non-invasive imaging and usually is not indicated to confirm diagnosis. In the present case we performed it with the aim of proceeding to embolization of the mass in order to possibly preserve the spleen in a young woman, and with the aim of either obtaining full necrosis of the entire mass and facilitate a spleen-preserving,

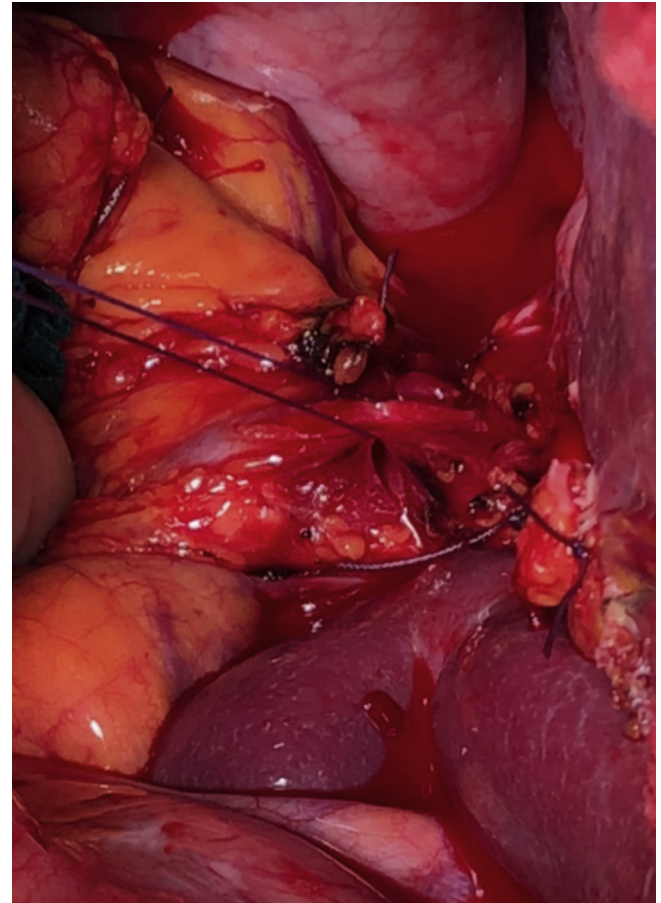


Fig. 6. Intraoperative view. After ligation of the short gastric vessel, the splenic artery is isolated and ligated.

upper pole resection, despite lack of evidence for this type of treatment. However, at selective splenic artery angiography, the pattern of vascularization of the mass revealed that embolization would cause extensive necrosis of the spleen in order to be effective. This led us to perform splenectomy, also to obtain histology of the mass. Furthermore, embolization may be technically difficult in cases of aberrant origin of the splenic artery from the superior mesenteric artery [23]. Fine needle aspiration biopsy (FNAB) was

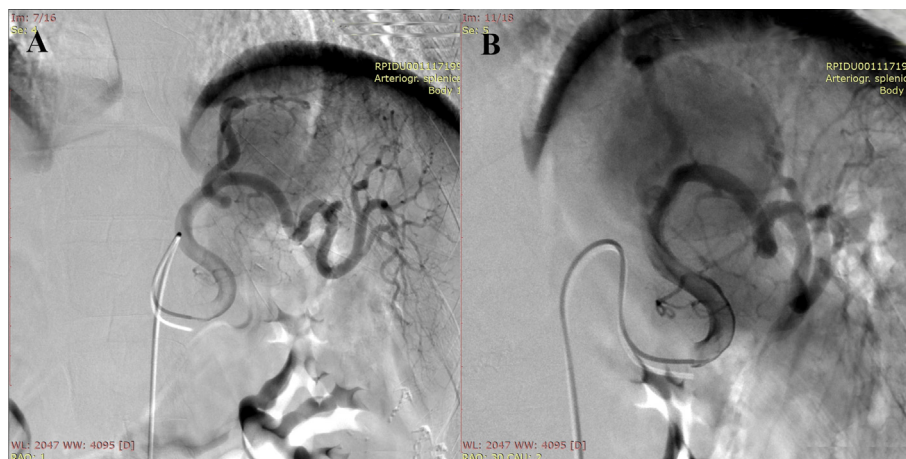


Fig. 5. Selective angiogram of the splenic artery. The round mass is mainly fed by the upper branch of the splenic artery (A), but also by collaterals from the lower branch (B) hindering selective embolization and preservation of the spleen.

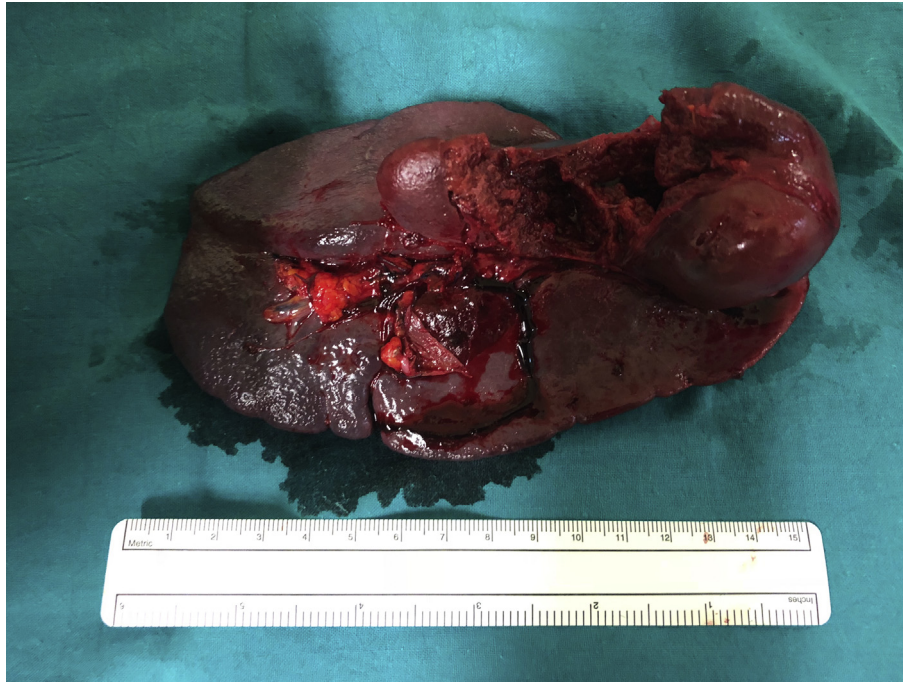

Fig. 7. Resected specimen of the spleen The mass arises from the upper pole of the spleen and is surrounded by a thin capsule. Mild splenomegaly coexists, with a spleen length of 15 cm.

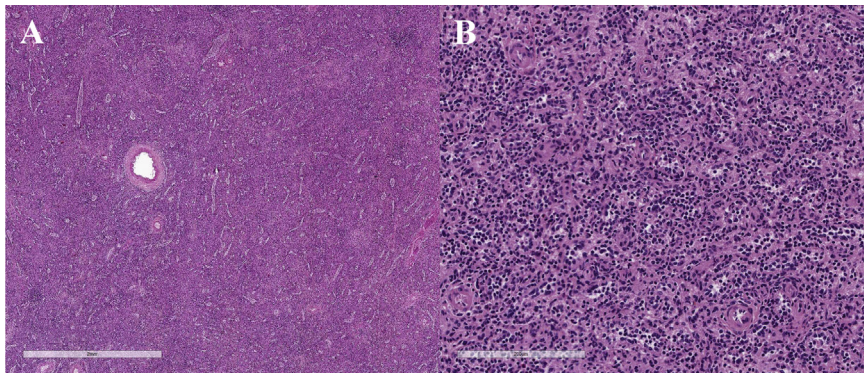


Fig. 8. 2× hematoxylin-eosin stain demonstrates a homogeneous red pulp proliferation, lacking malpighian corpuscle (A); higher magnification (20×) revealing haphazardly arranged small slit-like vascular spaces lined by plumped endothelial cell and red pulp element in a disorganized fashion. No extramedullary hematopoiesis was observed (B).

also considered, but discarded as considered at high risk of bleeding and limited diagnostic value, as previously reported [3].

Laparoscopic splenectomy is becoming the standard method for treatment of most splenic diseases, whereas open splenectomy is considered better indicated in case of splenomegaly, when the diameter of spleen exceeds 20 cm [24,25]. In the present case, the length of the spleen was of 15 cm, however we preferred an open approach due to the contact of the mass with the stomach, the thin capsule of the mass and its vascularization, anticipating a potentially increased risk of intraoperative bleeding.

Prognosis of resected splenic hamartomas is usually good, as local and distal recurrence rate is very low [26] and splenectomy can therefore be considered curative.

4. Conclusion

Hamartomas of the spleen are benign and asymptomatic in most of the cases. Nonetheless splenectomy is indicated in order to

obtain histological confirmation, rule out malignancy relieve or prevent symptoms related to potential growth of the mass and splenomegaly.

Ethical approval

Not required given the case report type of the study.

Funding

None.

Authors' contribution

GI, writing and critical review of the manuscript, final approval of the manuscript; GP, critical review of the manuscript, final approval of the manuscript; GP, data recording, final approval of the manuscript; RP, data recording, final approval of the manuscript;

BP, data gathering, final approval of the manuscript; CA, critical review of the manuscript, final approval of the manuscript; LDV Histological study, description of pathological features and final approval of the manuscript.

Conflicts of interest/Disclosure statement

The authors declare that they have no conflicts of interest.

Guarantor

Giulio Illuminati.

Research registration number

4194.

Statement of ethics

The study was performed in accordance with the Helsinki Declaration and Good Clinical Practice.

Consent of the patient

Written informed consent was obtained from the patient for publication of this case report and accompanying images. A copy of the written consent is available for review by the Editor-in-Chief of this Journal on request.

SCARE checklist

The work has been prepared in accordance with SCARE checklist.

References

- [1] Komo T, Hihara J, Kanou M, Kohashi T, Ohmori I, Yoshimitsu M, et al. Splenic hamartoma associated with thrombocytopenia: a case report. *Int J Surg Case Rep* 2017;39:172–5.
- [2] Yazici P, Aydin U, Ersin S, Kaplan H. Hamartoma - a rare benign tumor of the spleen: a report of four cases. *Eurasian J Med* 2008;40:48–51.
- [3] Yu RS, Zhang SZ, Hua JM. Imaging findings of splenic hamartoma. *World J Gastroenterol* 2004;10:2613–5.
- [4] Silverman ML, LiVolsi VA. Splenic hamartoma. *Am J Clin Pathol* 1978;70:224–9.
- [5] Agha RA, Fowler AJ, Saeta A, Barai I, Rajmohan S, Orgill DP, SCARE Group. The SCARE Statement: consensus-based surgical case report guidelines. *Int J Surg* 2016;34:180–6.
- [6] Berge T. Splenoma. *Acta Pathol Microbiol Scand* 1965;63:333–9.
- [7] Lam KY1, Yip KH, Peh WC. Splenic vascular lesions: unusual features and a review of the literature. *Aust N Z J Surg* 1999;69:422–5.
- [8] Tsitouridis I, Michaelides M, Tsitouridis K, Davidis I, Efstratiou I. Symptomatic splenoma (hamartoma) of the spleen. A case report. *Hippokratia* 2010;14:54–6.
- [9] Lee H, Maeda K. Hamartoma of the spleen. *Arch Pathol Lab Med* 2009;133:147–51.
- [10] Darden JW, Teeslink R, Parrish A. Hamartoma of the spleen: a manifestation of tuberous sclerosis. *Arch Pathol Lab Med* 2007;131:965–9.
- [11] Abramowsky C, Alvarado C, Wyly JB, Ricketts R. "Hamartoma" of the spleen (splenoma) in children. *Pediatr Dev Pathol* 2004;7:231–6.
- [12] Thompson SE, Walsh EA, Cramer BC, Pushpanathan CC, Hollett P, Ingram L, et al. Radiological features of a symptomatic splenic hamartoma. *Pediatr Radiol* 1996;26:657–60.
- [13] Hayes TC, Britton HA, Mewborne EB, Troyer DA, Saldivar VA, Ratner IA. Symptomatic splenic hamartoma: case report and literature review. *Pediatrics* 1998;101:E10.
- [14] Havlik RJ, Touloukian RJ, Markowitz RI, Buckley P. Partial splenectomy for symptomatic splenic hamartoma. *J Pediatr Surg* 1990;25:1273–5.
- [15] Darden JW, Teeslink R, Parrish A. Hamartoma of the spleen: a manifestation of tuberous sclerosis. *Am Surg* 1975;41:564–6.
- [16] Illuminati G, Pizzardi G, Calio F, Pacilè MA, Carboni F, Palumbo P, et al. Hemangiopericytoma of the spleen. *Int J Surg* 2015;15:6–10.
- [17] Illuminati G, Pizzardi G, Pasqua R. Open surgery for aneurysms of the splenic artery at the hilum of the spleen: report of three cases. *Int J Surg Case Rep* 2018;48:47–9.
- [18] Compérat E, Bardier-Dupas A, Camparo P, Capron F, Charlotte F. Splenic metastases: clinicopathologic presentation, differential diagnosis, and pathogenesis. *Arch Pathol Lab Med* 2007;131:965–9.
- [19] Sugihara T, Koda M, Kato J, Sakamoto T, Horie Y, Murawaki Y. Contrast-enhanced sonography with Sonazoid as a new diagnostic tool for splenic hamartoma: a single case report. *J Med Ultrason* 2016;43:113–8.
- [20] Brinkley AA, Lee JK. Cystic hamartoma of the spleen: CT and sonographic findings. *J Clin Ultrasound* 1981;9:136–8.
- [21] Zissin R, Lishner M, Rathaus V. Case report: unusual presentation of splenic hamartoma; computed tomography and ultrasonic findings. *Clin Radiol* 1992;45:410–1.
- [22] Ramani M1, Reinhold C, Semelka RC, Siegelman ES, Liang L, Ascher SM, et al. Splenic hemangiomas and hamartomas: MR imaging characteristics of 28 lesions. *Radiology* 1997;202:166–72.
- [23] Illuminati G, LaMuraglia G, Nigri G, Vietri F. Surgical repair of an aberrant splenic artery aneurysm: report of a case. *Ann Vasc Surg* 2007;21:216–8.
- [24] Habermalz B, Sauerland S, Decker G, Delaitre B, Gigot JF, Leandros E, et al. Laparoscopic splenectomy: the clinical practice guidelines of the European Association for Endoscopic Surgery (EAES). *Surg Endosc* 2008;22:821–48.
- [25] Casaccia M, Torelli P, Squarcia S, Sormani MP, Savelli A, Troilo B, et al. Laparoscopic splenectomy for hematologic diseases: a preliminary analysis performed on the Italian Registry of Laparoscopic Surgery of the Spleen (IRLSS). *Surg Endosc* 2006;20:1214–20.
- [26] Wang RT, Xu XS, Hou HL, Qu K, Bai JG. Symptomatic multinodular splenic hamartoma preoperatively suspected as metastatic tumor: a case report. *World J Gastroenterol* 2014;20:10637–41.