

## Short Communication

# *PRNP* P39L Variant is a Rare Cause of Frontotemporal Dementia in Italian Population

Emanuela Oldoni<sup>a,1</sup>, Giorgio G. Fumagalli<sup>a,1</sup>, Maria Serpente<sup>a</sup>, Chiara Fenoglio<sup>a</sup>, Marta Scarioni<sup>a</sup>, Andrea Arighi<sup>a</sup>, Giuseppe Bruno<sup>b</sup>, Giuseppina Talarico<sup>b</sup>, Annamaria Confaloni<sup>c</sup>, Paola Piscopo<sup>c</sup>, Benedetta Nacmias<sup>d</sup>, Sandro Sorbi<sup>d</sup>, Innocenzo Rainero<sup>e</sup>, Elisa Rubino<sup>e</sup>, Lorenzo Pinessi<sup>e</sup>, Giuliano Binetti<sup>f</sup>, Roberta Ghidoni<sup>f</sup>, Luisa Benussi<sup>f</sup>, Giulia Grande<sup>g</sup>, Beatrice Arosio<sup>h</sup>, Devan Bursey<sup>i</sup>, John S. Kauwe<sup>i</sup>, Sara MG Cioffi<sup>a</sup>, Marina Arcaro<sup>a</sup>, Daniela Mari<sup>h</sup>, Claudio Mariani<sup>g</sup>, Elio Scarpini<sup>a</sup> and Daniela Galimberti<sup>a,\*</sup>

<sup>a</sup>Neurology Unit, Department of Pathophysiology and Transplantation, University of Milan, Fondazione Ca' Granda, IRCCS Ospedale Policlinico, Milan, Italy

<sup>b</sup>University "Sapienza", Rome, Italy

<sup>c</sup>Istituto Superiore di Sanità, Rome, Italy

<sup>d</sup>Department of Neuroscience, Psychology, Drug Research and Child Health, University of Florence, Italy

<sup>e</sup>Neurology I, Department of Neuroscience, Department of Neuroscience, University of Torino, Italy

<sup>f</sup>Molecular Markers Laboratory, IRCCS Istituto Centro San Giovanni di Dio Fatebenefratelli, Brescia, Italy

<sup>g</sup>Center for Research and Treatment of Cognitive Dysfunctions, Institute of Clinical Neurology, Department of Biomedical and Clinical Sciences, "Luigi Sacco" Hospital, University of Milan, Milan, Italy

<sup>h</sup>Geriatric Unit, Department of Medical Sciences and Community Health, University of Milan, Fondazione Ca' Granda, IRCCS Ospedale Policlinico, Milan, Italy

<sup>i</sup>Department of Biology, Brigham Young University, Provo, UT, USA

Handling Associate Editor: Marco Bozzali

Accepted 23 October 2015

**Abstract.** The missense P39L variant in the prion protein gene (*PRNP*) has recently been associated with frontotemporal dementia (FTD). Here, we analyzed the presence of the P39L variant in 761 patients with FTD and 719 controls and found a single carrier among patients. The patient was a 67-year-old male, with a positive family history for dementia, who developed apathy, short term memory deficit, and postural instability at 66. Clinical and instrumental workup excluded prion disease. At MRI, bilateral frontal lobe atrophy was present. A diagnosis of FTD was made, with a mainly apathetic phenotype. The *PRNP* P39L mutation may be an extremely rare cause of FTD (0.13%).

**Keywords:** Frontotemporal dementia, mutation, P39L, prion, *PRNP*

<sup>1</sup>These authors contributed equally to this work.

\*Correspondence to: Daniela Galimberti, Neurology Unit, Department of Pathophysiology and Transplantation, University

of Milan, Fondazione Ca' Granda, IRCCS Ospedale Policlinico, Milan, Italy. Tel.: +39 0255033847; Fax: +39 0255036580; E-mail: daniela.galimberti@unimi.it.

## INTRODUCTION

Over the past years, several genes have been identified as causative of autosomal dominant frontotemporal dementia (FTD), including microtubule associated protein tau gene (*MAPT*), progranulin (*GRN*), and *C9ORF72* (see [1] for review).

In addition, prion protein gene (*PRNP*) mutations have been associated with clinical pictures mimicking neurodegenerative diseases [2, 3]. So far, different mutations associated with clinical phenotype mimicking FTD with behavioral disturbances and/or parkinsonism have been found, mainly in C-terminal region [4, 5]. Moreover, a novel missense P39L mutation in *PRNP* has been recently reported in two patients with FTD syndrome [6] who were negative for mutations in genes causative of dementia known to date.

Here, we analyzed 761 Italian patients with FTD and 719 controls for the presence of the *PRNP* P39L mutation and found a carrier in patients and none in controls.

## POPULATION AND METHODS

### Subjects

Seven hundreds sixty one patients (374 males and 387 females; mean age  $\pm$  standard deviation (SD):  $67.2 \pm 8.8$  years; mean age  $\pm$  SD at onset:  $62.8 \pm 4.3$  years) with FTD were recruited at: Alzheimer Unit of the Fondazione Cà Granda, IRCCS Ospedale Maggiore Policlinico, University of Milan (Milan), Center for Research and Treatment of Cognitive Dysfunctions, “Luigi Sacco” Hospital (Milan), University of Torino (Torino), University of Florence (Florence), University Sapienza (Rome), IRCCS Istituto Centro San Giovanni di Dio- Fatebenefratelli (Brescia).

All patients underwent a standard battery of examinations, including medical history, physical and neurological examination, screening laboratory tests, neurocognitive evaluation, and imaging. Cognitive dysfunctions were assessed by the Clinical Dementia Rating (CDR), the Mini-Mental State Examination (MMSE), the Frontal Assessment Battery (FAB), the Wisconsin Card Sorting Test (WCST), and the Tower of London test. The presence of significant vascular brain damage was excluded (Hachinski Ischemic Score  $<4$ ). The diagnosis of FTD was made according to current consensus criteria [7] and subsequent revisions [8, 9]. The control group consisted of 719 non-demented volunteers (343 male and 376 female patients, mean age  $\pm$  SD:  $67.8 \pm 9.3$  years), matched

for ethnic background and age, without memory and psycho-behavioral dysfunctions (MMSE  $\geq 28$ ). Informed consent to participate in this study was given by all subjects or their caregivers.

### DNA isolation and genotyping

High-molecular weight DNA was isolated from whole blood using a Flexigene Kit (Qiagen, Hilden, Germany), as described by the manufacturer. The amount of DNA for each sample was determined by measuring the optical density at 260 nm wavelengths using a spectrophotometer (Eppendorf AG, Germany). DNA samples were aliquoted and stored at  $-20^{\circ}\text{C}$  until use.

This population was previously screened for *GRN*, *C9ORF72* and *MAPT* genes: 23 patients were carriers of mutations in *GRN*, one of a mutation in *MAPT* and 56 of the expansion in the *C9ORF72* [10].

Patients and controls were tested for *PRNP* P39L mutation by allelic discrimination, using the Taq-Man methodology. A specific custom probe for this mutation has been designed (c116c.t.F; Forward Primer Seq: AGCCTGGAGGATGGAACACT; c116c.t.R; Reverse Primer Seq: GGTAGCGTTGCCTCCA) and labeled with 6-FAM and VIC as reporter dyes and MGB-NFQ (ABI) as quencher. Assays were performed in  $20\ \mu\text{l}$  reactions in 96 well plates using a StepOne Plus instrument (ABI). PCR mix consisted of  $7.7\ \mu\text{l}$  universal Master Mix,  $1\ \mu\text{l}$  probe and water to reach the final volume. Thermocycling consisted of 10 min at  $95^{\circ}\text{C}$  for AmpliTaqGold activation, and 50 cycles of  $92^{\circ}\text{C}$  for 15 s and  $60^{\circ}\text{C}$  for 1 min.

The presence of the variant was confirmed by bidirectional sequencing analysis on an AB3130 automated sequencer (Applied Biosystems).

## RESULTS

The *PRNP* P39L variant was identified in one out of 761 FTD cases and in none of 719 controls. The carrier had the M129M genotype. The clinical and neuropsychological features of patient-carrier are reported in Table 1.

The patient was a 67-year-old male, who worked as a bricklayer until the age of 58, when he retired. His education was discontinued at primary school. Family history was positive for dementia: his mother died at the age of 70 with a 3-year history of dementia. In his past medical history, he suffered from hypertension, type II diabetes, dyslipidemia, chronic bronchitis, and chronic renal failure. He had a history of alcohol abuse

Table 1  
Characteristics of the carrier

Gender	Male
Age	67
Age at onset	66
Family History for dementia	positive (mother)
Clinical features	apathy short term memory deficit postural instability emotional bluntness anhedonia episodes of aggressiveness disorientation in space and partially in time reduction of spontaneous speech
Neuropsychological characteristics	Cognitive impairment: MMSE 17/30; FAB 5/18
CSF	
14.3.3	absent
A $\beta$	714 pg/ml
Tau	152 pg/ml
P-Tau	28 pg/ml

(two bottles of wine per day for 20 years from the age of 40 to 60) and was a former smoker (20 cigarettes per day for 40 years).

From the age of 66, he developed apathy, short-term memory deficit, and postural instability with three falls in one month. The symptoms rapidly progressed and the patient was admitted to a hospital within one month from their onset. During his stay, he underwent neuropsychology testing (MMSE 17/30, FAB 5/18), multiple electroencephalogram (EEG), which disclosed absence of periodism, electromyography, which was consistent with mild chronic sensorimotor axonal polyneuropathy, and MRI, that showed bilateral frontal lobe atrophy, confluent lesions in the white matter and no alteration in diffusion-weighted imaging (DWI). He also underwent lumbar puncture that showed a weak positivity for 14.3.3. Cerebrospinal fluid (CSF) amyloid- $\beta$  (A $\beta$ ) levels were 1031 pg/ml and total tau levels were 540 pg/ml (reference values: A $\beta$   $\geq$ 550 pg/ml; total tau:  $\leq$ 375 pg/ml [11]). Autoantibodies (paraneoplastic-anti Thyroglobulin and anti-Thyropoxidase) were all negative both in plasma and CSF. He came to our attention 6 months after symptom onset. The family reported emotional bluntness, apathy, anhedonia, and episodes of aggressiveness, but the clinical status had remained stable. He was dependent on his family for instrumental daily activity and required assistance in self-care.

At clinical examination, the patient was disoriented in space and partially in time (could just say the month and the year). Spontaneous speech was reduced, but he could answer questions when stimulated. Nam-

ing, comprehension and repetition were spared. The speech was monotone, with reduced vocabulary. He had difficulty sustaining attention and an apathetic attitude.

His cranial nerves were intact, in particular his pursuit and saccades were normal. He did not have any motor or sensory deficit. Deep tendon reflexes were reduced symmetrically. Tone was mildly increased, especially in lower limbs.

He was instable with mild multidirectional oscillations. His gait was slow and cautious and could make just few steps. He did not show any dysmetria. Jaw jerk, glabellar, and palmo-mental reflexes were present. Myoclonus was absent.

Brain MRI showed neither cortical ribboning nor basal ganglia hyperintensities on DWI. Multiple lesions in the white matter, interpreted as vascular lesions, were observed, together with bilateral frontal lobe atrophy. FDG-PET showed hypometabolism in prefrontal cortex and insula bilaterally and in the right caudate (Fig. 1). At EEG, no periodic complexes were present.

The lumbar puncture was repeated. The 14.3.3 protein was absent, A $\beta$  levels were 714 pg/ml, total tau levels were 152 pg/ml, phosphorylated-tau levels were 28 pg/ml (reference value:  $\leq$ 52 pg/ml [11]). No oligoclonal bands were present. In addition, autoantibodies (Hu-Yo-Ri-Ma1-Ma2-CV2- amphiphysin) were absent. Genetic testing was negative for *MAPT*, *GRN*, and *C9ORF72*.

At 6-month follow up (one year from the onset), the patient was still apathetic, anhedonic, dependent on daily activity, and with double incontinence. He still

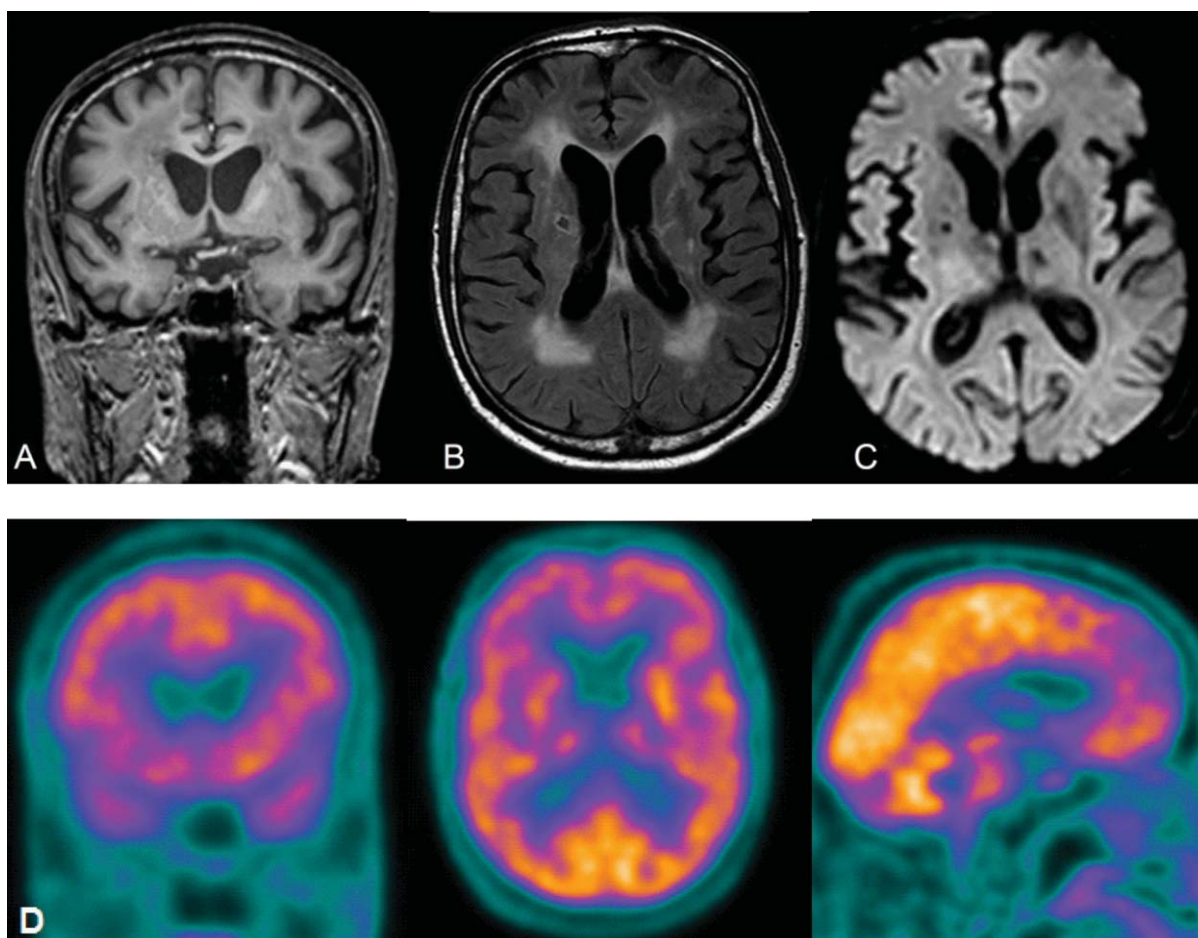


Fig. 1. MRI: A) Coronal T1 showing frontal lobe atrophy bilaterally; B) Axial flair with the evidence of multiple confluent lesions in the white matter; C) Axial diffusion-weighted imaging revealing neither hyperintensity in the cortex nor in the basal ganglia. D) FDG-PET showing hypometabolism in prefrontal cortex, insula and right caudate.

needed help for walking and developed preference for sweet food.

## DISCUSSION

In this study, we screened 761 FTD patients and 719 controls in order to test whether the PRNP P39L mutation may be causative of the disease. We found one carrier, who presented this variation in heterozygosis status, whereas in controls it was absent.

These results suggest that the PRNP P39L mutation is a very rare cause of FTD (frequency: 0.13% in our population). Moreover, the patient ancestors originated from Southern Italy, therefore it may be possible that he has a common founder with the patients previously reported by Bernardi et al. [6]. Unfortunately, we could not analyze the haplotype sharing in

these families to prove this hypothesis. Similarly to such patients, this case presented with frontal dementia dominated by dysexecutive syndrome whereas, conversely, he did not show severe behavioral disturbances, but apathy/anhedonia instead. Neuroimaging showed that atrophy was mainly frontal bilateral and did not show temporal or left parietal atrophy like the two previously described cases. This observation is consistent with the absence of language problems in this patient.

The presence of multiple lesions in the white matter, possibly due to vascular problems, considering his history of hypertension, type II diabetes, dyslipidemia, smoking and alcohol abuse, may be an additional factor in worsening the cognitive status of the patient. The CSF analysis, together with the clinical and instrumental workup, excluded the diagnosis of Creutzfeldt-Jakob disease [12].

Regarding the mechanism by which the variant is involved in FTD pathogenesis, it still remains not explained. It is, however, known that the N-terminal domain of PrP is highly conserved across species, suggesting it exerts a crucial biological role. It modulates “cellular Prp” conformer, which gives it a neuroprotective function controlled by several ligands [13]. The aminoacidic substitution could therefore produce a less rigid N-terminus with deleterious effects [6].

In conclusion, the PRNP P39L mutation may be an extremely rare cause of FTD, but the neuropathological confirmation will be needed to validate this hypothesis, preferably together with further replication in other cohorts.

## ACKNOWLEDGMENTS

This study was supported by the Italian Ministry of Health (Ricerca Corrente and 5x1000 Anno 2012 to ES and DG).

Authors' disclosures available online (<http://j-alz.com/manuscript-disclosures/15-0863r1>).

## REFERENCES

- [1] Galimberti D, Dell'Osso B, Altamura AC, Scarpini E (2015) Psychiatric symptoms in frontotemporal dementia: Epidemiology, phenotypes, and differential diagnosis. *Biol Psychiatry* **78**, 684-692.
- [2] Moore RC, Xiang F, Monaghan J, Han D, Zhang Z, Edström L, Anvret M, Prusiner SB (2001) Huntington disease phenocopy is a familial prion disease. *Am J Hum Genet* **69**, 1385-1388.
- [3] Guerreiro R, Brás J, Wojtas A, Rademakers R, Hardy J, Graff-Radford N (2014) A nonsense mutation in PRNP associated with clinical Alzheimer's disease. *Neurobiol Aging* **35**, 2656.e13-6.
- [4] Clerici F, Elia A, Girotti F, Contri P, Mariani C, Tagliavini F, Di Fede G (2008) Atypical presentation of Creutzfeldt-Jakob disease: The first Italian case associated with E196K mutation in the PRNP gene. *J Neurol Sci* **275**, 145-147.
- [5] Nitrini R, Teixeira da Silva LS, Rosemberg S, Caramelli P, Carrilho PE, Iughetti P, Passos-Bueno MR, Zatz M, Albrecht S, LeBlanc A (2001) Prion disease resembling frontotemporal dementia and parkinsonism linked to chromosome 17. *Arg Neuropsiquiatr* **59**, 161-164.
- [6] Bernardi L, Cupidi C, Frangipane F, Anfossi M, Gallo M, Conidi ME, Vasso F, Colao R, Puccio G, Curcio SAM, Mirabelli M, Clodomiro A, Di Lorenzo R, Smirne N, Maletta R, Bruni AC (2014) Novel N-terminal domain mutation in prion protein detected in 2 patients diagnosed with frontotemporal lobar degeneration syndrome. *Neurobiol Aging* **35**, 2657.e7-11.
- [7] Neary D, Snowden JS, Gustafson L, Passant U, Stuss D, Black S, Freedman M, Kertesz A, Robert PH, Albert M, Boone K, Miller BL, Cummings J, Benson DF (1998) Frontotemporal lobar degeneration: A consensus on clinical diagnostic criteria. *Neurology* **51**, 1546-1554.
- [8] McKhann GM, Albert MS, Grossman M, Miller B, Dickson D, Trojanowski JQ (2001) Clinical and pathological diagnosis of frontotemporal dementia: Report of the Work Group on Frontotemporal Dementia and Pick's Disease. *Arch Neurol* **58**, 1803-1809.
- [9] Rascofsky K, Hodges JR, Knopman D, Mendez MF, Kramer JH, Neuhaus J, van Swieten JC, Seelaar H, Dopper EGP, Onyike CU, Hillis AE, Josephs KA, Boeve BF, Kertesz A, Seeley WW, Rankin KP, Johnson JK, Gorno-Tempini M-L, Rosen H, Prioleau-Latham CE, Lee A, Kipps CM, Lillo P, Piguet O, Rohrer JD, Rossor MN, Warren JD, Fox NC, Galasko D, Salmon DP, Black SE, Mesulam M, Weintraub S, Dickerson BC, Diehl-Schmid J, Pasquier F, Deramecourt V, Lebert F, Pijnenburg Y, Chow TW, Manes F, Grafman J, Cappa SF, Freedman M, Grossman M, Miller BL (2011) Sensitivity of revised diagnostic criteria for the behavioural variant of frontotemporal dementia. *Brain* **134**, 2456-2477.
- [10] Galimberti D, Fenoglio C, Serpente M, Villa C, Bonsi R, Arighi A, Fumagalli GG, Del Bo R, Bruni AC, Anfossi M, Clodomiro A, Cupidi C, Nacmias B, Sorbi S, Piaceri I, Bagnoli S, Bessi V, Marccone A, Cerami C, Cappa SF, Filippi M, Agosta F, Magnani G, Comi G, Franceschi M, Rainero I, Giordana MT, Rubino E, Ferrero P, Rogava E, Xi Z, Confaloni A, Piscopo P, Bruno G, Talarico G, Cagnin A, Clerici F, Dell'Osso B, Comi GP, Altamura AC, Mariani C, Scarpini E (2013) Autosomal dominant frontotemporal lobar degeneration due to the C9ORF72 hexanucleotide repeat expansion: Late-onset psychotic clinical presentation. *Biol Psychiatry* **74**, 384-391.
- [11] Duits FH, Teunissen CE, Bouwman FH, Visser P-J, Mattsson N, Zetterberg H, Blennow K, Hansson O, Minthon L, Andreasen N, Marcusson J, Wallin A, Rikkert MO, Tsolaki M, Parnetti L, Herukka S-K, Hampel H, De Leon MJ, Schröder J, Aarsland D, Blankenstein, MA, Scheltens P, van der Flier WM (2014) The cerebrospinal fluid “Alzheimer profile”: Easily said, but what does it mean? *Alzheimers Dement* **10**, 713-723.e2.
- [12] Zerr I, Kallenberg K, Summers DM, Romero C, Taratuto A, Heinemann U, Breithaupt M, Vargas D, Meissner B, Ladogana A, Schuur M, Haik S, Collins SJ, Jansen GH, Stokin GB, Pimentel J, Hewer E, Collie D, Smith P, Roberts H, Brandel JP, van Duijn C, Pocchiari M, Begue C, Cras P, Will RG, Sanchez-Juan P (2009) Updated clinical diagnostic criteria for sporadic Creutzfeldt-Jakob disease. *Brain* **132**, 2659-2668.
- [13] Béland M, Roucou X (2012) The prion protein unstructured N-terminal region is a broad-spectrum molecular sensor with diverse and contrasting potential functions. *J Neurochem* **120**, 853-868.