MUSCULOSKELETAL SURGERY La Chirurgia degli Organi di Movimento

A study of 44 patients with subtrochanteric fractures treated using long nail and cerclage cables.

--Manuscript Draft--

Manuscript Number:	MUSC-D-15-00035R1
Full Title:	A study of 44 patients with subtrochanteric fractures treated using long nail and cerclage cables.
Article Type:	Original Article
Keywords:	subtrochanteric fracture, cerclage cable, long cephalo-medullary nail, mini-invasive
Corresponding Author:	Giovanni Noia, M.D. Policlinico Umberto I, Sapienza University of Rome rome, Italy ITALY
Corresponding Author Secondary Information:	
Corresponding Author's Institution:	Policlinico Umberto I, Sapienza University of Rome
Corresponding Author's Secondary Institution:	
First Author:	Pietro Persiani, MD, PhD
First Author Secondary Information:	
Order of Authors:	Pietro Persiani, MD, PhD
	Giovanni Noia, M.D.
	Claudia De Cristo, MD
	Graci Jole, MD
	Michele Dario Gurzì, MD
	Ciro Villani, MD, CHIARMAN
Order of Authors Secondary Information:	
Funding Information:	
Abstract:	Purpose: this study aims to demonstrate that the use of long cephalo-medullary nail and cerclage cables represents a good strategy in order to reduce the high risk of nonunion of the most displaced subtrochanteric fractures. Methods: This retrospective study examines 44 patients with average follow up of 23 months, with subtrochanteric fractures type SH IIB - C, IIIA - B treated by the same operator and with the same nail and cerclage cables. The clinical results which are derived from THRS have been reported. Results: Clinical and radiological consolidation occurred in all 44 cases, without re-intervention. The average evaluation derived from the THRS was 48 which corresponds to good, according to the scale. Conclusions: Considering the anatomic reduction achieved in all patients and the clinical results, we can define the use of long cephalomedullary nail and cerclage cables as the most useful technique in the armamentarium of a trauma surgeon for the treatment of the subtrochanteric fractures.
Response to Reviewers:	Reviewer 1: I'm agree with your introduction. This study aim to clarify what judicious use of cables means. Seeing the last studies published (1, 2) we can notice that cerclage cables could be used in this kind of fracture without any deleterious effect on bone healing, on the contrary seems to be a help for the faster healing of the fracture thanks to the anatomic reduction. 1.This is a good question because help me to explain better the article. I use this technique for the type II B when the spiral fracture is too long and in these case the closed reduction it is not enough, due to the action of the muscle groups that are inserted here.

	2.I have used traumatic hip score because this kind of score manage to combine a score based on the X-ray results and a score about hip functionality. 3.4. The meaning of our choice to use the Spearman correlation for the statistical analysis of our paper was to determine how the clinical feature of the patients and the severity of the fracture can influence the outcome measured by THRS score. Although, the meaning of our result could appear obvious, It show that the surgical treatment used can be mentioned as a factor that contributes to the fact that severity of the fracture measured with Sheinshemer score does not correlated with the final outcome 5.6. , 7. I have modified table I according to your advice 8. I apologize but, I don't have better quality x rays. Reviewer 2 1. A professional editing service has reviewed the manuscript. 2. This is a manuscript which report our experience and aims to show that the cerclage cable are a useful technique in the armamentarium of a trauma surgeon for the treatment of the subtrochanteric fractures. In our series thank to the small incision we haven't reported an increase in infections and blood loss. 4. I review time of surgery, in the previous version I have considered I considered the time of positioning of the patient, the time of the closed reduction of fracture and the time of surgery (from incision to suture. considering only the time of surgery we have as the average time of surgery 57,8 min, with minimum of 41 and maximum of 100 minutes. Reviewer 3 I have made general adjustments, as requested.

Conflict of interest statement

We certify to have no conflicts of interest, so We haven't financial and personal relationships with other people or organizations that could influence this work. We haven't accepted employment, consultancies, stock ownership, honoraria, paid expert testimony, patient applications and grants or other funding.

A study of 44 patients with subtrochanteric fractures treated using long nail and cerclage cables.

Pietro Persiani, M.D, Ph.D. Giovanni Noia, M.D. Claudia de Cristo, M.D Jole Graci, M.D Michele Dario Gurzì, M.D Ciro Villani, M.D, Chairman of Orthopaedic Department.

All authors belong to Sapienza, University of Rome, Umberto I hospital.

Piazzale Aldo Moro, 5 00187, ROMa (RM)

Corresponding author: Dr: Giovanni Noia. Telephone Number: +393280238547

Email: giovanni.noia@live.com

Acknowledgements

Thanks to Maria Elena Diamanti, graduate language and linguistics, for writing and translation assistance

Introduction

The subtrochanteric region of the femur is defined as the area extending 5 cm distally from the inferior border of the lesser trochanter. [1,2]

The subtrochanteric fractures can have a higher degree of displacement than the other lateral fractures of the femur [3,4].

The proximal fragment is abducted by the action of gluteus medius and minimus and, if the lesser trochanter is still attached, the iliopsoas flexes and externally rotates it. The adductors and hamstrings cause shortening and adduction of the distal fragment, producing a varus deformity [1,2,3].

The classification used in this study is the Seinsheimer classification, because in these fractures it is more useful for the evaluation of the severity of subtrochanteric fractures. [5,6,7].

The treatment of subtrochanteric fractures, especially groups SH IIB, IIC, IIIA, IIIB, with the long cephalo-medullary nail can present several difficulties [2].

It can be difficult to allow the passage of a guide wire. After the placement of a long cephalo-medullary nail, the fracture fragments can still appear displaced (5 -10 mm from each other), even if it is applied closed reduction. This can lead to varus malunion, and a prolonged time to radiographic evidence of fracture consolidation [8].

In addition to the cephalo-medullary nail it is necessary to use another method which can allow anatomic reduction and stable fixation, maintaining mini-invasive approach [4,8].

In literature same studies compare the outcomes of various methods of reduction before the application of cerclage cables. It is demonstrated that the clamp-assisted reduction leads to a longer time to weight-bearing and poorer functional status at one year compared to the use of cerclage cable [3,9].

Thorben M. et all. (10) reported that in view of the more invasive operative approach with additional soft tissue injuries, application of an additional cerclage should still be considered carefully. They also concluded that an additional cerclage in oblique subtrochanteric fractures is a good option to ensure the reposition and cortical medial support and to decrease osteosynthesis failure and rates of non-unions, so the damage to the soft tissue must be weighed against the benefit of the procedure.

Moreover the method of cerclage has been used for the periprosthetic hip fractures (Vancouver B1variety) with a satisfactory cure rate [8,9,11].

For the subtrochanteric fractures the cerclage has been used in two other studies which reported a consolidation rate of fourteen out of fifteen and twelve out of twelve with a good clinical evaluation [8,12].

Patients and Methods

Consolidation of the fracture is defined radiographically, following FDA guidelines, as the evidence of completely callus formation on standard plain X-rays until 9 months of the injury. Clinically consolidation is defined when the patient was able to walk either aided or unaided without pain at the fracture site.

The inclusion criteria were displaced subtrochanteric fractures type SH IIB, IIC, IIIA, IIIB, nonpathological, absence of other fractures (politrauma patients were excluded), fractures treated by the same surgeon and with the same cerclage cables and long intramedullary nail (ZNN®).

47 patients treated at our institution throughout February 2008 and April 2013 meet these criteria. 3 patients were lost during the follow up. Two patients died due to external causes, and the third patient was a homeless who was no longer reachable during the follow up.

Eighteen of these 44 patients were men and 26 were women.

The clinical status before the fracture was classified in 4 classes, depending on the status of deambulation. Four patients used axillary walker, fourteen patients constantly used one crutch with lameness, fourteen patients occasionally used one crutch without limping, twelve patients walked without limping and crutches.

The table I summarizes the data collected. The pre-oparative data included ASA, age, fractures type and hip functionality before fracture. The post operative data were days of hospitalization after surgery, time of surgery, traumatic hip rating scale (THRS), number of cerclage cables used.

The reduction was checked by fluoroscopy in anterior/posterior and axial planes. If the reduction obtained presents the deformities described above, the surgeon proceeds to reduce the fracture using the minimally-invasive technique as it follows.

An incision of 4 cm is made in the lateral aspect of the thigh centered at the fracture site in order to visualize the fascia lata. The fascia lata is then opened lengthwise, followed by blunt dissection of the fibers of the vastus lateralis until the fracture site is palpated. Then a reduction clamp is placed in position without stripping the periosteum. The fracture is reduced under fluoroscopic guidance (Figure 1 A) and then stabilized with a 1,8 mm cerclage wire immediately adjacent to the clamp. At this stage the surgeon decides the numbers of cerclages which should be used, evaluating the reduction achieved through fluoroscopy. It is important to be particularly careful where cerclage wires are placed to prevent them from interfering with the future introduction point for the lag screw.

If it is necessary the surgeon can apply another cerclage cable trough the incision used to introduce the lag screw, in order to respect the mini-invasiveness.

Although the fracture is reduced with the cerclage wire, the surgeon should try to avoid removing the clamp until the intramedullary nail is fully introduced [12].

Once the fracture is reduced and stabilized with the cerclage wire, the next step involves intramedullary fixation of the fracture with the long cephalomedullary nail (ZNN®) and the lag screw.

The average follow up was 23 months (12-46 months). Each patient was followed by subsequent clinical and radiological controls. The clinical outcome measures included the Traumatic Hip Rating Scale [12]. Radiological consolidation was evaluated by hip radiographs in 2P at 1, 3, 6, 9 months and at the last follow up. The clinical and radiographic evaluation were made by other two authors different from surgeons (GN and CdC). Moreover, we reported the time of surgery, the number of cerclages used, the number of blood units transfused during intraoperative phase and the number of postoperative days before discharge.

This study reports the clinical and radiological outcome of this treatment in order to define if and to what extent the cephalo-medullary nails and cerclage can determine an improvement of the patient with subtrochanteric fracture.

The SPSS for Windows is used to perform the analysis of correlation by determination of Spearman's rank and the analysis of association using the Chi-square test of Pearson. A P-value < 0.05 is considered statistically significant.

Results

Clinical and radiological consolidation of the fractures occurred in all 44 cases.

Radiographic consolidation occurred in all patients at the control of the sixth month post-operative.

Considering the definition of the CDC of deep or superficial infection, there were no cases of either superficial or deep infection. None of the patients required reintervention. Nobody reported a cutout of lag-screw. The cerclage cables did not move. There were no angular deformity >5° at the last follow up, and no cases of limb length discrepancy.

The number of cerclage most frequently used is two.

The average time of surgery was 57,8 minutes (SD 0,92). The average time of postoperative days before discharge was 5 days, including the delay due to the responses from rehabilitation clinics (SD 4,14). The average number of blood units transfused during intraoperative phase was 1.

The average evaluation derived from the THRS was 48 which corresponds to good, according to the scale (SD 5).

The only two patients who totaled 36 were patients who used a walker before the fracture and were classified as ASA 4.

The clinical results obtained at the last follow up showed that all patients returned to their deambulatory state before fracture.
The clinical results which derived from THRS at the last follow up were reported including the average score (with SD) obtained in each question in order to define, precisely, the clinical results of this treatment.
These results obtained at the last follow up show a good outcome for the pain and the radiographic evaluation. The reduction with varus less than 5°, which is the most important condition for fracture consolidation, was respected [11,13].
The results for the motion-muscle power and the walking (gait) are similar with an average value of 7. The average result for Daily activities is 5,9 (SD 3).
The analysis of correlation and association (table II -III) has showed the significance of the inverse relationship between the ASA and the THRS and the significance of the inverse relationship between the age and THRS ($p< 0,058$). These correlations demonstrate that the result of 36 totaled for the two 86 yo patients with ASA 4 are correlated to their co-morbidities and to their age.
Another two significant data are the association between the number of cerclages and the Seinshemer classification ($p< 0,026$) and the correlation between the number of cerclages and the ASA ($p< 0,011$). Considering the anatomic reduction achieved in all patients and the clinical results, we can define the use of long cephalomedullary nail and cerclage as the most useful technique in the armamentarium of a trauma surgeon for the treatment of the subtrochanteric fractures.

Discussion

The subtrochanteric area of the proximal femur is a high stress-concentration area. In fact, the medial side of subtrochanteric region experiences the highest compressive forces in the body with value up to 82 atm (by contrast to lateral cortex which experiences only 61,2 atm) [1,2].
Biologically, the subtrochanteric area is predominantly cortical bone and therefore has limited vascularity [2].
The literature recommended two types of treatment for the fractures of subtrochanteric region: nail or plate [14].
The use of plate leads to a large amount of periosteal stripping resulting in devascularization which often leads to nonunion and implant failure [2,15,16].
Rahme et all. (5) reported a non union rate of 28% for the plate group versus the 3% in the IM group and a revision rate of 28% in the plate group versus the 0% in the IM group.
When it is possible osteosynthesis through intramedullary nailing (no pathological fractures, no multifragmentary fractures, no fractures of the entry-point of the nail) is less surgically aggressive

and superior from a biomechanical point of view. In fact it is currently the most widely-used treatment for these fractures and provides better functional results than previous approaches [17,18,19].

Moreover, according to the literature the use of nail restores 58% of the femoral torsional stiffness of the intact femur and in axial load failed at 500% of the body weight. By contrast, the plate restores only 40% of torsional stiffness of intact femur and failed at 200% of the body weight [5,20].

The main problem in treating these fractures with intramedullary nails arises in presence of a short proximal fragment with a fixed flexion, abduction and external rotation deformity. This can result in malaligment with the subsequent risk of increased rates of non-union (7%) as compared to a fracture with an anatomic reduction where the nonunion rate can be as low as 2% [4,17].

Shukla et al. (3) reported that hospital stay time increased of 10 days in those subtrochanteric fractures fixed in varus, in contrast to those fixed anatomically. They also reported that a return to prefracture mobility status was significantly impaired by a non anatomical reduction, as only 21% returned to their pre-mobility status in the varus malunion group of patients versus 60% in those patients fixed in neutral alignment [3].

The treatment with long nail and cerclage cable with the anatomic reduction eliminates the risk of varus malunion, respecting to the aspired balance between anatomical reduction, reduced invasiveness and biological internal fixation [10,21,22,23,24].

The use of our technique has reduced the non-union rates . Indeed the other studies which analyze this technique reported a consolidation rate that is fourteen out of fifteen and twelve out of twelve patients [2,8].

The limitation of this study is its retrospective nature and small number of patients due to the fact that this is not a common fracture pattern.

References

1. Bedi A, Toan Le T. Subtrochanteric femur fractures. Orthop Clin North Am. 2004 ; 35: 473–483.

2.Tomás J, Teixidor J, Batalla L, Pacha D, Cortina J. Subtrochanteric fractures: treatment with cerclage wire and long intramedullary nail. J Orthop Trauma. 2013 ; 27(7) : 157–160.

3. Shukla S, Johnston P, Ahmad MA, Wynn–Jones H, Patel AD, Walton NP. Outcome of traumatic subtrochanteric femoral fractures fixed using cephalo–medullary nails. Injury 2007 ; 38(11) : 1286–1293.

4. Mustafa S, Koray U, Nadir S. Comparison of reduction methods in intramedullary nailing of subtrochanteric femoral fractures. Acta Orthop Traumatol Turc 2012 ; 46(2) : 113–119.

5. Rahme DM, Harris IA. Intramedullary nailing versus fixed angle blade plating for subtrochanteric femoral fractures: a prospective randomised controlled trial. J Orthop Surg 2007 ; 15(3) : 278–281.

6. Seinsheimer F. Subtrochanteric fracture of the femur. J Bone Joint Surg 1978 ; 60–A : 300–306.

7. van Doorn R, Stapert JW. The long gamma nail in the treatment of 329 subtrochanteric fractures with major extension into the femoral shaft. Eur J Surg 2000 ; 166 : 240–6.

8. Muiris T K, Airuddha M, Timothy G H, James A H, Declan R, Mark D. Subtrochanteric hip fractures treated with cerclage cables and long cephalomedullary nails: A review of 17 consecutive cases over 2 years. Injury 2011 ; 42 : 1317–1321.

9. Theerachai A, Phornphutkul C. Percutaneus cerclage wiring and minimally invasive plate osteosynthesis (MIPO): a percutaneous reduction technique in the treatment of Vancouver type B1 periprosthetic femoral shaft fractures. Arch Orthop Trauma Surg 2012 ; 132 : 813–822.

10. Thorben M, Tobias T, Christian A K. The benefit of wire cerclage stabilisation of the medial hinge in intramedullary nailing for the treatment of subtrochanteric femoral fractures: a biomechanical study. Intern Orthop (SICOT) 2011 ; 35: 1237–1243.

11. Briant–Evans TW, Veeramootoo D, Tsiridis E, Hubble MJ. Dynamic compression plates for Vancouver type B periprosthetic femoral fractures. A 3–year follow up of 18 cases. Acta Orthop 2009 ; 80(5) : 548–452.

12. Boopalan P R J V C, Jepegnanam T S, Nithyananth M, Venkatesh K, Cherian M V. Functional outcome of biological condylar blade plate of subtrochanteric fractures. J Orthop Sci 2012 ; 17 : 567–573.

13. Craig N, Sivaji C, Mafulli N. Subtrochanteric fractures. A review of treatment options. Hosp Joint Diseases 2001 ; 60(1) : 35–46.

14. Ruedi – Buckley - Moran. AO Principles of Fracture Management – Principles -

Specific Fractures. 2007.
15. Brien WW, Wiss DA, Becker Jr V, Lehman T. Subtrochanteric femur fractures: a comparison of the Zickel nail, 95 degrees blade plate, and interlocking nail. J Orthop Trauma 1991 ; 5(4): 458–464.
16. Perren SM. Evolution of the internal fixation of long bone fractures. The scientific basis of biological internal fixation: chosing a balance between stability and biology. J Bone Joint Surg Br 2002 ; 84-B: 1093–1110.
17. Robinson CM, Houshian S, Khan LAK. Trochanteric-Entry long cephalomedullary nailing of a subtrochanteric fractures caused by low energy trauma. J Bone Joint Surg Am 2005 ; 87 : 2217-2226.
18. Kraemer W J, Hearn T C, Powell J N, Mahomed N. Fixation of segmental subtrochanteric fractures. A biomechanical study. Clin Orthop Rel Res 1996 ; 332 : 71–79.
19. Kummer FJ, Olsson O, Pearlman CA. Intramedullary versus extramedullary fixation of subtrochanteric fractures. A biomechanical study. Acta Orthop Scand 1998 ; 69(6) : 580–4.
20. Tencer A F, Johnson K D, Johnston D W C, Gill K. A biomechanical comparison of various methods of stabilization of subtrochanteric fractures of the femur. J Orthop Res 1984 ; 2 : 297 –305.
21. Ely L. S, Ronen S. Braided cerclage wires: A biomechanical study. Injury 2011 ; 347–351.
22. Finsen V. The effect of cerclage wires on the strength of diaphyseal bone. Injury 1995 ; 26(3) : 159–161.
23. Mark L, Stephan M P, Boyko G. Underneath the cerclage : an ex vivo study on the cerclage–bone interface mechanics. Arch Orthop Trauma Surg 2012 ; 132 : 1467–1472. 11
24. Nather A, Ong HJC, Aziz Z. Structure of bone. In: Nather A, editor. Bone grafts and bone substitutes. Basic science and clinical applications. World Scientific Publishing Company ; 2005. p. 16.

Legends for illustrations

FIGURE 1. Fluoroscopy image which shows the achieved reduction trough the application of the clamps.

FIGURE 2. (A,C) X-ray of a 86y patient with SH IIB. A. Preoperative X-ray (notice the high degree of displacement) B Postoperative X-ray. C 6 months postoperative X-ray (notice the achieved consolidation and the absence of displacement of the lag screw and cerclage cables)

Figure

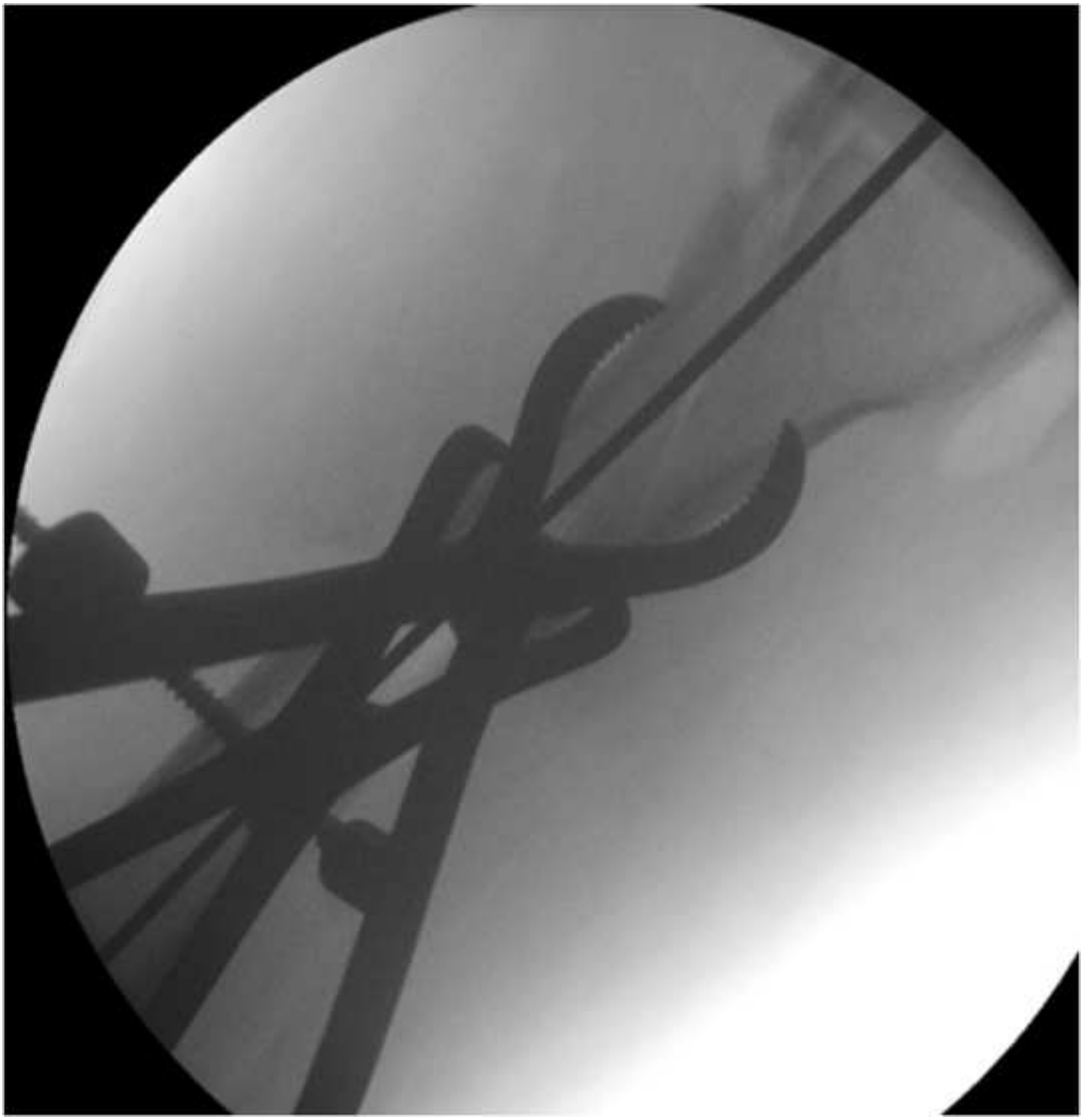

Figure

Figure

Figure

Table

Table I. - The preoparative and postoperative data

	N	Min	Max	Average	Median	Standard Deviation
AGE	44	43	93	78	/	7,326
N° CERCLAGE CABLES	44	1	5	/	2	1,077
ASA	44	1	4	/	2	,844
THRS	44	36	58	48,00	/	5,335
DAYS OF HOSPITALIZATION AFTER SURGERY	44	3	19	7,68	/	4,142
TIME OF SURGERY (min)	44	41	100	57,4	/	,926
SEINSHEIMER CLASSIFICATION	TYPE					N
	IIB					26
	IIC					8
	IIIA					8
	IIIB					9
STATUS OF DEAMBULATION BEFORE FRACTURE	CLASSES					N
	without limping and crutches					12
	occasionally one crutch without limping					14
	constantly used one crutch with lameness					14
	axillary walker					4

Table

Table II. Analysis of the correlations with Spearman's Rho

Spearman's Rho		AGE	N° CERCLAGE CABLES	ASA	SEINSHEMER CLASSIFICATION	TIME OF SURGERY	THRS
ASA	coefficient of correlation	,792	,381	1,000	,100	-,040	-,491
	Sig. (2-tail)	,000	,011	.	,520	,806	,001
	N	44	44	44	44	41	44
CLASSIFIC SEINSH	coefficient of Correlation	-,174	,191	,100	1,000	,293	,061
	Sig. (2-tail)	,260	,214	,520	.	,063	,693
	N	44	44	44	44	41	44
THRS	coefficient of Correlation	-,288	-,090	-,491	,061	-,339	1,000
	Sig. (2-tail)	,058	,560	,001	,693	,030	.
	N	44	44	44	44	41	44

Table

Table III. Analysis of the association with Chi-square of Person

Seinsheimer Classification	N° CERCLAGE CABLES					Tot
	1	2	3	4	5	
1	8	6	4	0	0	18
2	6	8	0	2	2	18
3	2	0	4	0	0	6
4	0	2	0	0	0	2
Totale	16	16	8	2	2	44
	Chi-square of Person	23,222	p-value	,026		