

Congenital Chagas disease in a Bolivian newborn in Bergamo (Italy)

Graziano Bargiggia¹, Maurizio Ruggeri², Gaia Ortalli¹, Simona Gabrielli³, Paola Rodari⁴, Lorenzo D'Antiga², Claudio Farina¹

¹Microbiology Institute, A.S.S.T. "Papa Giovanni XXIII", Bergamo, Italy;

²Pediatric Clinic, A.S.S.T. "Papa Giovanni XXIII", Bergamo, Italy;

³Parasitology Laboratory, Azienda Policlinico "Umberto I", Roma, Italy;

⁴Infectious Diseases Clinic, A.S.S.T. "Papa Giovanni XXIII", Bergamo, Italy

SUMMARY

Chagas disease (CD) is an uncommon disease in Europe. Its epidemiology has changed because of mass migration from Latin America to Europe. Herein we describe a congenital case of CD in a Bolivian newborn in Bergamo, the main city of residence for the Bolivian community in Italy. At delivery, serological analyses evidenced IgG antibodies against *Trypanosoma cruzi* both in the child and mother, as expected. Hemoscopic analyses on peripheral blood were repeatedly negative during the first months of life. Eventually, thanks to *T. cruzi* Real Time polymerase chain reaction (RT-PCR) positivity on peripheral blood

and development of progressive anemia in the following weeks, congenital Chagas disease was diagnosed and benznidazole-based therapy started. A progressive antibodies' index decrease was observed till negativity (306 days apart). RT-PCR was negative at the end of treatment. Our case is instructive and management of congenital CD is discussed from the perspective of a non-endemic country.

Keywords: Chagas disease, congenital, antibodies index, Real Time PCR.

INTRODUCTION

Chagas disease (CD) is a neglected tropical disease caused by the hemoflagellate *Trypanosoma cruzi*.

Although endemic in the rural Latin America, particularly in the Gran Chaco area of Bolivia, Paraguay and Argentina, its epidemiology changed in the last few decades due to the mass migration towards the United States, Europe and Italy particularly [1-2]. Among all, Bolivians are the most affected Latin Americans [3]. In Bergamo province, Northern Italy, the main Bolivian community in Italy is currently present, representing about 43% of all Bolivians resident in Italy. Considering undocumented people, about 10000 Bolivians are

living in Bergamo's province, out of 1.1 million. A previous retrospective (2012-2013) cohort study on 1305 Latin American residents in Bergamo's province showed *T. cruzi* seroprevalence in 17% of people [4]. More recent (2013-2016) data of *T. cruzi* infection in 561 Bolivians residents in Bergamo's province confirm the prevalence of 19% (unpublished data). In most part of cases CD is a silent disease; the chronic form, around a third of cases, evolves to heart or digestive disease, with important sequelae [5].

Children and pregnant women represent the most vulnerable population in the epidemiological chain of CD, also in non-endemic areas. Chronic CD, indeed, has appeared also in non-endemic areas in migrants, as it was for the acute forms mainly caused by vertical transmission during the period immediately before and after delivery [6].

Due to low and intermittent parasitemia, diagnosis of chronic CD is mainly performed through serological tests, using a whole-parasite antigen

Corresponding author

Claudio Farina

E-mail: cfarina@asst-pg23.it

or recombinant antigens [7]. The new generation tests stress the optimal characteristics in terms of sensitivity and specificity, probably linked to the greater *T. cruzi* protein differences, and their genetic diversity [8].

■ CASE REPORT

N.M.R. was born by spontaneous vaginal delivery at 34 week + 4 days (weight 5,99 lbs) on 14th March 2015, from a Bolivian mother. She tested positive to *T. cruzi* serology [index 10.9 (cutoff =1.0)] just before delivery by chemiluminescent microparticle immunoassay (CMIA) from recombinant antigens (Architect Chagas -Abbott Laboratories, Wiesbaden, Germany). The evidence of asymptomatic hypoglycemia and hyperbilirubinemia in the first hours of the child's life, considering the maternal serological reactivity, leads to in-depth diagnosis aimed at excluding a possible congenital CD.

For these reasons, direct parasitological analyses were first carried out to search for *T. cruzi* in peripheral blood (thin blood film, thick blood smears and buffy coat leukocyte) with negative results. Moreover, specific IgG antibodies were searched in child's serum samples by CMIA test from recombinant antigens. This analysis proved positive [index 11.27 (cutoff =1.0)], just like the one on the mother's serum.

This positive reaction was further confirmed by LineBlot procedure (NovaLine Chagas IgG - NovaTec Immundiagnostica GmbH - Germany) based on the recombinant TcF-Protein.

In the first four weeks of life, the baby suffered from frequent episodes of apnoea and hemolytic anemia (lowest haemoglobin level, 76 g/L), but direct Coombs test was negative, as other TORCH complex infections. Finally, he was again hospitalized one month after the birth because of his unclear apnoea and anemia.

Direct parasitological analyses on peripheral blood (with negative results) and reactivity to *T. cruzi* (CMIA index 8,14) were once more repeated before a transfusion of concentrated red cells. Echocardiography, brain and abdominal ultrasounds were normal.

On day 32 a peripheral blood sample was taken in EDTA and the execution of a Real-Time PCR (*T. cruzi* genesig® Advanced Kit, PrimerDesign™, UK) was requested: the test showed a "Weakly Positive" result.

In the following weeks the progressive and rapid anemization (Hb 76 → 62 g/L), in spite of the good general conditions with regular growth and advancement without evident etiological agent of disease (negativity in Coombs test, hemoglobin electrophoresis, osmotic resistance, G6PD deficiency) lead to a further hemotransfusional therapy.

Two further samples, drawn respectively on day 68 and 88, lead to a Real-Time PCR "Positive" results and confirmed the presence of circulating *T. cruzi* DNA.

Therefore, the diagnosis of *T. cruzi* congenital infection has been made, even if the only clinical evidences were recurrent anemia, prematurity and low birth weight.

On day 110 the pharmacological treatment based

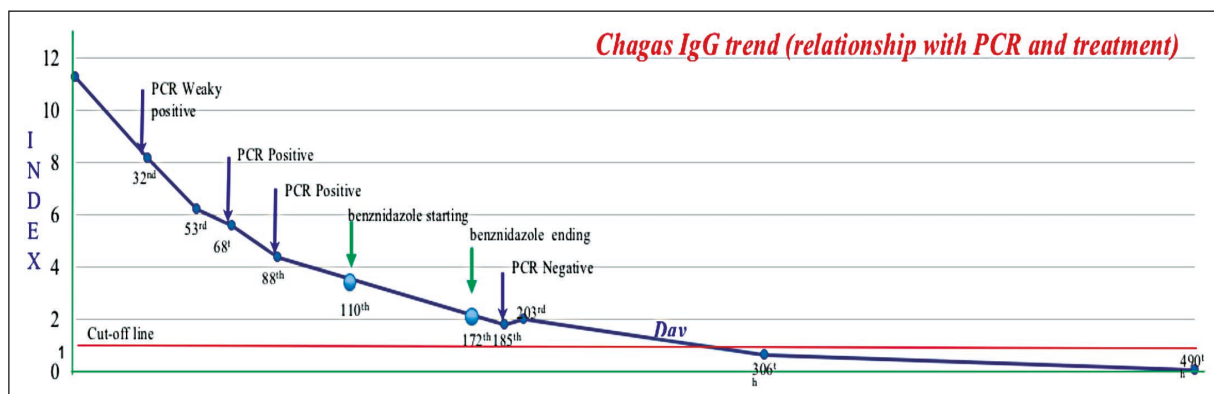


Figure 1 - Chagas IgG trend.

on benznidazole (Abarax, Laboratorio ELEA S.A.C.I.F. y A., Buenos Aires, Argentina) was started (4.85 mg/kg/die for 7 days; then, 8.5 mg/kg/die for 7 weeks).

The direct hemoscopic analyses repeated later were always negative and serological tests showed a reduction of the index from 6.22 to 5.57 and finally to 4.39.

On day 151, clinical analyses were indicative of good general conditions. The patient was vigilant and responsive, with regular trophism, autonomous breath, valid and pure heart tone, autonomous pauses, manageable flat abdomen. Liver and spleen were within the limits and the lymphatic apparatus was unharmed. The pharmacologic therapy was maintained till day 172, and then suspended.

On day 185 a reduction in the anemia picture frame (Hb 11.5 g/L) was observed. The Real-Time PCR test showed no evidence of *T. cruzi* DNA in the peripheral blood, the hemoscopic checks were negative and the antibodies in steep decrease (index 1,80).

Finally, on day 306 the serological analysis turned negative (index 0,63), and this result was reconfirmed by the 30-month-later follow-up, as summarized in Figure 1.

At the end of the breast-feeding period, the child's mother was treated with benznidazole, for two months.

■ DISCUSSION

CD currently represents an emerging public health problem, particularly in pregnant women and newborns. Not-endemic countries and Italy do not represent an exception.

In Bergamo, where the main Bolivian community in Italy resides, a protocol has been agreed with the Public Health Authorities to monitor the specific antibodies in Bolivian women within the third month of pregnancy or at delivery, to perform hemoscopic check in the newborn's peripheral blood in case of maternal seropositivity, and to make a comparison between the mother's antibody index and the newborn's one at least for one year after the birth and in any case till negativity. The cure assessment is evaluated through parasitological and serological methods [9, 10].

Even if no congenital CD cases are reported in

Italian literature, it remains a diagnostic challenge, particularly if direct parasitological analyses carried out at delivery to search for *T. cruzi* in peripheral blood (thin blood film, thick blood smears and buffy coat leukocyte) are negative, clinical condition of the newborn are not highly suggestive for CD, maternal and child's serological index are similar, and PCR is not available.

The decrease of antibody index highlighted by the use of CMIA test (sensitivity 100%, specificity 97.6%) is comforting because it allows us to believe that the infectious process which has affected the child is evolving in a favorable way [11].

Abras et al. report a continuous decreasing trend of passive IgG antibodies in 12-months in non-infected newborns; however, the antibody decline shows up after the start of the treatment in CD cases [12].

Considering that antibodies disappear at different time scales according to the phase of the disease, the age of patients and the genetic variability of *T. cruzi*, PCR can be a helpful tool to monitor acute forms of the disease; however, due to the intermittent and low parasitemia in the post-acute phase of CD, a negative PCR result does not necessarily suggest absolute absence of the parasite [13, 14]. The evidence of PCR tests which become positive once more, indeed, permits to record therapeutic failures after the treatment in the recent trials, probably due to a poor effectiveness of the benznidazole to penetrate into the infected tissues or to the existence of *T. cruzi* strain resistant to the currently used drugs [15, 16].

A different strategy is suggested for the diagnosis of congenital CD: polymerase chain reaction (PCR) could be proposed to confirm the maternal serological reactivity, and for newborns direct parasitological exams and PCR represent important tools in the first weeks of life, even if a positivity at that time could be considered as a maternal contamination, particularly in asymptomatic children, and serology is used after the first six months of life when maternal antibodies are lost [12].

In conclusion, we believe that active screening for *T. cruzi* infection in at risk pregnant women is of primary importance to guide newborn (and mother) follow-up: TORCH complex should not be regarded as a fix and limited disease complex, especially in this era of globalization. Moreover, all newborns, even if asymptomatic, whose mothers are of Latin American origin should perform

active clinical and microbiological check-ups. Those diagnosed of congenital CD must be followed with appropriate laboratory tests, including RT-PCR, every six months for at least the first few years of life.

ACKNOWLEDGMENTS

We thank Andrea Angheben, M.D., Tropical Diseases Center, Ospedale Equiparato Classificato Sacro Cuore - Don Calabria, Negrar (Italy) for his helpful criticism.

■ REFERENCES

- [1] Gascon J., Bern C., Pinazo M.J. Chagas disease in Spain, the United States and other non-endemic countries. *Acta Trop.* 115, 22-27, 2010.
- [2] Guerri-Guttenberg R.A., Ciannameo A., Di Girolamo C., Milei J.J. Chagas disease: an emerging public health problem in Italy? *Infez. Med.* 1, 5-13, 2009.
- [3] Requena-Méndez A., Albajar-Viñas P., Angheben A. et al. Health policies to control Chagas disease transmission in European countries. *PLoS Negl. Trop. Dis.* 8, e3245, 2014.
- [4] Repetto E.C., Zachariah R., Kumar A. et al. Neglect of a neglected disease in Italy: the challenge of access-to-care for Chagas Disease in Bergamo Area. *PLoS Negl. Trop. Dis.* 9, e0004103, 2015.
- [5] Pérez-Molina J.A., Molina I. Chagas disease. *Lancet.* 391, 10115, 82-94, 2018.
- [6] Herrador Z., Rivas E., Gherasim A. et al. Using hospital discharge database to characterize Chagas disease evolution in Spain: there is a need for a systematic approach towards disease detection and control. *PLoS Negl. Trop. Dis.* 9, e0003710, 2015.
- [7] Bem C. Chagas' disease. *N. Engl. J. Med.* 373, 456-466, 2015.
- [8] Praast G., Herzogenrath J., Bernhardt S., Christ H., Sickinger E. Evaluation of the Abbott Architect Chagas prototype assay. *Diagn. Microbiol. Infect. Dis.* 69, 74-81, 2011.
- [9] Carlier Y., Torrico F., Sosa-Estani S., et al. Congenital Chagas Disease: recommendations for diagnosis, treatment and control of newborns, siblings and pregnant women. *PLoS Negl. Trop. Dis.* 5, e1250, 2011.
- [10] Guedes P.M., Silva G.K., Gutierrez F.R., Silva J.S. Current status of Chagas disease chemotherapy. *Expert Rev. Anti Infect. Ther.* 9, 609-620, 2011.
- [11] Abras A., Gállego M., Llovet T., et al. Serological diagnosis of chronic Chagas disease: is it time for a change? *J. Clin. Microbiol.* 54, 1566-1572, 2016.
- [12] Abras A., Muñoz C., Ballart C., et al. Towards a new strategy for diagnosis of congenital *Trypanosoma cruzi* infection. *J. Clin. Microbiol.* 55, 1396-1407, 2017.
- [13] Coura J.R., Borges-Pereira J. Chagas disease. What is known and what should be improved: a systemic review. *Rev. Soc. Brasil. Med. Trop.* 45, 286-296, 2012.
- [14] Rassi Jr A., Rassi A., Marin-Neto J.A. Chagas disease. *Lancet* 375, 1388-1402, 2010.
- [15] Schijman A.G., Bisio M., Orellana L., et al. International study to evaluate PCR methods for detection of *Trypanosoma cruzi* DNA in blood samples from Chagas disease patients. *PLoS Negl. Trop. Dis.* 5, e931, 2011.
- [16] Mejía-Jaramillo A.M., Fernández G.J., Montilla M., Nicholls R.S., Triana-Chávez O. *Trypanosoma cruzi* strain resistant to benznidazole occurring in Colombia. *Biomédica* 32, 196-205, 2012.