

# Clinical comparison between an opaque and a clear pit and fissures sealants: a 12-month split-mouth, randomized controlled study

G.M. Nardi<sup>1</sup>, M. Mazur<sup>1</sup>, D. Corridore<sup>1</sup>, M. Capocci<sup>1</sup>, F. MD. Rinaldo<sup>1</sup>, A. Maruotti<sup>2</sup>, L. Ottolenghi<sup>1</sup>, F. Guerra<sup>1</sup>

<sup>1</sup>Department of Oral and Maxillofacial Sciences, Sapienza University of Rome; <sup>2</sup>Lumsa University, Rome, Italy

## Abstract

**Trial design.** We design a clinical split-mouth, randomized controlled study, in which the retention of an opaque and clear pit and fissures sealants were evaluated and their effectiveness compared at 6 and 12 months of follow up. A secondary aim was to evaluate the possibility of using a fluorescence based intra-oral camera through the clear sealant to monitor enamel demineralization.

**Methods.** Consecutive young adolescents with at least two molars with code 0, 1, 2 caries evidenced following the International Caries Detection and Assessment System (ICDAS II) were enrolled. A split-mouth randomized allocation was carried out. One skilled operator applied the sealant under 3.5 X magnification. A second operator evaluated clinical retention and performed the intra-oral camera assessments at 6 and 12 months follow up.

**Results.** A total of 42 patients, (20 males and 22 females, mean age 14.25) with 176 dental lesions were enrolled. Nine patients dropped out accounting for 26 teeth lost during follow up. Overall, a total of 150 sealed teeth were evaluated in the study. In 77 cases the clear sealant was used, while in 73 the opaque sealant was utilized. The opaque sealant rated 100% complete retention at 6 months, and 97.3% at 12 months, while the clear sealant 91.8% and 85.9% respectively. Demineralization under clear sealant was registered when sealant partial detachment occurred.

**Conclusions.** The overall retention rate of an opaque sealant was higher than that of a clear sealant after 12 months of follow-up. This difference may partly be due to difficulty in clinical detection of clear sealants during follow-up. Fluorescence based intra-oral camera seems useful to monitor enamel demineralization in clear sealant. *Clin Ter* 2018; 169(1):e5-9. doi: 10.7417/CT.2018.2046

**Key words:** clear sealant, opaque sealant, retention, fluorescence, demineralization

## Introduction

Despite a better oral hygiene conditions, young adolescents continue to have problems with dental caries even in low caries prevalence populations. In the USA, the 2011-2012 National Health and Nutrition Examination Survey

(NHANES) shows that 21% of children aged 6 to 11 years and 58% of adolescents aged 12 to 19 years had experienced carious lesions in their permanent teeth.

A very effective treatment of dental caries are dental sealants that were first introduced in the 1960s as part of preventive dental programs, which resulted in a decrease in the prevalence of dental caries among children and adolescents in the 70s and 80s (1-3).

A recent expert panel by the American Dental Association (ADA) Council on Scientific Affairs and the American Academy of Pediatric Dentistry, updated the previous evidence-based clinical recommendations for the use of sealants. They concluded that in children and adolescents sealants are effective both from primary and secondary prevention as compared with the non use of sealants or the use of fluoride varnishes (4). The panel recognized that it was not possible to recommend on the type of sealant over the others (resin-based sealants, glass ionomer (GI) cements, GI sealants, polyacid-modified resin sealants, and resin-modified GI sealants). They also underlined that, in order to achieve good sealant retention, clinicians should carefully consider the individual patient factors and select case by case the clinical approach (4).

Main goal of the study is to evaluate a clinical split-mouth, randomized controlled study, in which the retention of an opaque and a clear pit and fissures sealants were assessed and their effectiveness compared at 6 and 12 months of follow up. A secondary aim was to evaluate the possibility of using a fluorescence based intra-oral camera through the transparent sealant to monitor enamel demineralization.

## Material and methods

### Study population

The study was performed at the 1st Observation Unit of Department of Oral and Maxillofacial Sciences, "Sapienza" University of Rome. Consecutive young adolescents with at least two molars with code 0, 1, 2 caries evidenced following the International Caries Detection and Assessment

Correspondence: Dott. Fabrizio Guerra: fabrizio.guerra@uniroma1.it

System (ICDAS II) were enrolled. Recruitment was carried out between September 2015 and November 2015; the six months follow up was performed between April-June 2016 and the twelve months follow up between October-December 2016.

Patients with orthodontic appliances were excluded from this study.

The study was approved by the Local Ethical Committee (n. 3340) and patients signed informed consent.

Baseline patients' caries prevalence was described by DMFT. Baseline conditions of the tooth surfaces to be treated were clinically assessed with ICDAS II (code 0, 1, or 2) and with a fluorescence based intra-oral camera (VistaCam iX Proof, Dürr Dental AG), in which a cutoff value of 1.5 was considered to indicate early enamel demineralization.

#### *Description of the Sealants*

Two different sealants were used, the Grandio Seal (VOCO GmbH) and the Control Seal (VOCO GmbH).

The Grandio Seal is a light-curing nano-hybrid opaque sealant with 70% w/w highest filler content in its class and presents good physical properties in terms of low abrasion, high transverse strength, with extremely low shrinkage values.

The Control Seal is a light-curing highly filled, clear sealant containing fluoride, with the highest filler content among the transparent fissure sealants (55% w/w). It is suitable for laser fluorescence-based diagnostic methods and presents good physical properties in terms of high compressive strength, high flexural strength, with a low level of abrasion.

#### *Sample size*

A sample size of 123 teeth achieves 80% power at a 3% significance level using a one-sided equivalence test of correlated proportions when the standard proportion is 0.85, the maximum allowable difference between these proportions that still results in equivalence (the range of equivalence) is 0.05, and the actual difference of the proportions is 0.025.

Expecting a percentage of drop out of 10%, it will be assessed a total of 136 teeth.

#### *Randomized allocation*

The selected teeth were randomly assigned to receive the clear sealant or the opaque sealant. A split-mouth randomization was carried out as follows: the sealant material for the first tooth to be sealed per mouth was chosen according to the patient's birth date. Odd numbers were allocated to the clear sealant, while even numbers to the opaque sealant. The opposite material was chosen from the upper right quadrant, following with the upper left, lower left, and finally lower right quadrant. Based on this randomization, both molars in either the upper or lower jaws were sealed by a different material.

#### *Clinical Procedure*

One skilled dentist applied the sealant on the selected teeth, under 3.5 X magnification. After rubber dam placement, occlusal pit and fissures were cleaned with rotifox and

abrasive paste without fluoride, then water spray rinsed and air dried. Twenty to thirty seconds conditioning with 37% phosphoric acid followed by water spray for 60 seconds and air drying were performed, followed by sealant application, light curing and occlusal control (5).

Clinical follow-up at 6 and 12 months was performed by a different skilled operator to assess sealant retention and to monitor any demineralization trend under the clear sealant using the fluorescence measurements. Blinding of outcome assessors was not possible, as the clinical aspect of the sealants was dissimilar.

#### **Statistic analysis**

We have performed a logistic regression analysis to investigate if the treatment has a significant effect on retention at 6 and 12 months. The results of the logistic regression are presented as Odds ratios and 95%CI.

#### **Results**

A total of 42 patients, (20 males and 22 females, mean age 14.25) with 176 dental surfaces were enrolled. Nine patients, accounting for 26 teeth, dropped out during follow up.

Overall, a total of 150 sealed teeth were evaluated in the study. In 77 cases the clear sealant was used, while in 73 the opaque sealant was applied (Fig. 1 Consort flow chart).

Baseline patients' caries prevalence was described by DMFT, with a reported mean value of 2.07 (max 8; min 1).

#### *Opaque sealant retention*

Complete sealant retention rated 100% at 6 months, and 97.3% at 12 months. At 12 month follow up one case of partial and one of complete detachment of the sealant were observed. All the teeth with partial and null retention were located in the first quadrant.

#### *Clear sealant retention*

Complete sealant retention rated 91.8% at 6 months, and 85.9% at 12 months. Four cases of complete detachment of the sealant were observed at 12 months. Incomplete sealant retention occurred in 8.2% of cases at 6 months and in 14.1% of cases at 12 months. Four teeth with partial retention were in the first quadrant, three in the second, one in the third, and two teeth in the fourth quadrant. Two complete detachment presented in the second quadrant, one in the first and one in the third, respectively.

#### *VistaCam Assessment*

At baseline, 53% of the registered teeth were sound, both visually and when using the fluorescence camera; 47% presented an early demineralization (<1.5 with VistaCam with a mean score of 1.26, min 1.2-max 1.5 and ICDAS II 1- 2 code). Subsequent VistaCam assessment of surfaces underlying the transparent sealant did not changed from

CONSORT 2010 Flow Diagram

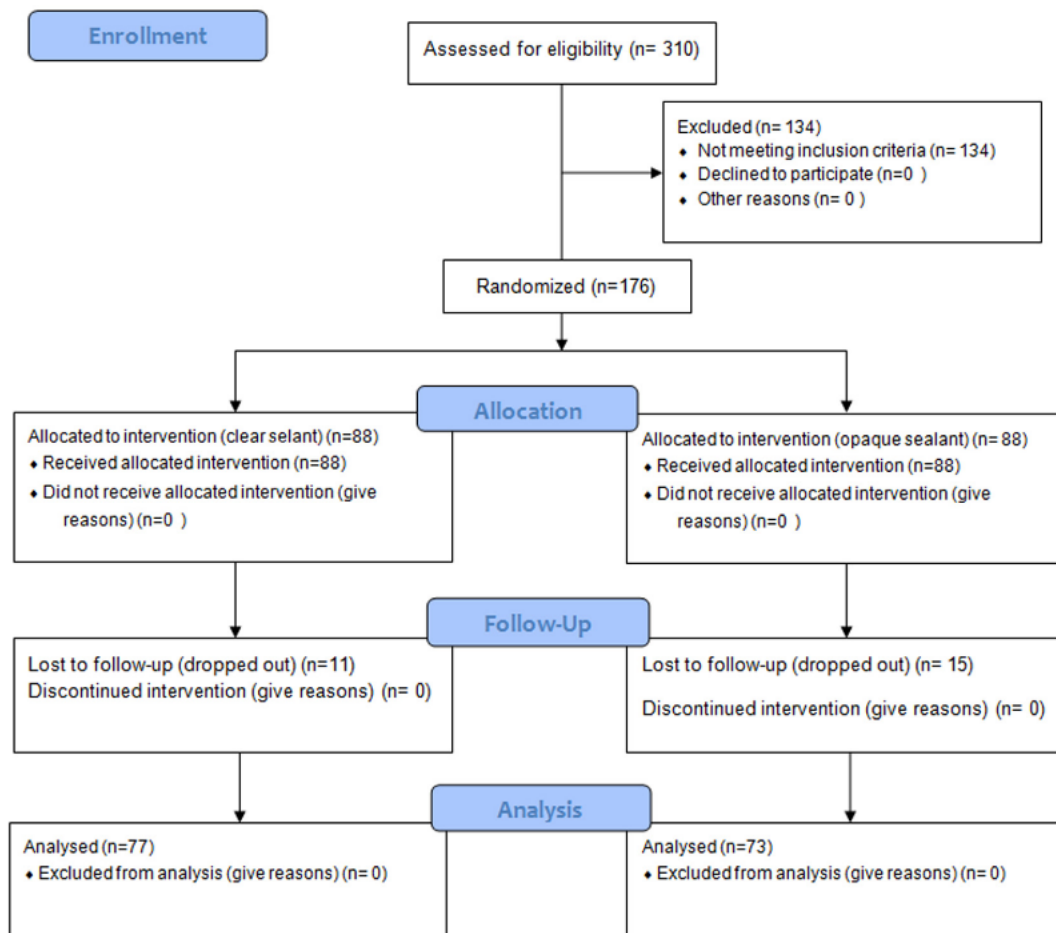


Fig. 1

the initial evaluations. At the 6-month follow-up, VistaCam measurements resulted stable in the whole sample. At 12-month follow up VistaCam confirmed previous evaluations, except for two permanent molars that showed an increase of demineralization from 1.2 to 1.3 in the VistaCam assessment and partial sealant retention.

**Statistical analysis**

Our main outcome is the total vs. partial tooth retention, and accordingly a binary outcome is considered. We have performed a logistic regression analysis to investigate if the treatment has a significant effect on retention at 6 and 12 months. Two different single-covariate equations are considered including a treatment dummy variable as predictor of the probability of recording a total retention. The results of the logistic regression are presented as Odds ratios and 95%CI.

Results are displayed in Table 1:

Table 1. The results of the logistic regression are presented as Odds ratios and 95% CI.

Variable	At 6 months		At 12 months	
	OR	95% CI	OR	95% CI
Treatment = G	1.536	0.564-4.62	3.804	1.551-10.785

By looking at the statistical analysis, no difference is estimated at 6 months between the two treatments; the coefficient associated to the treatment variable is not statistically significant. At 12 months we estimate instead a significant relationship between the G-treatment (Grandio Seal) and the probability of observing a total retention: the G-treatment leads to an odds ratio of 3.80 times (given by

the exponential of the associated coefficient 1.3361) with respect to the C-treatment (Control Seal), i.e a strong increase in the probability of having a total retention under the G-treatment is estimated.

## Discussion

In the present study, we compared the retention rate between a clear and an opaque sealant in a cohort of young adolescents. Overall, no difference among two sealants was found at 6-month, while at 12-month follow-up a significant increase in the clinical effectiveness of the opaque sealant was demonstrated (97.3% versus 85.9%,  $p=0.006$ ), i.e. a strong increase in the probability of having a total retention under the G-treatment is estimated.

Sealants are widely used in primary and secondary prevention (6) (7). Many clinical and in vitro studies showed their effectiveness in preventing both new occlusal caries and progression of demineralized caries, as the sealants eliminate contact with the oral fluids and the cariogenic bacteria. In 2002, Simonsen reported complete sealant's retention with a single application of opaque sealant in 82%, 57% and 28% of sealed teeth at five, 10 and 15 years, respectively. Griffin et al. (8) evaluated the effectiveness of sealants in managing caries lesions in a meta-analysis, and found their effectiveness in preventing dentin caries (annualized probability of preventing progression) to be in the range of 62% to 100% (median 74% for all; 83% for non-cavitated and 65% for cavitated lesions). They recommended the placement of sealants to arrest lesions in the early carious stages and also to surfaces where caries status is uncertain.

Regarding the question about which sealant should be used over the others, Simonsen (6), concluded that the use of an opaque versus a clear resin sealant is a matter of personal preference. However, it has been shown that the ability to properly assess retention in opaque sealants is much less error prone than with clear sealants. This is mainly due to difficulty in clinical detection of clear sealants during follow-up. (9) On the other hand, clear sealants do not interfere with the potential for laser fluorescent diagnosis of caries under the sealant once placed on pit and fissure. This may eventually become a valuable adjunct procedure in the follow-up routine of patients after sealant placement. (10) To this regard, a recent in vitro study on 31 teeth, investigating the effect of sealant placement on the detection of caries by using a fluorescence camera (Spectra caries detector) concluded that the camera system can detect caries under clear sealant with little loss of sensitivity (11).

In our study, we used the split mouth randomized design to compare the clinical effectiveness of the opaque sealant versus the clear one for the treatment of pit and fissures in a large cohort of young adolescences. The split mouth design of the study allowed us to compare the two sealants in the same environment, thus removing inter-individual variability and decreasing the possibility for a selection bias. Overall, we found that there was a significant higher effectiveness of the opaque sealant versus the clear one after one year of follow up. We believe that it is possible that, the presence of a clear sealant may not be identified on treated

tooth during follow up as previously reported by Rock and colleagues (9).

Fluorescence assessment was the main limitation of our study. Readers should be aware that laser fluorescence can be used on clear as well as on opaque sealed teeth, while VistaCam assessments can be performed only on clear sealants.

We assessed the feasibility and performance of the use of fluorescence based camera assessment of surfaces underlying the transparent sealant to evaluate its clinical effectiveness in assessing the demineralization trend underneath the sealant. We found that VistaCam assessment of surfaces underlying the transparent sealant found no changes over baseline data. The only exceptions were two permanent molars, which presented a slight increase of demineralization and partial sealant retention. Based on this performance data, which is close to the 97.3% rate of complete sealant retention at one year, it is plausible to speculate that some of the patients treated with clear sealant might have been unrecognized during subsequent clinical evaluation. However, no data on fluorescence based camera assessment of surfaces underlying the transparent sealant in humans are available and our hypothesis needs confirmation in future studies.

## Conclusions

In our study, we found that the overall retention rate of an opaque sealant was higher than that of a clear sealant after 12 months of follow-up. This difference may partly be due to difficulty in clinical detection of clear sealants during follow-up. Fluorescence based intra-oral camera seems useful to monitor enamel demineralization in clear sealant.

Acknowledgement of Funding Sources: this project has been made possible, in part, by VOCO GmbH.

## References

1. Marthaler TM ODVV. The prevalence of dental caries in Europe 1990-1995. ORCA Saturday Afternoon Symposium 1995.. *Caries Research* 1996; 30(4):237-55
2. TM. M. Changes in dental caries 1953-2003. *Caries Research* 2004; 38(3):173-81
3. Petersson GH BD. The caries decline: a review of reviews. *European Journal of Oral Sciences* 1996; 104 (4 Pt 2):436-43
4. Wright J, Crall J, Fontana M, et al. Evidence-based clinical practice guideline for the use of pit-and-fissure sealants. *J Am Dent Assoc* 2016; 147(8):672-82
5. Guerra F, Mazur M, Rinaldo F, et al. Clinical procedure in sealing pit and fissure using technological aids: VistaCam iX Proof and Combi. *Senses Sci* 2016; 3(1):157-62
6. Simonsen R. Pit and fissure sealant: review of the literature. *Pediatric Dentistry*. 2002; 24(5):393-414
7. Leo M, Cerroni L, Pasquantonio G, et al. Economic evaluation of Dental Sealants: A systematic review. *Clin Ter* 2016;167(1):e13-20. 2016; 167(1):e13-20
8. Griffin S, Oong E, Kohn W, et al. CDC Dental Sealant Systematic Review Work Group ea. The effectiveness of sealants

- in managing caries lesions. *J Dent Res* 2008; 87(2):169-74
9. Rock W, Potts A, Marchment M, et al. The visibility of clear and opaque fissure sealants. *Br Dent J* 1989; 167:395-6
  10. Takamori KH, Okumura Y, Watanabe S. Detection of occlusal caries under sealants by use of a laser fluorescence system. *J Clin Laser Med Surg*. 2001; 19:267-71
  11. Markovitz K, Rosenfeld D, Peikes D, et al. Effect of pit and fissure sealants on caries detection by a fluorescent camera system. *J Dent* 2013; 41(7):590-9
  12. Fejerskov O, Kidd E, Nyvad B, et al. Defining the disease: an introduction. In Fejerskov O, Kidd E. *Dental Caries The Disease and its Clinical Management*. Oxford: Blackwell Munksgaard Ltd; 2008; 3-6
  13. Keyes P. The infectious and transmissible nature of experimental dental caries. Findings and implications. *Arch Oral Biol*. 1960;(1):304-20
  14. Carvalho J, Ekstrand K, Thylstrup A. Dental plaque and caries on occlusal surfaces of first permanent molars in relation to stage of eruption. *J Dent Res* 1989; 68(5):773-9
  15. Marthaler T. Changes in dental caries 1953-2003. *Caries Res* 2004; 38:173- 81
  16. Welbury R, Raadal M, Lygidakis N. EAPD guidelines for the use of pit and fissure sealants. *Eur J Paediatr Dent* 2004; 5(3):179-84
  17. Feigal R, Donly K. The use of pit and fissure sealants. *Pediatr Dent* 2006; 28(2):143-50
  18. Beauchamp J, Caufield P, Crall J, et al. Evidence-based clinical recommendations for the use of pit-and- fissure sealants: a report of the American Dental Association Council on Scientific Affairs. *J Am Dent Assoc* 2008; 139(3):257-68
  19. Elderton R, Jenkins C, Marshall K, et al. Changing perceptions of the requirements of cavity preparations. *Br Dent J* 1990; 168(1):30-2
  20. van Amerogen J, van Amerogen W, Watson T, et al. Restoring the tooth: the seal is the deal. In Fejerskov O, Kidd E. *Dental Caries The Disease and its Clinical Management*. Oxford: Blackwell Munksgaard Ltd 2008; 385-426
  21. Simonsen R. Retention and effectiveness of dental sealant after 15 years. *J Am Dent Assoc* 1991; 122(10):34-42
  22. Romcke R, Lewis D, Maze B, et al. Retention and maintenance of fissure sealants over 10 years. *J Can Dent Assoc* 1990; 56(3):235-7
  23. Mertz-Fairhurst E, Schuster G, Fairhurst C. Arresting caries by sealants: results of a clinical study. *J Am Dent Assoc* 1986; 112(2):194-7
  24. Poulsen S, Laurberg L, Vaeth M, et al. A field trial of resin-based and glass-ionomer fissure sealants: clinical and radiographic assessment of caries. *Community Dent Oral Epidemiol*. 2006; 34(1):36-40
  25. Siegal M. Promotion and use of pit and fissure sealants: an introduction to the special issue. *J Public Health Dent*. 1995; 55(5):259-60
  26. Ekstrand K, Christiansen M. Outcomes of a non-operative caries treatment programme for children and adolescents. *Caries Res* 2005a; 39(6):455-67
  27. Braun A, Beisel C, Brede O, Krause F. Laser fluorescence of dentin caries covered with a novel nano-filled sealant. *Lasers Med Sci* 2013; 28:133-8