



Experimental gingivitis in patients with altered passive eruption: A case control study. Clinical and histological evaluation

Facoltà di Medicina e Odontoiatria

Dottorato di ricerca in tecnologie innovative nelle malattie dello scheletro, della cute e del distretto oro-cranio-facciale

Cattedra di Scienze Odontostomatologiche e Maxillo-Facciali

**Candidato: Rustam Aghazada
n° matricola: 1574966**

**Relatore
Prof. Andrea Pilloni**

A/A 2016/2017

Table of Contents

Background.....	3
Experimental gingivitis.....	10
Aim of the study.....	11
Material and methods.....	12
Statistical analysis.....	25
Results of histological analysis.....	35
Discussion.....	38
Conclusion.....	41
References.....	43

Background.

Frequently, short teeth are a common “chief complaint” expressed by patients dissatisfied with the appearance of their smile since the teeth are visually disproportionate in size. The diagnostic assessment of the smile is reflective of the amount of gingiva and tooth exposed during smiling¹. The appearance of short teeth can be due to excessive gingival display and/or a lack of incisal tooth display²

The position of the gingival margin is of clinical importance since it is not static. Almost more than a hundred years ago, Black³² reported that he had often observed that one half of the length of the crowns of permanent teeth were buried in the gingiva, even after these teeth were fully erupted¹². He noticed that, with age, the gingival margin shifts apically to show most of the crown of the tooth, until to a finally position which is very near the cemento-enamel junction – therefore an apical migration of the gingiva had occurred. Kronfeld³³ supported this viewpoint when he wrote that “the dental operator should always be aware of the fact that the level of the gingival margin, as he finds it in the patient’s mouth, is only temporary”. He believed that, with the course of time, a gradual physiological apical migration of the gingival margin was inevitable, which results in the larger tooth surface exposure to almost the cemento-enamel compound. While the movement of the gum occurs itself, the tooth eruption should also play a role in the physiological determination of the position of the gingival margin. It was Orban and Müller³⁴, who observed that the eruption of the tooth was not completed at the time when it came in occlusion with its antagonist, since at that time only 2/3 of the anatomical crown was clinically exposed. Gottlieb & Orban described two phases of tooth eruption. Active eruption they regarded as the actual movement of the tooth towards the occlusal line, a process, they said, that was accompanied by passive eruption, which was the movement of the gingival margin towards the tooth apex. Should the process of passive eruption be delayed or altered, one may anticipate that the gingiva would remain on the crown remote from the cemento-enamel junction. Gottlieb wrote that “eruption not only progresses by the operation of raising of the tooth from the alveolus, for at the gingival margin we can observe that the epithelial attachment, as well as the ligamentum circulare and the margin of the alveolus, are moving apically.

The lower part of the gingival trough passes beyond the amelo-cemental junction not only in different teeth of the same patient but also round the circumference of the same tooth at different points.” Volchansky et al¹². defined the clinical entity of altered passive eruption (APE) as “Altered passive eruption is present when a tooth has reached the occlusal plane and the gingival margin, in the mid-line of the tooth is at the junction between the cervical and middle third of the clinical crown or in the coronal third of the clinical crown in the absence of inflammation, hypertrophy or hyperplasia of the gingiva”¹².

Tooth eruption involves a complex series of events and has not yet been fully elucidated. According to the concept of continuous eruption³, eruption does not cease when teeth meet their functional antagonists but continues throughout life. Eruption consists of an active and a passive phase. Active eruption is the movement of the teeth in the direction of the occlusal plane, whereas passive eruption is the exposure of the teeth by apical migration of the gingiva. This concept distinguishes between the anatomic crown (portion of the tooth covered by enamel) and the anatomic root (portion of the tooth covered by cementum) and between the clinical crown (part of the tooth that has been denuded of its gingiva and projects into the oral cavity) and clinical root (portion of the tooth covered by periodontal tissues). When the teeth reach their functional antagonists, the gingival sulcus and junctional epithelium are still on the enamel, and the clinical crown is approximately two-thirds of the anatomic crown. Passive eruption is a process by which the epithelial attachment of the gingival tissue retracts from the enamel portion of the crown onto the root into adult position just apical to the CEJ allowing for a fibrous connective tissue attachment at the base of the sulcus (the biological width)^{2,4}

Historically passive eruption process has been divided (Fig.1) by Gottlieb and Orban³ in 4 stages:

Stage 1: The teeth reach the line of occlusion: the junctional epithelium and base of the gingival sulcus are on the enamel.

Stage 2: The junctional epithelium proliferates so that part is on the cementum and part is on the enamel: the base of the sulcus is still on the enamel.

Stage 3: The entire junctional epithelium is on the cementum and the base of the sulcus is at the cementoenamel junction. As the junctional epithelium proliferates

from the crown onto the root it does not remain at the cementoenamel junction any longer than at any other area of the tooth.

Stage 4: The junctional epithelium has proliferated farther on the cementum. The base of the sulcus is on the cementum, a portion of which is exposed. Proliferation of the junctional epithelium onto the root is accompanied by degeneration of gingival and periodontal ligament fibers and their detachment from the tooth.

Although originally thought to be a normal physiologic process, the 4th stage of passive eruption is now considered a pathologic process because it results with the formation of gingival recession.

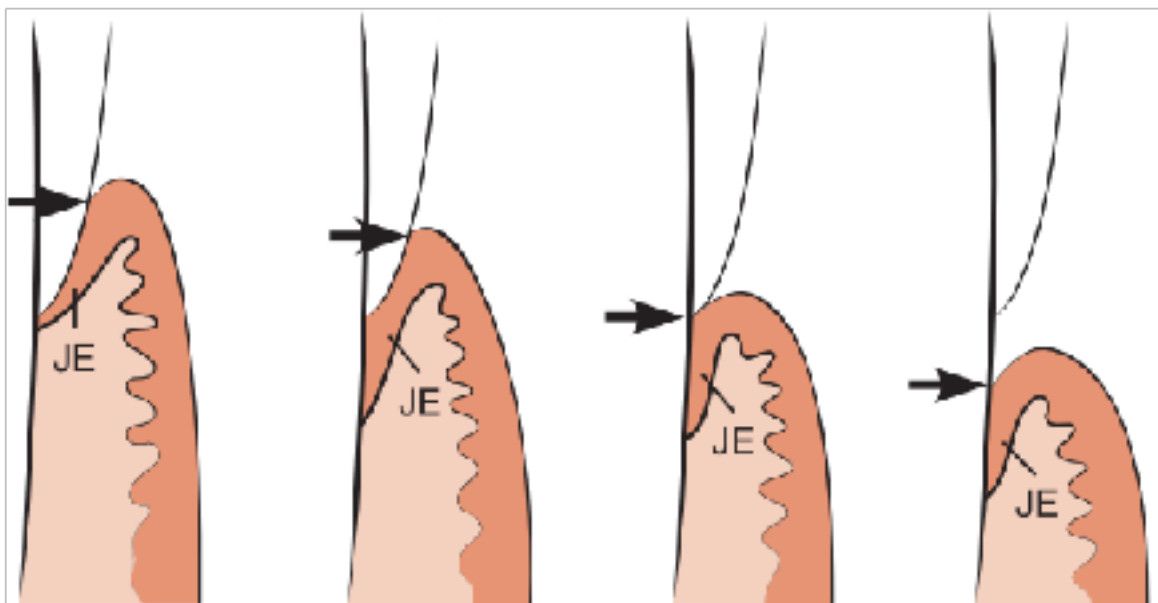


Fig.1 Diagrammatic representation of the four steps in passive eruption according to Gottlieb and Orban. (Figure from Carranza's Clinical Periodontology 11th edition, 2012, page 27, Elsevier Inc.)

The connective tissue attachment of the gingiva and the epithelial attachment are the part of the dentogingival junction which has been described as a functional unit by Gargiulo et al⁴. They reported that the connective tissue attachment varied in length from 0,0 to 6,84 mm with a mean of 1,07 mm; this measurement combined with the mean length of the epithelial attachment (0.97 mm) has been called the physiologic dentogingival junction^{3,4}.

The concept of a biologic width, as currently accepted 0.97 mm for the epithelial attachment and 1.07 mm for the connective tissue attachment, requires a minimum of 2,04 mm of sound tooth structure above the osseous crest^{4,5}.

Altered passive eruption (also known as retarded *passive eruption* or *delayed passive eruption*) occurs when the margin of gingiva is malpositioned incisally (occlusally) on the anatomic crown in adulthood and does not approximate the cemento-enamel junction⁷⁻⁹. The "normal" relation of the gingival margin to the CEJ is usually considered to be at or near the CEJ in the fully erupted teeth of adults¹⁰. The prevalence of APE in the adult population has been little studied to date, possibly because of the lack of clear diagnostic criteria. Based on a series of 1025 patients with a mean age of 24.2 ± 6.2 years, Volchansky and Cleaton-Jones¹² recorded a 12.1% incidence of APE.

The greatest clinical relevance of APE may be its aesthetic consequences. In fact, when APE affects the upper anterior teeth, it usually alters dentofacial harmony – the patient in person often taking the initiative to consult the dental professional because of the short and hidden appearance of his or her teeth.

In relation to smile aesthetics, a very important consideration is the relation of the gingival margins to the edge of the upper lip¹³⁻¹⁵. An analysis of the esthetic alterations produced by APE in the anterosuperior sextant reveals the influence of three factors:

- (a) The square appearance of the crowns. The gums positioned coronally over the tooth produce a square clinical crown silhouette, when the actual anatomical shape may be ovoid or elliptic, and thus aesthetically much more attractive.
- (b) On smiling, the gums are exposed by the upper lip. When such gum exposure exceeds 2-3 mm, it can produce a poor aesthetic effect known as gummy smile¹⁴.
- (c) Flattened gingival festooning. In APE, these three factors determine the so-called gummy smile, where in addition to producing excessive gingival exposure, the smile is globally lacking in expressivity¹⁶. (Fig.2)

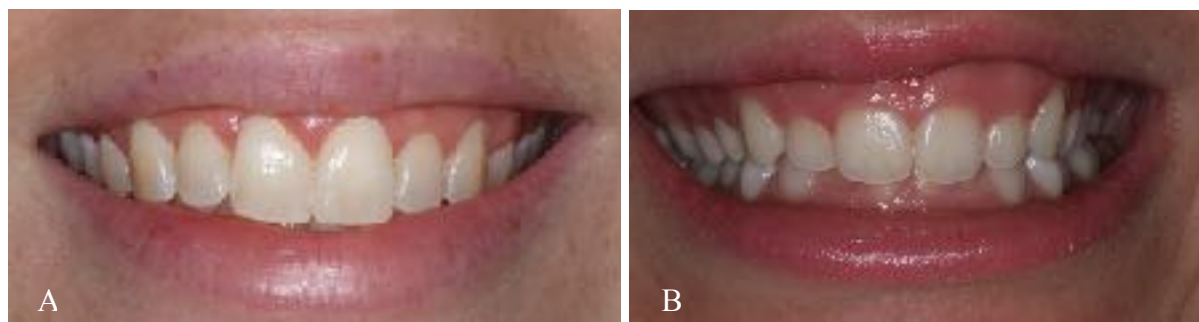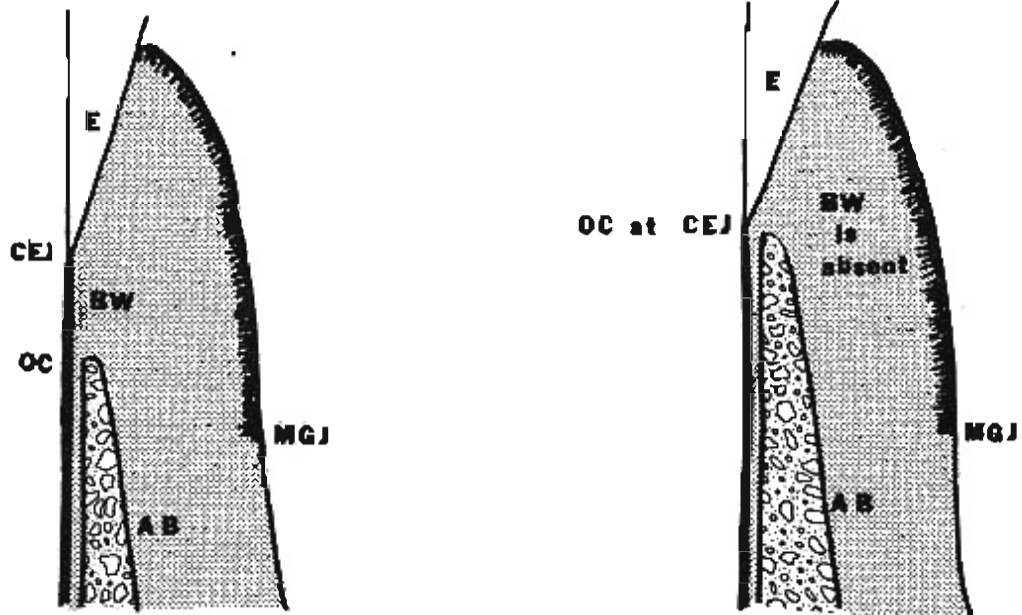


Fig.2. A – normal gingival anatomy, B – patient with altered passive eruption

TYPE 1: AN EXCESSIVE AMOUNT OF GINGIVA

A. NORMAL CREST-CEJ RELATIONSHIP

B. OSSEOUS CREST AT CEJ



TYPE 2: A NORMAL AMOUNT OF GINGIVA

A. NORMAL CREST-CEJ RELATIONSHIP

B. OSSEOUS CREST AT CEJ

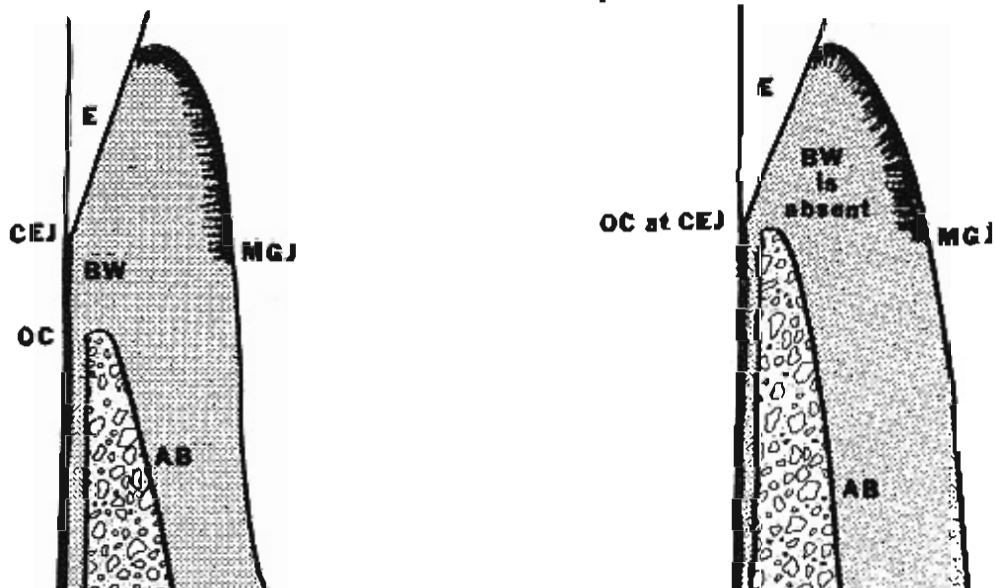


Fig. 3 Classification of APE. Coslet et al⁶

Coslet et al.⁶ classified cases (Fig.3) of altered passive eruption into two main types according to the relationship of the gingiva to the anatomic crown and then subdivided those classes according to the position of the osseous crest.

Type I is represented by the presence of the gingival margin incised or occlusal to the CEJ, where there is a noticeably wider band of gingiva from the gingival margin to the mucogingival junction. The mucogingival junction is usually apical to the alveolar crest in these cases. Type II is represented by a gingival dimension from the margin to the mucogingival junction that appears to fall within a normal width. In this

type, all of the gingiva is located on the anatomic crown, and the mucogingival junction is located at the level of the CEJ.

Both types I and II are then subdivided into IA, IB, IIA. and IIB. In the A subgroups, the alveolar crest-CEJ relationship corresponds to the 1.50 - to 2.0-mm distance accepted as normal. This distance allows for normal insertion of the gingival fiber apparatus into the cementum. In the B subgroups, the alveolar crest is at the level of the CEJ. This relationship, although uncommon in adults, is frequently observed during the transitional dentition that is undergoing active eruption¹¹.

There are several methods for diagnosis the altered passive eruption. Clinically, the most obvious sign of altered passive eruption is a short-looking tooth and excessive gingival display (EGD). Short teeth must be differentiate with teeth attrition. EGD can be associated with different causes. The decisional tree (Fig.4) made by Smidt et al¹⁹ can be useful in clinical diagnosis of APE

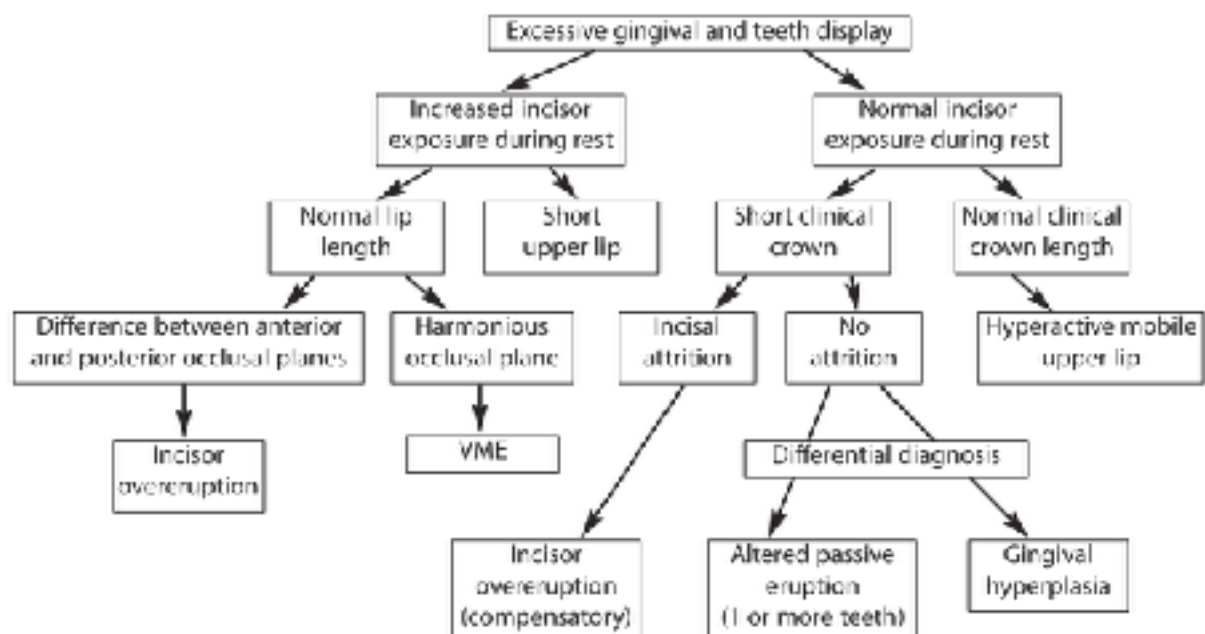


Fig. 4. Decisional tree for the clinical diagnosis of the excessive gingival display.

The most easy and repeatable method of APE diagnosis is intra-oral x-rays made by means of parallel ray technique with the Rinn's film holder. With the help of the

obtained radiographs it is possible to measure the length of the anatomical crown (the distance between incisal margin and CEJ) and compare it with the length of the clinical crown (the distance between incisal margin and the gingival margin). The difference between the two measurements correspond to the part of the crown that is excessively covered by the gingiva^{17,18}.

Alveolar bone sounding²¹ can be useful for determining sub-groups A and B. It should be performed only under local anaesthesia, which limits its use as a separate diagnostic method. Usually, bone sounding is used immediately before surgery. Bone sounding is not a reliable diagnostic method, because with its help, it is not always possible to determine the CEJ using a periodontal probe.²⁰

The aetiology of the altered passive eruption is still unclear. According to the study Rossi et al¹⁸ patients showing this condition might have one or more family members with the same clinical aspect. In the evaluated small group of 20 patients they have found that more than 50% of the patients had one family member showing the same clinical situation and 15% of the sample had all family members showing altered passive eruption.

The alveolar crest - CEJ distance reported by Gargiulo, Wentz and Orban⁴ in the normal periodontium is believed to be necessary for maintenance of gingival health. The absence of the normal alveolar crest - CEJ distance as described by these authors may account for the predisposition of many cases of delayed passive eruption in the adult to exhibit gingival pathology. There is usually a pseudopocket and lack of gingival tonus associated with gingival tissue high on the anatomic crown. These relationships are very significant as they relate to clinical dentistry⁶.

The significance of the alveolar crest - CEJ distance is related to the gingival fiber apparatus. Regarding Coslet et al, in either case, Type I or Type II, when the alveolar crest is located at the CEJ in the adult there is a lack of available cementum apical to the CEJ and coronal to the alveolar crest for the insertion of the collagen bundles of the gingival fiber apparatus. The organization of the fibers of the gingival corium differ from those described by Goldman in the normal periodontium.

The clinical significance of this alteration in the dentogingival junction cannot be completely assessed at this time; however, it may be related to the predisposition to gingival pathology. It certainly could be a significant relationship that could alter the wound healing of the dentogingival junction when delayed passive eruption cases are treated surgically⁶.

The literature discusses whether APE is a genuine risk to periodontal health, and points to difficulties in oral hygiene and a narrow connective tissue attachment as possible causes^{6,9}. Coslet⁶ indicated that APE 2A, 1B and especially 2B are risk situations for health, particularly before dental treatment - identifying a narrow band of gum and the absence of connective insertion to the root as risk factors. Volchansky and Cleaton-Jones¹² reported a statistically significant relationship between the presence of APE and acute necrotizing ulcerative gingivitis, arguing that a deep gingival sulcus creates the necessary anaerobic conditions for the development of this infection.

Other authors indicate that an excess of gum on the tooth impedes oral hygiene and can cause disease especially in individuals who already have a high predisposition to periodontitis. Dello Russo⁷ considers APE to be a clear risk situation for the periodontium in teeth that are going to be restored with total crowns or class II or III restorations. The author gives three reasons for this: the presence of a short clinical crown forces the clinician to make intrasulcular margin restorations; the difficulty of hygiene in this zone; and the absence of connective attachment to the radicular cement that can pose problems for the periodontal defences.

Experimental gingivitis.

Epidemiology and the natural history of gingivitis and periodontitis indicate that the inflammation of the gums is a indispensable component of periodontitis, and that gingivitis precedes the onset of periodontitis²⁴. However, it is also incontrovertible

that not all cases of gingivitis continue until the development of periodontitis. The reason for this is that a bacterial plaque is necessary but not sufficient for the development of periodontitis, a susceptible host is necessary. The fact that gingivitis is a very weak predictor of periodontitis in people under the age of 30 may also be due to the fact that gingivitis occurs just after a few days or weeks²⁵, after the onset plaque accumulation, while for the development of periodontitis, in most cases a much longer period is required (from several years to several decades). Currently there are no reliable means to predict susceptibility to periodontitis. However, according to the literature, susceptibility to periodontitis may be associated with susceptibility to gingivitis.

The experimental model of gingivitis, originally developed by Loe²⁰ and his colleagues as a tool for demonstrating relationships between bacterial plaque and gingivitis was repeatedly checked and widely used in the last years for the study of the pathogenesis of gingivitis and evaluation of therapeutic interventions²³.

The experimental model of gingivitis was widely tested in humans, non-human primates, and other mammals, has a well documented common qualitative and quantitative characteristics of expected response and provide invaluable historical control, and it is the only model of periodontal disease that is completely reversible, which excludes any constant damage to the participants²³.

Aim of the study.

Despite the fact that many authors^{6,7,9} suggest that the patients with altered passive eruption are more susceptible to gingivitis and periodontitis due to the excess of gingiva, which impedes the correct oral hygiene procedure, there is to-date no clinical study confirming this assumption. The aim of the present study is therefore to examine the onset, progress and the healing of experimental gingivitis in patients with altered passive eruption when compared to patients with normal gingival anatomy.

Material and Methods

Population

9 patients with altered passive eruption for the test group and 9 patients with normal anatomy of gingival tissues as a control group were selected for the study. The clinical parameters have been compared also intrapatiently, due to fact that the patient developed an experimental gingivitis only in one selected side(test) of maxillary arch, another side has been considered as a control.

Sample size

A two sided logrank test with an overall sample size of 18 subjects (9 in the control group and 9 in the test group) achieves 80 % power at a 0,05 significance level to detect a hazard ratio of 5 to develop gingivitis (primary outcome – Gingival Index (GI)) when the control group hazard rate is 1. The study lasts for 18 time periods of which subject accrual occurs in the first 12 time periods. The accrual pattern across time periods is uniform (all periods equal). The proportion dropping out of the control and test groups is 0,1.

Selection criteria

Inclusion:

age \geq 18 years;

probing depth \leq 3 mm;

Exclusion:

Smoking

Periodontitis

Systemic diseases that are a contraindication for periodontal surgery;
 Immunosuppressed or immunocompromised patients;
 Use of medications affecting periodontal status;
 Uncontrolled diabetes;
 Pregnancy or lactation;
 Addiction to alcohol or drugs;
 Psychiatric problems;
 Presence of any restorations on the examined quadrant
 Presence of periapical and endo-perio lesions
 Teeth with malposition and alteration in crown morphology
 Patients with an acute infection (abscess) in the site intended for treatment.

Study design

The present study is controlled, parallel-designed, experimental gingivitis clinical trial. After a period of professional hygiene, in each subject for three teeth of the same maxillary quadrant was prepared stent which impedes the normal oral hygiene procedure, and patient has been instructed to put it on during toothbrushing. After 21 days of oral hygiene withdrawal at the level of three teeth covered by stent, subjects were assigned to a self-performed oral hygiene regimen for 21 days by using powered toothbrush (Oral-B Pro 3000, Braun, Procter and Gamble, USA) and interdental brushes. The study design was approved by the local ethical committee and was found to conform to the requirements of the “Declaration of Helsinki” as




Fig.5 Trial workflow

originally adopted and subsequently revised. All participants provided written informed consent.

Tooth and site selection.

The following three maxillary teeth were used in each test and control quadrant: central incisor, lateral incisor, canine. For each tooth, parameters were evaluated on the buccal aspect. Plaque indices were evaluated also in palatal aspect.

Clinical parameters

The following clinical parameters were obtained in the order listed below from the selected test and control sites in T0, T1, T2, T3, T4, T5 and T6

- **Angulated bleeding score (AngBS)**²⁶ - Angulated bleeding score (AngBS), was introduced by Trombelli et al.²⁶, which is a modification of the angulated bleeding index as reported by van der Weijden²⁷. After lightly drying the gingiva with compressed air, a periodontal probe (PCP 15 UNC, Hu Friedy, Chicago, IL, USA) was held at an angle of approximately 60° to the longitudinal axis of the tooth and in contact with the sulcular gingival tissues. AngBS was scored as: 0: no bleeding; 1: bleeding upon probe stimulation; 2: spontaneous bleeding.
- **Gingival index (MGI)** according to Silness & Loe²⁹, but without probing component, due to not disturb plaque accumulation, was registered as:
 1. - Normal gingiva;
 2. - Mild inflammation – slight change in color and slight edema
 3. - Moderate inflammation – redness, edema and glazing,

4. - Severe inflammation – marked redness and edema, ulceration with tendency to spontaneous bleeding.
- **Plaque index (PLI)**, according to Silness & Loe²⁹ was scored as:
1. - No plaque ;
 2. - A film of plaque adhering to the free gingival margin and adjacent area of the tooth. The plaque may be seen in situ only after application of disclosing solution
 3. - Moderate accumulation of soft deposit s within the gingival pocket, or the tooth and gingival margin which can be seen with the naked eye.
 4. - Abundance of soft matter within the gingival pocket and/or on the tooth and gingival margin.
- **Quigley Hein Plaque Index³⁰ - QH** (Modified by Turesky et al³¹) was registered after using disclosing solution as:
- 0 - No plaque
 - 1 - Separate flecks of plaque at the cervical margin of the tooth
 - 2 - A thin continuous band of plaque (up to one mm) at the cervical margin of the tooth
 - 3 - A band of plaque wider than one mm but covering less than one-third of the crown of the tooth
 - 4 - Plaque covering at least one-third but less than two-thirds of the crown of the tooth
 - 5 - Plaque covering two-thirds or more of the crown of the tooth
- **Gingival crevicular fluid volume (GCF)**, collected as previously described²⁸ and measured according to Periotron 8.000 manufacturer's (OraFlow Inc., Plainview, NY, USA) instructions. The individual site was gently air dried in an apico-coronal direction without removal of any visible supragingival plaque. The area was

carefully isolated with cotton rolls, to avoid salivary contamination. A sterile paper strip (Periopaper; OraFlow Inc.) was introduced into the crevice until mild resistance was felt. Attention was paid to avoid any mechanical injury to marginal tissues. The strip was left in place for 5 s and immediately transferred, for volume determination, to the calibrated, chair-side located Periotron 8,000 (OraFlow Inc.). Paper strips contaminated by gingival bleeding during GCF determination were discarded and corresponding data were recorded as missing.

Pretrial preparation

To achieve optimum gingival health and to standardize gingival baseline conditions all subjects participated in a pretrial period (Fig. 5). On day 7, after professional scaling and polishing a powered toothbrush (Oral-B pro 3000, Braun, Procter and Gamble, USA), individually chosen interdental brush (Tepe, Sweden), and standard toothpaste (AZ – pro expert, Procter and Gamble, USA), along with oral hygiene instructions, were provided. Subjects were instructed to brush the teeth by using powered toothbrush.

Stent fabrication

Individual cast models were prepared on alginate impressions. A 2-mm thick film of technical wax was set on the supra gingival area at buccal and proximal surfaces of study teeth on test quadrant. This was done in order to eliminate stent contact with the cervical margin of the teeth, thus avoiding any disturbance to plaque accumulation and gingival condition during stent insertion/removal. The customized stents were then obtained by using 2 -mm thick base plate material and a single-

chambered vacuum machine. The stent was adapted and trimmed to fit the teeth (from central incisor to canine) only in the test quadrant, extending at least 4–5 mm apical to the gingival margin on both buccal and palatal aspects (Fig.6). The stents

were checked in the mouth and minor adjustments were performed chair side during pretrial visits. The stent were delivered at day 0. Subjects were instructed to wear the stent prior to the oral hygiene session throughout the experimental gingivitis period to prevent plaque removal during brushing of the remaining dentition.

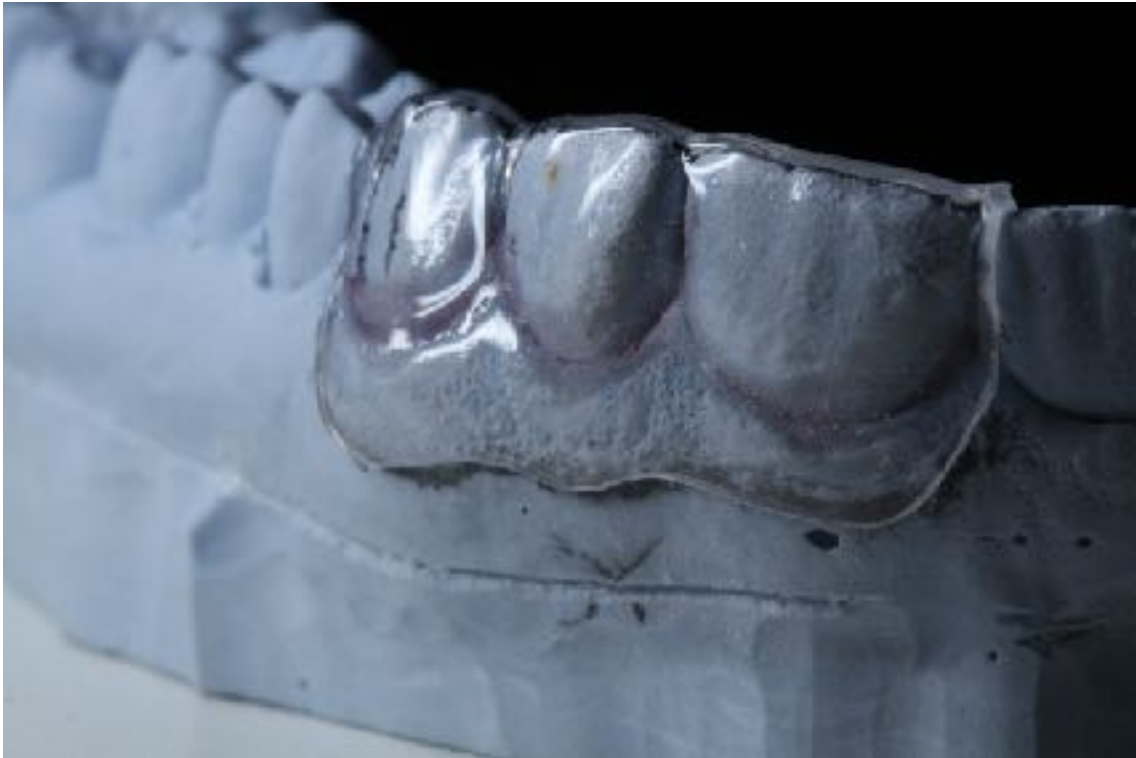

Fig. 6. Stent prior to delivery.

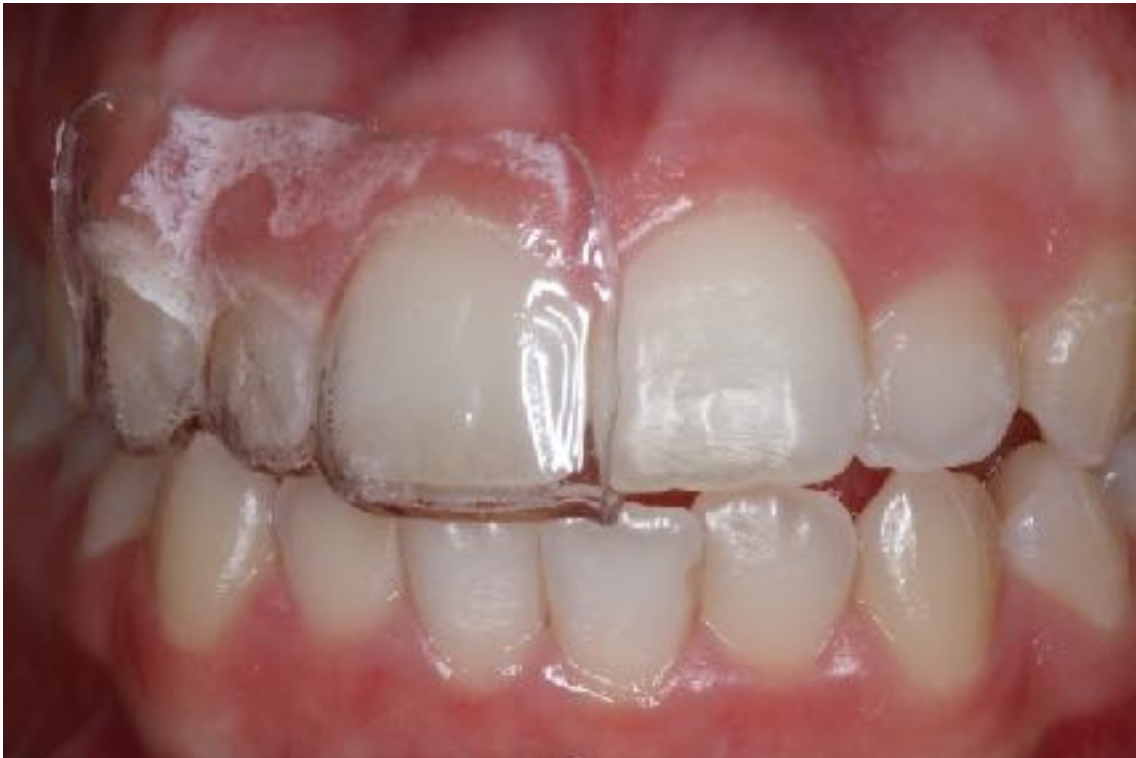

Fig. 7. Stent delivery

Procedures by visit

The procedures by visit are outlined in Fig. 5. Additional information/explanations for specific visits are given below:

Day 0 (T0): Presence of healthy gingival condition (i.e. GI = 0) in all sites of interest was verified. Clinical parameters were registered. All patients get stents, powered toothbrushes, toothpastes and interdental brushes.

Day 7 (T1): Control visit, and clinical parameters registering.

Day 14 (T2): Control visit, and clinical parameters registering.

Day 21 (T3): Clinical parameters registering. Subjects were asked to reinstitute the oral hygiene regimen (powered toothbrush, interdental brush) in the test quadrant. All subjects received the same treatment regimen for 21 days

Day 28 (T4): Control visit, and clinical parameters registering.

Day 35 (T5): Control visit, and clinical parameters registering.

Day 42 (T6): After recording of clinical parameters, oral hygiene instruction and an additional session of supragingival scaling, as needed, and polishing were given.

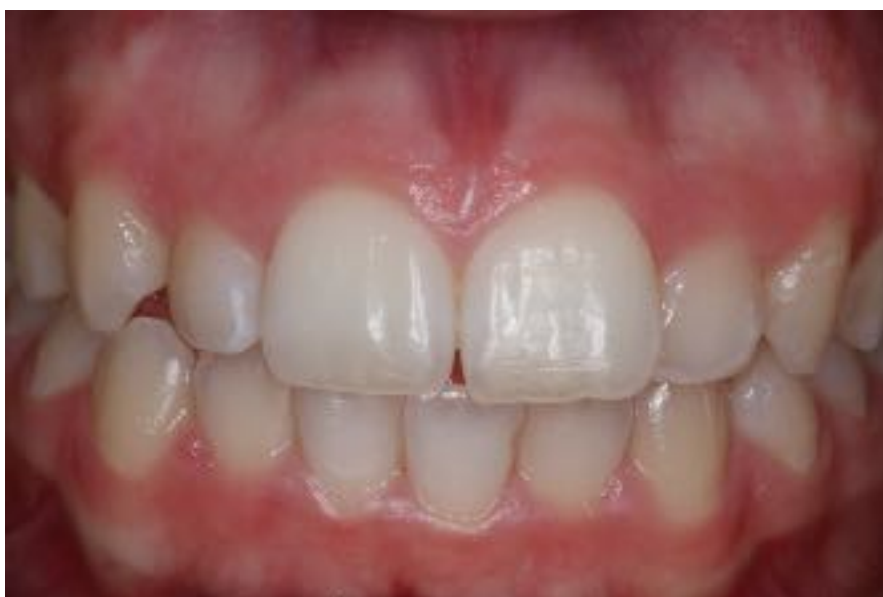

Fig. 8. Patient with APE at T0

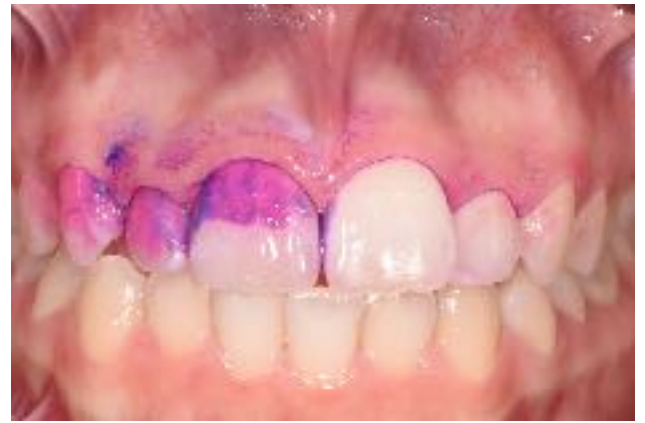
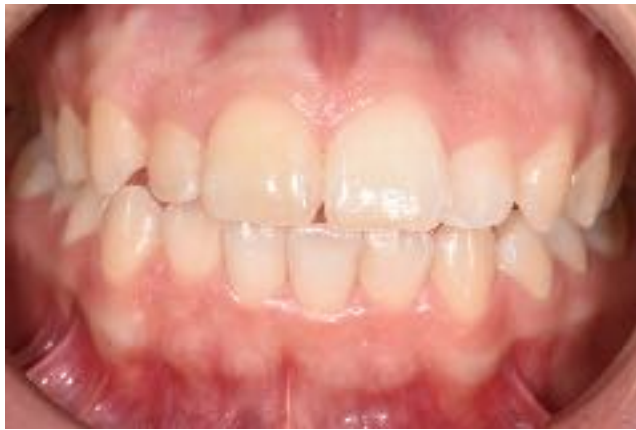
Fig. 9. Same patient at T3

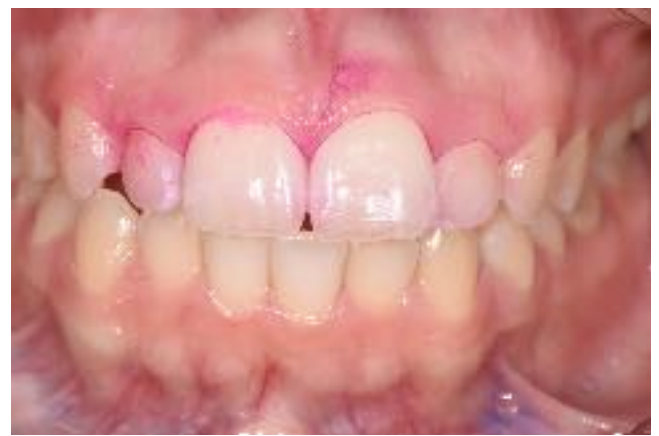
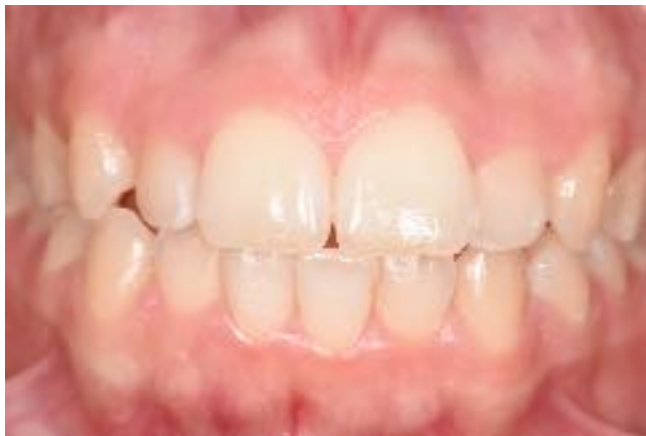
Fig. 10. Same patient at T6

After the end of the experimental gingivitis period, patients with APE were asked to perform a surgical correction of the gingival smile. Of the 9 patients participating in the experiment, only 5 were given consent for the proposed procedure. Due to the fact that the secondary flap that was removed during the surgery and had to be analyzed histologically, the information consent was prepared and signed by each participant. Histological examination was approved by the local ethical committee and was found to conform to the requirements of the “Declaration of Helsinki” as originally adopted and subsequently revised.

Treatment of choice for altered passive eruption²⁰.

Apically positioned flap with buccal osteoplasty is the treatment of altered passive eruption of type 1A and 2A. Ostectomy is performed only in the case of subclasses "B". The envelope flap is carried out without vertical release incisions. The extension of the flap in the mesio-distal direction depends on the number of dental elements involved and generally extended for one more mesial and distal tooth than those affected by the altered passive eruption; from canine to canine treatment the flap is extended to the first premolars. The design of the flap consists of a series of paramarginal, scalloped incisions (parabola incision) starting at the buccal aspect of the teeth, affected by altered passive eruption, are connected at the level of the papilla. The intersection of two buccal adjacent paramarginal incisions at the interdental area determines the design of the surgical papilla. The significance of incision has been overestimated in the past, so that it was considered as the key determinant factor of the future shape and size of the teeth. This has led to the fact that for years gingivectomy has been acknowledged as the treatment of choice of the altered passive eruption. In fact, the future shape and size of the teeth primarily depend on the topographic relationship between the bone crest and CEJ, as well as on the thickness of bone tissue, buccal and interproximal soft tissues. Performing of precise and correct incision serve to accelerate the clinical process of healing and, therefore, confer to the patient a good immediate postoperative aesthetics. Bacterial plaque control and brushing are facilitated in the first postsurgical stage.

To perform correctly the design of the flap incisions, both the position and the shape of the parabolas must be considered²⁰. Therefore, the height of the anatomical crown which can be measured on periodical radiographs must be taken into consideration:

The position of the incision parabola depends on:

The difference between the heights of clinical and anatomical crowns. The radiographic length of the crown measured as the linear distance (in millimeters) from the incisal margin to CEJ. Length of the clinical crown measured from the incisal margin to gingival margin with periodontal probe (PCP15-UNC). The difference between two measurements will determine the position of the incision (but only if it leave at least 2 mm of keratinized tissue on the buccal flap)

Height of the buccal keratinized tissue: the greater the height of the keratinized tissue

the more apical can be placed the paramarginal incision;

CEJ position/buccal bone crest: the more apical the CEJ/bone crest is located to the gingival margin, the more paramarginal can be the incision.

Canons of aesthetic dentistry, according to which the gingival margin of the lateral incisors are in a more coronal position than that of the canines and the central incisors.

The shape of the parabola incision depends on:

Position/course of the mucogingival line: the incision must leave in the buccal flap the same height of keratinized tissue on counter-lateral homologous teeth (central incisors, lateral incisors and canines).

Patient biotype: the more apical the CEJ/bone crest is positioned, the more cylindrical teeth has patient and the more scalloped can be the incision.

The incision design is performed with the scalpel perpendicular to the underlying planes, inserting the blade into the connective tissue without coming into contact without reaching the bone level. It results in a bleeding line that is used as a guide for both surgical papilla partial thickness incision and full thickness buccal incision.

The elevated flap has mixed thickness: partial at the level of the surgical papillae and total at the level of the vestibular portion of the parabola. The goal is to give an equal thickness to the entire flap. In order to reflect the surgical papillae in partial thickness, the scalpel blade should be maintained parallel to the outer mucous surface, while in the buccal portion of the parabola, under which the crown of the tooth is located, a sharp incision is performed with scalpel held perpendicular to the underlying planes. This will allow to obtain an adequate tissue thickness for use of the periosteal elevator during the detachment of the full-thickness buccal flap. The marginal buccal keratinized tissue is eliminated. The vestibular flap reflection terminates 3-5 mm apically to the buccal bone crest.

After the elevation of the flap the topographic relationship between the buccal bone crest and CEJ of the teeth is analyzed. If the bone ridge is at a distance of 1-2 mm from the CEJ, the altered passive eruption will belong to the subclass "A" and it is not necessary to perform buccal osteotomy. Sometimes few but not all teeth with passive

eruption have minimal (1 mm) biological space for the insertion of supracrestal connective fibers. In this case, buccal ostectomy will be limited to teeth without this space. The buccal ostectomy is performed after osteoplasty reduces the buccal and interproximal bone thickness.

Due to the fact that the relationship between CEJ and the buccal bone ridge of adjacent teeth is often different, gingivectomy can not be considered as the method of choice in the treatment of altered passive eruption. Presence of a thick buccal bone crest, particularly in the interdental area, is almost constantly appearing phenomenon. Inadequate osteoplasty may lead to a coronal regrowth of the soft tissue margin and thus to a partial recurrence of the altered passive eruption. The inability to perform osteoplasty is one of the main reasons why the gingivectomy is not indicated in the treatment of altered passive eruption. Osteoplasty is performed with mid to fine granule diamond burs. Ostectomy is performed with small bone chisels (PF 1, 2, 4) and intended to expose 1-2 mm of the root surface apically to the CEJ. At the buccal bone crest it is conferred to a course parallel to the CEJ. Since the root cement is the tissue on which the supracrestal connective fibers are inserted, the exposed root surface planning must not be performed. The flap is positioned 1mm coronally to the CEJ and stabilized with single interrupted sutures which anchors the surgical papillae to the interdental connective tissue.

Surgical procedure

Following the local anesthesia, a submarginal incision, approximately 0.5 mm coronal to the calculated CEJ level, will be performed at each treated tooth using a 15c blade. Only the buccal site will be involved in the surgical procedure. Maximum care will be exercised to preserve papilla. Then secondary flap will be removed with maximum care and will be placed in test-tubes with formalin, and will be sent to University of Rome «Tor Vergata» for histomorphometric study.

A full thickness flap will be then elevated using elevator. Intrasurgical measurement of the distance between bone crest and CEJ will be then performed. When the distance will be <1 mm, a gentle osseous resection will be accomplished to create a scalloped bone profile with at least 2mm of distance to the CEJ. Osteoplasty will be

performed when necessary. Then flap will be then sutured at the preestablished level, slightly coronal to the CEJ level, to obtain a primary closure using of interrupted non-resorbable sutures.

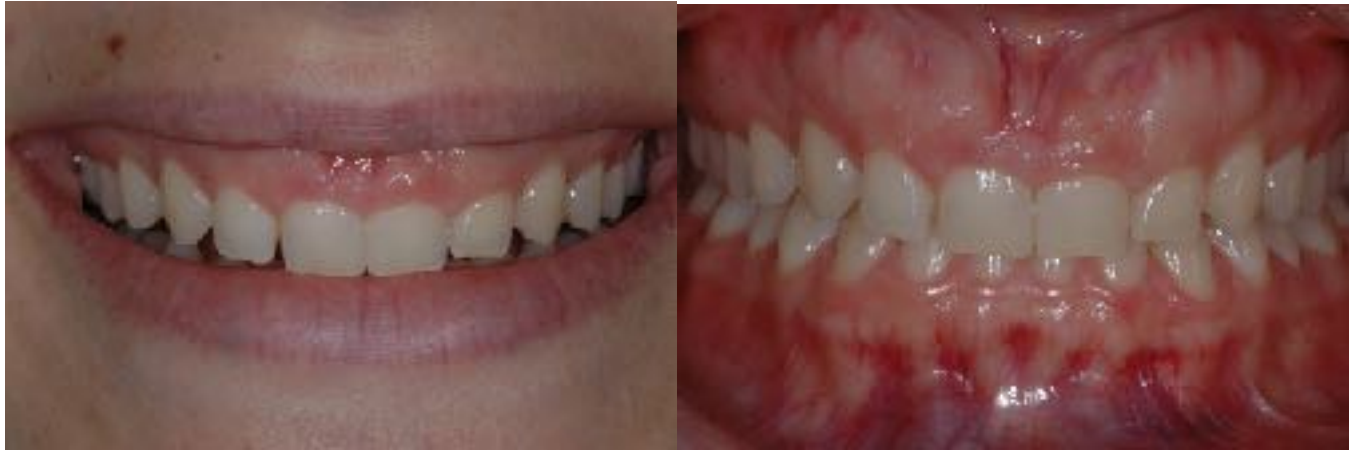

Fig. 11. Altered passive eruption.

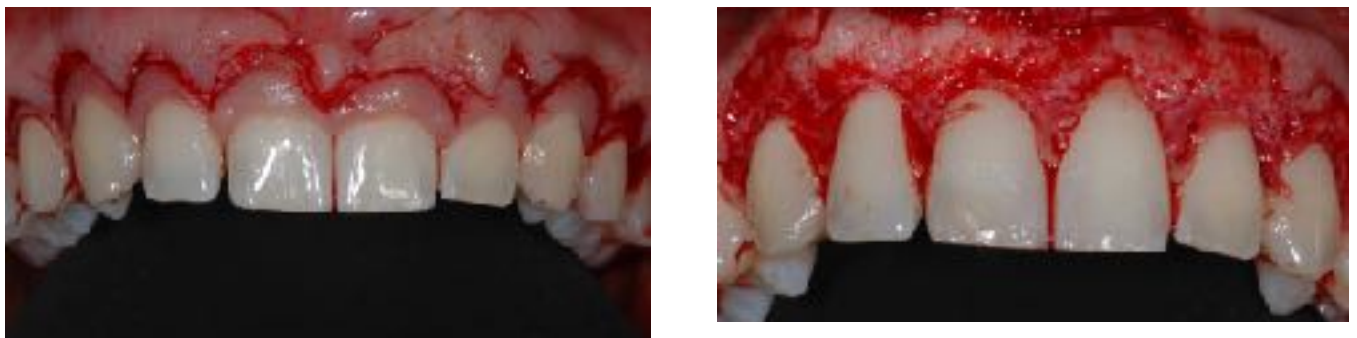


Fig 12. A – paramarginal incision. B – flap elevation. Note the absence of biological width. Only 2.1 presents little root surface exposure under the CEJ.

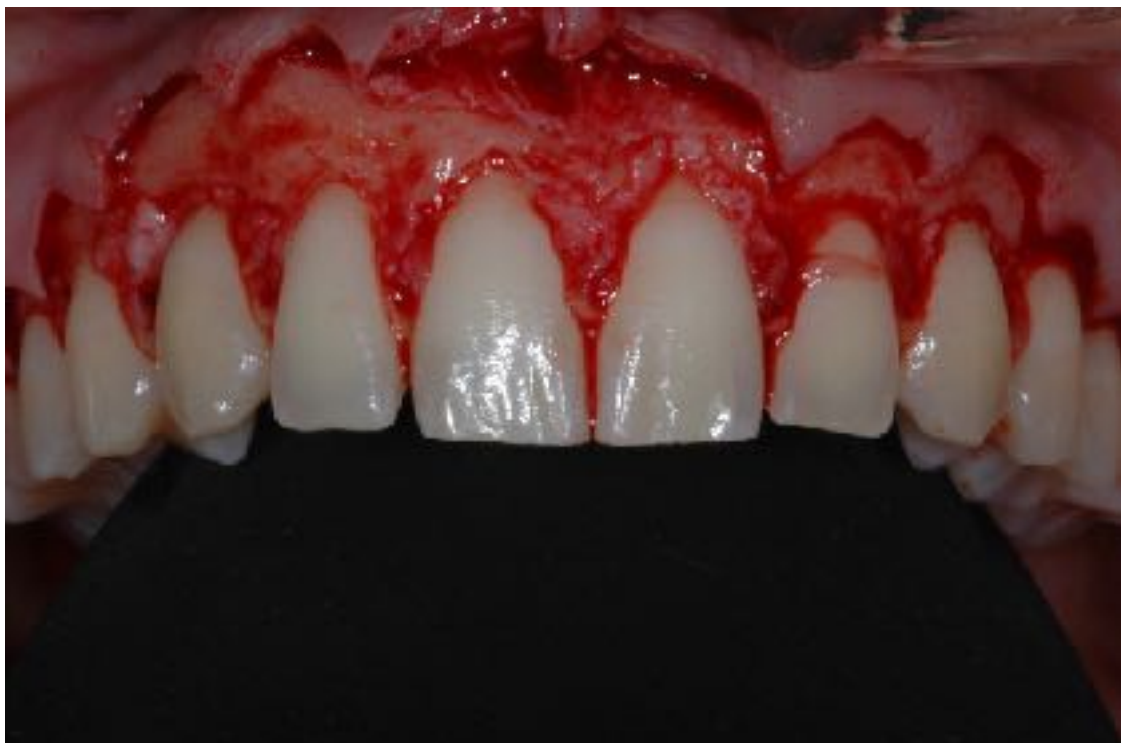

Fig 13. Ostectomy and osteoplasty was performed.

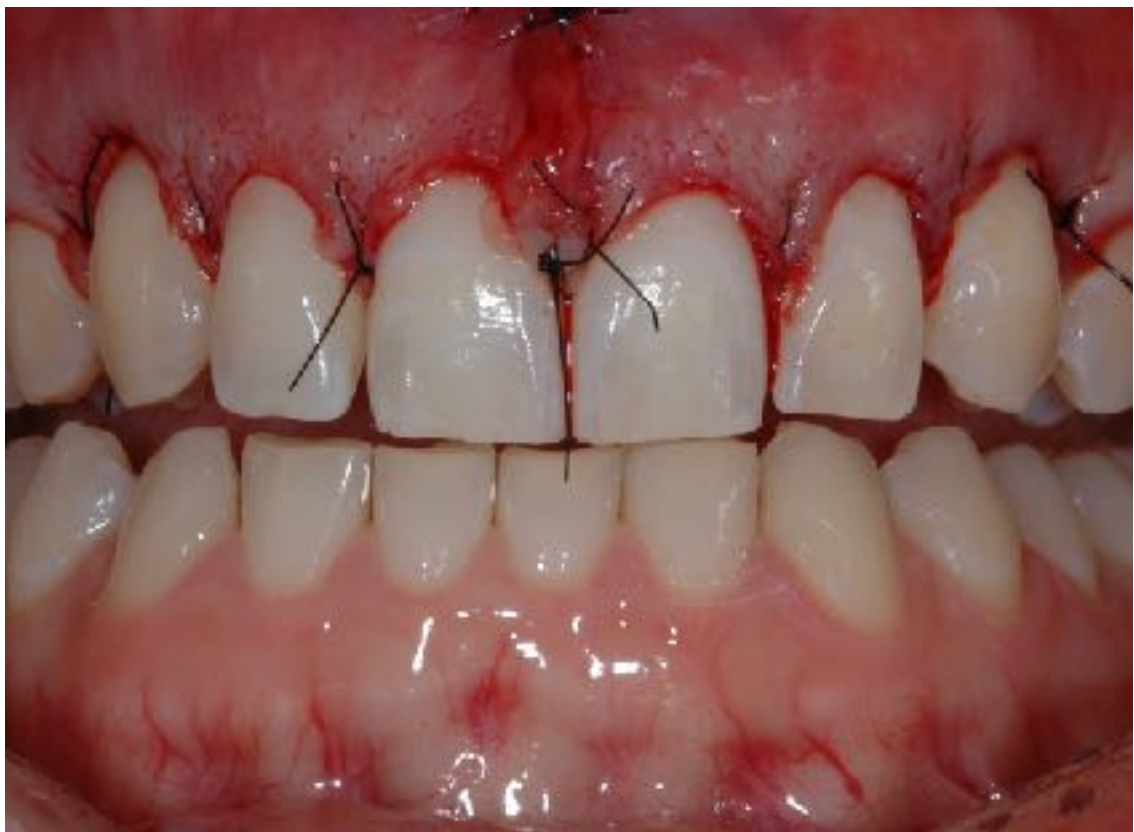

Fig 14. Flap sutured

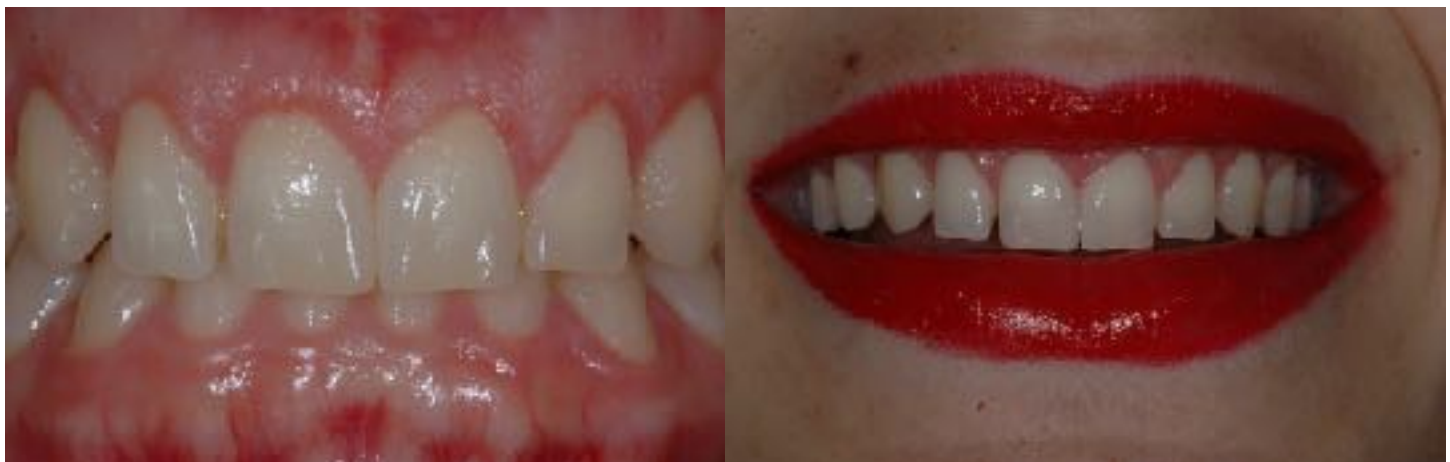

Fig 15. Final esthetic result

Postoperative Regimen

Patients will receive 0.12% chlorhexidine mouthrinses, twice a day for 2 weeks. Ibuprofen 400 mg 2-4 times per day will be prescribed, but patients will be instructed not to take it in absence of pain. Mechanical tooth cleaning will not be allowed in the surgical area for the first 6 postoperative weeks. Sutures will be removed at least 7

days following surgery. Patients will be then placed on monthly recall visits, during the first 6 months, and every 3 months thereafter.

Histological samples acquisition

The tissue samples were fixed in 10% neutral buffered formalin for 24 h and then were oriented in order to correctly identify the sulcus and sectioned perpendicularly to longitudinal diameter by 2 mm cuts. The biopsies were sampled *in toto* in two histological biocassettes: in the first was put the representative sample of the gingival margin of the side that was subjected to experimental gingivitis (3 samples – 1 sample for tooth) and in the second the side without any past experiments (3 samples – 1 sample for tooth). Finally, they were embedded in paraffin wax. 4 µm serial sections were cut at different levels and stained with haematoxylin and eosin from each block. The slices were examined with Nikon Eclipse E1200 light microscopy and pictures taken by Nikon camera system.

Statistical analysis

The subject was regarded as the statistical unit. For each clinical parameter at each observational period the side with experimental gingivitis (side A) of the subjects with APE and of the subjects with normal gingival anatomy was represented respectively as a test and a control group. Therefore, additional statistical analysis was conducted on the side without gingivitis (side B) between the patients with APE and without APE.

APE group

	Mean	Median	Moda	Standard deviation	Minimum	Maximum	Percentiles	
							25	75
PLIAT0	0,00	0,00	0	0,00	0	0	0,00	0,00
PLIBT0	0,00	0,00	0	0,00	0	0	0,00	0,00
PLIAT1	1,22	1,00	1	0,44	1	2	1,00	1,50

PLIBT1	0,22	0,00	0	0,44	0	1	0,00	0,50
PLIAT2	2,11	2,00	2	0,60	1	3	2,00	2,50
PLIBT2	0,22	0,00	0	0,44	0	1	0,00	0,50
PLIAT3	2,33	2,00	2	0,50	2	3	2,00	3,00
PLIBT3	0,22	0,00	0	0,44	0	1	0,00	0,50
PLIAT4	0,78	1,00	1	0,44	0	1	0,50	1,00
PLIBT4	0,11	0,00	0	0,33	0	1	0,00	0,00
PLIAT5	0,67	1,00	0 ^b	0,71	0	2	0,00	1,00
PLIBT5	0,11	0,00	0	0,33	0	1	0,00	0,00
PLIAT6	0,56	1,00	1	0,53	0	1	0,00	1,00
PLIBT6	0,11	0,00	0	0,33	0	1	0,00	0,00
QHAT0	0,00	0,00	0	0,00	0	0	0,00	0,00
QHBT0	0,00	0,00	0	0,00	0	0	0,00	0,00
QHAT1	3,00	3,00	3	0,71	2	4	2,50	3,50
QHBT1	0,89	0,00	0	1,45	0	4	0,00	2,00
QHAT2	4,22	4,00	5	0,83	3	5	3,50	5,00
QHBT2	0,22	0,00	0	0,44	0	1	0,00	0,50
QHAT3	4,67	5,00	5	0,50	4	5	4,00	5,00
QHBT3	0,11	0,00	0	0,33	0	1	0,00	0,00
QHAT4	1,56	1,00	0 ^b	1,67	0	4	0,00	3,50
QHBT4	0,11	0,00	0	0,33	0	1	0,00	0,00
QHAT5	1,22	1,00	0	1,72	0	5	0,00	2,00
QHBT5	0,11	0,00	0	0,33	0	1	0,00	0,00
QHAT6	1,22	1,00	0	1,64	0	4	0,00	2,50
QHBT6	0,11	0,00	0	0,33	0	1	0,00	0,00
AngBSAT0	0,00	0,00	0	0,00	0	0	0,00	0,00
AngBSBT0	0,00	0,00	0	0,00	0	0	0,00	0,00
AngBSAT1	0,78	1,00	1	0,67	0	2	0,00	1,00
AngBSBT1	0,11	0,00	0	0,33	0	1	0,00	0,00
AngBSAT2	1,22	1,00	1	0,67	0	2	1,00	2,00
AngBSBT2	0,00	0,00	0	0,00	0	0	0,00	0,00
AngBSAT3	1,78	2,00	2	0,44	1	2	1,50	2,00

AngBSBT3	0,00	0,00	0	0,00	0	0	0,00	0,00
AngBSAT4	0,67	1,00	0 ^b	0,71	0	2	0,00	1,00
AngBSBT4	0,00	0,00	0	0,00	0	0	0,00	0,00
AngBSAT5	0,44	0,00	0	0,53	0	1	0,00	1,00
AngBSBT5	0,00	0,00	0	0,00	0	0	0,00	0,00
AngBSAT6	0,33	0,00	0	0,50	0	1	0,00	1,00
AngBSBT6	0,00	0,00	0	0,00	0	0	0,00	0,00
MGIAT0	0,00	0,00	0	0,00	0	0	0,00	0,00
MGIBT0	0,00	0,00	0	0,00	0	0	0,00	0,00
MGIAT1	1,00	1,00	1	0,50	0	2	1,00	1,00
MGIBT1	0,22	0,00	0	0,67	0	2	0,00	0,00
MGIAT2	1,89	2,00	2 ^b	1,05	0	3	1,00	3,00
MGIBT2	0,00	0,00	0	0,00	0	0	0,00	0,00
MGIAT3	2,78	3,00	3	0,44	2	3	2,50	3,00
MGIBT3	0,00	0,00	0	0,00	0	0	0,00	0,00
MGIAT4	1,22	1,00	1	0,83	0	3	1,00	1,50
MGIBT4	0,00	0,00	0	0,00	0	0	0,00	0,00
MGIAT5	1,11	1,00	1	0,601	0	2	1,00	1,50
MGIBT5	0,00	0,00	0	0,00	0	0	0,00	0,00
MGIAT6	0,67	1,00	0 ^b	0,71	0	2	0,00	1,00
MGIBT6	0,00	0,00	0	0,00	0	0	0,00	0,00
GCFAT0	0,10	0,08	,06 ^b	0,04	0,06	0,18	0,06	0,13
GCFBT0	0,11	0,09	0,06	0,06	0,04	0,20	0,06	0,17
GCFAT1	0,18	0,19	,09 ^b	0,06	0,09	0,26	0,13	0,22
GCFBT1	0,13	0,13	,07 ^b	0,05	0,07	0,25	0,09	0,16
GCFAT2	0,28	0,23	,13 ^b	0,19	0,13	0,78	0,20	0,27
GCFBT2	0,16	0,14	,07 ^b	0,07	0,07	0,28	0,11	0,21
GCFAT3	0,33	0,25	,20 ^b	0,17	0,20	0,69	0,21	0,47
GCFBT3	0,14	0,13	,06 ^b	0,07	0,06	0,25	0,08	0,21
GCFAT4	0,21	0,09	,05 ^b	0,23	0,05	0,70	0,06	0,34
GCFBT4	0,12	0,07	0,07	0,10	0,05	0,31	0,05	0,20
GCFAT5	0,15	0,13	,07 ^b	0,13	0,07	0,49	0,08	0,15

GCFBT5	0,12	0,10	,06 ^b	0,06	0,06	0,25	0,08	0,15
GCFAT6	0,11	0,09	,04 ^b	0,07	0,04	0,26	0,07	0,14
GCFBT6	0,12	0,14	,06 ^b	0,05	0,06	0,18	0,07	0,16

No APE group

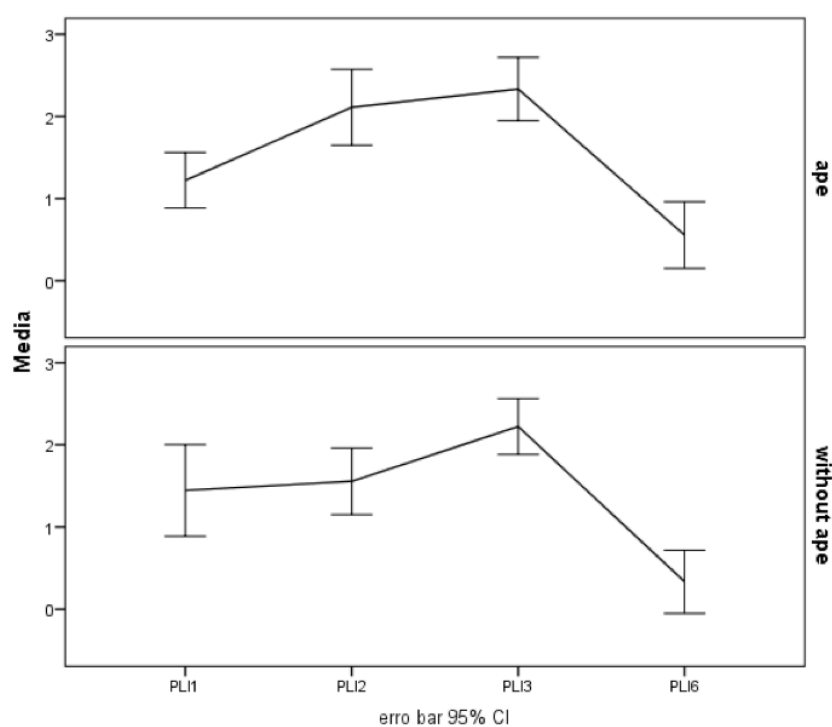
	Mean	Median	Moda	Standard deviation	Minimum	Maximum	Percentiles	
							25	75
PLIAT0	0,00	0,00	0	0,00	0	0	0,00	0,00
PLIBT0	0,00	0,00	0	0,00	0	0	0,00	0,00
PLIAT1	1,44	1,00	1	0,73	1	3	1,00	2,00
PLIBT1	0,00	0,00	0	0,00	0	0	0,00	0,00
PLIAT2	1,56	2,00	2	0,53	1	2	1,00	2,00
PLIBT2	0,11	0,00	0	0,33	0	1	0,00	0,00
PLIAT3	2,22	2,00	2	0,44	2	3	2,00	2,50
PLIBT3	0,11	0,00	0	0,33	0	1	0,00	0,00
PLIAT4	0,78	1,00	1	0,44	0	1	0,50	1,00
PLIBT4	0,00	0,00	0	0,00	0	0	0,00	0,00
PLIAT5	0,56	1,00	1	0,53	0	1	0,00	1,00
PLIBT5	0,22	0,00	0	0,44	0	1	0,00	0,50
PLIAT6	0,33	0,00	0	0,50	0	1	0,00	1,00
PLIBT6	0,00	0,00	0	0,00	0	0	0,00	0,00
QHAT0	0,00	0,00	0	0,00	0	0	0,00	0,00
QHBT0	0,00	0,00	0	0,00	0	0	0,00	0,00
QHAT1	3,44	4,00	4	1,01	2	5	2,50	4,00
QHBT1	0,00	0,00	0	0,00	0	0	0,00	0,00
QHAT2	4,67	5,00	5	0,71	3	5	4,50	5,00
QHBT2	0,11	0,00	0	0,33	0	1	0,00	0,00
QHAT3	4,89	5,00	5	0,33	4	5	5,00	5,00
QHBT3	0,11	0,00	0	0,33	0	1	0,00	0,00
QHAT4	1,22	1,00	1	0,97	0	3	0,50	2,00
QHBT4	0,00	0,00	0	0,00	0	0	0,00	0,00

QHAT5	1,00	1,00	0	1,32	0	4	0,00	1,50
QHBT5	0,33	0,00	0	0,71	0	2	0,00	0,50
QHAT6	0,56	0,00	0	1,33	0	4	0,00	0,50
QHBT6	0,00	0,00	0	0,00	0	0	0,00	0,00
AngBSAT0	0,00	0,00	0	0,00	0	0	0,00	0,00
AngBSBT0	0,00	0,00	0	0,00	0	0	0,00	0,00
AngBSAT1	0,11	0,00	0	0,33	0	1	0,00	0,00
AngBSBT1	0,00	0,00	0	0,00	0	0	0,00	0,00
AngBSAT2	0,22	0,00	0	0,44	0	1	0,00	0,50
AngBSBT2	0,00	0,00	0	0,00	0	0	0,00	0,00
AngBSAT3	0,67	1,00	1	0,50	0	1	0,00	1,00
AngBSBT3	0,00	0,00	0	0,00	0	0	0,00	0,00
AngBSAT4	0,11	0,00	0	0,33	0	1	0,00	0,00
AngBSBT4	0,00	0,00	0	0,00	0	0	0,00	0,00
AngBSAT5	0,11	0,00	0	0,33	0	1	0,00	0,00
AngBSBT5	0,00	0,00	0	0,00	0	0	0,00	0,00
AngBSAT6	0,00	0,00	0	0,00	0	0	0,00	0,00
AngBSBT6	0,00	0,00	0	0,00	0	0	0,00	0,00
MGIAT0	0,00	0,00	0	0,00	0	0	0,00	0,00
MGIBT0	0,00	0,00	0	0,00	0	0	0,00	0,00
MGIAT1	0,78	1,00	1	0,44	0	1	0,50	1,00
MGIBT1	0,00	0,00	0	0,00	0	0	0,00	0,00
MGIAT2	0,89	1,00	1	0,33	0	1	1,00	1,00
MGIBT2	0,00	0,00	0	0,00	0	0	0,00	0,00
MGIAT3	1,33	1,00	1	0,50	1	2	1,00	2,00
MGIBT3	0,00	0,00	0	0,00	0	0	0,00	0,00
MGIAT4	0,11	0,00	0	0,33	0	1	0,00	0,00
MGIBT4	0,00	0,00	0	0,00	0	0	0,00	0,00
MGIAT5	0,11	0,00	0	0,33	0	1	0,00	0,00
MGIBT5	0,00	0,00	0	0,00	0	0	0,00	0,00
MGIAT6	0,00	0,00	0	0,00	0	0	0,00	0,00
MGIBT6	0,00	0,00	0	0,00	0	0	0,00	0,00

GCFAT0	0,11	0,12	,05 ^b	0,03	0,05	0,14	0,09	0,13
GCFBT0	0,11	0,10	0,12	0,03	0,07	0,15	0,07	0,13
GCFAT1	0,19	0,19	,12 ^b	0,05	0,12	0,30	0,15	0,22
GCFBT1	0,11	0,10	0,13	0,03	0,08	0,16	0,09	0,13
GCFAT2	0,18	0,18	0,19	0,06	0,09	0,28	0,14	0,22
GCFBT2	0,10	0,11	,02 ^b	0,05	0,02	0,15	0,05	0,14
GCFAT3	0,22	0,23	,15 ^b	0,04	0,15	0,30	0,17	0,24
GCFBT3	0,10	0,08	0,07	0,04	0,05	0,18	0,07	0,13
GCFAT4	0,13	0,12	,07 ^b	0,05	0,07	0,22	0,09	0,19
GCFBT4	0,11	0,12	,08 ^b	0,03	0,08	0,17	0,09	0,13
GCFAT5	0,08	0,07	,04 ^b	0,03	0,04	0,13	0,06	0,10
GCFBT5	0,07	0,07	,03 ^b	0,04	0,03	0,15	0,03	0,10
GCFAT6	0,08	0,08	,04 ^b	0,04	0,04	0,15	0,05	0,11
GCFBT6	0,08	0,06	,03 ^b	0,05	0,03	0,16	0,04	0,12

Plaque accumulation

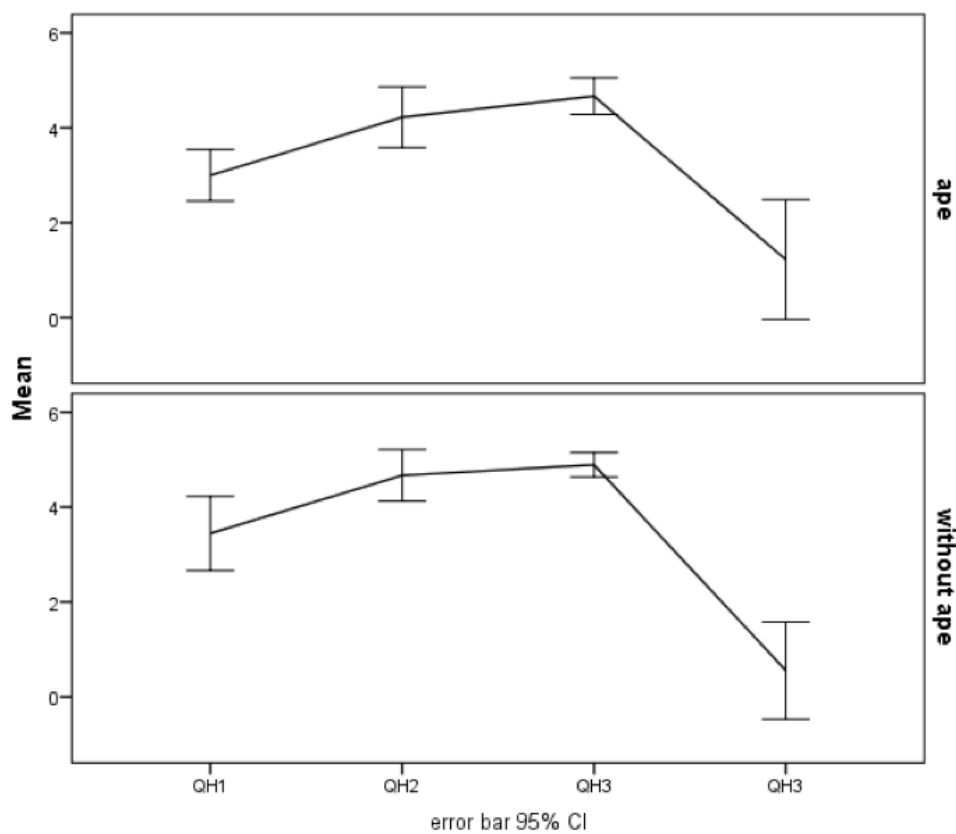
There is no difference between two groups on plaque accumulation in T1 and T6 (p=0.436). On day 7 (T1), PLI was 1.22 ± 0.44 in test and 1.44 ± 0.73 in control



Graphic 1. Plaque index in two groups

groups ($p=0.666$). On day 21 (T3) PLI was 2.33 ± 0.50 in test and 2.22 ± 0.44 in control groups ($p=0.113$). On day 42 (T6) values of PLI were similar to day 0 (T0) 0.56 ± 0.53 in test and 0.33 ± 0.50 in control groups.

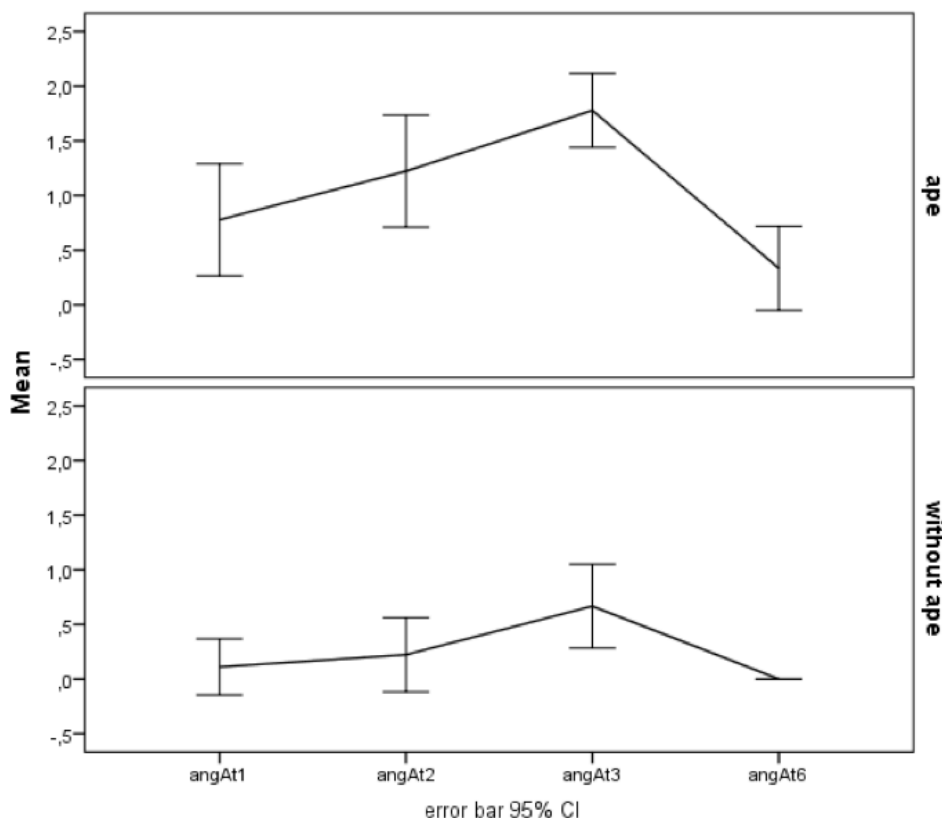
Although, there was no difference between two groups in QH plaque index in T1 and T6 ($p=0.258$). On day 7 (T1) QH was 3 ± 0.71 in test and 3.44 ± 1.01 in control groups ($p=0.340$). On day 21 (T3) QH was 4.67 ± 0.50 in test and 4.89 ± 0.33 in control groups ($p=0.436$). On day 42 (T6) QH was 1.22 ± 1.64 in test and 0.56 ± 1.33 in control groups ($p=0.258$)



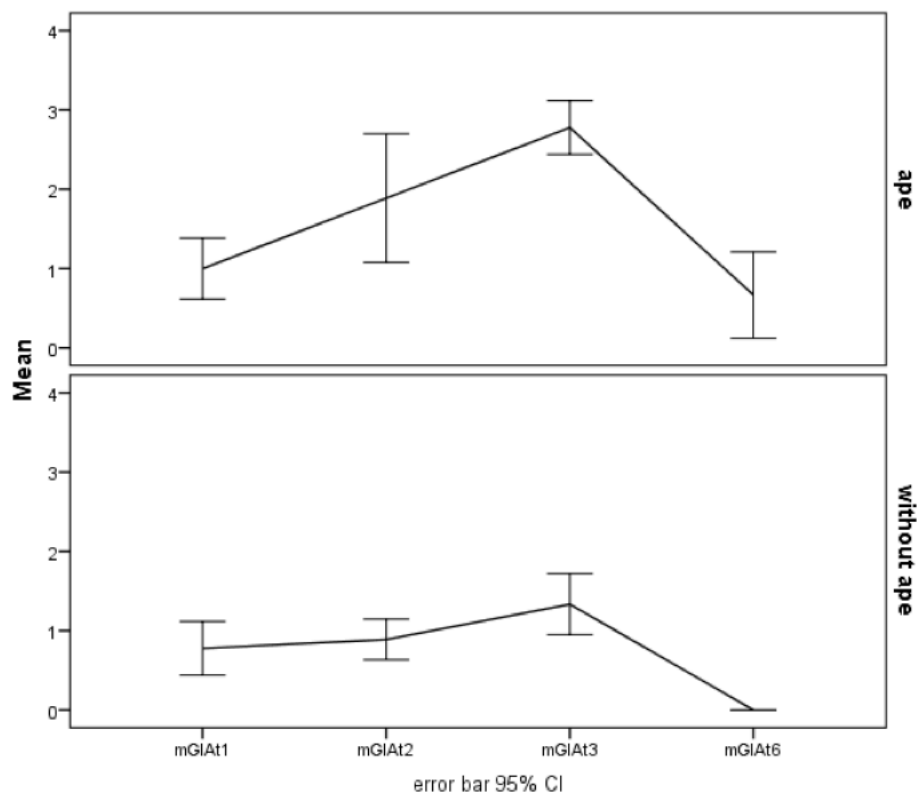
Graphic 2. QH plaque index in two groups

Gingival inflammation

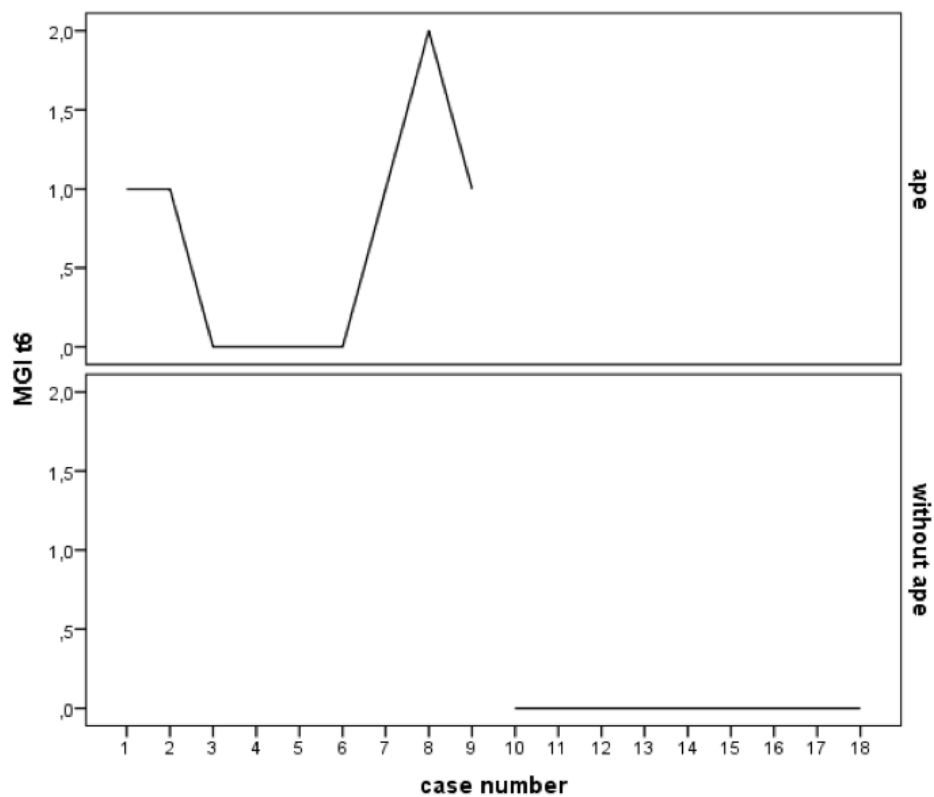
On day 7 (T1), all clinical parameters related to gingival status were similarly low in both test and control groups. AngBS on day 7 was 0.78 ± 0.67 in test and 0.11 ± 0.33 ($p=0.05$); and MGI in the same period was 1 ± 0.50 in test and 0.78 ± 0.44 in control groups ($p=1.00$). On day 21 (T3), at the time of maximum amount of plaque accumulation, there was a statistically significant difference between two groups in the gingival inflammatory indices. Thus, AngBS on day 21 (T3) was 1.78 ± 0.44 in test and 0.67 ± 0.50 in control groups ($p=0.002$); and MGI was 2.78 ± 0.44 in test and 1.33 ± 0.50 in control groups ($p=0.002$). At the end (T6) of experimental gingivitis, the difference in the inflammatory indices was insignificant, but despite this, some patents in the test group still had signs of gingivitis, while the patients from control group were completely healthy related to gingival status (graphic 5). So on day 42 (T6) AngBS was 0.33 ± 0.50 in test and 0 in control groups ($p=0.206$); and MGI was 0.67 ± 0.71 in test and 0 in control groups ($p=0.029$).



Graphic 3. Noted the difference of the AngBS between the groups on T3.



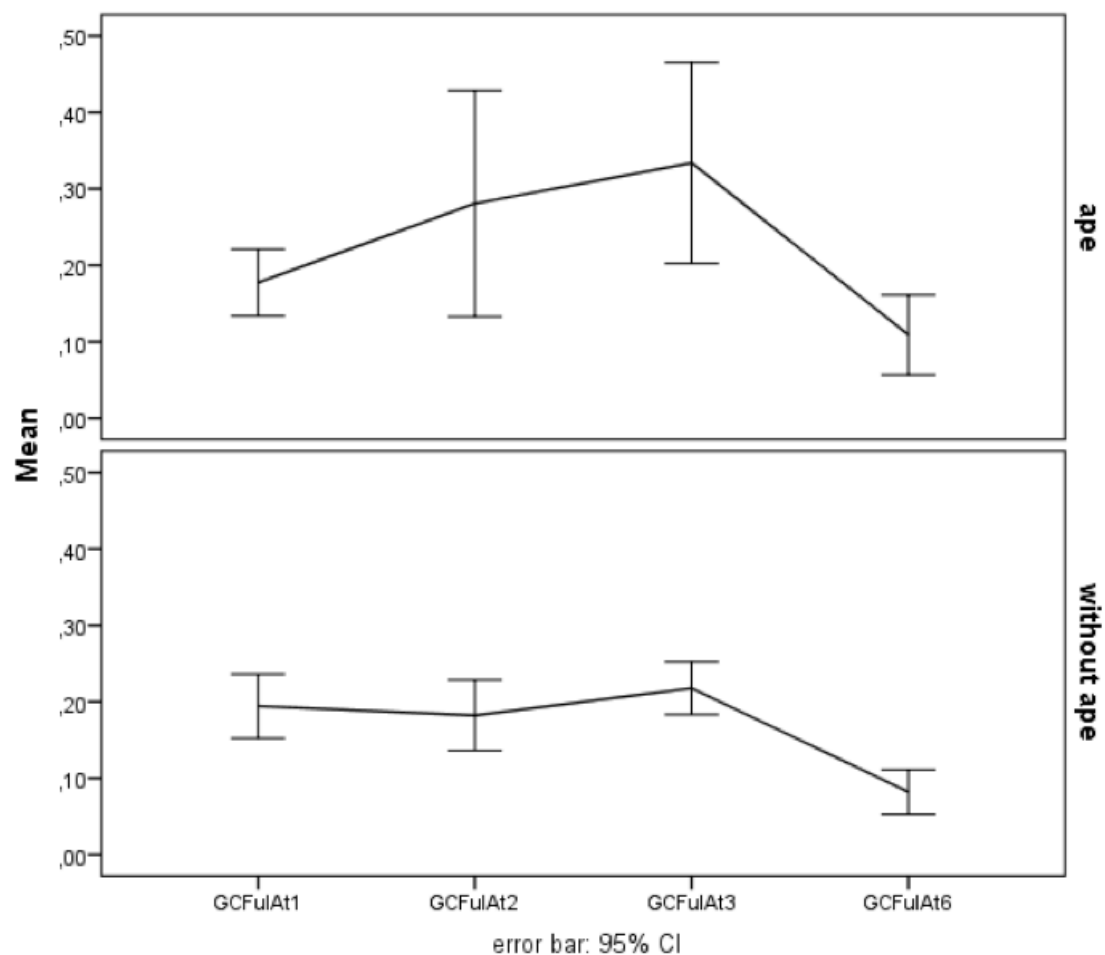
Graphic. 4. The difference between the groups MGI on T3



Graphic. 5. On T6 all the patients of control group not presenting an inflammation. Despite this some patients from control group are still had sign of gingivitis

Gingival crevicular fluid (μl)

GCF between 7 (T1) and 21 days (T3) varied from 0.18 ± 0.06 to 0.33 in test group and from 0.19 ± 0.05 to 0.22 ± 0.04 in control group. At the peak of the plaque accumulation and inflammation (T3) the difference between the two groups were not statistically significant. ($p=0.057$). At the end of the study values return to similar values in both groups. Thus, on day 42 (T6) GCF was 0.11 ± 0.07 in test and 0.08 ± 0.04 in control group, which was similar to values on day 0 (T0) 0.10 ± 0.06 and 0.11 ± 0.03 in test and control group respectively. ($p=1.0$)



Graphic. 6. Gengival crevicular fluid (μl) in patients with APE and without APE, in different time periods.

Results of histological analysis

Prichard⁴¹ has postulated that a more close gingival margin localized to the occlusal surface of the tooth diminishes the protective capacity against chewing traumas. This is what happens in the altered passive eruption as suggested by Evian et al⁹. In addition, some patients may develop, in certain cases, a generalized reactive gingival hyperplasia. From the clinical point of view, most patients have a healthy gum in the absence of bacterial plaque.

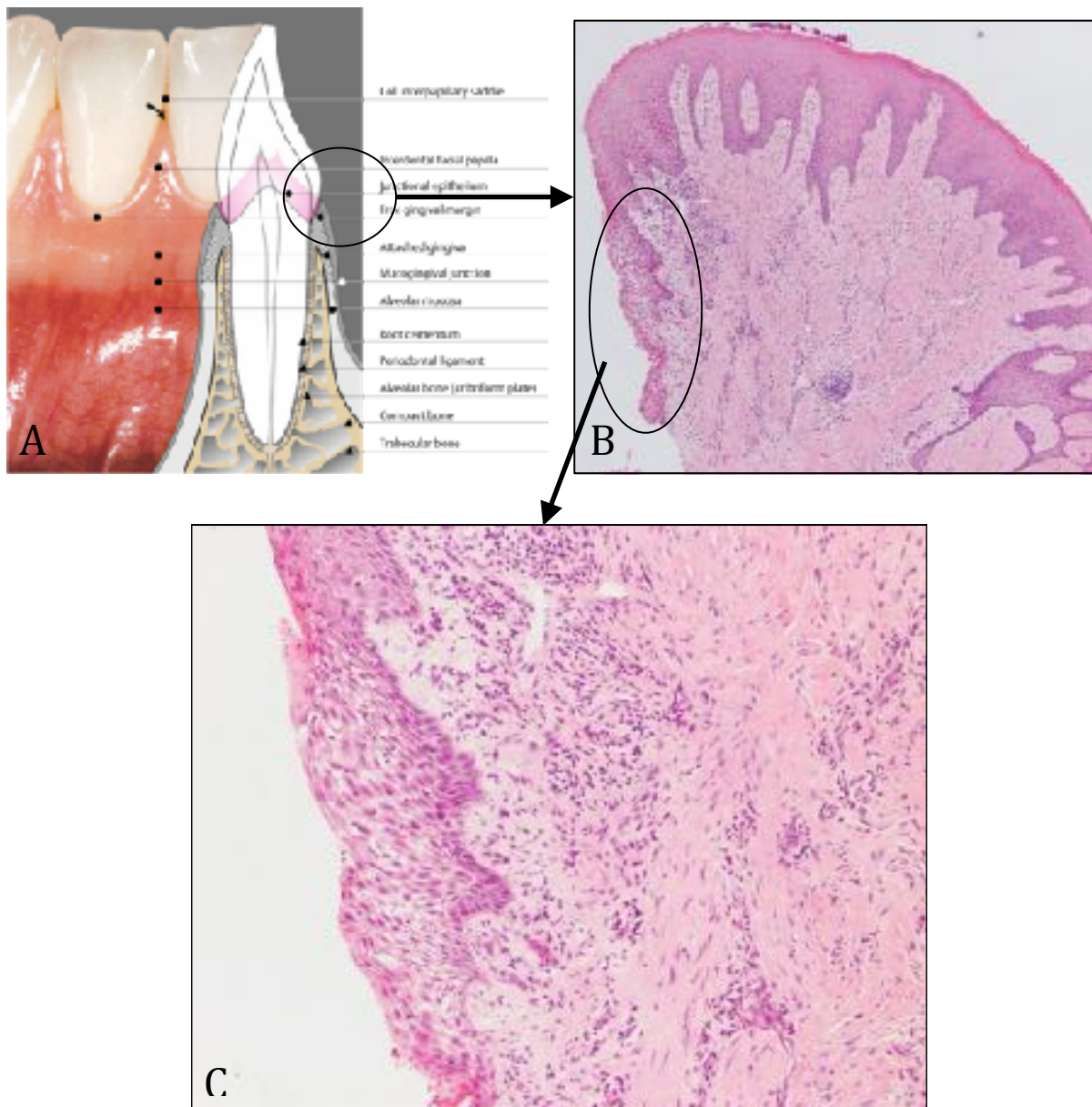


Fig. 16. A - Schematic figure of periodontal tissues (figure from Color Atlas of periodontology, Wolf, Rateitschak, Hassel, 2005, page 2, Thieme). B - Rete ridges elongation and acanthosis. C - Same site with high magnification

From what we observed in our cases, all patients except one, had histologic aspects compatible with a chronic gingivitis with different degrees of severity.

In particular, the epithelium corresponding to the gingival sulcus showed typical signs of acute inflammation including: spongiosis, neutrophil exocytosis, and in the most severe cases, true ulceration with underlying exposure of the lamina propria with its inflammatory granulation tissue. The surrounding gingival epithelium showed aspects of reactive hyperplasia with elongation of the rete ridges and acanthosis. (Fig. 16)

This was associated with the presence of chronic lympho-plasmacellular inflammatory infiltrate in this case with varying degrees of intensity (from perivascular to intense and diffuse) (Fig. 17)

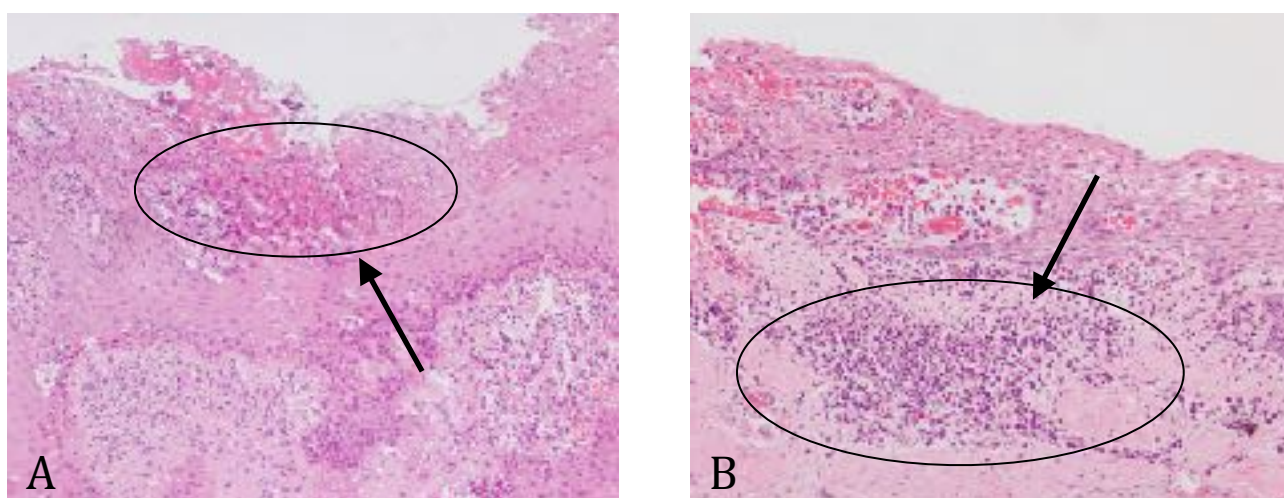


Fig. 17. A - Wide ulceration. B - Chronic lympho-plasmacellular inflammatory infiltrate

By dividing the sub-epithelial connective tissue into two main portions (Fig. 18) a superficial and a deep, collagen fibers were more dense in the deep part parallel to the gingival epithelium from which came off the less dense surface fibers (less numerous and thinner) with a “sunburst” pattern with respect to the alveolar bone and root surface but perpendicular to the gingival lining epithelium (Fig. 19)

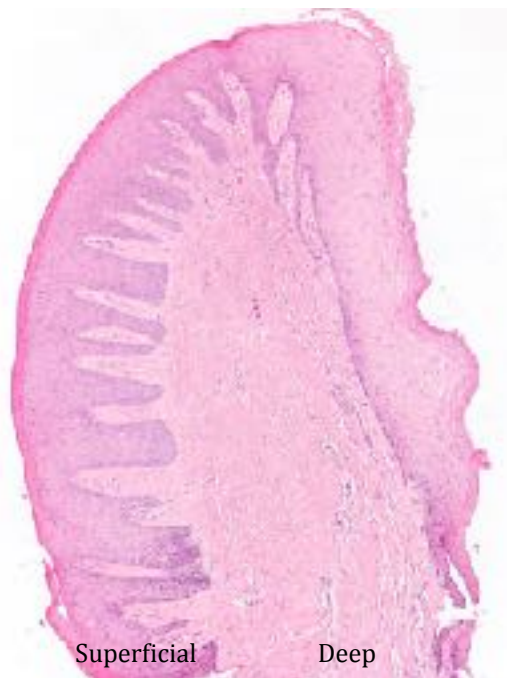

Fig. 18.

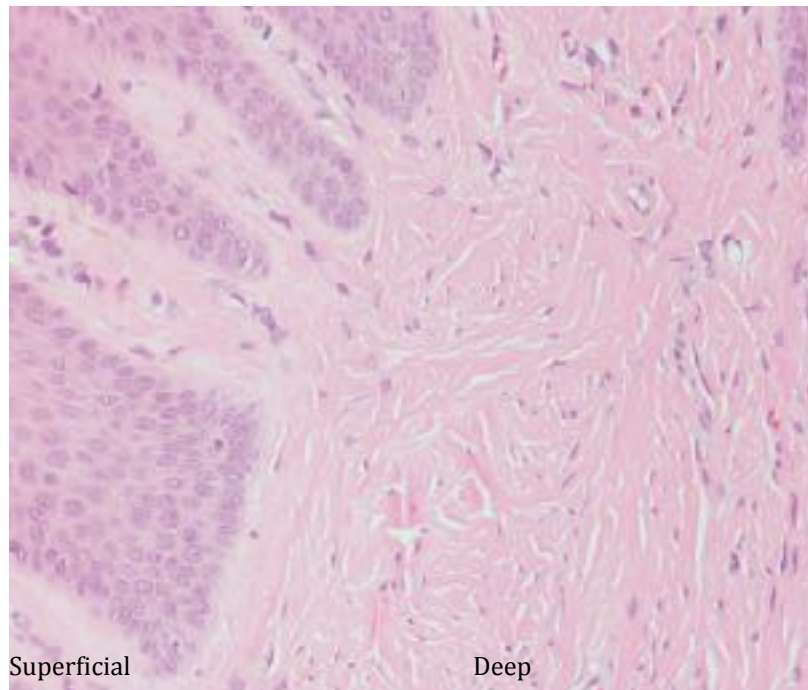


Fig. 19

In patients with altered passive eruption, this aspect of collagen fibers was maintained but with an increase in the size and number of fibers corresponding to a significant sclerotization of the deep part and a loss of "laxity" of the superficial part (see Fig. 20)

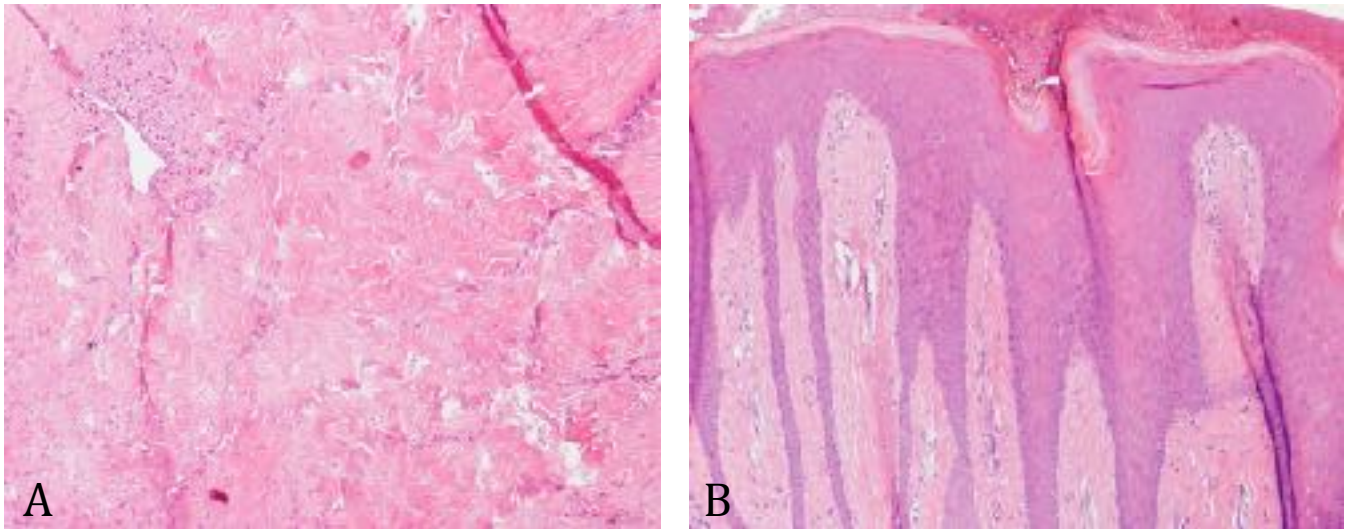


Fig. 20. A - Patients with APE presents significant sclerotization of collagen fibers in the deep part. B - and loss of laxity in the superficial part

In addition, the histological appearance of lesion of the sulcular epithelium in all cases except one confirms the hypothesis of chronic injury associated with the aspect of stable chronic plasmacellular gingivitis. This is even more interesting considering that the patients had no clinical signs of gingivitis at the moment of the surgery.

Discussion

The altered passive eruption is an anatomical condition that leads to aesthetic problems that seems to be related with an easier onset of gingivitis and/or periodontitis.

Our experimental gingivitis clinical trial revealed that among patients with altered passive eruption (test group) and those with a normal gingival anatomy (control group) there were no significant differences in the plaque accumulation time and its amount. Patients with altered passive eruption can maintain gingival health exactly as patients without such morphological anomaly, if perform a scrupulous oral hygiene procedures. However, in case of plaque accumulation, altered passive eruption is presumably a predisposing factor for the development and progression of gingivitis

more rapid with higher inflammation indexes (AngBs and MGI). In fact, on day 21 (T3), which represents the time of maximum plaque accumulation, there was found a statistically significant difference ($p=0.002$) between the two groups as to above-mentioned indexes. It should be also noted, that despite the significant gingival inflammation, even patients with altered passive eruption are likely to respond adequately to the therapy (which involves regular and attentive oral hygiene and professional oral hygiene). Thus, at time T6 (end of the trial) differences in inflammatory indexes between the two groups were insignificant ($p=0.206$ for AngBs). In spite of that, while the patients in the control group were all completely cured of experimental gingivitis, some patients with altered passive eruption continued to show signs of gingival inflammation.

As a result of the evaluation of the volume of gingival crevicular fluid in our clinical trial one may conclude that, although we could expect a significant increase in the amount of fluid itself at the time of maximum plaque accumulation and, therefore, at the peak of gingival inflammation in patients with altered passive eruption, the difference was at the limit of the statistical significance between the patients in test group and that in the control group.

From what was stated previously, it is possible to infer that subjects with altered passive eruption are at a greater risk of growing gingivitis and, therefore, probably also periodontitis, especially in cases where there is already a high predisposition to the development of such a problem^{16,35}.

The probable anatomical differences between periodontal tissues among subjects affected by altered passive eruption and subjects without this anatomical condition and, in some cases of APE, with the total lack of biological width, the presence of which leads to the protection counter traumatic insults of any nature and, in particular, mechanic^{5,6,10,36-30} are among the hypotheses mentioned in the literature to explain this phenomenon

Moreover, the excess of gingiva covering the dental crowns and, in some types of APE, the position of the mucogingival line at the level of CEJ could cause difficulties in oral hygiene procedures^{6,9,16}.

Another hypothesis that could justify the relation between altered passive eruption and gingival/periodontal disease is the presence in subjects with APE of a deeper gingival sulcus which would lead to the establishment of a favourable environment to bacterial growth⁴⁰.

At the same time, it is worth noting that the patients affected by altered passive eruption at the time T6 and immediately prior to surgery, showed no clinical signs of gingivitis, but at a microscopic level signs of acute or chronic inflammation have been revealed.

In fact, all the patients but one have presented histologic aspects compatible with acute and/or chronic gingivitis with varying degrees of intensity. Spongiosis, acanthosis, inflammatory infiltrate and, in the most serious cases, ulcerations have been discovered among the microscopic characters shown at the level of the epithelial tissue. On the other hand, in the connective tissue normally located, but more dense and voluminous due to the increased sclerotization, collagen fibers have been detected. The microscopic characteristics emerging from the histological examinations of the gingival fragments taken in this study confirm the hypothesis of chronic traumatism in subjects with altered passive eruption associated with histologic signs of stable chronic plasmacellular gingivitis.

Clinical aspect of gingival excess in patients with altered passive eruption could result not only from an anatomical anomaly, but also from a real increase of collagen, even in the absence of gingival hyperplasia maintained by chronic irritation and not necessarily associated with bacterial plaque.

It is not known at present whether these patients are predisposed genetically to produce more collagen for an abnormal function of fibroblasts, have a defect in enzymes destined for the removal thereof (protease, metalloproteinase), inhibition mechanisms (TIMP, inhibitors of metalloproteinase) or simply due to chronic irritation.

According to our histological findings, in the presence of chronic inflammation, surgical treatment is justified not only for aesthetic reasons, but also to reduce the

irritation that for the moment seems to be at the base of the pathology or at least to create a “loop” that would sustain chronic gingivitis over time and consequently lead to collagen deposition, predisposing patients to plaque accumulation and to a greater difficulty in maintaining oral hygiene.

It would be interesting to study the healing of surgical wounds in subjects affected by altered passive eruption to see if the increase in the density and size of the collagen fibers, that characterizes them, could affect the healing itself, leading, for example, to the formation of keloid scars. In addition to the hypothesis regarding the alteration of collagen fibers, other causes that lead to a different healing of surgical wounds in patients with altered passive eruption were suggested in literature. One of those causes seems to be, for instance, the lack of available space on the root cement for the attachment of collagen fibers (which normally provide protection for deep periodontal tissues) as in the patients with subtype B of altered passive eruption⁶.

Nevertheless, our findings are compatible with studies in the literature that indicate a gingival margin located more coronally on the dental surface (as in the case of altered passive eruption) reduces the protective capacity of periodontal tissues against chewing traumas, contributing to the development of chronic inflammation and predisposition to gingival pathology^{9,35,41}.

Conclusion

Altered passive eruption is an anatomical condition that is frequently diagnosed in periodontal clinical practice, especially for the ever-increasing demand of patients for the aesthetic improvement of their smile.

In addition to its aesthetic value, however, altered passive eruption could also affect gingival and periodontal health. In fact, in the case of plaque accumulation, the altered passive eruption is likely to be a predisposing factor for a more rapid progression of gingivitis with higher inflammation indexes (AngBs and mGI).

Notwithstanding, even if gingivitis in patients with altered passive eruption is developed much more rapidly, thorough home oral hygiene and plaque control conduces to complete clinical recovery. In spite of the clinical convalescence, however, some patients with APE show microscopic signs of gingival inflammation.

Further studies with a large number of patients are required to confirm the correlation between altered passive eruption and periodontal diseases, and to determine how its surgical correction can affect this relationship.

References

1. Rufenacht CR, Principles of Esthetic Integration: Quintessence Books, Carol Stream, IL, 2000.
2. Stephen J. Chu, Susan Karabin, Saiesha Mistry, Short Tooth Syndrome: Diagnosis, Etiology, and Treatment Management CDA. Journal. 32; 142-153, 2014.
3. Gottlieb B, Orban B: Active and passive continuous eruption of teeth, J Dent Res. 13:214, 1933
4. Gargiulo, AW, Wentz FM, Orban B, Dimensions and relations of the dentogingival junction in humans. J Periodontal 32:261-7, 1961.
5. Vacek, J. S., Gher, M. E., Assad, D. A., Richardson, A. C. & Giambarresi, L. I. (1994) The dimensions of the human dentogingival junction. The International journal of periodontics & restorative dentistry 14, 154–165.
6. Coslet JO. et al. Diagnosis and classification of delayed passive eruption of the dentogingival junction in the adults. Alpha Omegan 1977;3:24-28.
7. Dello Russo NM. Placement of crown margins in patients with altered passive eruption. Int J Periodon Rest Dent 1994; 4(1):59- 65.
8. Wolffe GN, van der Weijden FA, Spanauf AJ, de Quincey ON. Lengthening clinical crowns - A solution for specific periodontal, restorative, and esthetic problems Quintessence Int 1994; 25; 81-88.
9. Evian C, Cutler S. Rosenberg E. Altered passive eruption: The undiagnosed entity. J Am Dent Assoc 1993; 124; 107-110.
10. Ainamo J. Loe H. Anatomic characteristics of gingiva: A clinical and microscopic study of the free and attached gingiva. J Periodontol 1966; 37; 5-13.
11. Arthur H. Dolt, J. William Robbins, Altered passive eruption: An etiology of short clinical crowns. Quintessence Int 1997:28:363

12. Volchansky A, Cleaton-Jones PE. Delayed passive eruption. A predisposing factor to Vincent's infection? J Dent Asso S Africa 1974;29:291-294.
13. Garber DA, Salama MA. The aesthetic smile: diagnosis and treatment. Periodontol 2000. 1996;11:18-28.
14. Vig RG, Brundo GC. The kinetics of anterior tooth display. J Prosthet Dent. 1978;39:502-4.
15. Kois JC. Altering gingival levels: the restorative connection. I. Biologic variables. J Esthet Dent. 1994;6:3-9.
16. Alpiste-Illueca F. Altered passive eruption (APE): A little - known clinical situation. Med Oral Patol Oral Cir Bucal. 2011 Jan 1;16 (1):e100-4.
17. F. Cairo, F. Graziani, L. Franchi, E. Defraia, and GP Pini Prato. Periodontal Plastic Surgery to Improve Aesthetics in Patients with Altered Passive Eruption/Gummy Smile: A Case Series Study. Int J Dent. 2012; 2012; 1-6
18. Rossi R, Brunelli G, Piras V, Pilloni A. Altered passive eruption and familial trait: a preliminary investigation. Int J Dent 2014: 2014 Epub 2014 May 20.
19. Smidt A, Silberberg N, Goldstein M. Excessive gingival display – Etiology, diagnosis and treatment modalities. Quintessence International. 2009, 40:809-818
20. Zucchelli G., Mucogingival esthetic surgery. 2013. Quintessence Publishing.
21. Greenberg J, Laster L, Listgarten MA. Transgingival probing as a potential estimator of alveolar bone level. J Periodontol 1976;47: 514-7.
22. Loe, H., Theilade, E. & Jensen, S. B. Experimental gingivitis in man. Journal of Periodontology 1965; 36, 177–187.
23. Tatakis DN, Trombelli L: Modulation of clinical expression of plaque-induced gingivitis. I. Background review and rationale. J Clin Periodontol 2004; 31: 229–238.

24. Lindhe, J., Hamp, S. & Loe, H. Experimental periodontitis in the beagle dog. *Journal of Periodontal Research* 1973; 8, 1-10.
25. Prayitno, S. W., Addy, M. & Wade, W. G. Does gingivitis lead to periodontitis in young adults? *Lancet* 1993; 342, 471–472.
26. Trombelli L, Tatakis DN, Scapoli C, Bottega S, Orlandini E, Tosi M: Modulation of clinical expression of plaque-induced gingivitis. II. Identification of “highresponder” and “low-responder” subjects. *J Clin Periodontol* 2004; 31: 239–252.
27. van der Weijden, G. A., Timmerman, M. F., Nijboer, A., Reijerse, E. & van der Velden, U. Comparison of different approaches to assess bleeding on probing as indicators of gingivitis. *Journal of Clinical Periodontology* 1994, 21, 589–594.
28. Fransson, C., Mooney, J., Kinane, D. F. & Berglundh, T. Differences in the inflammatory response in young and old human subjects during the course of experimental gingivitis. *Journal of Clinical Periodontology* 1999, 26, 453–460.
29. Silness, J. & Loe, H. Periodontal disease in pregnancy. II. Correlation between oral hygiene and periodontal condition. *Acta Odontologica Scandinavica* 1964, 22, 121–135.
30. Quigley, G. A. & Hein, J. W. Comparative cleansing efficiency of manual and power brushing. *Journal of the American Dental Association* 1962, 65, 26–29.
31. Turesky, S., Gilmore, N. D. & Glickman, I. Reduced plaque formation by the chloromethyl analogue of vitamin C. *Journal of Periodontology* 1970, 41, 41–43.
32. Black, G. V. (1902) *Descriptive anatomy of the human teeth*, 4th edition, p. 159. Philadelphia: SS White Dental Manufacturing Company.
33. Kronfeld, R. (1936) Increase in size of the clinical crown of human teeth with advancing age. *Journal of the American Dental Association* 23, 382–392.
34. Orban, B. & Mueller, E. (1929) The gingival crevice. *Journal of the American Dental Association* 16, 1206–1242.
35. Dolt AH, Robbins JW. Altered passive eruption: an etiology of short clinical crowns. *Quintessence Int.* 1997;28:363-372.

36. Alpiste-Illueca F. Morphology and dimensions of the dentogingival unit in the altered passive eruption. *Med Oral Patol Oral Cir Bucal*. 2012 Sep 1;17(5): 814-820.
37. Alpiste-Illueca F. Dimensions of dentogingival unit in maxillary anterior teeth: a new exploration technique (parallel profile radiograph). *Int J Periodontics Restorative Dent*. 2004;24:386-396.
38. Sicher H. Changing concepts of the supporting dental structure. *Oral Surg Oral Med Oral Pathol*. 1959;12:31-35.
39. Schmidt JC, Sahrman P, Weiger R, Schmidlin PR, Walter C. Biologic width dimensions – a systematic review. *J Clin Periodontol*. 2013;40:493-504.
40. Volchansky A, Cleaton-Jones P. Clinical definition of altered passive eruption. *Br Dent J*. 1979;147:292.
41. Prichard JF. *Advanced Periodontal Disease*, ed 2. Philadelphia Saunders. 1979:420.