


# Takotsubo Cardiomyopathy and Sepsis: A Systematic Review

Angiology  
1-16  
© The Author(s) 2016  
Reprints and permission:  
sagepub.com/journalsPermissions.nav  
DOI: 10.1177/0003319716653886  
ang.sagepub.com  


Simone Cappelletti, MD<sup>1,2</sup>, Costantino Ciallella, MD<sup>1</sup>,  
Mariosaria Aromatario, MD, PhD<sup>1</sup>,  
Hutan Ashrafian, PhD, MRCS<sup>2,3</sup>,  
Sian Harding, BSc, PhD, FESC, FAHA, FISHR, FSB<sup>4</sup>,  
and Thanos Athanasiou, MD, PhD, FRCS, FETCS<sup>2</sup>

## Abstract

Takotsubo cardiomyopathy (TTC) is characterized by a systolic dysfunction localized in the apical and medial aspect of the left ventricle. It is usually related to physical or emotional stress. Recent evidence highlighting the role of infection led us to analyze the links between TTC and sepsis. A systematic review of the literature was undertaken to assess any trends in clinical findings, diagnosis, and outcomes in such patients. We identified 23 selected papers reporting a total of 26 patients, having sepsis, in whom TTC occurred. For each case, we collected data identifying population characteristics, source of sepsis, clinical disease description, and the results of cardiovascular investigations. The majority of patients were females ( $n = 16$ ), mean age was 62.8 (14.0 standard deviation) years, and clinical outcome was favorable in 92.3% of the cases once the management of sepsis was initiated. A better understanding of the mechanisms of sepsis-associated TTC may generate novel strategies to treat the complications of this cardiomyopathy and may even help predict and prevent its occurrence.

## Keywords

takotsubo cardiomyopathy, tako-tsubo, stress cardiomyopathy, infectious diseases, sepsis, sirs

## Introduction

Takotsubo cardiomyopathy (TTC) is an increasingly recognized cardiac condition that is also known as apical ballooning syndrome or broken heart syndrome. It has been classified by the American Heart Association as both a primary and an acquired cardiomyopathy<sup>1</sup> and is listed by the European Society of Cardiology (ESC) as an unclassified cardiomyopathy.<sup>2</sup> It has been described by transient midsegmental left ventricular (LV) dysfunction that may involve the apex, which can mimic the shape of a trap used by Japanese fishermen for octopus fishing (hence the name). Takotsubo cardiomyopathy was first mentioned by Sato et al in 1990 reporting the picture of a takotsubo-shaped heart during ventriculography.<sup>3</sup> The main characteristic of TTC, especially in its initial period, is a transient apical ballooning with regional abnormalities sometimes spread to the midventricular segments. This is also known as the classical presentation of TTC. Additionally, a “reverse” takotsubo exists where there is akinesis of the basal segments with a normal apex, although this is uncommon (<20%).<sup>2</sup>

Takotsubo cardiomyopathy is more prevalent in females and usually occurs in combination with a stressful event; associations with different triggers (eg, infections and

neurological conditions) have also been reported.<sup>4,5</sup> Takotsubo cardiomyopathy typically carries a favorable prognosis with full recovery of LV function, although serious complications may rarely arise. The underlying pathophysiology of TTC has not been fully clarified, although the enhanced central and local sympathetic stimulation are consistently described.<sup>4</sup> Since sepsis can be considered as a significant stressful event, our systematic review aims at gathering the evidence of reported cases concerning the onset of TTC in patients with sepsis.

<sup>1</sup> Department of Anatomical, Histological, Forensic Medicine and Orthopedic Sciences, Sapienza University of Rome, Rome, Italy

<sup>2</sup> Department of Surgery and Cancer, Imperial College London, London, United Kingdom

<sup>3</sup> Department of Cardiothoracic Surgery, Hammersmith Hospital, Imperial College Healthcare NHS Trust, London, United Kingdom

<sup>4</sup> Myocardial Function Section, National Heart and Lung Institute, Imperial College London, London, United Kingdom

## Corresponding Author:

Simone Cappelletti, Department of Anatomical, Histological, Forensic Medicine and Orthopedic Sciences, Sapienza University of Rome, Viale Regina Elena, 336-00161 Rome, Italy.

Email: simone.cappelletti@uniroma1.it

## Definition of TTC

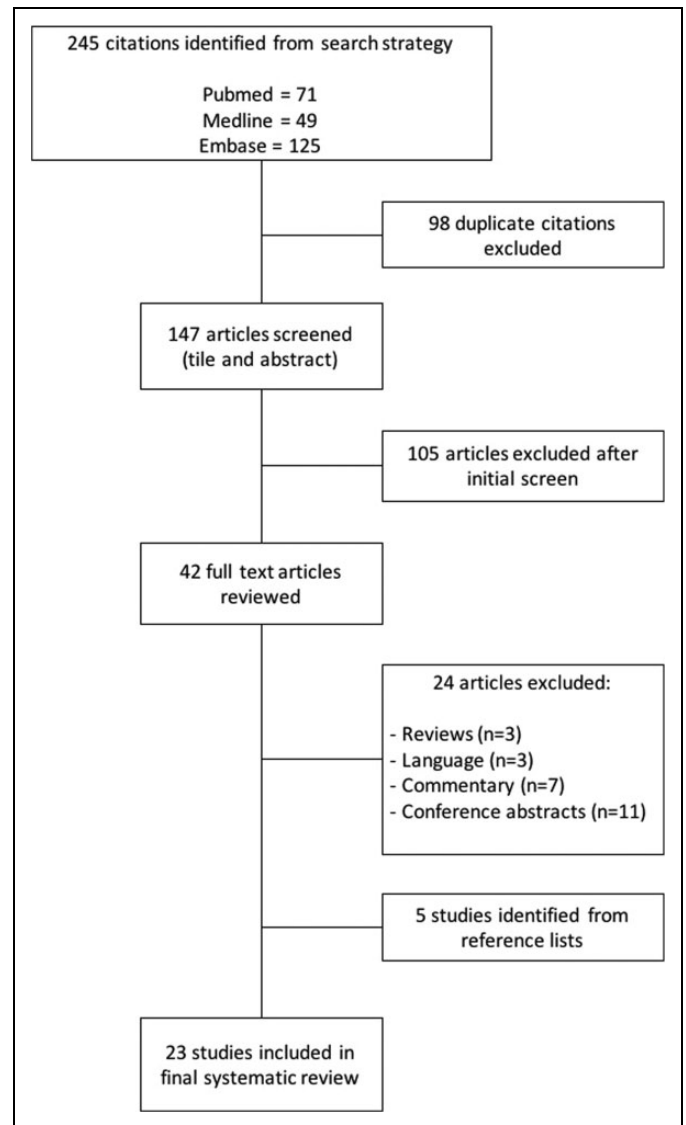
There is as yet no consensus on the diagnostic criteria for TTC. Researchers at the Mayo Clinic proposed diagnostic criteria in 2004, which were modified in 2008.<sup>6,7</sup> Taking into account these 2 main classifications, the TTC is defined as:

1. Transient abnormalities of LV contraction during ventriculography with akinesia of the apical part and hyperkinesis of the base (midapical form). In the majority of cases, the coronary arteries lack relevant flow obstruction. Nevertheless, concomitant coronary artery disease does not exclude takotsubo syndrome.
2. The definition has to include also patients with different ventricular contraction patterns such as midventricular transient contraction abnormalities, presenting with hyperkinesis of the base and apex of the LV and akinesia of the midventricular part (midventricular form). Also, the “inverted” type with hyperkinesis of the apex and transient basal akinesia of the heart has to be included (midbasal form).
3. In patients with TTC, the motion abnormalities resolve in the following few weeks.<sup>8</sup> However, in some patients, the process of resolving motion abnormalities may be as long as 1 year<sup>9</sup>; for this reason, constant monitoring is important in patients with TTC.
4. Changes in the electrocardiogram (ECG) indicative of myocardial ischemia most often presented in the chest leads V1 to V6 but may also be present in the limb leads. The most common changes are sinus tachycardia and ST-segment elevation in the chest leads with evolving T-wave inversions in nearly all leads. These changes resolve with passing time, and changes persisting over a certain time frame other than T-wave inversion are rare.
5. Exclusion of pheochromocytoma or myocarditis. According to the Mayo Clinic criteria, this definition also includes physical stressors such as seizures, major trauma, and stroke.<sup>10</sup>

## Methods

### Study Objectives

The objective of this systematic review is to summarize the available evidence for the development of TTC during sepsis. In particular, (1) we attempt to highlight the main microorganisms involved in TTC when sepsis occurred, (2) compare and contrast the symptoms of this cohort study with these of non-septic patients with TTC, (3) evaluate the risk factors presented in the cases reviewed, (4) study the ECG changes of the cases reviewed and find similarities and differences in non-septic patients with TTC, (5) evaluate changes in cardiac and hemodynamic biomarkers in order to offer clinicians useful guidance in cases of septic patients with TTC, (6) assess the main findings obtained from the diagnostic procedures, and (7) present



**Figure 1.** Flow diagram for systematic search.

the outcome of the cases reviewed and find differences in non-septic patients with TTC.

### Literature Search

A literature search was performed using PubMed, Embase, and MEDLINE using combinations of the terms “takotsubo” or “tako-tsubo” or “takotsubo syndrome” or “takotsubo cardiomyopathy” or “left ventricular apical ballooning” or “broken heart syndrome” or “stress cardiomyopathy” and “sepsis” or “sirs” or “systemic inflammatory response syndrome” with the limitations “humans” and “English language.”

The last date for this search was February 18, 2016. Figure 1 outlines our search strategy. All studies are listed in Table 1.

### Inclusion and Exclusion Criteria

Relevant publications were identified on the basis of titles and abstracts using the following inclusion and exclusion criteria.

**Table 1.** Epidemiological and General Data in Patients With Sepsis Having Takotsubo Cardiomyopathy.

Authors, Country, (year)	Number of Patients	Age	Sex	Type of Takotsubo	Time Interval of Onset From Admission	Symptoms at Admission	Diagnostic Methods	Microorganism	Onset of Sepsis	Outcome
Chidiac and Salon, United States (1995) <sup>11</sup>	1	39	M	Typical	<24 hours	Confusion, diaphoresis	Autopsy	<i>Cryptococcus neoformans</i>	Before recovery	Died
Greco et al, Italy (2006) <sup>12</sup>	1	40	F	Typical	ND	Chest pain	IgM+ IgG+	CMV	Before recovery	Complete resolution after 30 days
Cattaneo et al, Italy (2006) <sup>13</sup>	1	78	F	Typical	<24 hours	Dyspnea	ND	<i>Staphylococcus saprophyticus</i> MR	Before recovery	Complete resolution after 12 days
Bigalke et al, Germany (2007) <sup>14</sup>	1	67	F	Typical	<24 hours	Chest pain	PCR and direct DNA sequencing	HHV-6	Before recovery	Complete resolution, days ND
Ohigashi-Suzuki et al, Japan (2007) <sup>15</sup>	1	69	F	Typical	<24 hours	High fever, appetite loss	Blood and urine cultures	<i>Klebsiella pneumoniae</i>	Before recovery	Complete resolution, days ND
Geng et al, China (2008) <sup>16</sup>	1	65	F	Typical	<24 hours	Chest pain	Endotracheal tube aspirate	<i>Streptococcus pneumoniae</i>	Before recovery	Complete resolution after 26 days
Palacio et al, United States (2009) <sup>17</sup>	1	52	M	Typical	ND	Chest pain, fatigue, weakness, dizziness, fever, chills, night sweats, nausea, and vomiting	Blood, urine, and respiratory tract cultures	<i>Pseudomonas aeruginosa</i>	Before recovery	Complete resolution after 21 days
Sarullo et al, Italy (2009) <sup>18</sup>	1	55	F	Typical	<24 hours	Dyspnea, fever	Blood and urine cultures	<i>Staphylococcus cohnii</i>	Before recovery	Complete resolution, days ND
Lee et al, Republic of Korea (2010) <sup>19</sup>	1	41	F	Atypical	ND	Fever	ND	ND	During recovery	Complete resolution, days ND
Tanriver et al, Germany (2010) <sup>20</sup>	1	57	M	Typical	<24 hours	Chest pain, vomiting, dyspnea	Blood culture	<i>Escherichia coli</i>	Before recovery	Complete resolution, days ND
Hassan et al, Israel (2011) <sup>21</sup>	1	57	F	Typical	4 days	Chest pain, dyspnea, diaphoresis, nausea	Dialysate culture	<i>Staphylococcus aureus</i>	During recovery	Complete resolution, days ND

(continued)

Table 1. (continued)

Authors, Country, (year)	Number of Patients	Age	Sex	Type of Takotsubo	Time Interval of Onset From Admission	Symptoms at Admission	Diagnostic Methods	Microorganism	Onset of Sepsis	Outcome
Odjie-Okon et al, United States (2011) <sup>22</sup>	1	62	F	Typical	4 days	Fever, chills, nausea, headache	Blood smear, blood culture, PCR	Babesia, MSSA, torulopsis glabrata	Before recovery	Complete resolution after 11 days
Okumura et al, Japan (2011) <sup>23</sup>	1	72	F	Typical	2 days	Epigastric pain, fever, vomiting	Blood culture	Aeromonas hydrophila, K pneumoniae	During recovery	Complete resolution, days ND
Yonekawa et al, Switzerland (2011) <sup>24</sup>	1	61	F	Typical	4 days	Dyspnea, fever, diarrhea, vomiting	ND	ND	Before recovery	Complete resolution, days ND
Karvouniaris et al, Greece (2012) <sup>25</sup>	1	60	M	Typical	2 days	Chest pain, fever	Blood and urine cultures	E coli	Before recovery	Complete resolution, days ND
Xu et al, China (2012) <sup>26</sup>	1	90	M	Typical	<24 hours	Chest pain, dyspnea, fever	ND	ND	Before recovery	Died from multiorgan failure
Galea et al, Malta (2013) <sup>27</sup>	1	73	F	Typical	<24 hours	Diminished level of consciousness	ND	ND	Before recovery	Complete resolution, days ND
Santoro et al, Italy (2013) <sup>28</sup>	1	63	M	Typical	ND	Chest pain, fever, chills	Urinary catheter culture	Staphylococcus gallinarum	Before recovery	Complete resolution after 10 days
Ghoniim and Dubrey, United Kingdom (2014) <sup>29</sup>	1	57	F	Typical	ND	Lethargy	Urine analysis	ND	Before recovery	Complete resolution after 28 days
Kakroo et al, United States (2014) <sup>30</sup>	1	84	M	Atypical	ND	Altered mental status, fever, chills	Blood and catheter cultures	E coli	Before recovery	Complete resolution, days ND
Omar et al, United States (2014) <sup>31</sup>	1	42	F	Typical	<24 hours	Suprapubic and flank pain, fever, chills, rigors, nausea, vomiting	Urine culture	ND	Before recovery	Complete resolution, days ND

(continued)

**Table 1.** (continued)

Authors, Country, (year)	Number of Patients	Age	Sex	Type of Takotsubo	Time Interval of Onset From Admission	Symptoms at Admission	Diagnostic Methods	Microorganism	Onset of Sepsis	Outcome
Y-Hassan et al, Sweden (2014) <sup>32</sup>	4	74	M	Typical	ND	ND	Blood culture	<i>Citrobacter koseri</i>	ND	Complete resolution, days ND
		69	F	Atypical	ND	ND	Blood culture	<i>E coli</i>	ND	Complete resolution, days ND
		76	M	Typical	ND	ND	Blood culture	<i>Klebsiella oxytoca</i>	ND	Complete resolution, days ND
		48	M	Atypical	<24 hours	Fever, headache	Blood and urine cultures	Negative	Before recovery	Complete resolution, days ND
Heller et al, United States (2015) <sup>33</sup>	1	82	F	Typical	ND	Altered mental status, fever	ND	ND	Before recovery	Complete resolution after 14 days

Abbreviations: Atypical, midventricular and midbasal forms; CMV, cytomegalovirus; F, female; HHV-6, human herpesvirus 6; M, male; MR, methicillin resistant; MSSA, methicillin-sensitive staphylococcus aureus; ND, not declared; PCR, polymerase chain reaction; Typical, midapical form.

Inclusion criteria were (1) patients with takotsubo syndrome described as also having sepsis, (2) the study population had culture-proven sepsis or suspected infection based on clinical algorithm, and (3) the manuscript evaluated TTC using imaging and/or instrumental techniques. The following publication types were excluded: reviews, meta-analyses, commentaries, non-English articles, conference publications, in vitro studies, animal studies, and guidelines.

The references of the excluded articles were reviewed to identify any additional relevant studies. The retrieved studies were carefully examined to exclude potentially duplicate or overlapping data. Abstracts were excluded from the analysis because non-peer-reviewed data may introduce bias into the study.

### Data Extraction and Validity Assessment

Two independent reviewers (T.A. and S.C.) independently performed the literature search to identify relevant studies. A third investigator (M.A.) was available for arbitration in the event of discordance. Relevant data on authors, country, year of publication, patient population, age, gender, microorganisms involved, time interval between admission and TTC onset, type of takotsubo, cardiac enzymes, ECG changes, echocardiogram/coronary angiography/left ventriculography findings, ejection fraction (EF), previous risk factor for cardiovascular diseases, symptoms at admission, and outcomes were extracted and presented in Tables 1 and 2.

## Results

### Selected Studies

Of 245 potentially relevant manuscripts, 23 were selected for final review (Figure 1). Baseline demographic characteristics of the included studies are shown in Table 1. A total amount of 26 patients were reviewed. Most patients were female ( $n = 16$ ), mean age was 62.8 (14.0 standard deviation) years, and the vast majority presented with the typical, apical-involving pattern (84.6%).

### Sepsis and TTC

Bacterial sepsis was the most frequent cause of TTC in our systematic review (57.7%). Moreover, 7 (26.9%) cases were described without providing any pathogenic microorganism; 2 (7.8%) cases were related to viral agents; in 1 (3.8%) case, sepsis was due to a fungus; and finally, in 1 (3.8%) further case, the culture results were negative, and the diagnosis of sepsis was based on clinical criteria.

Historically, the association between TTC and sepsis was first described in 2005 by Park et al<sup>34</sup> on 92 patients admitted to intensive care units and in which sepsis was the only variable associated with the onset of LV apical ballooning (odds ratio = 9.2; 95% confidence interval = 2.4-35.8,  $P < .001$ ). In 2012, El-Sayed and his colleagues,<sup>35</sup> in their study on data of 24 701 patients diagnosed with TTC, showed that sepsis increased the risk of TTC development. A recent Italian study,<sup>36</sup> performed

on a smaller group of 26 patients with TTC, suggested the role of pulmonary infections and showed that sepsis was the complication in 31% of patients with TTC.

Our study showed that the majority of bacterial sepsis was sustained by *Escherichia coli* ( $n = 3$ ). Other bacteria mainly involved were *Klebsiella pneumoniae* and *Staphylococcus aureus* ( $n = 2$  each one).

Concerning the cases of sepsis and TTC sustained by viral agents, we found only 2 cases in which sepsis was due to cytomegalovirus (CMV) and human herpesvirus 6 (HHV-6), respectively.<sup>12,14</sup> The pathophysiological mechanisms underlying the damage are different; in herpes virus infections (CMV and HHV-6), the cause of myocardial cell damage is primarily an immune-mediated reaction.<sup>37</sup>

Among the cases reviewed, only one was related to a parasitic infection (babesiosis). In babesiosis, infected erythrocytes cause vascular stasis, leading to microvascular obstruction, tissue anoxia, and ischemia.<sup>22</sup> These findings were confirmed, in other studies, using animal models, describing cases of cardiomegaly, myocarditis, and multifocal coagulation cardiac necrosis.<sup>22</sup> The authors hypothesized that there may be an association between babesiosis and TTC.

With regard to the diagnostic procedures adopted to identify such microorganisms, the main techniques were blood and urine cultures. Positive blood culture was recorded in 13 patients, negative in 1 patient; positive urinary culture was recorded in 8 patients; other diagnostic methods used consisted of polymerase chain reaction (PCR;  $n = 2$ ), antibodies immunoglobulin (Ig) M/IgG ( $n = 1$ ), endotracheal tube aspirate ( $n = 1$ ), and dialysate culture ( $n = 1$ ). In 6 cases, authors did not provide information on the diagnostic methods.

Summarizing, TTC in patients with sepsis has been observed independently from the microorganism responsible for it. Although TTC could be related to sepsis due to bacteria, virus, parasites, and fungus, we found a significant frequency of case related to bacterial infection.

### Cardiovascular Risk Factors and Symptoms of Presentation

The available scientific literature shows that a great variety of factors can predispose, trigger, and eventually result in TTC.<sup>38</sup> These factors can be classified as triggers (eg, emotional stressors, physical stressors, and neurologic triggers), pathogenic mechanisms (eg, increased catecholamine levels and coronary vasomotor abnormalities), and predisposing factors (eg, cardiovascular risk factors). Although different studies have reported data on precipitating events and pathogenic mechanisms in septic and nonseptic patients presenting with TTC,<sup>39,40</sup> there is still a paucity of data on risk factors.

Generally, patients with TTC have a prevalence of cardiovascular risk factors higher than the general population and similar to that seen in patients with acute myocardial infarction (MI).<sup>41</sup> Two important studies showed an unexpected high prevalence of cardiovascular risk factors, in spite of the absence of obstructive coronary artery disease.<sup>41,42</sup> The main

**Table 2. Cardiac Findings in Patients With Sepsis Having Takotsubo Cardiomyopathy.**

Authors, Country (Year)	Risk Factor for Cardiovascular Diseases	Cardiac Enzymes	ECG Changes	Echocardiogram Findings	Ejection Fraction	Coronary Angiography	Left Ventriculography	Takotsubo Localization	Cardiac Complication
Chidiac and Salon, United States (1995) <sup>11</sup>	Intravenous drug use	CKMB normal	Sinus tachycardia, nonspecific ST-T wave changes	Severe reduction in LV contractility with asynergy of the apical region	30%	Not done Autopsy: normal coronary arteries	Not performed	Midapical	Cardiogenic shock, mild mitral, and moderate tricuspid regurgitation
Greco et al, Italy (2006) <sup>12</sup>	No	TnI + (5.36 ng/mL); CKMB + (10 ng/mL)	T-wave inversion	Not performed	ND	Normal coronary arteries	Apical ballooning	Midapical	No
Cattaneo et al, Italy (2006) <sup>13</sup>	Diabetes type II, hypercholesterolemia	CK + (457 IU/L); CKMB + (31 IU/L)	ST-segment elevation	Extensive anteroapical akinesis with hyperkinesis of the basal segments	45%	Normal coronary arteries	Akinesis of the apex, with ballooning during systole; hyperkinesis of the basal segments; severe mitral regurgitation; opacification of pulmonary veins	Midapical	Mitral regurgitation
Bigalke et al, Germany (2007) <sup>14</sup>	No	TnI + (24.2 ng/mL); CK + (475 IU/L); CKMB + (69 IU/L)	ST-segment abnormalities T-wave inversion	Not performed	ND	Normal coronary arteries	Apical ballooning; moderately reduced LV function	Midapical	Heart failure
Ohigashi-Suzuki et al, Japan (2007) <sup>15</sup>	Diabetes type II	Tn + (no values)	Sinus tachycardia, ST-segment elevation	Apical dyskinesis and basal hyperkinesis	20%	Normal coronary arteries	Apical ballooning	Midapical	Heart failure, DIC
Geng et al, China (2008) <sup>16</sup>	Diabetes type II, hypertension	TnI + (3 ng/mL)	ST-segment elevation	Severe LV dysfunction; Akinesis of the distal anterior septum and apical regions and hyperkinesis of the basal segments	20%-25%	Trivial coronary disease	Not performed	Midapical	Pulmonary edema and respiratory arrest
Palacio et al, United States (2009) <sup>17</sup>	Hypertension, alcohol abuse, cancer	TnT + (6.09 ng/mL)	ST-segment elevation	Severe reduction of LV systolic function with dyskinesis of the anterior and apical walls	ND	Normal coronary arteries	LV dilatation and significant anteroapical dyskinesia	Midapical	Cardiorespiratory arrest
Sarullo et al, Italy (2009) <sup>18</sup>	Hypertension, previous ischemic stroke, hyperthyroidism	TnT + (2850 ng/mL); CKMB + (75.98 ng/mL)	Sinus tachycardia, ST-segment elevation	Akinesis of the LV apex	28%	Normal coronary arteries	Not performed	Midapical	Pulmonary edema

(continued)

**Table 2.** (continued)

Authors, Country (Year)	Risk Factor for Cardiovascular Diseases	Cardiac Enzymes	ECG Changes	Echocardiogram Findings	Ejection Fraction	Coronary Angiography	Left Ventriculography	Takotsubo Localization	Cardiac Complication
Lee et al. Republic of Korea (2010) <sup>19</sup>	Anticancer treatment	TnT + (0.393 ng/mL); CKMB + (19.47 ng/mL); NT-proBNP + (3500 pg/mL)	Sinus tachycardia, T inversion, QTc	Severe LV systolic dysfunction with akinesia of the LV base and midportion, together with hypercontractility of the apex	ND	Normal coronary arteries	Akinesia of the LV base and midportion except for the apex	Midbasal	Heart failure and cardiogenic shock
Tanriver et al, Germany (2010) <sup>20</sup>	Pheochromocytoma	TnI + (no values); CK + (no values)	ST-segment elevation	Not performed	ND	Normal coronary arteries	Severely impaired contraction of the apical anterior wall extending to the apical inferior wall	Midapical	Pulmonary edema
Hassan et al, Israel (2011) <sup>21</sup>	ND	TnI normal	Sinus tachycardia, ST-segment elevation, T-wave inversion	Akinesia of the LV apex with apical ballooning	30%	Normal coronary arteries	Not performed	Midapical	ND
Odigie-Okon et al, United States (2011) <sup>22</sup>	Hypertension, hypercholesterolemia	TnI + (0.44 ng/mL); CKMB + (4.3 ng/mL); BNP + (1860 pg/mL)	Sinus tachycardia, ST-segment elevation	Overall decrease in LV systolic function; hypokinetic mid anteroseptum and anterior wall, extending to and involving the entire apex, with a global hypokinesis of all other segments	30%	Not performed	Not performed	Midapical	Mitral and tricuspid regurgitation
Okumura et al, Japan (2011) <sup>23</sup>	ND	ND	ST-segment elevation	Posterolateral LV wall dysfunction	ND	Normal coronary arteries	Not performed	Midapical	ND
Yonekawa et al, Switzerland (2011) <sup>24</sup>	ND	TnT + (2.9 ng/mL)	T-wave inversion	Akinetic apical and anteroseptal walls, hyperkinetic basal and lateral walls	30%	Normal coronary arteries	Contraction of only basal parts of the LV	Midapical	Left ventricular thrombus, ischemic stroke
Karvouniaris et al, Greece (2012) <sup>25</sup>	Diabetes type II, hypercholesterolemia	TnI + (2.87 ng/mL)	Sinus tachycardia, ST-segment elevation	Akinetic LV apical segments and relatively hyperkinetic basal segments	ND	Not performed	Not performed	Midapical	Cardiogenic shock
Xu et al, China (2012) <sup>26</sup>	No	TnT + (no values); CKMB + (154 IU/L)	ST-segment elevation	Severe global LV dysfunction	29%	Normal coronary arteries	Apical dyskinesia and basal hyper contractility	Midapical	Ventricular fibrillation

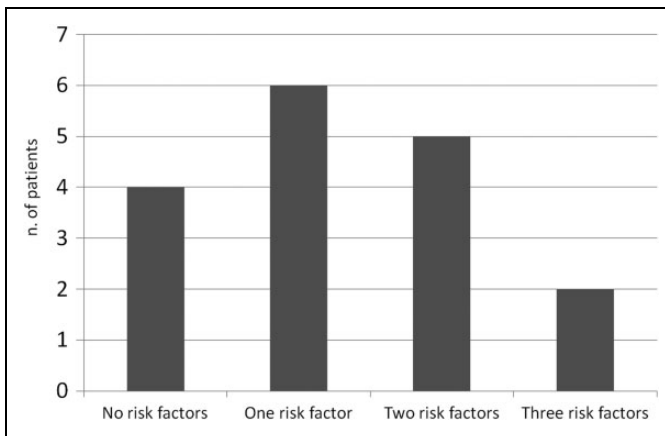
(continued)



**Table 2.** (continued)

Authors, Country (Year)	Risk Factor for Cardiovascular Diseases	Cardiac Enzymes	ECG Changes	Echocardiogram Findings	Ejection Fraction	Coronary Angiography	Left Ventriculography	Takotsubo Localization	Cardiac Complication
Galea et al, Malta (2013) <sup>27</sup>	ND	TnI + (1.10 ng/mL)	Sinus tachycardia, ST-segment elevation	Not performed	ND	Ballooned LV with akinetic anterior, lateral, and inferior apical walls; poor global contractility, high-filling pressures; moderate stenosis of the LAD ostium, the mid-LAD and the OM	Not performed	Midapical	ND
Santoro et al, Italy (2013) <sup>28</sup>	ND	TnI + (5.8 ng/mL); NT-proBNP + (8680 pg/mL)	Sinus tachycardia, ST-segment elevation	Apical ballooning and moderate mitral regurgitation.	35%	Normal coronary arteries	Apical ballooning	Midapical	Heart failure
Ghoniim and Dubrey, United Kingdom (2014) <sup>29</sup>	Hypertension	ND	T-wave inversion	Apical ballooning and apical akinesis	30%	Not performed	Not performed	Midapical	Pulmonary edema
Kakroo et al, United States (2014) <sup>30</sup>	No	TnI + (8.14 ng/mL); CKMB + (15.9 ng/mL)	AF	Akinesis of the basal and mid segments of the entire LV with preserved contractility of the apical segments	40%-45%	Normal coronary arteries	Not performed	Midbasal	ND
Omar et al, United States (2014) <sup>31</sup>	Hypertension, hypercholesterolemia	TnI + (6.78 ng/mL); CK + (251 U/L); CKMB + (21.5 ng/mL); BNP + (2547 pg/mL)	Sinus tachycardia, T-wave inversion, QTc	Dilated LV; apical and anteroseptal hypokinesis	30%	Normal coronary arteries	Not performed	Midapical	ND
Y-Hassan et al, Sweden (2014) <sup>32</sup>	ND	ND	ST-segment elevation	ND	ND	Not performed	Not performed	Midapical	ND
	ND	ND	ST-segment elevation	ND	ND	Normal coronary arteries	Not performed	Midventricular	ND
	ND	ND	ST-segment elevation	ND	ND	Three-vessel disease	Not performed	Midapical	ND
	ND	TnT + (649 ng/mL); NT-proBNP + (4690 pg/mL)	ST-segment elevation	ND	ND	Myocardial bridging of a segment of the LAD with systolic compression	Left midventricular ballooning with normal apical and basal LV contractions	Midventricular	ND
Heller et al, United States (2015) <sup>33</sup>	Hypertension	TnI + (34.6 ng/mL)	ST-segment elevation	LV dilatation, apical ballooning	ND	Not performed	Not performed	Midapical	ND

Abbreviations: AF, atrial fibrillation; BNP, brain natriuretic peptide; CK, creatine kinase; CKMB, creatine kinase muscle brain; DIC, disseminated intravascular coagulation; ECG, electrocardiogram; LAD, left anterior descending; LV, left ventricular; MR, methicillin resistant; ND, not declared; NT-proBNP, N-terminal pro-brain natriuretic peptide; OM, obtuse marginal branches; PCR, polymerase chain reaction; Tn, troponin; TnI, troponin I; TnT, troponin T; QTc, prolongation of corrected QT.



**Figure 2.** Frequency of risk factors among patients with sepsis having takotsubo cardiomyopathy. One risk factor indicates diabetes type II, hypertension, cancer, pheochromocytoma, or intravenous drug abuse. Two risk factors indicate diabetes type II + hypercholesterolemia, diabetes type II + hypertension, hypertension + hypercholesterolemia. Three risk factors indicate hypertension + alcohol abuse + cancer; hypertension + previous stroke + hyperthyroidism.

risk factors in nonseptic patients were described as hypertension (54%), dyslipidemia (32%), smoking (22%), diabetes (17%), and obesity (17%); similar prevalence were observed by Summers et al.<sup>42</sup>

Concerning the cardiovascular risk factors in sepsis-induced TTC, these were found in 17 (65.3%) patients: the most common were diabetes type II (38.5%), hypercholesterolemia (15.4%), and hypertension (7.7%). Four (15.4%) patients had no cardiovascular risk factors; in 9 patients, the authors did not report this information. The frequency of cardiovascular risk factors encountered in our study is presented in Figure 2.

In conclusion, taking into account the sample differences between our study and the others analyzed for nonseptic patients, it seems that diabetes is strongly related to TTC and that hypertension and dyslipidemia are less frequently encountered in septic than in nonseptic cohort.

Furthermore, 3 patients had associated diseases (hyperthyroidism, cancer, and pheochromocytoma, respectively), which may also have contributed to the induction of TTC. Indeed, some of these comorbidities are known to be associated with excessive catecholamine production and could represent the potential link with the TTC.

With regard to the symptoms, it was shown that the most common presenting cardiovascular symptoms in patients with sepsis having TTC were dyspnea, fever, and chest pain (see Table 1). These symptoms are quite similar, with the exception of the fever that was not described, to the ones reported in nonseptic patients presenting with TTC. Indeed, main symptoms in nonseptic patients are described as chest pain, followed by dyspnea, palpitations, and physical fatigue.<sup>10,43</sup> These symptoms are commonly characterized by a preceding physical or emotional stress such as a surgical operation.

Finally, in the time interval of TTC onset from the admission to the hospital, we observed the following: 11 patients

developed TTC within 24 hours from the recovery; 2 patients within 48 hours, and 3 patients within 96 hours. We could not establish the time interval between admission and development of TTC in 10 cases. The short-time interval between admission and TTC needs to be pointed out as an important consideration for the clinicians to be aware of this TTC characteristic.

### Electrocardiogram Changes

Since the majority of patients with TTC presented to the emergency department with symptoms mimicking an acute coronary syndrome, ECG represents a fast and reliable tool for establishing the diagnosis of myocardial ischemia. During TTC, changes in the ECG are a common feature most often reported from the chest leads.<sup>11,22</sup>

In our review, we found that ECG abnormalities were often observed after admission and the most common were (in descending order) ST-segment elevation ( $n = 15$ ), sinus tachycardia ( $n = 10$ ), T-wave inversion ( $n = 7$ ), QTc ( $n = 2$ ), ST “anomalies” ( $n = 2$ ), and atrial fibrillation (AF;  $n = 1$ ). In 3 cases, ECG changes were not described.

In particular, leads representing the anterior wall of the left ventricle (eg, V1-V6) are often affected during the acute phase of the TTC; these anomalies normalize, usually, in a few hours. Following the ST-segment elevation, sinus tachycardia and T-wave inversion are the major ECG anomalies reported in nonseptic patients with TTC and are present in almost all chest and limb leads.

There is persuasive evidence that T-wave inversion is not an evolution of ST-segment elevation but, especially in the Caucasian population, could be present from the beginning of TTC pathophysiology,<sup>44,45</sup> and a prolongation of the QT interval is more common after a few days and can persist months after discharge.

Moreover, attenuation of the QRS complexes, albeit not commonly noticed on routinely performed ECGs, is common in the acute phase of the takotsubo syndrome<sup>46</sup> and is related to systolic dysfunction.<sup>47</sup>

Another feature reported is the prolongation of the corrected QT interval (QTc). Complications can arise through these variations in the ECG like ventricular or AF, and these changes can be life threatening with fatal prognosis. For example, a case of AF in an 84-year-old man presenting with a midbasal TTC has been included in this study.

Finally, the ECG changes described are similar to those of ST-segment elevation myocardial infarction (STEMI). In order to differentiate the diagnosis between TTC and STEMI, the observation of the absence of ST-segment elevation in V1 and the presence of ST-segment depression in aVR (ST-segment elevation in aVR) has been proposed.<sup>43</sup> Yoshikawa reported differences in the distribution of ST-segment elevation between patients with TTC and those with STEMI. Most patients with anterior acute MI had ST-segment elevation in leads V2 to V4. In contrast, in patients with TTC, ST-segment elevation most frequently occurred in leads II, III, aVF, aVR, and V5 to V6 facing the apical and inferolateral regions.

**Table 3.** Descriptive Analysis of the Enzymatic Values in Patients With Sepsis Having Takotsubo Cardiomyopathy.<sup>a</sup>

	Range		Mean	
	Minimum	Maximum	Average	SD
TnI, ng/mL	0.44	34.6	9.23	11.17
TnT, ng/mL	0.39	2850	701.7	1233.08
CK, IU/L	251	475	394.3	124.45
CKMB, IU/L	31	154	84.7	62.97
CKMB, ng/mL	4.3	75.98	24.5	25.98
BNP, pg/mL	1860	2547	2203.5	485.78
NT-proBNP, pg/mL	3500	8680	5623.3	2713.19

Abbreviations: BNP, brain natriuretic peptide; CK, creatine kinase; NT-proBNP, N-terminal pro-brain natriuretic peptide; SD, standard deviation; TnI, troponin I; TnT, troponin T.

<sup>a</sup>Data were rounded to the second decimal place.

### Cardiac and Hemodynamic Biomarkers

During initial presentation to the hospital, most of the patients have normal or mild elevated biomarkers of myocardial necrosis such as troponin I (TnI), troponin T (TnT), creatine kinase (CK), and creatine kinase muscle brain (CKMB). Some patients even present with normal concentrations of the corresponding necrosis biomarkers of the myocardium, despite severe symptoms or transient wall motion defects in the ventriculography or echocardiography mimicking myocardial ischemia.<sup>11,21</sup>

From our review, we observed that cardiac enzymes were provided in 73% of the cases. Among these cases, the TnI enzyme was elevated in 10 patients, CKMB in 9 patients, and TnT and CK in 5 and 3 patients, respectively (see Table 3 for descriptive statistics).

Hemodynamic biomarkers, especially brain natriuretic peptide (BNP) and its more stable variant N-terminal pro-brain natriuretic peptide (NT-proBNP), are important to monitor the severity and the clinical course of patients with TTC. Despite it was described that patients with a high BNP or NT-proBNP concentration are more likely to have an adverse outcome reflecting the fact of diminished EF and hemodynamic impairment,<sup>48</sup> in our review, we have not recorded cases with high levels of BNP and/or NT-proBNP that had an adverse outcome. On the other hand, declining BNP levels might be a valuable marker showing the improvement in LV function in patients with TTC over time.<sup>48</sup>

In the studies reviewed, NT-proBNP and BNP levels were provided in only 3 and 2 cases, respectively (see Table 3 for descriptive statistics).

Our analysis of biomarker levels was not able to distinguish whether TTC is due to sepsis. The important role of these biomarkers in the differential diagnosis between TTC and acute coronary syndrome leading to MI must be highlighted.

In fact, acute coronary syndrome with ST-segment elevation and the subsequent risk of STEMI is noted as one of the most common diseases that require to be differentiated from TTC. The differential diagnosis can be based on the presence of

relatively remarkable elevation of the concentration level of BNP compared with TnT; for this reason, Ahmed et al proposed the BNP–TnT ratio as a potential and useful tool for differential diagnosis.<sup>49</sup>

Moreover, the pattern of troponin elevation differs considerably from acute STEMI. Usually, peak TnT levels in TTC are modest, mean about 60-fold the upper limit of normal (ULN, defined as 99th percentile) as opposed to >400-fold the ULN for acute STEMI, similar to those seen in non–ST-segment elevation MI.<sup>49,50</sup>

In conclusion, the patterns of biomarker elevations observed are noteworthy, but there is no threshold identified that has clinically meaningful sensitivity or specificity to distinguish acute MI from TTC. Clinicians should take this limit into account when interpreting such data.

### Diagnostic Methods

Cardiac imaging studies were carried out using echocardiography, coronary angiography, and/or left ventriculography. Echocardiogram is an important diagnostic procedure performed to diagnose and monitor the transient changes in systolic function. This procedure is also used to assess the valve hemodynamics and the diastolic function of these patients.<sup>13,22</sup> The mitral regurgitation described in some cases could be explained by the outflow tract obstruction due to the hyperkinesia of the base of the ventricle.

In our review, echocardiograms were performed in 69.2% of the patients, and the main findings are reported in Table 2.

With regard to coronary angiography, patients usually undergo this procedure due to the fact that initial presentation of TTC can mimic an acute coronary syndrome. Coronary angiography is followed in the majority of cases by a left ventriculography; furthermore, as shown in Table 2 and Figure 3, most patients have no coronary artery disease that could explain the wall motion abnormalities. Nevertheless, concomitant coronary artery disease may not be directly related to underlying TTC because the wall motion defects are often not located in the territory of a single coronary artery.

Coronary angiography and left ventriculography have been carried out in 76.9% and 42.3%, respectively, of the cases reviewed. Interestingly, coronary angiography showed normal arteries in 80% of the cases analyzed.

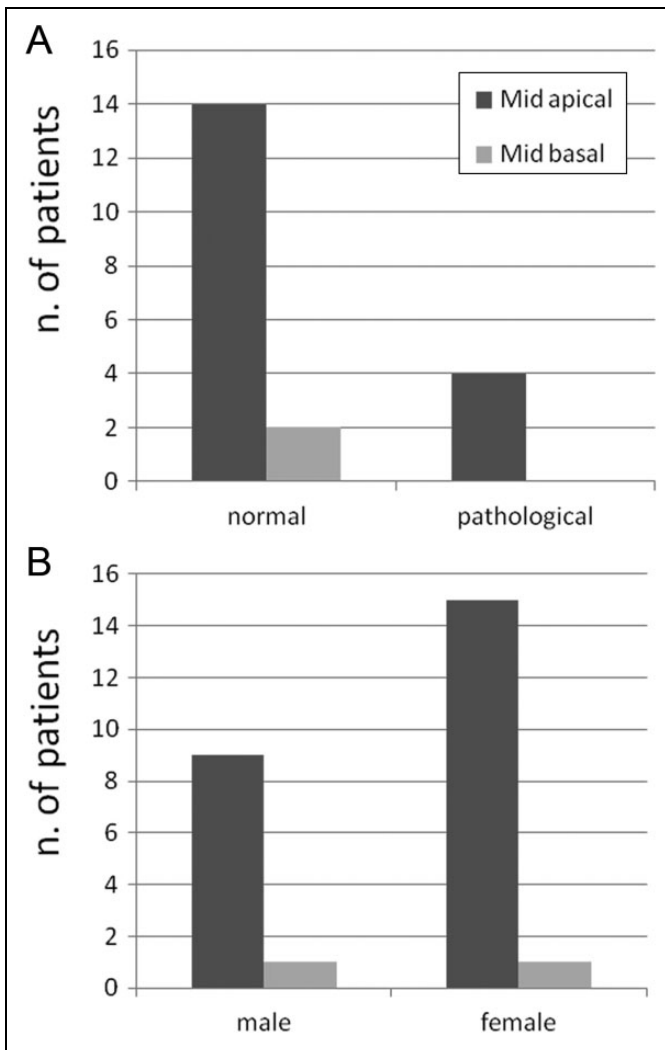
With regard to the type of TTC, the imaging studies showed that the midapical involvement was prevalent, being observed in 92.3% of the patients compared with the midbasal form that was present only in 7.7% of the patients.

The EF was between 20% and 45% (average = 30.9; median = 30). In 13 cases, the EF was not reported.

Finally, we carried out some comparison statistical analysis on the relationship between type of TTC and sex and results of coronary angiography (normal vs pathological); the results are shown in Figure 3.

### Outcome and Comparative Analysis

The prognosis of TTC is more often favorable. The prevalence of prehospital mortality is unknown but should not be



**Figure 3.** Frequency of type of takotsubo cardiomyopathy in relation with (A) sex and (B) results obtained from the coronary angiography.

underestimated, as mortality during the acute phase in hospitalized patients is 4% to 5%, which is similar to the mortality seen in patients with STEMI. Moreover, despite the recovery of LV function and absence of coronary artery disease, mortality after hospital discharge is notably higher than that in age-matched healthy populations.<sup>51</sup> Furthermore, in the largest published cohorts, the in-hospital mortality (IHM) was 6.8% in Japan,<sup>52</sup> 4.2% in the United States,<sup>53</sup> 2.6% in Italy,<sup>54</sup> and 2.2% in Germany and Austria.<sup>55</sup>

In the cases reviewed, clinical outcome was favorable in 92.3% of these, and all the survived patients were discharged after an average of 19 days (median = 17.5). Unfortunately, for 16 cases, data on the time interval to discharge were not provided.

Interesting findings have been obtained from the comparison of the outcome (survived vs died patients) and sex, risk factors (presence or absence), coronary angiography results (normal vs pathological findings), and time interval between admission and TTC. Results are shown in Figure 4.

## Discussion

### Takotsubo Cardiomyopathy and Sepsis—How Common Is It?

Defining the exact frequency of TTC among patients with sepsis is difficult because of the lack of reliable epidemiological data. With the exception of the above reported case reports, only 3 studies described the association between sepsis and TTC in a cohort of patients. Park et al<sup>34</sup> reported 25 cases of sepsis in which TTC was detected in 16 (68%) patients. Lee et al<sup>56</sup> described 56 patients with TTC; sepsis was considered the cause in 15 (27%) cases. Finally, Brinjikji et al<sup>53</sup> reported further 24 701 patients with TTC; sepsis was considered the cause in 7% of these patients.

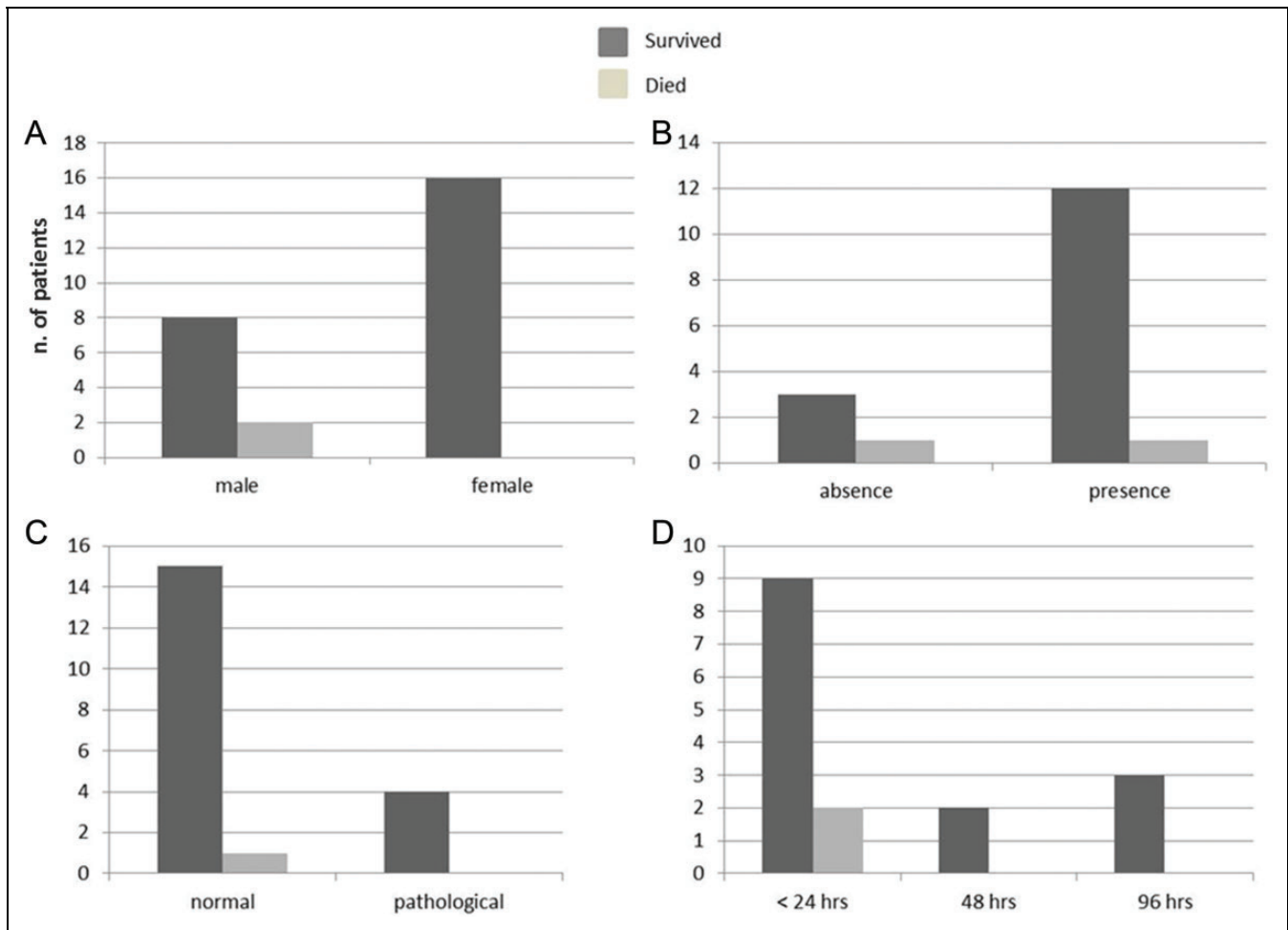
Recently, the role of gender-based mechanisms contributing to the association between TTC and sepsis has been discussed in the literature.<sup>57</sup> Here, the authors report that although TTC is more prevalent in women and the great majority of the reported clinical cases had a favorable outcome, a possible gender effect in clinical outcome, especially on IHM in the presence of sepsis, could be possible and should be taken into account.<sup>57</sup> As support for this theory, Brinjikji et al,<sup>53</sup> in their study on 24 701 cases with TTC (89.0% women), showed that male patients had a higher mortality rate than women (11.0% vs 6.5%), and those with sepsis as well (24.9% vs 20.8%). Moreover, Isogai et al,<sup>52</sup> in a study carried out on 3719 patients, demonstrated that patients with in-hospital TTC had a higher proportion of men than out-of-hospital patients with TTC (31.3% vs 21.3%). In conclusion, although TTC mostly affects women, men seem to be exposed to a worst clinical outcome and higher IHM in the presence of sepsis.

### Possible Mechanisms of Sepsis-Related TTC

The pathophysiology of sepsis-induced TTC is complex. Four major hypotheses on the pathogenesis have been discussed in the literature; these could be defined as:

1. The role of sepsis-induced systemic inflammation, which mediators of inflammation and products of microbial derivation could lead to myocardial dysfunction.<sup>40</sup>
2. The role of cardiac catecholamine toxicity.<sup>40</sup>
3. Exogenous administration of catecholamines in patients having septic shock.<sup>32</sup>
4. Myocardial ischemia resulting from inadequate coronary blood flow during sepsis.<sup>32</sup>

There are data suggesting that tumor necrosis factor  $\alpha$  and interleukin (IL) 1 $\beta$  and possibly other cytokines involved in septic shock, which potentially mediate the myocardial depression in septic shock by several mechanisms.<sup>58</sup> For example, these may act as powerful trigger factors for TTC induction through activation of the local cardiac sympathetic nervous system leading to disruption of the cardiac sympathetic nerve terminals and causing noradrenaline spillover.<sup>32</sup> Our group



**Figure 4.** Frequency of outcome (survived vs died) in patients with takotsubo cardiomyopathy in relation with (A) sex, (B) risk factors (absence or presence), (C) results obtained from the coronary angiography, and (D) time interval of takotsubo presentation from admission.

demonstrated that IL-6 was the cardiodepressant factor in sepsis, acting via the myocardial depressant p38 mitogen-activated protein kinase pathway that is common in patients with takotsubo syndrome.<sup>59-61</sup> In both sepsis and TTC, we had suggested that the cardiodepression was linked to cardioprotective anti-apoptotic/antiarrhythmic Gi-mediated signaling cascade.

With regard to the role of endogenous and exogenous (eg, infusion of epinephrine or norepinephrine as a therapeutic intervention) catecholamines in triggering TTC, their role is well known in nonsepsis-induced TTC population<sup>62,63</sup>; this model could also be used to explain the sepsis-induced TTC. Indeed, sepsis produces an overstimulation of the sympathetic nervous system and subsequent high levels of catecholamine plasma levels. This would precipitate the  $\beta_2$  adrenoceptor-Gs to Gi switch to result in takotsubo syndrome myocardial depression.<sup>60</sup> We had considered the possibility that patients with takotsubo sepsis might be “inotrope-unresponsive” patients who had been given excess adrenaline. Such a mechanism, however, may not be predominant in these patients as many would have already been having TTC before being admitted to an inotropic support environment (such as an

intensive care unit). Summarizing, sepsis-induced inflammation and related cytokines, high endogenous catecholamine production, and the administered exogenous catecholamines can be seen as triggering factors for inducing TTC through activation of sympathetic nervous system.<sup>32</sup>

The pathophysiologic mechanisms involved in catecholamine-induced cardiac toxicity may depend on inflammation, oxidative stress, and abnormal calcium handling, resulting in myocardial stunning, apoptosis, and necrosis.<sup>57</sup>

### Reverse Takotsubo and Sepsis

Reverse TTC is a more recently recognized variant of the TTC where, in the regional wall, motion abnormalities are localized to the basal segments with hyperkinetic apical segments. From our review, we described a case of a 41-year-old woman with an echocardiogram diagnosis compatible with reverse TTC.<sup>19</sup> Also, for the reverse TTC, the clinical presentation may be indistinguishable from acute coronary syndrome and may include symptoms of chest pain, dyspnea, ECG changes of ischemia or acute MI, and elevated cardiac and hemodynamic biomarkers.

In order to explain this variant, it has been hypothesized that variations in the density of adrenoceptors on the myocardium account for the changes in the distribution of the wall motion abnormalities. Indeed, a greater density of adrenoceptors in the base may result in reverse TTC, whereas increased apical distribution results in classic TTC. Furthermore, it has been suggested that the adrenoceptor density shifts with age from the base to the apex of the heart.<sup>64</sup> Reverse TTC also differs from the classic form with respect to its hemodynamic and biochemical profile. Indeed, reverse TTC is usually associated with higher levels of cardiac biomarkers, perhaps due to the larger area of myocardial involvement compared to the apical variant. Despite this, we have not observed higher level of cardiac biomarkers in the case of reverse TTC reported by Lee et al.<sup>19</sup>

### Limitations

The present review has several limitations: first, only case reports and case series on patients with TTC associated with sepsis were screened; second, many papers only provided partial data about the characteristics of patients and adopted procedures. The findings of this report must be substantiated in larger studies, and until then the displayed information should be regarded as hypothesis-generating observations.

### Implications of the Study and Directions for Future Research

Our main aim of this study was to address the knowledge gap of almost total lack of research evidence on the relation between sepsis and TTC.

This study offers the opportunity to refine and validate some important concepts and theories. For example, the idea of an association between sepsis and subsequent onset of TTC will need further refinement and in-depth studies in terms of both the microorganisms involved and the exact pathological mechanisms involved. In the same way, future research should emphasize the high frequency of false acute coronary syndrome diagnosis and how to early recognize these 2 different pathologies; this is particularly important in terms of their differential outcomes and treatments.

Furthermore, noteworthy is the necessity to avoid the great amount of negative invasive examinations, such as coronary angiography, that are routinely carried out in these patients; the nonnegligible cost of such examinations, the potential risk of in-hospital complication related to the unnecessary procedures, and the following medicolegal problem that could arise should also be taken into account.

### Conclusion

Although the association between cardiomyopathy and sepsis has been debated in previous papers, this systematic review represents the greatest cohort of cases with sepsis-induced TTC in the literature.

Findings obtained from our study further support the role of catecholamines in the etiology of sepsis-induced TTC. It also

highlights its benign course and its prevalence among females. There was insufficient data to suggest any gender-related effects on outcome, although recent studies have highlighted that men seemed to have a worse clinical outcome and higher IHM in the presence of sepsis. For this reason, male patients suspected for sepsis-induced TTC should be carefully monitored in order to avoid harmful and life-threatening consequences.

Awareness of the relationship between sepsis and TTC is important as it can avoid diagnostic dilemmas, limit inappropriate examinations, and allow timely initiation of supportive medical therapy. A better understanding of the mechanisms of sepsis-associated TTC may aid in the generation of novel strategies to treat the complications of this potentially lethal disease and may even help predict and prevent its occurrence in patients most at risk of this specific cardiomyopathy.

### Authors' Note

All authors contributed substantially to (1) conception and design, acquisition of data, or analysis and interpretation of data, (2) drafting the article or revising it critically for important intellectual content, and (3) final approval of the version to be published.

### Declaration of Conflicting Interests

The author(s) declared no potential conflicts of interest with respect to the research, authorship, and/or publication of this article.

### Funding

The author(s) received no financial support for the research, authorship, and/or publication of this article.

### References

1. Maron BJ, Towbin JA, Thiene G, et al. Contemporary definitions and classification of the cardiomyopathies: an American Heart Association Scientific Statement from the Council on Clinical Cardiology, Heart Failure and Transplantation Committee; Quality of Care and Outcomes Research and Functional Genomics and Translational Biology Interdisciplinary Working Groups; and Council on Epidemiology and Prevention. *Circulation*. 2006; 113(14):1807-1816.
2. Elliott P, Andersson B, Arbustini E, et al. Classification of the cardiomyopathies: a position statement from the European Society of Cardiology Working Group on Myocardial and Pericardial Diseases. *Eur Heart J*. 2008;29(2):270-276.
3. Sato H, Tateishi H, Uchida T. Takotsubo-type cardiomyopathy due to multivessel spasm. In: Kodama K, Haze K, Hon M, eds. *Clinical Aspect of Myocardial Injury from Ischemia to Heart Failure*. Tokyo, Japan: Kagakuhyouronsya; 1990:56-64.
4. De Giorgi A, Fabbian F, Pala M, et al. Takotsubo cardiomyopathy and acute infectious diseases: a mini-review of case reports. *Angiology*. 2015;66(3):257-261.
5. Porto I, Della Bona R, Leo A, et al. Stress cardiomyopathy (takotsubo) triggered by nervous system diseases: a systematic review of the reported cases. *Int J Cardiol*. 2013;167(6):2441-2448.

6. Bybee KA, Kara T, Prasad A, et al. Systematic review: transient left ventricular apical ballooning: a syndrome that mimics ST-segment elevation myocardial infarction. *Ann Intern Med.* 2004;141(11):858-865.
7. Prasad A, Lerman A, Rihal CS. Apical ballooning syndrome (Tako-Tsubo or stress cardiomyopathy): a mimic of acute myocardial infarction. *Am Heart J.* 2008;155(3):408-417.
8. Sharkey SW, Lesser JR, Zenovich AG, et al. Acute and reversible cardiomyopathy provoked by stress in women from the United States. *Circulation.* 2005;111(4):472-479.
9. Sharkey SW, Windenburg DC, Lesser JR, et al. Natural history and expansive clinical profile of stress (tako-tsubo) cardiomyopathy. *J Am Coll Cardiol.* 2010;55(4):333-341.
10. Sinning Ch, Keller T, Abegunewardene N, Kreitner KF, Münzel T, Blankenberg S. Tako-Tsubo syndrome: dying of a broken heart? *Clin Res Cardiol.* 2010;99(12):771-780.
11. Chidiac TA, Salon JE. Left ventricular segmental wall motion abnormality in septic shock. *Crit Care Med.* 1995;23(3):594-598.
12. Greco C, Saolini M, Mariani S, et al. Tako-tsubo syndrome: a potential role for cytomegalovirus infection. *J Cardiovasc Med (Hagerstown).* 2006;7(8):623-627.
13. Cattaneo P, Marchetti P, Morandi F, Salerno-Uriarte JA. Left ventricular apical ballooning in mitral endocarditis. *Int J Cardiol.* 2007;119(2):261-263.
14. Bigalke B, Klingel K, May AE, Kandolf R, Gawaz MG. Human herpesvirus 6 subtype A-associated myocarditis with 'apical ballooning'. *Can J Cardiol.* 2007;23(5):393-395.
15. Ohigashi-Suzuki S, Saito Y, Tatsuno I. Takotsubo cardiomyopathy associated with sepsis in type 2 diabetes mellitus. *Am J Emerg Med.* 2007;25(2):230-232.
16. Geng S, Mullany D, Fraser JF. Takotsubo cardiomyopathy associated with sepsis due to *Streptococcus pneumoniae* pneumonia. *Crit Care Resusc.* 2008;10(3):231-234.
17. Palacio C, Nugent K, Alalawi R, Cevik C. Severe reversible myocardial depression in a patient with *Pseudomonas aeruginosa* sepsis suggesting tako-tsubo cardiomyopathy. *Int J Cardiol.* 2009;135(1):e16-e19.
18. Sarullo FM, Americo L, Accardo S, et al. Tako-tsubo cardiomyopathy observed in a patient with sepsis and transient hyperthyroidism. *Monaldi Arch Chest Dis.* 2009;72(1):33-36.
19. Lee S, Lee KJ, Yoon HS, Kang KW, Lee YS, Lee JW. Atypical transient stress-induced cardiomyopathies with an inverted Takotsubo pattern in sepsis and in the postpartal state. *Tex Heart Inst J.* 2010;37(1):88-91.
20. Tanriver Y, Betz MJ, Nibbe L, Pfluger T, Beuschlein F, Strowski MZ. Sepsis and cardiomyopathy as rare clinical manifestations of pheochromocytoma—two case report studies. *Exp Clin Endocrinol Diabetes.* 2010;118(10):747-753.
21. Hassan S, Hassan F, Hassan D, Hassan S, Hassan K. Takotsubo cardiomyopathy associated with peritonitis in peritoneal dialysis patient. *Ren Fail.* 2011;33(9):904-907.
22. Odigie-Okon E, Okon E, Dodson J, Vorobiof G. Stress-induced cardiomyopathy complicating severe babesiosis. *Cardiol J.* 2011;18(1):83-86.
23. Okumura K, Shoji F, Yoshida M, Mizuta A, Makino I, Higashi H. Severe sepsis caused by *Aeromonas hydrophila* in a patient using tocilizumab: a case report. *J Med Case Rep.* 2011;5:499.
24. Yonekawa K, Mussio P, Yuen B. Ischemic cerebrovascular stroke as complication of sepsis-induced Takotsubo cardiomyopathy. *Intern Emerg Med.* 2011;6(5):477-478.
25. Karvouniaris M, Papanikolaou J, Makris D, Zakyntinos E. Sepsis-associated takotsubo cardiomyopathy can be reversed with levosimendan. *Am J Emerg Med.* 2012;30(5):832. e5-e7.
26. Xu RH, Yu DQ, Ma GZ, et al. Takotsubo cardiomyopathy in a 90-year-old Chinese man. *Chin Med J (Engl).* 2012;125(5):957-960.
27. Galea F, Abela GP, Felice H. Takotsubo cardiomyopathy in chronic infection. *Scott Med J.* 2013;58(4):e11-e14.
28. Santoro F, Di Biase M, Brunetti ND. Urinary sepsis associated with Takotsubo cardiomyopathy. *Int J Urol.* 2014;21(4):432-433.
29. Ghonim S, Dubrey SW. Overwhelming infection causing takotsubo syndrome. *Br J Hosp Med (Lond).* 2014;75(4):234-235.
30. Kakroo MA, Chowdhury MA, Luni FK, Moza A, Bhat PK. Reverse Takotsubo cardiomyopathy: a story of a critically ill man with transient cardiac dysfunction. *Cardiology.* 2014;129(4):213-215.
31. Omar HR, Mangar D, Camporesi EM. Urosepsis-induced takotsubo. *Am J Emerg Med.* 2014;32(8):946. e5-e6.
32. Y-Hassan S, Settergren M, Henareh L. Sepsis-induced myocardial depression and takotsubo syndrome. *Acute Card Care.* 2014;16(3):102-109.
33. Heller M, Gelabert C, Preblich C, Habboushe J, Finefrock D. Takotsubo's cardiomyopathy: the spectrum expands. *Am J Emerg Med.* 2015;33(9):1326. e1-e2.
34. Park JH, Kang SJ, Song JK, et al. Left ventricular apical ballooning due to severe physical stress in patients admitted to the medical ICU. *Chest.* 2005;128(1):296-302.
35. El-Sayed AM, Brinjikji W, Salka S. Demographic and co-morbid predictors of stress (takotsubo) cardiomyopathy. *Am J Cardiol.* 2012;110(9):1368-1372.
36. Pullara A, Chinaglia A, Giammaria M, et al. Takotsubo cardiomyopathy: real life management in the intensive coronary care unit. *Minerva Med.* 2013;104(5):537-544.
37. Pankuweit S, Klingel K. Viral myocarditis: from experimental models to molecular diagnosis in patients. *Heart Fail Rev.* 2013;18(6):683-702.
38. Lee YP, Poh KK, Lee CH, et al. Diverse clinical spectrum of stress-induced cardiomyopathy. *Int J Cardiol.* 2009;133(2):272-275.
39. Suzuki H, Matsumoto Y, Kaneta T, et al. Evidence for brain activation in patients with takotsubo cardiomyopathy. *Circ J.* 2014;78(1):256-258.
40. Clemente G, Tuttolomondo A, Colomba D, et al. When sepsis affects the heart: a case report and literature review. *World J Clin Cases.* 2015;3(8):743-750.
41. Pelliccia F, Parodi G, Greco C, et al. Comorbidities frequency in Takotsubo syndrome: an international collaborative systematic review including 1109 patients. *Am J Med.* 2015;128(6):654. e11-e19.
42. Summers MR, Lennon RJ, Prasad A. Pre-morbid psychiatric and cardiovascular diseases in apical ballooning syndrome

- (tako-tsubo/stress-induced cardiomyopathy): potential predisposing factors? *J Am Coll Cardiol*. 2010;55(7):700-701.
43. Yoshikawa T. Takotsubo cardiomyopathy, a new concept of cardiomyopathy: clinical features and pathophysiology. *Int J Cardiol*. 2015;182:297-303.
  44. Núñez-Gil IJ, Luaces M, Garcia-Rubira JC, Zamorano J. Electrocardiographic criteria in Takotsubo cardiomyopathy and race differences: Asians versus Caucasians. *J Am Coll Cardiol*. 2010;56(17):1433-1434.
  45. Guerra F, Rrapaj E, Pongetti G, et al. Differences and similarities of repolarization patterns during hospitalization for Takotsubo cardiomyopathy and acute coronary syndrome. *Am J Cardiol*. 2013;112(11):1720-1724.
  46. Madias JE. Transient attenuation of the amplitude of the QRS complexes in the diagnosis of Takotsubo syndrome. *Eur Heart J Acute Cardiovasc Care*. 2014;3(1):28-36.
  47. Guerra F, Giannini I, Pongetti G, et al. Transient QRS amplitude attenuation is associated with clinical recovery in patients with takotsubo cardiomyopathy. *Int J Cardiol*. 2015;187:198-205.
  48. Nef HM, Möllmann H, Troidl C, Weber M, Hamm C, Elsässer A. Tako-Tsubo cardiomyopathy: NT-proBNP as a reliable parameter of a favourable prognosis? *Int J Cardiol*. 2008;124(2):237-238.
  49. Ahmed KA, Madhavan M, Prasad A. Brain natriuretic peptide in apical ballooning syndrome (takotsubo/stress cardiomyopathy): comparison with acute myocardial infarction. *Coron Artery Dis*. 2012;23(4):259-264.
  50. Sharkey SW, Lesser JR, Menon M, Parpart M, Maron MS, Maron BJ. Spectrum and significance of electrocardiographic patterns, troponin levels, and thrombolysis in myocardial infarction frame count in patients with stress (tako-tsubo) cardiomyopathy and comparison to those in patients with ST-elevation anterior wall myocardial infarction. *Am J Cardiol*. 2008;101(12):1723-1728.
  51. Akashi YJ, Nef HM, Lyon AR. Epidemiology and pathophysiology of takotsubo syndrome. *Nat Rev Cardiol*. 2015;12(7):387-397.
  52. Isogai T, Yasunaga H, Matsui H, et al. Out-of-hospital versus in-hospital takotsubo cardiomyopathy: analysis of 3719 patients in the Diagnosis Procedure Combination database in Japan. *Int J Cardiol*. 2014;176(2):413-417.
  53. Brinjikji W, El-Sayed AM, Salka S. In-hospital mortality among patients with takotsubo cardiomyopathy: a study of the National Inpatient Sample 2008 to 2009. *Am Heart J*. 2012;164(2):215-221.
  54. Citro R, Rigo F, D'Andrea A, et al. Echocardiographic correlates of acute heart failure, cardiogenic shock, and in-hospital mortality in tako-tsubo cardiomyopathy. *JACC Cardiovasc Imaging*. 2014;7(2):119-129.
  55. Schneider B, Athanasiadis A, Stöllberger C, et al. Gender differences in the manifestation of tako-tsubo cardiomyopathy. *Int J Cardiol*. 2013;166(3):584-588.
  56. Lee PH, Song JK, Sun BJ, et al. Outcomes of patients with stress-induced cardiomyopathy diagnosed by echocardiography in a tertiary referral hospital. *J Am Soc Echocardiogr*. 2010;23(7):766-771.
  57. Fabbian F, De Giorgi A, Tiseo R, et al. Takotsubo cardiomyopathy, sepsis and clinical outcome: does gender matter? *Am J Emerg Med*. 2015;33(10):1525-1527.
  58. Krishnagopalan S, Kumar A, Parrillo JE, Kumar A. Myocardial dysfunction in the patient with sepsis. *Curr Opin Crit Care*. 2002;8(5):376-388.
  59. Pathan N, Franklin JL, Eleftherohorinou H, et al. Myocardial depressant effects of interleukin 6 in meningococcal sepsis are regulated by p38 mitogen-activated protein kinase. *Crit Care Med*. 2011;39(7):1692-1711.
  60. Paur H, Wright PT, Sikkell MB, et al. High levels of circulating epinephrine trigger apical cardiodepression in a  $\beta_2$ -adrenergic receptor/Gi-dependent manner: a new model of takotsubo cardiomyopathy. *Circulation*. 2012;126(6):697-706.
  61. Pathan N, Hemingway CA, Alizadeh AA, et al. Role of interleukin 6 in myocardial dysfunction of meningococcal septic shock. *Lancet*. 2004;363(9404):203-209.
  62. Agarwal V, Kant G, Hans N, Messerli FH. Takotsubo-like cardiomyopathy in pheochromocytoma. *Int J Cardiol*. 2011;153(3):241-248.
  63. Abraham J, Mudd JO, Kapur NK, Klein K, Champion HC, Wittstein IS. Stress cardiomyopathy after intravenous administration of catecholamines and beta-receptor agonists. *J Am Coll Cardiol*. 2009;53(15):1320-1325.
  64. Mansencal N, El Mahmoud R, Pillière R, Dubourg O. Relationship between pattern of Tako-Tsubo cardiomyopathy and age: from midventricular to apical ballooning syndrome. *Int J Cardiol*. 2010;138(1):e18-e20.