

## Efficacy of First-Line Sodium Thiosulfate Administration in a Case of Potassium Cyanide Poisoning

Diletta Sabatini<sup>1</sup>, Andrea Giampreti<sup>2</sup>, Paolo Mazzini<sup>3</sup>, Carla Caranti<sup>4</sup>, Antonella Valli<sup>5</sup> and Maria Caterina Grassi<sup>1\*</sup>

<sup>1</sup>Emergency Toxicology and Poison Control Centre Unit, Policlinico Umberto I - "Sapienza" University of Rome, Rome, Italy <sup>2</sup>Pavia Poison Control Centre and National Toxicology Information Centre, Toxicology Unit, IRCCS Maugeri Foundation, Pavia, Italy

<sup>3</sup>Department of Anesthesiology - Intensive Care Unit and

<sup>4</sup>Department of Mental Health, ASL RM B, Ospedale Sandro Pertini, Rome, Italy,

<sup>5</sup>Laboratory of Analytical Toxicology, Clinical Chemistry Service, IRCCS Policlinico San Matteo Foundation, Pavia, Italy

\*Corresponding author: Maria Caterina Grassi, Professor of Pharmacology and Toxicology, Department of Physiology and Pharmacology "V. Erspamer" - Sapienza" University of Rome, School of Medicine, Piazzale Aldo Moro, 500185 Rome, Italy, Tel: +39 335 6188151; Fax: +39 06 4450618; E-mail: [caterina.grassi@uniroma1.it](mailto:caterina.grassi@uniroma1.it)

Received date: Jun 11, 2015; Accepted date: Jun 28, 2015; Published date: Jun 30, 2015

Copyright: ©2015 Sabatini D. This is an open-access article distributed under the terms of the Creative Commons Attribution License, which permits unrestricted use, distribution, and reproduction in any medium, provided the original author and source are credited.

### Abstract

Cyanide poisoning may occur following accidental fire-smoke inhalation or deliberate ingestion of salts. Hydroxocobalamin represents a first-line life-saving antidote. Although hydroxocobalamin represents a first-line life-saving antidote, it is still not promptly available in the emergency department. Sodium thiosulfate can be administered in association with hydroxocobalamin whereas the delayed onset of clinical response makes sodium thiosulfate less suitable for emergency use. We describe a case of cyanide intoxication of a 43-year-old man who ingested an unknown amount of potassium cyanide, purchased via the Internet, in an attempted suicide. At admission to the emergency department, the patient presented GCS 3 with severe lactic acidosis. Orotracheal intubation, gastric lavage and oral activated charcoal were applied. Sodium thiosulfate was available in the emergency department and 10 grams were infused over a 30 minute period. Hydroxocobalamin was prescribed by the poison control centre and 5 grams were infused 2 hours after admission. Following sodium thiosulfate administration the patient was arousable and lactate concentration improved. No adverse effects were noted. Metabolic acidosis completely resolved 12 hours later. Cyanide concentration performed on blood samples collected at admission confirmed high cyanide blood levels (15 mg/L). This report highlights as the first-line administration of sodium thiosulfate, in rapid infusion, resulted effective and safe for cyanide poisoning. Our report suggests that sodium thiosulfate should be considered when hydroxocobalamin is not promptly available in an emergency setting.

**Keywords:** Cyanide salts; Hydroxocobalamin; Sodium thiosulfate; Cyanide antidotes

where the prompt administration of sodium thiosulfate improved clinical outcome and lactic acidosis.

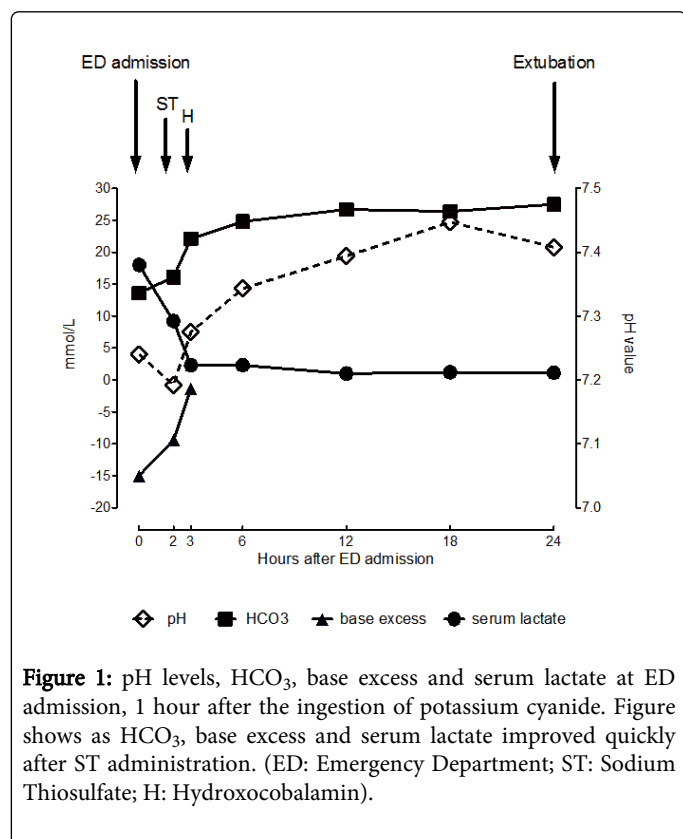
### Introduction

Cyanide is a potent and fast acting poison, available in gaseous forms, poorly water-soluble salts and water-soluble potassium or sodium cyanide salts [1-4]. Cyanide exposure may occur following accidental enclosed fire-smoke inhalation or ingestion of salts. Cyanide ingestion is mainly related to accidental events, deliberate self-harm or attempted homicides [1-4]. The ingestion of a minimal amount of potassium cyanide salts (200-300 mg) may cause death within minutes [1,5]. Furthermore, cyanide intoxication remains a challenging diagnosis since initial symptoms are not specific, and laboratory confirmation is not usually available in an emergency setting [3]. Treatment includes supportive and antidotal therapy. Currently two antidotes have been proposed for empiric therapy in cyanide poisoning: hydroxocobalamin and sodium thiosulfate. Hydroxocobalamin, a precursor of vitamin B12, represents the first-line antidote, owing to its efficacy, safety and scarcity of severe side effects [3,4,6]. Sodium thiosulfate can be administered in association with hydroxocobalamin whereas the delayed onset of clinical response makes sodium thiosulfate less suitable for emergency use [4,6]. We describe a laboratory confirmed case of severe cyanide intoxication following ingestion of potassium salts, purchased on the Internet,

### Case Report

A 43-year-old man (90 kg) was admitted at the Emergency Department (ED) after sudden collapse at work. He had ingested 1 hour before an unknown amount of extra pure potassium cyanide, purchased on the Internet, in an effort to commit suicide. The patient had a history of depressed mood, treated with Paroxetine (40 mg/die), Gabapentin (900 mg/die) and Sodium Valproate (600 mg/die). In addition, he had attempted suicide five months before. At admission, the patient was unresponsive, Glasgow Coma Scale (GCS) 3, with blood pressure 125/70 mmHg and pulse rate 120 beats/min. Areflexic bilateral mydriasis was present. Orotracheal Intubation (IOT) was applied and 50 grams activated charcoal coupled with 30 grams magnesium sulphate were administered after gastric lavage. Fluid resuscitation was started and a bolus of 10 ml/kg crystalloids infused. Arterial Blood Gas (ABG) revealed severe lactic acidosis (pH 7.24, pCO<sub>2</sub> 26.6 mmHg, pO<sub>2</sub> 202 mmHg, HCO<sub>3</sub> 13.6 mmol/L, base excess -15 mmol/L, serum lactate 18 mmol/L, FiO<sub>2</sub> 60%; Figure 1) and blood gas performed on venous blood (collected from external jugular vein) showed venous arterialization (SvO<sub>2</sub> 89.9%, FeO<sub>2</sub> 7.2%). Electrocardiogram demonstrated ventricular conduction delay; brain computed tomography scan and chest X-ray revealed no abnormalities. Blood samples were collected to detect cyanide

concentration. All other laboratory parameters were within the range of normality.



**Figure 1:** pH levels, HCO<sub>3</sub><sup>-</sup>, base excess and serum lactate at ED admission, 1 hour after the ingestion of potassium cyanide. Figure shows as HCO<sub>3</sub><sup>-</sup>, base excess and serum lactate improved quickly after ST administration. (ED: Emergency Department; ST: Sodium Thiosulfate; H: Hydroxocobalamin).

Sodium thiosulfate was available in the ED and 10 grams were infused in 30 minutes. Following sodium thiosulfate administration the patient was arousable and lactate concentration (9.2 mmol/L), as well as base excess (-9.4 mmol/L) and HCO<sub>3</sub><sup>-</sup> (16.1 mmol/L) improved.

Hydroxocobalamin was prescribed and provided by poison control centre and 5 grams subsequently infused 3 hours after ED admission. The patient showed further improvement of acid base balance (pH 7.27, pCO<sub>2</sub> 54.7 mmHg, pO<sub>2</sub> 101 mmHg, HCO<sub>3</sub><sup>-</sup> 22.1 mmol/L, base excess -1.4 mmol/L, serum lactate 2.3 mmol/L, FiO<sub>2</sub> 50%), SvO<sub>2</sub> 65.2% FeO<sub>2</sub> 31%, and was fully responsive to verbal stimuli and orders. The patient was moved to intensive care unit; fluid therapy and mechanical ventilation were performed (10 ml/kg crystalloids infused and FiO<sub>2</sub> 50%); acid-base balance continually controlled. Metabolic acidosis completely resolved 12 hours later (pH 7.39, pCO<sub>2</sub> 44.7 mmHg, pO<sub>2</sub> 164 mmHg, HCO<sub>3</sub><sup>-</sup> 26.7 mmol/L, serum lactate 1.2 mmol/L), no additional episodes of lactic acidosis were noted and IOT was removed 24 hours from ED admission. Laboratory findings showed cyanide serum concentrations of 15 mg/L at admission, declined to 0.2 mg/L 24 hours later. The patient remained neurologically intact and haemodynamically stable throughout the hospital stay. Four days later, he was moved to the psychiatric department and discharged asymptomatic 9 days later.

## Discussion

Cyanide poisoning is a life-threatening condition. Its lethality is related to the rapid onset of toxicity and lack of pathognomonic symptoms [4]. Furthermore blood cyanide concentration should be

detected to confirm the poisoning, therefore delaying the diagnosis [3,4]. The first line treatment is frequently based on clinical features and circumstantial evidence [3,4].

Cyanide exerts its toxicity by binding to cytochrome c oxidase a<sub>3</sub>, causing a cytotoxic hypoxia [2-4,7]. As a result the aerobic respiration is paralyzed with a buildup of lactate in mitochondria and rapid impairment of vital functions [2-4,7]. Clinical features include loss of consciousness, respiratory abnormalities, cardiovascular dysfunction, and severe hypotension progressing rapidly to cardio-respiratory arrest [2,5-7]. In this frame, diagnosis of cyanide poisoning requires a careful correlation of the patient medical history, physical examination, and laboratory findings as severe lactate acidosis with increased anion gap [6]. Treatment includes supportive treatment and antidotal therapy [6].

Gastric lavage and cathartics aimed to remove any remaining cyanide salts in the gastrointestinal tract should be started as soon as possible. Although its usefulness may be questionable, the prompt administration of activated charcoal dose may reduce potassium cyanide absorption [8]; simultaneously, high flow oxygen should be administered and metabolic acidosis treated with bicarbonate [2,5-7].

Currently several antidotes, with differing mechanisms of action, are available [4,6,7,9]. Hydroxocobalamin is the first-line antidote in case of cyanide exposure. Its action consists in chelating cyanide to form cyanocobalamin, which is excreted in urine [4,6,9]. Moreover, hydroxocobalamin does not interfere with tissue oxygenation, improving the hemodynamic stability of the patients admitted in ED in shock or with hypotension [9]. Sodium thiosulfate reduces cyanide toxicity by converting cyanide into the nontoxic thiocyanate through the action of the enzyme rhodanase [2,4]. Conflicting results on the efficacy of sodium thiosulfate arise from studies conducted in animals and the efficacy of sodium thiosulfate is based on case reports [4]. Indeed, although it has been shown that sodium thiosulfate infusion accelerates the conversion of cyanide to thiocyanate by rhodanase enzyme, the slow onset of such effect suggests that sodium thiosulfate may have a preventive, more than a curative, function [4]. Thiosulfate provides a delayed but lasting and reliable effect, therefore continuous infusion associated with hydroxocobalamin is recommended [4,6,9,10]. Currently, there are no clinical trials comparing the efficacy of combining hydroxocobalamin and sodium thiosulfate versus the administration of one of these treatments alone [10]. However the rapid infusion of sodium thiosulfate immediately after hydroxocobalamin could decrease the effectiveness of the treatment due to the formation of thiosulfate-cobalamin unable to bind cyanide [10]. In this case several factors contributed to a favourable outcome: patient's history and ABG findings allowed a rapid diagnosis, the high body-weight of the patient and the possibility to administer both sodium thiosulfate and hydroxocobalamin. Anyway, following sodium thiosulfate administration both the neurological deficits and lactic acidosis improved rapidly. In particular first administration of sodium thiosulfate was able to rescue cyanide toxicity in presence of higher blood cyanide levels than those reported in medical literature and no adverse effects were noted [9]. A rapid schedule of infusion (less than 30 minutes) was tolerable and could have played a role in enhancing the clinical response to sodium thiosulfate alone.

## Conclusion

In conclusion, the efficacy of sodium thiosulfate is based on individual case reports [9,10]. Currently, the first line administration

of sodium thiosulfate is recommended in mild or moderate poisonings [10]. This case highlights as sodium thiosulfate, in rapid infusion, could be considered an early first-line efficacious treatment in cyanide poisonings.

## References

1. Musshoff F, Kirschbaum KM, Madea B (2011) An uncommon case of a suicide with inhalation of hydrogen cyanide. *Forensic Sci Int* 204: e4-7.
2. Reade MC, Davies SR, Morley PT, Dennett J, Jacobs IC; Australian Resuscitation Council (2012) Review article: management of cyanide poisoning. *Emerg Med Australas* 24: 225-238.
3. Coentrão L, Moura D (2011) Acute cyanide poisoning among jewelry and textile industry workers. *Am J Emerg Med* 29: 78-81.
4. Hall AH, Dart R, Bogdan G (2007) Sodium thiosulfate or hydroxocobalamin for the empiric treatment of cyanide poisoning? *Ann Emerg Med* 49: 806-813.
5. Lee-Jones M, Bennett MA, Sherwell JM (1970) Cyanide self-poisoning. *Br Med J* 4: 780-781.
6. Mégarbane B, Delahaye A, Goldgran-Tolédano D, Baud FJ (2003) Antidotal treatment of cyanide poisoning. *J Chin Med Assoc* 66: 193-203.
7. Petrikovics I, Budai M, Kovacs K, Thompson DE (2015) Past, present and future of cyanide antagonism research: From the early remedies to the current therapies. *World J Methodol* 5: 88-100.
8. Chyka PA, Seger D, Krenzelok EP, Vale JA; American Academy of Clinical Toxicology; European Association of Poisons Centres and Clinical Toxicologists (2005) Position paper: Single-dose activated charcoal. *Clin Toxicol (Phila)* 43: 61-87.
9. Hall AH, Saiers J, Baud F (2009) Which cyanide antidote? *Crit Rev Toxicol* 39: 541-552.
10. Zakharov S, Vaneckova M, Seidl Z, Diblik P, Kuthan P, et al. (2015) Successful Use of Hydroxocobalamin and Sodium Thiosulfate in Acute Cyanide Poisoning: A Case Report with Follow-up. *Basic Clin Pharmacol Toxicol*.