



Contents lists available at ScienceDirect

## International Journal of Surgery Case Reports

journal homepage: [www.casereports.com](http://www.casereports.com)

## Schwannoma of the descending loop of the hypoglossal nerve: Case report



Giulio Illuminati\*, Giulia Pizzardi, Rocco Pasqua, Piergaspare Palumbo, Francesco Vietri

The Department of Surgical Sciences, The University of Rome "La Sapienza", Rome, Italy

## ARTICLE INFO

## Article history:

Received 21 February 2017

Received in revised form 27 February 2017

Accepted 4 March 2017

Available online 7 March 2017

## Keywords:

Case report

Schwannoma

Hypoglossal nerve

Descending loop

## ABSTRACT

**INTRODUCTION:** Schwannomas of the descending loop of the hypoglossal nerve are very rare. They are slow-growing tumors that may masquerade a carotid body tumor.

**PRESENTATION OF CASE:** A 60-year-old female was referred for a latero-cervical mass appearing as a chemodectoma at CT-scan. At operation, a 2 cm mass arising from the descending loop of the hypoglossal nerve was resected en bloc with the loop itself and a functional lymphadenectomy was associated. Post-operative course was uneventful and the patient is free from disease recurrence at one year follow-up.

**DISCUSSION:** En bloc resection remains the real curative treatment of Schwannomas, ensuring unlimited freedom from disease, although causing functional impairment which may be significant. Nonetheless recurrence should be prevented as, beside requiring reintervention, it may harbor a malignant evolution towards sarcoma.

**CONCLUSION:** Schwannomas of the descending loop of the hypoglossal nerve may masquerade a chemodectoma of the carotid bifurcation and can be curatively resected without any functional impairment.

© 2017 The Author(s). Published by Elsevier Ltd on behalf of IJS Publishing Group Ltd. This is an open access article under the CC BY-NC-ND license (<http://creativecommons.org/licenses/by-nc-nd/4.0/>).

## Introduction

Schwannomas are benign, slow-growing tumors of the neural sheath, which may affect cranial, sympathetic and peripheral nerves [1–3]. Extracranial and neck region are affected in 25–45% of the cases [2,4], whereas Schwannomas arising from the descending loop of the hypoglossal nerve are extremely rare [5]. According to the SCARE criteria [6], the case of a Schwannoma of the descending loop of the hypoglossal nerve, masquerading a tumor of the carotid body and treated with curative resection is reported herein.

## Case report

A 60-year-old woman was referred for a non-tender, latero-cervical mass enlarging within a month, without pain, dysphagia, dysarthria or any other symptom. At physical examination the mass measured about 2 cm diameter, was non pulsating and fixed on the deeper planes. Overlying skin was normal and no deviation, fasciculation or hemiatrophy of the tongue upon protrusion was observed. No lymph nodes were palpable. At cervical ultrasound examination (US), it appeared solid, homogeneous and located between the internal (ICA) and external (ECA) carotid arteries, with normal flow velocities in both of them. CT-scan showed a round, homogeneous mass of 1.5 cm extending for 1.5 cm in height and depth, arising

1 cm distally to the carotid artery bifurcation apparently adherent to both ICA and ECA, suggestive of chemodectoma (Fig. 1). A fine needle aspiration biopsy was not performed, due to the risk of inadvertent arterial puncture and the sufficiently clear imaging indicating surgical excision in any case. At surgery, access was gained through a standard pre-sternocleidomastoid incision. The common carotid artery (CCA), ICA and ECA were controlled at distance from the mass and the hypoglossal nerve was identified and exposed along all its course crossing the carotid bifurcation. Systemic heparinization was performed (50 IU of sodium heparin/kg of body weight, not reversed at the end of operation). The mass was well delimited and capsulated, arose from the descending branch of the hypoglossal nerve and was easily detached from the ICA and ECA. En bloc resection of the mass together with the descending branch of the hypoglossal nerve and a functional neck lymphadenectomy was performed (Fig. 2). Pathologic examination showed a well-differentiated schwannoma. The patient made an uneventful recovery and was discharged home on post-operative day 2. Regular controls, both clinical and with cervical US every 6 months on an outpatient basis were programmed. She is well and free from any disease recurrence at one year follow-up.

## Discussion

Schwannomas of the vagus and hypoglossal nerve are known to potentially masquerade a tumor of the carotid body at preoperative imaging, due to the close situation of these structures [7–11].

\* Corresponding author at: Via Vincenzo Bellini 14, 00198 Rome, Italy.  
E-mail address: [giulio.illuminati@uniroma1.it](mailto:giulio.illuminati@uniroma1.it) (G. Illuminati).

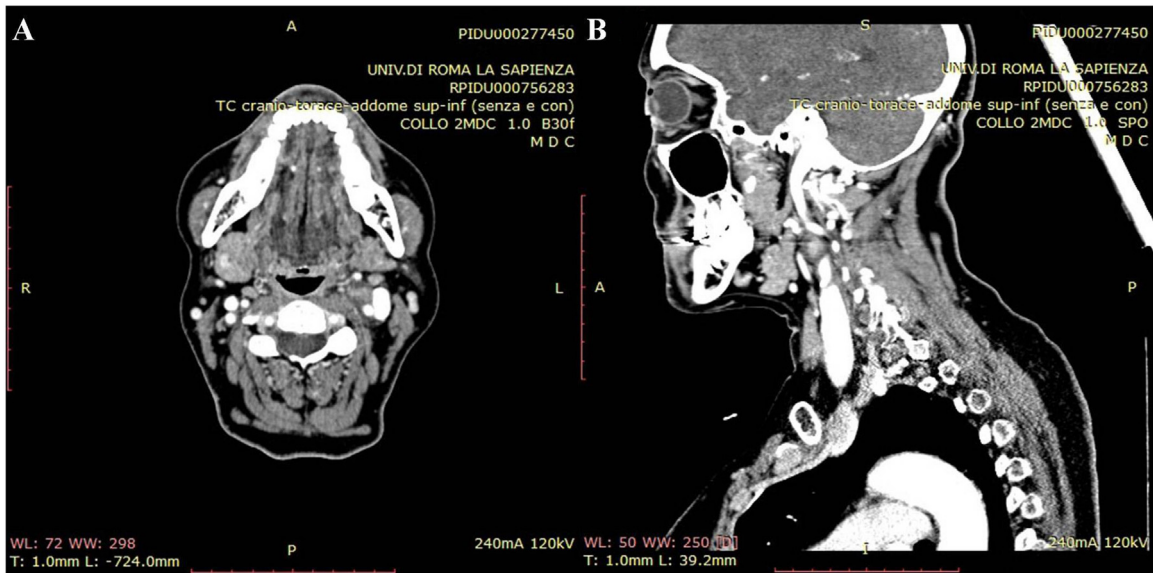


Fig. 1. CT-scan of the neck showing a mass arising 2 cm above the carotid bifurcation, displacing internal and external carotid arteries.

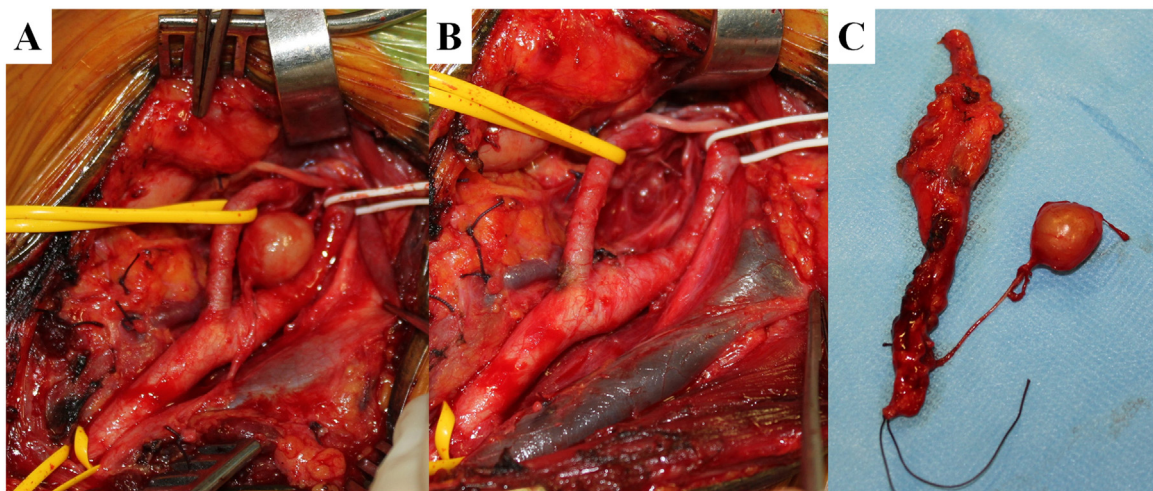


Fig. 2. Intraoperative picture showing a mass arising from the descending loop of the hypoglossal nerve displacing, but not adhering to the internal and external carotid arteries (A). The surgical field after curative resection and functional lymphadenectomy (B). The resected specimen together with latero-cervical lymphatics (C).

However, true Schwannomas arising from the hypoglossal nerve are usually associated with hemiatrophy, fasciculation and deviation of the tongue upon protrusion [10], which can be rarely caused also by Schwannomas of the cervical vagus nerve [11], whereas carotid body tumors are almost never associated with such symptoms. Schwannomas of the descending branch of the hypoglossal nerve should be neurologically asymptomatic, until compression of adjacent cranial nerves occurs, given the absence of functional actions of the descending branch itself, which was the case in this presentation. However, as well as tumors arising from the hypoglossal and vagus nerve, they may masquerade a carotid body tumor at diagnostic imaging. This too occurred in the case object of this report. As for Schwannomas arising from other cranial nerves, excision of the mass “en bloc” with the whole nerve is the best option in order to achieve a curative treatment [1], given that, limited to the descending loop of the hypoglossal nerve, this purpose can be reached without any functional impairment. The need for a curative resection is supported by the opportunity of avoiding a redo operation in case of recurrence and by the possibility that both

primary and recurrent Schwannomas may potentially show an evolution towards sarcoma [1,8,12–14]. Technical tips of the reported case include the standard access through a presternocleidomastoid incision, as for a standard carotid endarterectomy, a separate control of CCA, ECA and ICA together with systemic heparinization, should the need for clamping of the carotid bifurcation arise. For large masses, extending high, above C1, as anticipated at preoperative imaging, nasal intubation should be considered, in order to gain sufficient exposure toward the base of the skull and for gaining safe control of the distal ICA. Due to its anatomical situation and to the small diameter of the Schwannoma reported herein, this adjunct maneuver was, obviously, not necessary. No matter from which nerve the Schwannoma arises, regular controls, both clinical and US, on a 6-month basis for at least the first 3 years, then on a yearly basis, are strongly advised, in order to promptly detect and treat any eventual recurrence, although this is expected to be extremely rare after a proper curative resection.

In conclusion, existing literature on this matter is limited to one previously reported case, and this report adds that prompt

resection of even small masses involving the carotid bifurcation is always indicated in order to obtain the maximum possibilities of a durable cure, limiting at maximum functional impairment.

#### Conflicts of interest

No conflicts of interest to disclose.

#### Funding

No sources of funding other than regular institutional funds.

#### Ethical approval

No institutional ethical approval is required for case reports.

#### Consent

Since identification of the patient from submitted material is not possible, written consent for publication was not obtained.

#### Author contributions

Giulio Illuminati: Study concept, data analysis, writing the paper  
 Giulia Pizzardi: Data collection and data analysis  
 Rocco Pasqua: Data collection and data analysis  
 Piergaspare Palumbo: Data analysis and critical review of manuscript  
 Francesco Vietri: Data analysis and critical review of manuscript

#### Guarantor

Giulio Illuminati.

#### References

- [1] G. Illuminati, G. Pizzardi, A. Minni, F. Masci, B. Ciamberlano, R. Pasqua, et al., Superiority of resection over enucleation for schwannomas of the cervical vagus nerve: a retrospective cohort study of 22 consecutive patients, *Int. J. Surg.* 29 (2016) 74–78.
- [2] R. Yasumatsu, T. Nakashima, R. Miyazaki, Y. Segawa, S. Komune, Diagnosis and management of extracranial head and neck schwannomas: a review of 27 cases, *Int. J. Otolaryngol.* 2013 (2013) 973045.
- [3] M.P. Colreavy, P.D. Lacy, J. Huges, D. Bouchier-Hayes, P. Brennan, A.J. O'Dwyer, et al., Head and neck schwannomas – a 10 year review, *J. Laryngol. Otol.* 114 (2000) 119–124.
- [4] B.S. Ducatman, B.W. Scheithauer, D.G. Piepgras, H.M. Reiman, D.M. Ilstrup, Malignant peripheral nerve sheath tumors: a clinicopathologic study of 120 cases, *Cancer* 15 (1986) (57–21).
- [5] M.A. Morey Mas, J.I. IriarteOrtabe, J. CaubetBaiyna, H.A. Hamdan, Neurinoma of the descending loop of the hypoglossal nerve: report of a case, *An. Otorrinolaringol. Ibero Am.* 28 (2001) 523–529.
- [6] R.A. Agha, A.J. Fowler, A. Saetta, I. Barai, S. Rajmohan, D.P. Orgill, the SCARE Group, The SCARE statement: consensus-based surgical case report guidelines, *Int. J. Surg.* 34 (2016) 180–186.
- [7] P.P. Suthar, K.A. Mistry, P. Rajan, P. Ankit, C. Mehta, Isolated hypoglossal nerve Schwannoma: an uncommon presentation of Schwannoma, *J. Clin. Diagn. Res.* 9 (2015) T101–T102.
- [8] R.M. Lee, C.P. Ong, A.S. Jacobsen, M.Y. Chan, W.S. Hwang, Malignant peripheral nerve sheath tumor mimicking carotid body tumor—case report and review, *J. Pediatr. Surg.* 46 (2011) 554–558.
- [9] M.K. Lee, D.R. Sidell, A.H. Mendelsohn, K.E. Blackwell, Hypoglossal schwannoma masquerading as a carotid body tumor, *Case Rep. Otolaryngol.* 2012 (2012) 842761.
- [10] D. Biswas, C.N. Marnane, R. Mal, D. Baldwin, Extracranial head and neck schwannomas—a 10 year review, *Auris Nasus Larynx* 34 (2007) 353–359.
- [11] G. Rallis, K. Mourouzis, C. Maltezos, P. Stathopoulos, Hemiatrophy of the tongue caused by an extensive vagus nerve schwannoma masquerading as a carotid chemodectoma, *J. Maxillofac. Oral Surg.* 14 (2015) 366–369.
- [12] V. Mahajan, S. Rao, P. Gupta, M. Munjal, S. Agrawal, Angiosarcoma developing in a vagal schwannoma: a rare case report, *Head Neck Pathol.* 9 (2015) 405–411.
- [13] H.L. Liu, S.Y. Yu, G.K. Li, W.I. Wei, Extracranial head and neck Schwannomas: a study of the nerve of origin, *Eur. Arch. Otorhinolaryngol.* 268 (2011) 1343–1347.
- [14] A. Ziadi, I. Saliba, Malignant peripheral nerve sheath tumor of intracranial nerve: a case series review, *Auris Nasus Larynx* 37 (2010) 539–545.

#### Open Access

This article is published Open Access at [sciedirect.com](http://sciedirect.com). It is distributed under the [IJSCR Supplemental terms and conditions](#), which permits unrestricted non commercial use, distribution, and reproduction in any medium, provided the original authors and source are credited.