

Quality of Life in Patients Rehabilitated with Palatal Obturator without Reconstruction Versus Fixed Implant-Prosthesis after Reconstruction of Maxillectomy Defects

Pompa G. *, Brauner E., Jamshir S., De Angelis F., Giardino R., Di Carlo S.

1. Department of Odontostomatologic and Maxillofacial Sciences Sapienza University of Rome / Italy.

Abstract

The rehabilitation of head and neck oncological patients is a very difficult and a multidisciplinary approach are necessary. The rehabilitation of the maxilla was accomplished with a palatal obturator without reconstruction or fixed implant-prosthesys. The aim of this work is to compare quality of life in patients rehabilitated through a palatal obturator and/or a fixed implant-prosthesis.

68 patients with surgical maxillary resection were rehabilitated between 2008 and 2016. 47 patients rehabilitated with an implant fixed prosthesis (group A), while 21 subjects with a palatal obturator (group B). All the patients has been interviewed through two questionnaires to evaluate the quality of life related to the two procedures: Visual Analogue Scale (VAS) and the Oral Health Impact Profile –14 (OHIP–14). Visual Analogue Scale shows suggest how the obturator solution could reach some just limited success; only a small number of cases turns out to be completed positively, since the mean score was 6,4 in values range from 4 to 7.

Positive impact of implant fixed prosthesis was evident at OHIP–14, in terms of patients life habits, and confirmed that fixed implant-prostheses represent best solution for rehabilitation in head and neck oncologic patients.

Clinical article (J Int Dent Med Res 2017; 10: (1), pp. 1-8)

Keywords: Maxillectomy, Palatal obturator, Implant prosthesys, OHIP-14, Visual analogue scale.

Received date: 12 December 2016

Accept date: 17 January 2017

Introduction

The unique 3D infrastructure of the maxillary skeleton carries out several tasks. Anatomically, the palate, the alveolus, and the paired maxillary buttresses provide a platform for the dentition and an opposing arch for the mandible. Aesthetically, the maxilla provides support for the orbit and a framework for the nose and midface.

Functionally, the bone allows chewing, swallowing, speech and breathing. Consequently, rehabilitation of oncological patients who have undergone surgical maxillary resection is a very difficult challenge faced in a multidisciplinary approach by prosthodontist, maxillo-facial surgeon and reconstructive surgeon., the complex nature of the maxilla discouraged surgeons from reconstruction, and for this reason restoration of

the maxilla was largely accomplished with a prosthetic obturator¹⁻².

Today, introduction of microvascular free tissue transfer change radically the way to deal with question about rehabilitation. Several kinds of microvascular free flaps have been described for maxillary reconstruction, including the iliac crest, fibula, radial forearm, anterolateral thigh, rectus abdominis myocutaneous, and scapula free flaps³. Each of these alternatives has its own advantages and disadvantages in maxillary reconstruction; on the one hand they provides abundant tissue for reconstruction, the freedom to orient, shape, and inset the flap as required for the specific defect, and the ability for reconstruction to be performed as a single-stage procedure⁴. In addition, transfer of vascularized bone provides the option of dental restoration through use of osseointegrated implants⁵.

On the other hand this solution is rather challenging and associated to longer surgical and recovery times as well as to increased risks for complications. Until a few years ago, rehabilitation was achieved commonly via application of a palatal obturator. Also today, it is

*Corresponding author:

Prof. Giorgio Pompa
Department of Odontostomatologic and Maxillofacial Sciences
Sapienza University of Rome / Italy.
E-mail: giorgio.pompa@uniroma1.it

used since it allows shorter operative time, shorter postoperative hospital stay, and complete visualization of the maxillectomy cavity which simplifies oncologic surveillance⁶. Unfortunately this solution is associated to important disadvantages, too; potential for hypernasal speech, regurgitation of foods and liquids into the nasal cavity, difficulty in maintaining hygiene of the maxillectomy cavity, poor retention and stability, and the need for repeated prosthesis adjustments due to progressive changes in the size and shape of the palatal defect, especially in patients who receive radiation therapy, represent most significant negative aspects⁷⁻⁸⁻⁹.

Today a dispute over the need for reconstruct or not a maxillary defect exists among international authors. This choice affects unavoidably the rehabilitation protocol, since a free tissue harvest makes it possible to applicate an implant-supported fixed prosthesis; otherwise persistence of the post-resection cavity will require a prosthetic obturator for its closure. Oncological resection of maxillae, inevitably leads to negative consequences in anatomical, functional, psychological and social dimensions. Changes of facial morphology, creation of oro-naso-sinusal communication, loss of hard structures, soft tissues and teeth, impaired chewing, swallowing and speech, represent important invalidations for patient life. Therefore complications are established in social and emotional life, with anxiety, depression, behaviour changes, feelings degeneration, compromission of interpersonal relationships, abitudinal habits and working life, and finally decrease of self-esteem. All of these events result in a dramatic impact on the quality of life for such patients, and for this reason being able to investigate on QOL in post-oncological patients makes it possible to know targets for a complete rehabilitation and to reach it. The aim of this work is to compare quality of life in oncological patients undergone maxillectomy and subsequently rehabilitated through a palatal obturator and a fixed prosthesis after surgical reconstruction of defect with rotation flaps or vascularized free flaps.

Materials and methods

In this study 68 patients treated at the department of Implanto-Prosthetic Rehabilitation of Policlinico Umberto I in Rome between 2008

and 2016, are assessed; 60 of them had undergone surgical treatment of maxillectomy at U.O.C of Maxillo-Facial Surgery belonging to Policlinico Umberto I, whereas remaining 8 at other institutes. The sample is composed of 39 male patients and 29 female, with an age between 16 and 75 years. Basic oncologic diseases result malignant in 64 cases and benign in the other 4; among the latter, Ameloblastoma appears in 2 cases, keratocystic odontogenic tumor in 1 case and pleomorphic adenoma in the remaining one. Malignancies are represented by squamous cell carcinomas in 49 cases, mucoepidermoid carcinoma and rare variants of malignant neoplasms of palate minor salivary glands in 12 cases, and finally ameloblastic carcinoma, chondroblastic osteosarcoma and rhabdomyosarcoma in remaining 3 cases. For 38 patients a RT adjuvant or neoadjuvant protocol was planned, while for 17 other an integrated radio-chemotherapy.

In order to organize the sample in a more intuitive way, all patients are classified according a classification system¹⁰ for maxillectomy defects; such classification, with a purely prosthetic meaning, takes as a reference surgical outcome suggesting an acceptable related rehabilitation choice, and furthermore it takes in consideration dental component and biomechanical stability of prosthetic device, so showing an important significance in terms of predictability of treatment. This classification takes into account two parameters: extension/topography of defect and evidence of an oro-naso-antral communication (ONAC); the latter could be persistent, or repaired through a surgical reconstruction. Basing on both the implemented organization of sample according our classification and adopted measure of rehabilitation, all patients are split into two groups: Group A composed by "patients with fixed prosthesis" and Group B composed by "patients with palatal obturator". 47 patients are annexed to the group of surgically reconstructed patients and rehabilitated with an implant fixed prosthesis (group A), while 21 subjects fall within the group of non-reconstructed patients with a palatal obturator for closure of maxillectomy discontinuation (group B). It is important to specify that in 11 cases, before definitive option, patients in group A have been rehabilitated through an intermediate temporary step with prosthetic obturator. (Tab. 1)

In group A, for 13 patients the defect is closed with a temporal myofascial flap, and the remaining 34 have been reconstructed with vascularized free tissue containing-bone transfer. The most widely used has been fibula free flap (FFF) with its 19 cases, followed by deep-circumflex iliac artery flap (DCIA) in 9 cases, osteo-cutaneous radial forearm flap (OCFR) in 3 patients, antero-lateral thigh flap (ALT) in 2 cases and last subscapular system free flap (SSFF) in 1 patient. In all 47 reconstructed patients 216 implants have been planned and placed, instead in group of obturator they have been 64, in accordance with a waiting period of at least 12 months after last session of RT in cases of patients with a history of radiation therapy and 4-6 months after surgical treatment in the remaining subjects as a protocol of "secondary placement" of implants.

The next surgical step of implant exposure and application of healing caps has been realized after 6 months in not irradiated patients and 8 months in irradiated ones. After these times, a minimum of 15 days has been waited to start the final prosthetic steps, with the purpose of ensuring an optimal quality of perimplantar gingiva. At the end of all procedures, each reconstructed patient has been rehabilitated with an implant-supported fixed prosthesis, instead patients with persistence of defect through a tissue-borne palatal obturator. Finally for every patients it has been envisaged a follow-up lasting on average 99,1 months.

All the patients has been interviewed through two questionnaires, aimed to evaluate impact on quality of life related to the two rehabilitation procedures. First of all a Visual Analogue Scale (VAS)¹¹ has been adopted and calibrated on values into a range from "0" to "10", that are extremes which respectively mean "totally dissatisfied" and "completely satisfied"; through this evaluation scale it has been able to measure overall impact of prosthetic obturator on patient quality of life in terms of comfort, chewing, speech, aesthetics, ease to clean, self-esteem level and general satisfaction.

Then all patients have been undergone a second questionnaire, the Oral Health Impact Profile – 14 (OHIP – 14)¹², composed by 14 questions about evaluation of quality of life after rehabilitation with both palatal obturator and fixed prosthesis in relation to seven parameters: functional limitation, physical pain, psychological

discomfort, physical disability, psychological disability, social disability and social handicap. Answers given by all patients for each question are related with the rate of different problems concerning dental and oral health detected in the last year, and they are defined through scores according to the Likert Scale: "0" referred to "never", "1" to "hardly ever", "2" related to "occasionally", "3" to indicate "fairly often", and "4" to express "very often". Overall scores achieved with the questionnaire will be included between the two extremes "0" and "56", where low scores mean a good quality of life and high scores define a poor QOL.

Finally, another question has been included in OHIP questionnaire: "it was worth it realizing the fixed prosthetic rehabilitation?". Through it we have opportunity to evaluate general satisfaction about fixed prosthesis in reconstructed patients.

Results

Visual Analogue Scale (Fig. 1) used for patients rehabilitated through palatal obturator shows intermediate values, mainly suggesting how this solution could reach some just limited success; only a small number of cases turns out to be completed positively. The most favourable parameters have proven to be chewing, with average answer scores about 6,9 in a range from 4 to 8, and ease to clean, thanks to median value of 6,7 in the range 5 to 8.

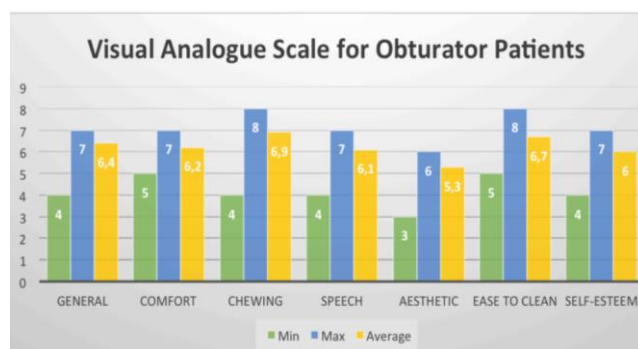


Figure 1. VAS results. For each parameter are reported minimum, maximum and average values based on answers.

Other parameters, concerning comfort, speech and self-esteem have revealed just discrete results, and aesthetics has given more alarming scores, due to average values of 5,3 in a range between 3 and 6. Globally, overall

satisfaction shown by patients about palatal obturator has been disappointing, since the mean score was 6,4 in values range from 4 to 7. A more direct comparison between fixed prosthesis and palatal obturator has been provided with OHIP – 14 questionnaire. We report number and corresponding percentage of patients who to a specific question have answered with a specific response value according to Likert Scale (Tab. 2). Through an analysis based upon distribution of sample in the different available range of results, it is safe to assume how fixed prosthesis in reconstructed patient was clearly more compatible with a good quality of life, if compared to prosthetic obturator applied to rehabilitate non-reconstructed maxillectomy defects. More specifically it may be observed how in group A of patients with fixed device a number of subjects as “zero” (n = 0) or otherwise low percentage in range value “very often” and “fairly often” are more frequent; it indicates that a lesser amount of patient report a high rate of problems following fixed rehabilitation. Positive impact of implant-supported fixed prosthesis on QOL different parameters has turned out so evident, in terms of patients life habits, their satisfaction, their psychologic dimension and social conditions.

On the contrary, in group B of palatal obturator in non-reconstructed patients in over half of questions large percentages of subjects answering a score “4” corresponding to “very often” are found (p > 10%); this evidence confirms functional, psychological, emotional and social difficulties for patients rehabilitated through prosthetic obturator. So alarming it is resulted parameter concerning psychological disability, in which 1 of 4 patients reports total inconveniences. Concerning last added question “it was worth it realizing the fixed prosthetic rehabilitation?”, an important difference in patient answers has been found between under-60 and over-60 patients. In group with younger subjects, answers referred by patients have resulted 10/10, so full satisfaction, for 100% of them. In second group, that one of older subject, we have got answer values from 8/10 to 10/10; these scores are still extremely acceptable, but are proof of an inconvenience for some over-60 patients.

Discussion

Compared to previous years, medical-scientific progress, concept of acceptable

functionality in post-oncological head and neck patients, and the increased importance about aesthetics in the modern age, have led in last two decades to a prevalence of surgical reconstruction procedures for maxillary defects in such patients¹³. However concerning the rehabilitation choice between fixed or removable prosthesis, technical considerations are important, such as implant position, aesthetic result, or psychological considerations like acceptability of a removable prosthesis, and not less important, the economic possibilities¹⁴.

Conventional removable prosthesis after oral mucosa cancer guarantees good control of the mucosa by the operator and at the same time, good hygiene control by the patient⁷⁻⁸⁻⁹. Nevertheless, the reconstructive surgery, even if considered best solution, cannot always guarantee morphology similar to the patient's natural pre-operative condition, particularly after large reconstructions. In these cases, a removable solution can be the best choice in terms of aesthetic and functional results.

Although each rehabilitation technique had benefits and disadvantages, only a small portion of patients undergone maxillectomy is treated with an exclusively prosthetic approach. Actually tooth and/or tissue-borne prosthetic obturators are adopted as a compromise when existence of unfavorable local or general conditions could contraindicate some different options. Anyway it represents a temporary solution which could restore continuity of a defect and quickly rehabilitate usually within 30 days chewing, swallowing, speech quality and harmony of midfacial contours, waiting for a definitive measure. Regardless of reasons that promote a particular choice, palatal obturator is simpler and quicker to be made, and more economic too, so that it can shorten procedure times, offering the opportunity for an immediate and acceptable oro-dental rehabilitation. Its “removable” nature allows clinician to monitor surgical cavity repeatedly and simply by removing device, and make it possible to carry out the necessary clinical exams during follow-up with the aim to intercept a risk of neoplastic relapse. On the other hand the main weakness derived from the use of an obturator are represented by incomplete coverage of a post-surgical oro-naso-antral communication, poor retention and stability of device worsened by overweight which often defines denture, high

frequency of friction against soft tissues caused by continuous instability of device or simply its insertion and removal, and last but not least a high tendency of bacterial plaque to build up over denture surfaces and in interface tissues-prosthesis¹⁵.

An only partial recovery of diaphragm which normally separate oral from naso-antral region is responsible for continuous dispersion of secretions, fluid and solid food, or even just air; the latter phenomenon is the main cause of impairment in speech function, and troubles during respiratory acts too. Precarious retention and stability of a palatal obturator are caused by insufficiency of residual dental support and impossibility of reaching a constant morphological adjustment of denture surfaces in acrylic resin with residual tissues in incessant change. When a partial edentulism is present, device often produces unfavorable forces on residual dentition, damaging it long-term; the total absence of residual teeth make it more problematic biomechanic stability and retention of removable denture, which exclusively rely on hard and soft tissues spared by surgical resection. In addition the gravity force caused by heavy configuration of device that produces a vertical action in contrast with its stability compromises the correct biomechanic features. Such deficits of retention and stability result in too much mobility of inserted prosthesis, which may be source of traumatism and irritation for oral mucosae. The problems patients show in realizing a correct hygiene of residual cavity and prosthetic device imply frequently accumulations of bacterial plaque and food; moreover materials which traditionally characterizes prosthetic obturators form surface of adhesion for microorganisms which populate oral cavity or colonize in an opportunistic way¹⁶.

On the other hand, best advantages shown by using fixed prosthesis are chance to get precise, 3-dimensional and permanent filling of defect, excellent retention and stability, and acceptable restoration of midfacial contours^{16,17}.

Free flaps provide the surgeon an opportunity to deal with the problems associated with prosthetic obturation: nasal leakage, cleaning, and constant prosthetic refinement¹⁸. Dental status has an important bearing on patients' well-being, and the combination of vascularized bone and osteointegrated implants can provide the opportunity for effective oral

rehabilitation. Nevertheless, realization of a surgical reconstruction with vascularized free flaps and a subsequent fixed prosthesis leads to higher surgical times and complexity, more intra and post-operative complications, and a greater surgical stress for patients, if compared with prosthetic obturator^{19,20,21}. Other than that, the evidence of a systemic comorbidities, such as diabetes mellitus or cardiovascular diseases, represents an important contraindication for surgical reconstruction, due to a high risk of losing free flap. Another question concerns the possibility that obliteration of the maxillectomy defect by the free flap may delay the diagnosis of a local recurrence. Fixed prostheses are the best option, because they guarantee stability, but they should be made so that the operator can remove them whenever necessary, to periodically check the health of the oral tissues underneath them, in order to intercept any relapse of tumor²².

Nevertheless the few studies carried out to compare obturators with free flaps reconstructions of maxillary defects have not been able to demonstrate a difference in this terms^{3-4,23}. If on the one hand a removable prosthesis allows a surveillance of surgical cavity through its simple removal, on the other one instrumental and radiological examinations²⁴ are still able to intercept phenomena of neoplastic relapse.

Whatever the selected strategy, in the treatment of both oncological and non-oncological patients, the success of an oral rehabilitation is measured by evaluating different parameters, the most important of which are phonetics, alimentation and aesthetic results²². As pointed out in above questionnaires, fixed prosthesis (group A) is the best solution for achieving these targets if compared with palatal obturator (group B). With the latter measure (group B) the most reported problems were about leakage into the nose on swallowing liquids, dryness of the mouth, difficulties in chewing food, and in pronouncing words, problems with keeping the maxillectomy cavity clean, residue build-up on the obturator even with vigilant cleaning, and the inability to eat or communicate effectively without the device. Other parameters to take into account concerns psychological and social factors, strongly associated with aesthetics. Patients with fixed prosthesis after reconstruction (group A) have answered more positively questions about "psychological disability", "social

disability” and “social handicap”; they resumed early their daily activities, working life, and showed a higher satisfaction for results. These considerations imply a much greater well-being in post-rehabilitation times not only limited to personal and social dimensions, but extended to anatomical, functional and aesthetic ones.

Conclusions

According to our experience and result got through this questionnaires, it can be confirmed that fixed implant-prostheses after surgical reconstruction of maxillactomy defects represent best solution for rehabilitation in head and neck oncologic patients. In fact this option has been associated to more statistically encouraging results if compared to palatal obturator solution. Patients in group A resume their normal daily activities and work life earlier than those ones in group B, they recover more successfully their oral function (chewing, swallowing, speech), they are completely reintegrated in their social dimension and show higher satisfaction for rehabilitation.

The less satisfaction of older patients for fixed prosthesis referred by our last asked question can be interpreted in two ways: first of

all, over-60 patients are most prone to surgical stress than younger ones, so that they could report more doubts about fixed solution; furthermore, among the younger patients, an important percentage of subject had undergone to a previous temporary step with a removable rehabilitation through a palatal obturator before they were reconstructed, having the opportunity to compare both solution with obturator and with fixed prosthesis, knowing differences between them, contrary to older patients who were all directly reconstructed and rehabilitated with fixed prostheses.

In front of advantages derived by using a fixed prosthesis. On the other hand palatal obturator has proved effective in the immediate post-surgical times as temporary strategy, or it has represented a good compromise in all those cases in which a different alternative was not possible.

Declaration of Interest

The authors report no conflict of interest and the article is not funded or supported by any research grant.

<i>Group A</i>		
Code	Anatomicalsite	N° patients
U1-R	Premaxillae	9
U1+2-R		4
U2-R	Postero-lateral area	7
U3-R	Hemimaxillectomy	12
U4-R	Total maxillectomy	2
Uc1-R	Premaxillae + ONAC	0
Uc2-R	Postero-lateral area + ONAC	7
Uc3-R	Hemimaxillectomy + CONA	4
Uc4-R	Total maxillectomy + CONA	2

<i>Group B</i>		
Code	Anatomicalsite	N° patients
U1-c	Premaxillae	4
U1+2-c		3
U2-c	Postero-lateral area	5
U3-c	Hemimaxillectomy	9
U4-c	Total maxillectomy	0

Table 1. Group A: patients fixed prosthesys; group B: patients with palatal obturator.

Questions Likert Scale	0 never		1 Hardly ever		2 occasionally		3 Fairly often		4 Very often	
	B	A	B	A	B	A	B	A	B	A
Functional limitation Have you had trouble pronouncing any words because of problems with your teeth, mouth or dentures? Have you felt that your sense of taste has worsened because of problems with your teeth, mouth or dentures?	2 9,5%	43 91,5%	4 19,0%	3 6,4%	5 23,8%	1 2,1%	6 28,6%	0	4 19,0%	0
Physical pain Have you had painful aching in your mouth? Have you found it uncomfortable to eat any foods because of problems with your teeth, mouth or dentures?	0 9,5%	23 48,9%	3 14,3%	17 36,2%	13 61,9%	4 8,5%	1 4,8%	2 4,2%	4 19,0%	1 2,1%
Psychological discomfort Have you felt self conscious because of problems with your teeth, mouth or dentures? Do you felt tense because of problems with your teeth, mouth or dentures?	1 4,8%	34 73,3%	2 9,5%	7 14,9%	5 23,8%	2 4,2%	9 42,8%	3 6,4%	4 19,0%	1 2,1%
Physical disability Has your diet been unsatisfactory because of problems with your teeth, mouth or dentures? Have you had to interrupt meals because of problems with your teeth, mouth or dentures?	7 33,3%	36 76,6%	3 14,3%	6 12,8%	4 19,0%	4 8,5%	5 23,8%	0	2 9,5%	1 2,1%
Psychological disability Have you found it difficult to relax because of problems with your teeth, mouth or dentures? Have you been a bit embarrassed because of problems with your teeth, mouth or dentures?	4 19,0%	40 85,1%	5 23,8%	3 6,4%	10 47,6%	4 8,5%	1 4,8%	0	1 4,8%	0
Social disability Have you been a bit irritable with other people because of problems with your teeth, mouth or dentures? Have you had difficulty doing your usual jobs because of problems with your teeth, mouth or dentures?	8 38,1%	42 89,4%	4 19,0%	3 6,4%	4 19,0%	1 2,1%	3 14,3%	1 2,1%	2 9,5%	0
Social handicap Have you felt that life in general was less satisfying because of problems with your teeth, mouth or dentures? Have you been total unable to function because of problems with your teeth, mouth or dentures?	3 14,3%	41 87,2%	4 19,0%	2 4,2%	8 38,1%	2 4,2%	5 23,8%	2 4,2%	1 4,8%	0
	3 14,3%	40 85,1%	5 23,8%	4 8,5%	8 38,1%	3 6,4%	3 14,3%	0	2 9,5%	0

Table 2. OHIP – 14 results. Columns represent values according Likert Scale; rows indicate the 14 questions addressed to patients arranged in 7 categories. For each question, number of patients giving a specific answer and corresponding percentage are set out.
B: obturator A: fixed prosthesis.

References

1. Rogers SN, Brown JS, Vaughan ED, et al., Health-related quality of life after maxillectomy: a comparison between prosthetic obturation and free flap. *J Oral Maxillofac Surg.* 2003;61:174-181.
2. Genden EM, Okay DJ, Stepp MT, Rezaee RP, Mojica JS, Buchbinder D, Urken ML, Comparison of functional and quality-of-life outcomes in patients with and without palatomaxillary reconstruction: a preliminary report. *ArchOtolaryngol Head NeckSurg.* 2003;129:775-780.
3. Futran ND, Retrospective case series of primary and secondary microvascular free tissue transfer reconstruction of midfacial defects. *J ProsthetDent.* 2001;86:369-76.
4. Yim KK, Wei FC, Fibula osteo septocutaneous free flap in maxillary reconstruction. *Microsurgery.* 1994;15:353-7.
5. Danza M, Quaranta A, Caringi F, Paracchini L, Pompa G, Vozza I. Biomechanical evaluation of dental implants in D1 and D4 bone by finite elements analysis. *Minerva stomatal.* 2010;59,6:305-313.
6. Tirelli G, Rizzo R, Biasotto M, Di Lenarda R, Argenti B, Gatto A, Bullo F, Obturator prostheses following palatal resection: clinical cases. *Acta Otorhino laryngolItal.* 2010;30:33-39.
7. Kreeft AM, Krap M, Wismeijer D, Speksnijder CM, Smeele LE, Bosch SD, Muijen MSA, Balm AJM, Oral function after maxillectomy and reconstruction with an obturator. *Int J Oral Maxillofac Surg.* 2012;41:1387-1392.
8. Kornblith AB, Zlotolow IM, Gooen J, Huryn JM, Lerner T, Strong EW, Shah JP, Spiro RH, Holland JC, Quality of life of maxillectomy patients using an obturator prosthesis. *Head Neck.* 1996;18:323-334.
9. Dichamp J, Razouk O, Sidibe CA, et al, An obturator prosthesis in a patient with perfect dentition. Functional, esthetic approach. *Rev Stomatol Chir Maxillofac.* 1994;95:195-6.
10. Brauner E, Valentini V, Jamshir S, Guarino G, Battisti A, Fadda MT, Pompa G, Retrospective review of 78 rehabilitated head and neck postoncological patients: a new classification method. *Minerva Stomatologica.* 2016;65(1):17-38.
11. Chigurupati R, Aloor N, Salas R, Schmidt BL. Quality of life after maxillectomy and prosthetic obturator rehabilitation. *J Oral Maxillofac Surg.* 2013;71:1471-8.
12. Candel-Marti E, Peñarrocha-Oltra D, Peñarrocha-Diago MA, Peñarrocha-Diago M, Satisfaction and quality of life with palatal positioned implants in severely atrophic maxillae versus conventional implants supporting fixed full-arch prostheses. *Med Oral Patol Oral Cir Bucal.* 2015;20(6):751-6.
13. Locker D, Allen PF, Developing short-form measures of oral health-related quality of life. *J Public Health Dent.* 2002;62:13-20.
14. Rieger J, Bohle III G, Huryn J, Lam Tang J, Harris J, Seikaly H. Surgical reconstruction versus prosthetic obturator of extensive soft palate defects: a comparison of speech outcomes. *Int J Prosthodont.* 2009;22:566-572.
15. Depprich RA, Handschel JG, Meyer U, Meissner G, Comparison of prevalence of microorganisms on titanium and silicone/polymethyl methacrylate obturators used for rehabilitation of maxillary defects. *J Prosthet Dent.* 2008;99(5):400-405.
16. Chiapasco M, Biglioli F, Auteliano L, Romeo E, Brusati R, Clinical outcome of dental implants placed in fibula-free flaps used for the reconstruction of maxillo-mandibular defects following ablation for tumors or osteo radio necrosis. *Clin Oral Impl Res.* 2006;17:200-8.
17. Andrades P, Militsakh O, Hanasono MM, Rieger J, Rosenthal EL, Current strategies in reconstruction of maxillectomy defects. *Arch Otolaryngol Head Neck Surg.* 2011;137(8):806-812.
18. Moreno MA, Skoracki RJ, Hanna EY, Hanasono MM, Microvascular free flap reconstruction versus palatal obturation for maxillectomy defects. *Head Neck.* 2010;32(7):860-8.
19. Brown JS, Zuydam AC, Jones DC, Rogers SN, Vaughan ED, Functional outcome in soft palate reconstruction using a radial forearm free flap in conjunction with a superiorly based pharyngeal flap. *Head Neck.* 1997;19:524-534.
20. Hirsch DL, Howell KL, Levine JP, A novel approach to palatomaxillary reconstruction: use of radial forearm free tissue transfer combined with zygomaticus implants. *J Oral Maxillo fac Surg.* 2009;67:2466-72.
21. Frodel JL, Funk GF, Capper DT, et al, Osseointegrated implants: a comparative study of bone thickness in four vascularized bone flaps. *Plast Reconstr Surg.* 1993;92:449-55.
22. Brauner E, Valentini V, Jamshir S, Battisti A, Guarino G, Cassoni A, Gaimari G, Fadda MT, Di Carlo S, Pompa G, Two clinical cases of prosthetic rehabilitation after a tumor of the upper maxilla. *Eur Rev Med Pharmacol Sci.* 2012;16:1882-1890.
23. Wang F, Wei H, Chenping Z, Jian S, Xingzhou Q, Yiqun W, Functional outcome and quality of life after a maxillectomy: a comparison between an implant supported obturator and implant supported fixed prostheses in a free vascularized flap. *Clin Oral Impl Res.* 2006;00:1-7.
24. Cassetta M., Di Carlo S., Pranno N., Pompa V., Pompa G. The use of high resolution magnetic resonance on 3.0-T system in the diagnosis and surgical planning of intraosseous lesions of the jaws: Preliminary results of a retrospective study. *Eur Rev Med Pharmacol Sci.* 2012;16 (14), 2021-2028.