

Early caries detection: comparison of two procedures. A pilot study

Carmine Fabrizio Guerra¹ *, Denise Corridore¹, Marta Mazur¹, Francesca Rinaldo¹, Francesca Merge¹, Debora Pasqualotto¹, Maurizio Vichi², Antonello Maruotti³, Gianna Maria Nardi¹, Livia Ottolenghi¹

¹Department of Oral and Maxillo-Facial Sciences, "Sapienza" University of Rome, Via Caserta 6, 00161 Rome, Italy.

²Department of Statistical Sciences, "Sapienza" University of Rome, Piazzale Aldo Moro, 00161 Rome, Italy.

³Centre for Innovation and Leadership in Health Sciences, University of Southampton, Southampton, UK.

*Corresponding author: Fabrizio Guerra - E-Mail: fabrizio.guerra@uniroma1.it; tel.: +39-0649918151

Article history

Received: November 30, 2016

Accepted: December 16, 2016

Published: December 30, 2016

Abstract

Caries is one of the most common chronic diseases and the main cause of tooth loss. Early detection provides a better evaluation of the disease and improves the chances to succeed of prevention strategies. This pilot study aims to compare the effectiveness of ICDAS-II system (International Caries Detection and Assessment System) and the fluorescence terminal (Proof) of VistaCam iX intraoral camera, in the early diagnosis and assessment of caries in permanent teeth. Results shows a fair correlation between ICDAS II and VistaCam iX Proof; intraoral camera proved to be a useful support to the ICDAS II visual / tactile monitoring of carious lesions in occlusal surfaces.

Keywords: Occlusal caries; Fluorescence-based camera; ICDAS II; VistaCam iX Proof.

Introduction

Dental caries is the most common oral cavity disease and one of the major health problems in industrialized countries. It affects 60-90% of schoolchildren and adults. [1] Caries is a chronic disease and is the main cause of tooth loss. In the early stages, disease can stop or regress with calcium, phosphate and fluoride ions supply, but, without proper care, can hesitate in tooth cavitation [2] [3] [4]. Caries detection, at early stages of enamel demineralization, provides a better evaluation of disease and improves the success of primary and secondary preventive strategies [5] [6], thus reducing as possible the tooth tissues injuries.

Actually, detection and diagnosis of caries lesions relies on traditional tactile/visual inspection, radiography or

new technological diagnostic tool based on light transmission, light fluorescence and other systems such as ultrasound and near infrared illumination [7] [8] [9].

Oral radiographic examinations, such as panoramic, bitewing and intraoral periapical radiographs, shows low sensitivity and specificity in detecting small occlusal caries lesion [10].

Traditional methods are the most widely used in clinical practice. Visual inspection, though essential for tooth surface evaluation, also shows low sensitivity and specificity. Tactile examination employs a sharp probe exploring occlusal surfaces to assess tooth texture and/or shape but is not able to detect the deeper pit and fissure lesions; furthermore, some authors demonstrated that pressure used to analyze tooth surfaces may generate iatrogenic damage [11] [12]. The limit of the traditional tactile/visual inspection is the subjective judgment and

intra-examiner reliability. It is also required a proper competence of the examiners, in order to obtain an objective evaluation of the dental surfaces without leading to mistakes due to pigmented or fluorosis areas or DDE (developmental defects of enamel) [13], that could trick the eye of not enough experienced clinician. Currently, for the diagnosis of initial carious lesions is employed the dental caries examination criteria ICDAS II (International Caries Detection and Assessment System), through training/calibration sessions, has standardized traditional visual/tactile methods to achieve a high inter and intra-examiner reliability. It was created by the need to systematize the scientific international literature results.

VistaCam iX is an intraoral camera whose fluorescence Proof terminal takes advantage of the fact that carious tissue and sound tissue fluoresce at different intensity when excited by light at specific wavelengths. The resulting digital image shows the enamel with different colors shades and with numerical score, based on the extent and depth of carious lesion [10].

This pilot study aims to evaluate the performance of two diagnostic methods, currently available for the diagnosis of occlusal caries. Particularly, we compared the ICDAS-II system and the fluorescence terminal (Proof) of VistaCam iX intraoral camera (Durr Dental, Bietigheim-Bissingen, Germany) [10].

Materials and Methods

For this in vivo study, we recruited patients, with no restorative treatment in the posterior dental areas, arrived at the First Unity Visit of the Department of Oral and Maxillo-Facial Sciences of Sapienza University of Rome. Exclusion criteria were poor oral hygiene and systemic diseases that could affect oral health.

All the patients subscribed an informed consent. Before the measurements, all teeth underwent oral hygiene, with rotating bristle brush and prophylactic pastes, and rinse and drying with air-water syringe. A calibrated and certified dental clinician conduct dental examination based on the ICDAS II criteria, inspect the occlusal teeth surfaces and assigned an ICDAS II code.

ICDAS II is an international system of detection and classification of caries, standardized, created to enable the early detection of caries lesions and, therefore, to allow an appropriate and customized treatment. The inspection of the tooth surfaces is carried out using only the sense of sight and touch of operator.

Visual exam should be performed on clean and carefully dry teeth; for tactile examination, it is recommended use of a probe with a rounded tip, to gently slide on surfaces, in order to avoid damage to enamel surface layer. To the examined teeth, is assigned a

numerical value from 0 to 6, according to criteria established by ICDAS II system, which takes into account the anatomical location of the lesion and the presence or absence of restoration or sealant [14] [15]. The chosen sites were recorded as ICDAS-II codes:

- 0 - Sound (43 teeth);
- 1 - First visible sign of a non-cavitated lesion, seen only when the tooth is dried (34 teeth);
- 2 - Clinically visible non-cavitated lesion, seen when wet and dry (61 teeth);
- 3 - Microcavitation in enamel (62 teeth);
- 4 - Non-cavitated lesion extending into dentin, seen as an undermining shadow (00 teeth);
- 5 - Small cavitated lesion with visible dentin: less than 50 % of surface (00 teeth);
- 6 - Large cavitated lesion with visible dentin: more than 50 % of surface (00 teeth).

Using the VistaCam iX Proof fluorescence based camera, images of the same occlusal tooth surfaces were taken.. For higher reproducibility it has been used a positioner provided by the manufacturer. The LEDs of VistaCam iX Proof terminal emit high power blue-violet light at 405 nm on the occlusal surface of the tooth. At this wavelength, the porphyrins, produced by tooth decay related bacteria, emit red light at a lower energy, differently from the sound enamel, that instead emits green light [16] [17]. The camera recorded fluorescence that is, then, processed and stored by a software (DBSWIN, Durr). The software analyzed the images and assigned a numeric code and different shades of color, thus stating the extent and depth of demineralization (tab 1), according to manufacturer's scale: 0-0.9=sound enamel; >0.9-1.5= initial caries, beginning enamel caries; >1.5-2= enamel caries to enamel-dentin limit; >2.0-2.5= dentin caries; >2.5= deep dentine caries.

Statistical analysis

To find the agreement of two rating methods, the ICDAS II and the VistaCam iX Proof, we start by considering Cohen's kappa [18] and weighted kappa [19]. The weighted version of the Cohen's kappa is given by the (probability of observed matches - probability of expected matches) / (1 - probability of expected matches) and considers off diagonal elements as well; the simple kappa just considers the matches on the main diagonal.

As the ratings are ordinal in nature, the weighted kappa seems to be more appropriate.

To judge the level of agreement, it is good to bear in mind the following general classification often used in practice:

Kappa Agreement < 0 Less than chance agreement; 0.01–0.20 Slight agreement; 0.21– 0.40 Fair agreement; 0.41–0.60 Moderate agreement; 0.61–0.80 Substantial agreement; 0.81–0.99 Almost perfect agreement.

Results

In this pilot study, 26 subjects for a total of 200 permanent teeth (53 premolars e 147 molars) were examined. The age was between 13 and 30 years, 10 male and 16 female.

Weighted and unweighted coefficients are displayed in table 2, along with their confidence intervals.

The aspects can be easily detected from these results.

Ignoring the off diagonal elements and the ordinal nature of the categories leads to an almost chance agreement, as shown by the unweighted kappa estimated. However, by using the more appropriate weighted kappa, we can conclude that there is a fair agreement between the methods.

Discussion

This pilot study compares the effectiveness of ICDAS II system and the fluorescence terminal (Proof) of VistaCam iX intraoral camera, in early diagnosis and assessment of caries in permanent teeth. The early detection and monitoring of carious lesions plays an essential role in context of primary and secondary prevention policies, especially for early lesions, which, if not recognized or underestimated, may delay treatment, thus resulting in deep carious lesions extending to the dentin.

Results demonstrated a fair correlation between the ICDAS II system and the fluorescence measurements.

These results confirm data from studies in literature centered on use of fluorescence-based cameras in caries detecting. Jablonski-Momeni et al [6] observed a strong correlation between ICDAS and a fluorescence camera.

In study of Melo et al, the fluorescence-based techniques showed greater validity than the visual and tactile method [20]. This result may be related to visual tactile diagnosis method, which did not apply the ICDAS II method with a trained and calibrated operator.

Our results also show that, in comparison to the values of VistaCam iX Proof, the ICDAS II method, in certain cases, might underestimate initial caries and overestimate deep caries. This shows how VistaCam iX Proof validates and strengthen a protocol considered the gold standard in the diagnosis of caries. The Vista Cam iX Proof intraoral self-calibrating fluorescence camera is a novel dental diagnostic tool for quantitative assessment of dental caries with a high sensitivity; it does not require a specific operator training.


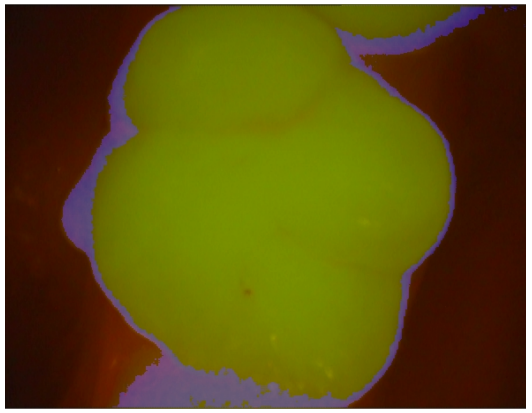

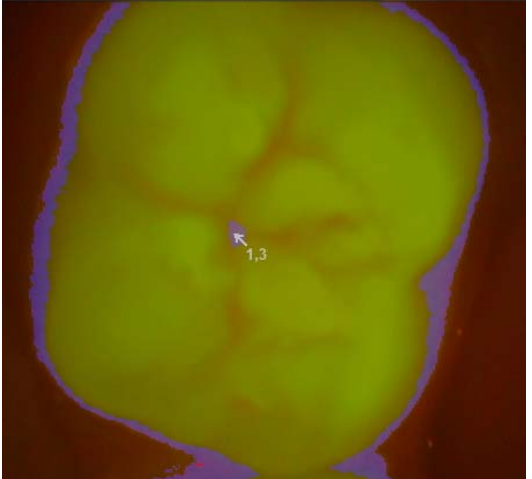

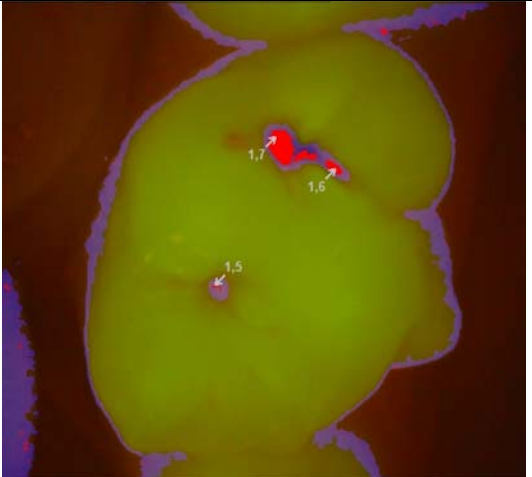
Its image processing software, also allows storing data for each patient, in order to quantitatively compare the images in following checks, to monitor over time sound occlusal surfaces or early enamel lesions that can be treated with non-invasive methods. Furthermore, the VistaCam iX Proof images highlight the presence of plaque, and this may lead clinicians to improve their professional oral hygiene performance. In addition, the opportunity to show on a screen the oral findings may be an additional means of communication with patients and could prompt the patient to perfect the quality of his oral hygiene and its oral health [6].

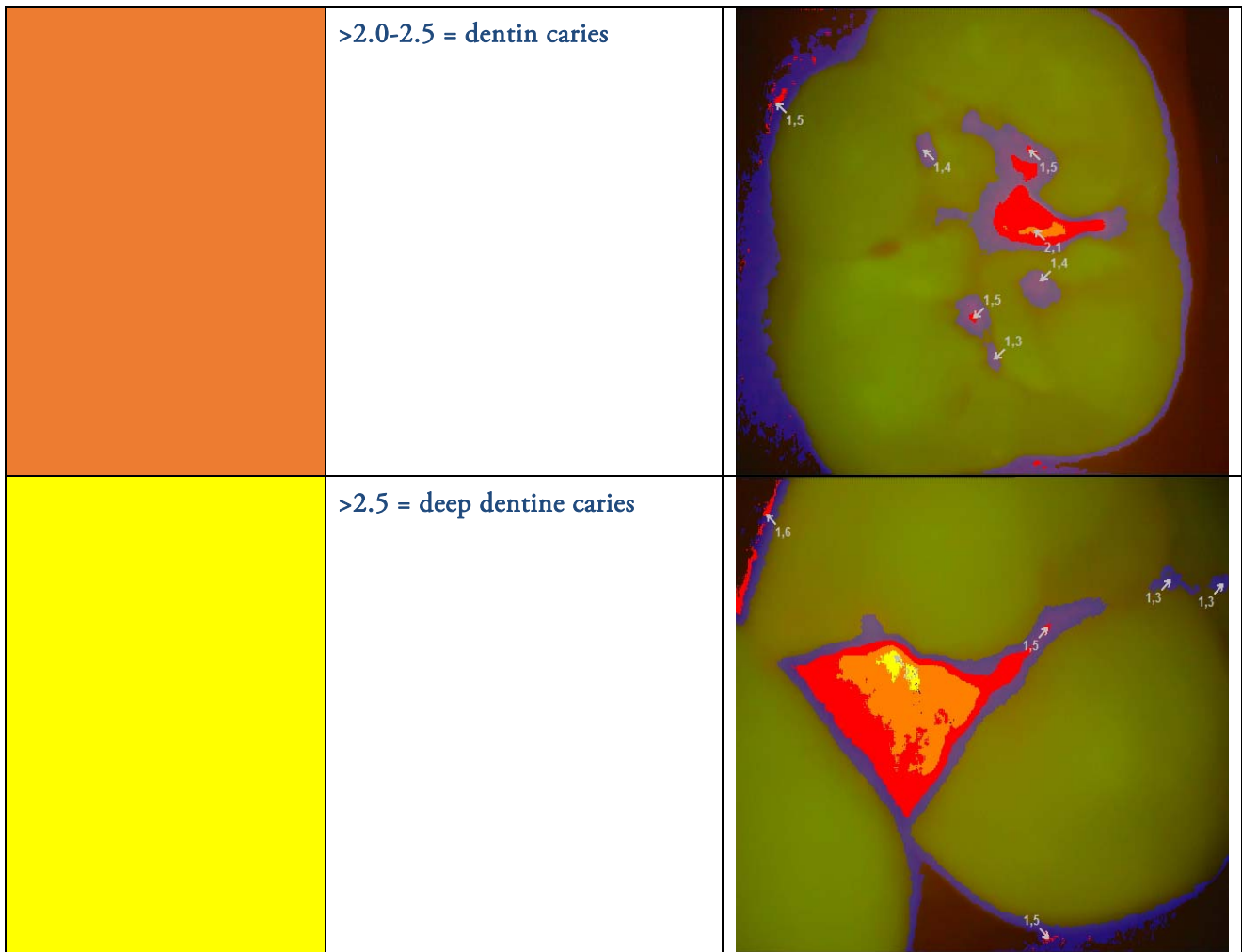
Conclusions

In conclusion, a correlation between ICDAS II and VistaCam iX Proof was confirmed. Intraoral camera proved to be a useful support to the visual / tactile ICDAS II examination in occlusal surfaces. It allows creating personal folders of patient and a long term monitoring over time the development of remineralized lesions and improves the visual examination in order to minimize diagnostic evaluation errors. Moreover, all clinicians can use VistaCam iX Proof as it does not require a preliminary calibration session.

The study goes on to get a highly significant sample to reinforce these preliminary results. Based on these preliminary data, we expect to assert that the ICDAS II method has a level of objectivity at or just lower than the VistaCam iX Proof.

Tab. 1: Manufacturer's color and code scale for VistaCam iX Proof

	<p>0-0.9 = sound enamel</p>	
	<p>>0.9-1.5 = initial caries, beginning enamel caries</p>	
	<p>>1.5-2 = enamel caries to enamel-dentin limit</p>	



Tab 2: Weighted and unweighted coefficients: ICDAS II vs VistaCam iX Proof

	Lower	Estimate	Upper
Unweighted kappa	-0.021	0.048	0.12
Weighted kappa	0.397	0.469	0.54

References

- Zeitouny M, Feghali M, Nasr A, Abou-Samra P, Saleh N, Bourgeois D, et al. SOPROLIFE system: an accurate diagnostic enhancer. *The Scientific World Journal*, 2014.
- Fejerskov O, Nyvad B, Kidd E. Clinical and histological manifestations of dental caries. In *Dental Caries: Disease and Its Clinical Management.*: Blackwell Publishing Ltd; 2003. p. 71-97.
- Fejerskov O. Concepts of dental caries and their consequences for understanding the disease.. *Community dentistry and oral epidemiology*, 1997, 25.1: 5-12.
- Pitts N. Modern concepts of caries measurement.. *Journal of dental research*, 2004, 83.suppl 1: C43-C47.
- Nyvad B. Diagnosis versus detection of caries.. *Caries Res* 2004; 38: 192–198.
- Jablonski-Momeni A, Heinzl-Gutenbrunner M, Vill G. Use of a fluorescence-based camera for monitoring occlusal surfaces of primary and permanent teeth. *Int J Paediatr Dent*. 2016 Nov;26(6):448-456. doi: 10.1111/ipd.12216. Epub 2015 Nov 21.
- Gimenez T, Piovesan C, Braga MM, al e. Visual inspection for caries detection: a systematic review and meta-analysis. *Journal of dental research*, 2015, 94 (7): 895-904.
- Gomez J, Zakian C, Salsone S, Pinto S, Taylor A, Pretty IA, et al. In vitro performance of different methods in detecting occlusal caries lesions.. *Journal of dentistry*, 2013, 41 (2): 180-186.
- Tassery H, Levallois B, Terrer E, al e. Use of new minimum intervention dentistry technologies in caries management.. *Australian dental journal*, 2013, 58.s1: 40-59.
- Guerra F, Mazur M, Rinaldo F, Corridore D, Salvi D, Pasqualotto D, et al. New diagnostic technology and hidden pits and fissures caries. *Senses Sci*. 2015; 2 (1):20 -23.
- Ismail A. Visual and visuo-tactile detection of dental caries.. *Journal of Dental Research*, 83.suppl.1, 2004: C56-C66.
- Newbrun E. Problems in caries diagnosis.. *International dental journal*, 1993, 43 (2): 133-42.
- Guerra F, Mazur M, Corridore D, al. e. Developmental Defects of Enamel: an increasing reality in the everyday practice.. *Senses Sci*, 2014, 1: 87-95.
- Neeraj G, al e. International Caries Detection and Assessment System (ICDAS): A New Concept. *International Journal of Clinical Pediatric Dentistry*, MayAugust 2011;4(2):93-100.
- Hellwig E, Lennon A. Systemic versus topical fluoride. *Caries Res* 2004; 38:258-62.
- König K, Flemming G, Hibst R. Laser—induced autofluorescence spectroscopy of dental caries.. *Cellular and molecular biology*, 1998, 44.8: 1293-1300..
- Lussi A, Megert B, Longbottom C, Reich E, Francescut P. Clinical performance of a laser fluorescence device for detection of occlusal caries lesions.. *European Journal of Oral Sciences*, 2001, 109.1: 14-19.
- Cohen J. A coefficient of agreement for nominal scales.. *Educational and Psychological Measurement*. 1960;20 (1): 37–46.
- Cohen J. Weighed kappa: Nominal scale agreement with provision for scaled disagreement or partial credit.. *Psychological Bulletin*. 1968;70 (4): 213–220.
- Melo M, Pascual A, Camps I, al. e. Caries diagnosis using light fluorescence devices in comparison with traditional visual and tactile evaluation: a prospective study in 152 patients.. *Odontology*, 2016, 1-8 .