

Diagnostic accuracy of sonohysterography vs hysteroscopy in benign uterine endocavitary findings

M. ZINNA, M. GENTILE, F. TORCIA, P. BIANCHI, G. COZZA, R. MARZIANI, G.N. MILAZZO, A. CATALANO, M. DI PROPERZIO, F. MANZARA, M. SCHIMBERNI, D. CASERTA, A. FREGA

Department of Gynecological, Obstetric and Urological Sciences, "Sapienza" University of Rome, Sant'Andrea Hospital, Rome, Italy

Abstract. – OBJECTIVE: To compare diagnostic accuracy of sonohysterography vs hysteroscopy in patients with benign uterine endocavitary findings.

PATIENTS AND METHODS: This retrospective study evaluated 202 patients submitted to sonohysterography after transvaginal ultrasound examination suspicious for uterine endocavitary findings. Cytological sample was taken and analyzed from the fluid used to distend the uterine cavity. Of 202 patients enrolled for this study, 86 patients underwent gynaecological surgery, of whom 77 were treated with operative hysteroscopy and 9 with other gynaecological surgical techniques. Statistical analysis was performed to evaluate diagnostic agreement between sonohysterography vs hysteroscopy and cytology vs histology.

RESULTS: Diagnostic concordance between sonohysterography and hysteroscopy was significant (k value 0.87). The correlation between cytological and histological findings had a moderate level of concordance (k value 0.49).

CONCLUSIONS: Sonohysterography provides a diagnostic accuracy as well as hysteroscopy, therefore, it could be considered an alternative procedure in the diagnosis of benign uterine endocavitary findings.

Key Words:

Sonohysterography, Hysteroscopy, Endometrial cytology, Histological diagnosis, Benign uterine findings.

Introduction

In the last years the introduction of ultrasounds in clinical practice strongly improved the diagnostic accuracy, in both obstetrics and gynaecology, thanks to the continuous technological evolution of images quality provided by the new high-resolution devices. The wide variety of symptoms reported by patients (oligomenor-

rhoea, amenorrhoea, dysmenorrhoea, polymenorrhoea, abnormal uterine bleeding, acute and chronic pelvic pain, infertility, recurrent miscarriage) helps guide the ultrasound examination in the diagnosis of both congenital (genetic syndromes, malformations) and acquired (endocavitary neoformations, infections, endometrial fluid collections, iatrogenic diseases as Ashermann's syndrome, hormonal changes) benign uterine endocavitary findings. Past studies have shown the central role of sonohysterography especially in those patients with abnormal uterine bleeding (AUB). In order to establish a correct diagnostic and therapeutical approach for AUB it is essential to define an organic bleeding cause according to patient's age and hormonal state (childbearing age, perimenopause, postmenopause). AUB is defined as an abnormal uterine bleeding in perimenopause and childbearing age patients, due to anatomical causes (polyps, fibroids, adenomyosis, endometrial hyperplasia), neoplastic diseases and iatrogenic factors. In 2010, Goldstein¹ underlined the difficulties encountered in endometrial sampling in diagnostic examinations, especially because of endometrial's pathologies focal nature. In the past the diagnostic and therapeutic use of blind curettage of the uterus (D and C, dilatation and curettage) was associated with a 10% false negative endometrial lesions²; in 1970, the introduction of Vabra[®] Aspirator³ improved diagnosis accuracy of malignant and premalignant lesions up to 86%; in 1984 the Pipelle de Cornier[®] ⁴ has shown an accuracy similar to Vabra[®] Aspirator, resulting to be better tolerated by patients⁵. In 1980 the high frequency ultrasound vaginal probes were available, allowing a more exhaustive study of the uterus and endometrium (technically defined by Goldstein in 1991 as "sonomicroscopy"). Later on, many mul-

ticentre and prospective studies correlated the endometrial thickness (< 4 mm and < 5 mm) to the endometrial carcinoma onset in postmenopausal women with AUB until 2009, when the ACOG Committee Opinion No. 440 confirmed an endometrial thickness more than 4 mm as threshold for further diagnostic tests⁶.

The limits of conventional ultrasound 2D examination in endometrial findings have been reported⁷; hence, the need for ultrasound subsets in the study of endometrial findings spread out. Nowadays sonohysterography is a well tolerated contrastographic technique, allowing an adequate visualization of the uterus. For this reason it can be included in what Goldstein¹ in 2010 defined as “ultrasound screening”: an algorithm for triage and management of benign uterine endocavitary findings in perimenopause, postmenopause and childbearing age patients.

Saline Infusion Sonohysterography (SIS) is an ultrasound technique used to analyze uterus and cavity contents through the use of a contrast media, such as a sterile saline solution injected into the cavity through a transcervical catheter. SIS sensibility results to be higher than 87% and its specificity is above 66% in the study of benign uterine endocavitary findings. Generally, sonohysterography is an easy operating examination, well tolerated and burdened by a very low prevalence of complications⁸. Furthermore, the sonohysterography represents a valid diagnostic support in the study of benign endometrial and uterus endocavitary findings, thanks to the possibility to contextually perform a cytological examination through the use of sterile saline solution. Since numerous investigations showed the possible migration of neoplastic cells in both the fallopian tubes and peritoneum after saline solution injection, it is not suggested to perform sonohysterography as soon as a neoplastic pathology is suspected⁹⁻¹². Nevertheless, hysteroscopy is still today the gold standard for the diagnostic determining of uterine endocavitary findings, due to the possibility to perform a targeted biopsy. In this article we reported our case load comparing diagnostic accuracy of sonohysterography vs hysteroscopy in benign uterine endocavitary findings.

Patients and Methods

This study evaluated 202 patients subjected to sonohysterography after a conventional transvagi-

nal ultrasound examination suspicious for endometrial or benign uterine endocavitary findings from 2006 to 2012. Both symptomatic (AUB, pelvic pain) and asymptomatic (routine ultrasound, follow-up for breast cancer) patients, in childbearing, perimenopausal or postmenopausal age were selected for the study population. All patients gave their written informed consent. The study was reviewed and approved by the Institutional Review Board (Prot. CE 3389/14).

Patients with initial ultrasound examination strongly suspicious for neoplastic disease were not submitted to sonohysterography. Sonohysterography was performed using a flexible catheter (40 cm length, CH 08). A pediatric Foley (CH 08) with balloon was rarely used. The catheter was introduced through the cervix and positioned in the middle third of the uterine cavity, using a speculum and a tenaculum to hold the cervix. Ultrasound guidance was used to check the correct position of the catheter, so that the uterine cavity could be filled with 20 ml of sterile saline solution in order to evaluate the presence of jutting formations or pathological thickening. A cytological sample of the liquid used to distend the uterine cavity was taken for completion and diagnostic support, making sure that the aspirated liquid was coming out of the uterine cavity and not from the vagina. All the patients underwent the endometrial sampling for cytological examination in liquid phase, except for those patients suspected for neoplastic pathology.

Out of the 202 patients, 86 (42.6%) underwent gynaecological surgery, of whom 77 were treated with operative hysteroscopy and 9 with other gynaecological surgical techniques with contextual histological examination. Diagnostic agreement between sonohysterography and hysteroscopy was evaluated on the basis of histological examination. Cytological and histological correlation and the concordance between hysteroscopy and histological findings were assessed. Association between sonohysterography and age of the patients were analyzed in order to relate the higher appearance of a particular endocavitary finding within a certain age group, which indirectly represents the patient's hormonal state. Similarly, also age and performing surgery choice were inquired.

Statistical Analysis

SPSS 9 software (SPSS Inc., Chicago, IL, USA) was used for statistical data processing, obtaining the descriptive analysis for each demographic parameter. We used the K test of Cohen

Table I. Features of the population.

Ultrasound indication	Cases N (%)
Routine check-up	109 (54%)
Abnormal uterine bleeding	67 (3%)
Prior breast cancer (oncologic follow-up)	24 (12%)
Pap test AGC	1 (0.5%)
Pelvic pain	1 (0.5%)
Childbearing/perimenopause	94 (46.6%)
Postmenopause	93 (46%)
Amenorrhea	15 (7.4%)

for the study of concordance about qualitative variables. K test values by Cohen for the study of concordance are: 0 (no concordance); 0-0.4 (poor concordance); 0.4-0.6 (moderate concordance); 0.6-0.8 (good concordance); 0.8-1 (optimal concordance), 1 (maximum concordance). The comparative diagnostic accuracy between sonohysterography and hysteroscopy was assessed using ROC curves and measuring the AUC (area under curve, value 0-1, cut value 0.5).

Results

The 202 patients, aged between 25 and 80 years with an average age of 52 years (±11.3 DS) underwent ultrasound screening and sonohysterography (Figure 1). Features of the study population are shown in Table I.

Ultrasound and cytological diagnosis results are shown in Table II. From the 202 patients we selected a cohort of restricted patients undergone to gynaecological surgery with definitive histological examination, for a total of 86 patients (42.6%), 77 undergone operative hysteroscopy and 9 other surgery for neoplastic pathology or other gynaecological concomitant pathology. Hysteroscopic and histological diagnoses are listed in Table II. The result of correlation analysis between diagnoses obtained with sonohysterography and operative hysteroscopy resulted to be significant (K value 0.87). No statistically significant correlation between age of the patient and ultrasound diagnosis was observed (K value 0.73). No statistically significant correlation between age of patients and surgery was found (K value 0.83), as there was not a linear correlation between the two variables that had a Gaussian distribution, taking the age as a dependent variable (Figure 2). Cytological and histological di-

agnosis presented moderate concordance (K value 0.49). We also attempted to justify the inadequacy of samples submitted to cytological examination in relationship to the age of patients and their hormonal status. About the 52 inadequate cytological samples, 2 (4%) were taken from patients with previous breast cancer and in amenorrhea; 23 (44%) belonged to patients in childbearing age (including perimenopausal period) and in proliferative phase and 27 (52%) concerned postmenopausal patients. Twenty-nine (56%) cytological samples resulted inadequate were related to patients in inactive hormonal status (amenorrhea, menopause). This may explain the absence of endometrial exfoliating cells in cytological sampling made on washing liquid and not through cavity scraping or curettage. The statistical analysis showed an evident difference concerning the two exam's specificity. The diagnostic accuracy of the sonohysterography versus operative hysteroscopy was calculated with ROC curves by measuring the value of AUC (Figures 3, 4). The two techniques were substantially similar in terms of accuracy (0.614 for sonohysterography and 0.577 for hysteroscopy).

Discussion

Transvaginal ultrasound represents a non-invasive diagnostic screening technique used to highlight all those findings involving uterus and uterine cavity¹³. Sonohysterography was introduced as ultrasound subset in order to improve the performance of traditional transvaginal ultrasound, with a reported sensibility above 87%

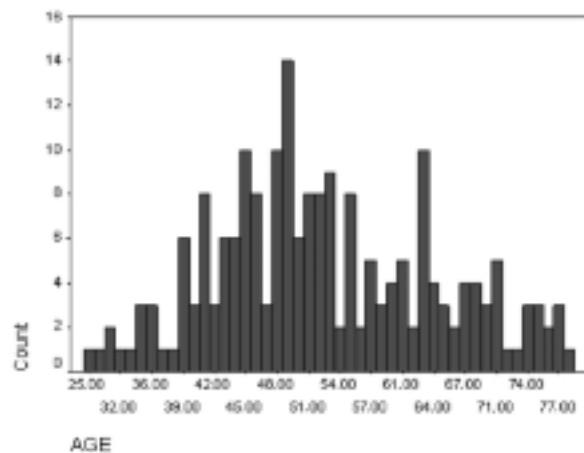


Figure 1. Chart of age distribution of patients.

Table II. Instrumental and hystopathological findings.

Ultrasound diagnosis		Cytological diagnosis	
	Cases N (%)		Cases N (%)
Endometrial polyps	90 (44.5%)	Endometrial atrophy	
	1 (0.5%)	Absence of endometrial cells	
Endometrial thickening	27 (13.4%)	Atypical cells	
	52 (25.7%)	Dubious endometrial hyperplasia	
Endometrial thickening and polyps	2 (1%)	Endometrial hyperplasia	
	5 (2.5%)	Atypical endometrial hyperplasia	4 (2%)
Suspect for neoplastic pathology	5 (2.5%)	Neoplastic cells	2 (1%)
	1 (0.5%)	Normal examination	117 (57.9%)
Endometrial fluid collection	1 (0.5%)	Inflammation	1 (0.5%)
	17 (8.4%)	Endometrial fluid collection drained	2 (1%)
Endometrial fluid collection and synechia	1 (0.5%)		
Submucosal uterine myoma	12 (5.9%)		
Endometrial fluid collection and polyps	1 (0.5%)		
Normal ultrasound examination	63 (31.2%)		
Hysteroscopic diagnosis		Histological diagnosis	
	Cases N (%)		Cases N (%)
Endometrial polyps	58 (75.3%)	Polyps and endometrial atrophy	1 (0.5%)
Increased endometrial thickness	9 (3.9%)	Endometrial hyperplasia	4 (2%)
Myoma	3 (3.9%)	Endometrial atypical hyperplasia	5 (2.5%)
Normal	7 (9.1%)	Endometrial polypoid hyperplasia	3 (1.5%)
		Endometrial carcinoma	3 (1.5%)
		Uterine myoma	4 (2%)
		Negative for pathology	9 (4.4%)
		Endometrial polyps	46 (22.7%)
		Polyp and endometrial hyperplasia	1 (0.5%)
		Polyp and endometrial atypical hyperplasia	2 (1%)
		Hyperplastic polyps	8 (4%)
		Absence of histological examination	116 (57.4%)

and a specificity higher than 66% in the diagnosis of all kinds of uterine endocavitary findings¹⁴. In our selected sample all patients underwent a prior transvaginal ultrasound screening and a sonohysterography in the suspect of benign uterine endocavitary findings (except 5 patients with suspected neoplastic disease). Patients in perimenopause represented at the same time, both a difficulty for the clinician in the diagnostic classification of abnormal uterine bleeding (dysfunctional uterine bleeding, anatomical causes, neoplastic disease) and a starting point for further examinations, especially in those symptomatic patients. Goldstein¹ in 2010 assessed that postmenopausal bleeding is an endometrial cancer until proven otherwise, differently from perimenopausal age bleeding which resulted to be more problematic. Indeed, absence of ovulation, resulting very often in an

abnormal uterine bleeding in women over 35 years, may represent the primum movens for diagnostic examinations to exclude endometrial carcinoma according to ACOG 2001¹⁵; above all in consideration of the arbitrariness of the clinical definition of menopause as absence of menstrual flow for 12 months and in relation to the fact that the gonadotropins values may not always reflect definite shift in the ovarian function. Furthermore, in our study we did not find a statistically significant correlation between age and ultrasound diagnosis, and neither between age and surgery, to support that none uterine pathology can be excluded if not readily determined, regardless of age. So we divided our patients depending on age, clinical symptoms referred, hormonal status and we tested them using sonohysterography and endometrial cytology as a diagnostic completion, reserving to hys-

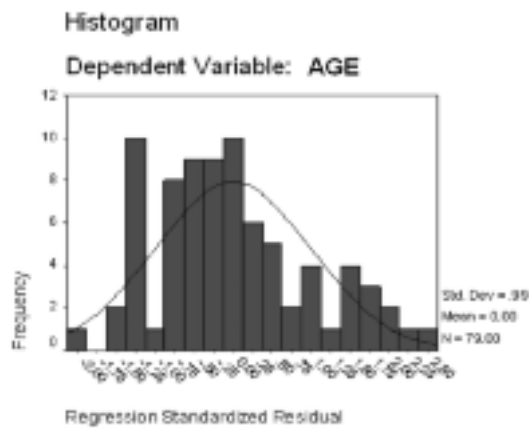


Figure 2. Correlation between age of patients and surgery.

teroscropy a primarily surgical role for those cases in which the endometrial evaluation was insufficient if compared to the clinical case (technique failure). Furthermore, from a diagnostic point of view comparing sonohysterography and operative hysteroscopy we found a good level of concordance with the K test and measuring the AUC by the ROC curve, which currently represents the best method of statistical comparison of two diagnostic techniques. We found a high diagnostic accuracy in both techniques (0.614 for sonohysterography and 0.577 for hysteroscopy). Multiple studies correlated sonohysterography and hysteroscopy with variable results. Suna Soguktas et al¹⁶ in 2012 showed a superiority in terms of diagnosis of hysteroscopy versus sonohysterography and transvaginal ultra-

sound with AUC in the ROC curves of 0.947, 0.894, 0.778 respectively, stressing however the additional utility role of sonohysterography in diagnostic path for AUB especially when compared to transvaginal ultrasound. Grimbizis et al¹³ in 2010 confirmed the same concept of superiority of hysteroscopy compared to sonohysterography (also this analysis was conducted using ROC curves), highlighting the superiority of sonohysterography in terms of cost and tolerability of examination compared to transvaginal ultrasound. Concerning the tolerability of examination, Graziano et al¹⁷ showed a significantly lower pain intensity of sonohysterography compared to hysteroscopy. Abu Salem et al¹⁸, instead, showed how the sonohysterography sensitivity, specificity and diagnostic accuracy increases using the 3D reconstruction, resulting in some cases equal or superior to hysteroscopy, especially in the evaluation of the structures out of the uterus (fibroids, ectopic pathologies). The correlation between cytological and histological diagnosis was moderately significant (K value 0.49). Endometrial cytology was less sensitive but more specific in the diagnosis of endometrial carcinoma with a good detection rate for diagnosis of typical and atypical endometrial hyperplasia. Our findings showed that the inadequacy of cytological specimens derives from the insufficient presence of exfoliating endometrial cells in the washing fluid in case of endometrial atrophy in patients with amenorrhea or in postmenopausal women. Surely, the cytological sampling, a non-invasive way to achieve better com-

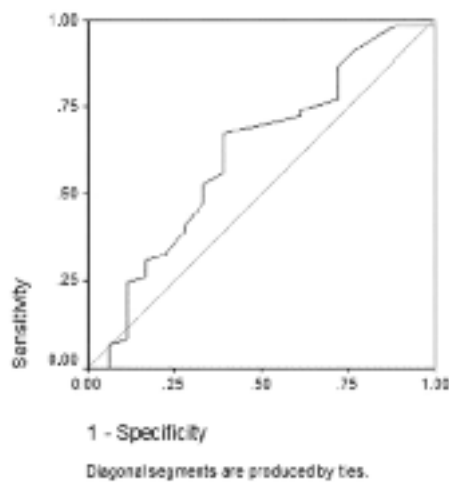


Figure 3. Area under the curve test result variable(s): predicted value of sonohysterography: 0.614.

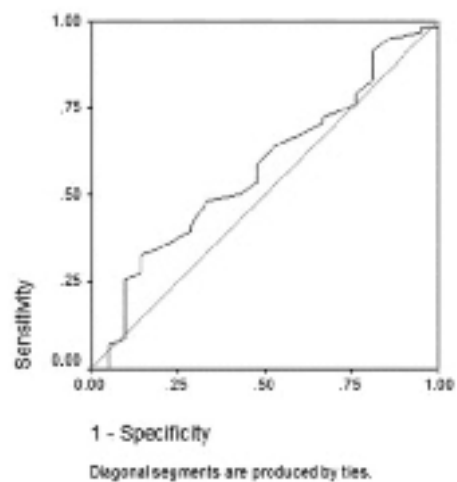


Figure 4. Area under the curve test result variable(s): predicted value of hysteroscopy: 0.577.

pliance of patients, was in some cases inadequate for the diagnostic purposes. Surgical treatment is based on sonohysterography exam instead of cytological sampling that often provides unsatisfactory results. In contrast to carcinoma of the cervix there is not an endometrial cytological screening and the application of the method is based on the needs and experience of the operators. Buccoliero et al¹⁹ in 2007 in a study conducted on 670 women with endometrial thickening (> 4 mm) during transvaginal ultrasound and undergone cytological sampling in the liquid phase and hysteroscopy, assessed sensitivity and specificity of cytology and they resulted respectively 95%, and 98%, equal in terms of diagnostic accuracy to histological examination. In Japan the endometrial cytology is accepted as a method of screening for endometrial pathology and considered to be satisfying to exclude endometrial cancer or precancerous lesions (atypical hyperplasia)²⁰. There is not a unanimous consensus on methodology. The cytological examination in the liquid phase resulted to be useful than conventional cytological examination because it eliminates contamination by cervical mucus and blood²¹ and, as the endometrial cytology is globally a not negligible diagnostic support, some authors²² tried to codify diagnostic criteria about cytological and morphological characteristics of the endometrial elements in liquid phase.

Conclusions

Hysteroscopy, providing an opportunity to perform histological examination, represents the definitive diagnostic and therapeutic way for management of patients with suspected uterine endocavitary findings. In our case load sonohysterography provides a diagnostic accuracy as well as hysteroscopy; furthermore, sonohysterography seems to be a useful additional tool in the diagnosis of benign uterine endocavitary findings.

Conflict of Interest

The Authors declare that they have no conflict of interests.

References

- 1) GOLDSTEIN SR. Modern evaluation of the endometrium. *Obstet Gynecol* 2010; 76: 116-168.
- 2) WORD B, GRAVLEE LC, WIDEMAN GL. The fallacy of simple uterine curettage. *Obstet Gynecol* 1958; 12: 642-648.
- 3) VUOPALA S. Diagnostic accuracy and clinical applicability of cytological and histological methods for investigating endometrial carcinoma. *Acta Obstet Gynecol Scand Suppl* 1997; 70: 1-72.
- 4) CORNIER E. The Pipelle: a disposable device for endometrial biopsy. *Am J Obstet Gynecol* 1984; 148: 109-110.
- 5) KAUNITZ AM, MASCIELLO A, OSTROWSKI M, ROVIRA EZ. Comparison of endometrial biopsy with the endometrial Pipelle and Vabra aspirator. *J Reprod Med* 1988; 33: 427-431.
- 6) AMERICAN COLLEGE OF OBSTETRICIANS AND GYNECOLOGISTS. ACOG Committee Opinion No. 440. The role of transvaginal ultrasonography in the evaluation of postmenopausal bleeding. *Obstet Gynecol* 2009; 114: 409-411.
- 7) GOLDSTEIN SR. The endometrial echo revisited: have we created a monster? *Am J Obstet Gynecol* 2004; 191: 1092-1096.
- 8) Italian Society of Obstetric and Gynecologic Ultrasound (SIEOG). Guidelines 2010 EDITEAM.
- 9) ALCÁZAR JL, ERRASTI T, ZORNOZA A. Saline infusion sonohysterography in endometrial cancer: assessment of malignant cells dissemination risk. *Acta Obstet Gynecol Scand* 2000; 79: 321-322.
- 10) DESSOLE S, RUBATTU G, FARINA M, CAPOBIANCO G, CHERCHI PL, TANDA F, GALLO O, AMBROSINI G. Risks and usefulness of sonohysterography in patients with endometrial carcinoma. *Am J Obstet Gynecol* 2006; 194: 362-368.
- 11) BERRY E, LINDHEIM SR, CONNOR JP, HARTENBACH EM, SCHINK JC, HARTER J, EICKHOFF JC. Sonohysterography and endometrial cancer: incidence and functional viability of disseminated malignant cells. *Am J Obstet Gynecol* 2008; 199: 240-248.
- 12) BESE T, DEMIRKIRAN F, GURALP O, SANIOGLU C, ARVAS M. Transtubal transport of carcinoma cells into the peritoneal cavity after saline infusion via transcervical route in patients with endometrial carcinoma. *Int J Gynecol Cancer* 2009; 19: 682-685.
- 13) GRIMBIZIS GF, TSOLAKIDIS D, MIKOS T, ANAGNOSTOU E, ASIMAKOPOULOS E, STAMATOPOULOS P, TARLATZIS BC. A prospective comparison of transvaginal ultrasound, saline infusion sonohysterography and diagnostic hysteroscopy in the evaluation of endometrial pathology. *Fertil Steril* 2010; 94: 2720-2725.
- 14) FAROUHAR C, EKEROMA A, FURNESS S, ARROLL B. A systematic review of transvaginal ultrasonography, sonohysterography and hysteroscopy for the investigation of abnormal uterine bleeding in premenopausal women. *Acta Obstet Gynecol Scand* 2003; 82: 493-504.
- 15) ACOG COMMITTEE ON PRACTICE BULLETINS—GYNECOLOGY. American College of Obstetricians and Gynecologists. ACOG practice bulletin: Management of anovulatory bleeding. *Int J Gynecol Cancer* 2001; 72: 263-271.

- 16) SOGUKTAS S, COGENDEZ E, KAYATAS SE, ASOGLU MR, SELCUK S, ERTEKIN A. Comparison of saline infusion sonohysterography and hysteroscopy in diagnosis of premenopausal women with abnormal uterine bleeding. *Eur J Obstet Gynecol Reprod Biol* 2012; 161: 66-70.
- 17) GRAZIANO A, LO MONTE G, SOAVE I, CASERTA D, MOSCARINI M, MARCI R. Sonohysterosalpingography: a suitable choice in infertility workup. *J Med Ultrasonics* 2013; 40: 225-229.
- 18) ABOU-SALEM N, ELMAZNY A, EL-SHERBINY W. Value of 3-dimensional sonohysterography for detection of intrauterine lesions in women with abnormal uterine bleeding. *J Minim Invasive Gynecol* 2010; 17: 200-204.
- 19) BUCCOLIERO AM, GHERI CF, CASTIGLIONE F, GARBINI F, FAMBRINI M, BARGELLI G, BARBETTI A, PAPPALARDO S, TADDEI A, BODDI V, SCARSELLI GF, MARCHIONNI M, TADDEI GL. Liquid-based endometrial cytology in the management of sonographically thickened endometrium. *Diagn Cytopathol* 2007; 35: 398-402.
- 20) YANO H K, HIRAI Y, SAKAMOTO A, AOKI D, MORIYA T, HIURA M, YAMAWAKI T, SHIMIZU K, NAKAYAMA H, SASAKI H, TABATA T, UEDA M, UDAGAWA Y, NORIMATSU Y. New terminology for intrauterine endometrial samples: a group study by the Japanese Society of Clinical Cytology. *Acta Cytol* 2012; 56: 233-241.
- 21) NORIMATSU Y, KOUDA H, KOBAYASHI TK, MORIYA T, YANO H K, TSUKAYAMA C, MIYAKE Y, OHNO E. Utility of thin layer preparations in the endometrial cytology: evaluation of benign endometrial lesions. *Ann Diagn Pathol* 2008; 12: 103-111.
- 22) PAPAETHIMIOU M, SYMIAKAKI H, MENTZELOPOULOU P, TSIVELEKA A, KYROUDES A, VOULGARIS Z, TZONOU A, KARAKITSOS P. Study on the morphology and reproducibility of the diagnosis of endometrial lesions utilizing liquid-based cytology. *Cancer* 2005; 105: 56-64.