

Pleomorphic adenoma rehabilitative treatment in growing up patient: a 20-years follow-up

E. BRAUNER¹, S. JAMSHIR¹, G. GUARINO¹, A. CIOLFI¹, V. VALENTINI², G. POMPA¹, S. DI CARLO¹

¹Implantoprosthesis Unit, Department of Oral and Maxillo-Facial Sciences, Sapienza University of Rome, Rome, Italy

²Maxillo-Facial Surgery Unit, Department of Oral and Maxillo-Facial Sciences, Sapienza University of Rome, Rome, Italy

Abstract. – OBJECTIVE: Although tumors of minor salivary glands are rare, the pleomorphic adenoma is the most common pathology among the benign neoplasm and can be found with high prevalence in the junction between hard palate and soft palate. Most of the maxillary tumors are surgically treated through either a total or partial maxillectomy. However, surgical defects lead to both clinical and psychological disorders for the patient.

A postoperative obturator prosthesis is a good option in patients who underwent maxillectomy. It allows to restore both masticatory and speaking functions, as well as aesthetic appearance. When reconstruction of the surgical site is possible, an implant-supported prosthesis can be considered to guarantee a better function and aesthetic's rehabilitation.

CASE REPORT: This clinical report presents the prosthetic rehabilitation of a patient who underwent maxillectomy because of a pleomorphic adenoma of hard palate minor salivary glands. The patient was treated with a palatal obturator prosthesis first and with an implant-supported prosthesis after surgical site's reconstruction and complete healing.

CONCLUSIONS: The rehabilitation of the patient after maxillectomy through both these devices was an excellent option and provided clinical benefits, improving the patient's quality of life, allowing the patient's reinsertion into society.

Key Words:

Pleomorphic adenoma, Maxillectomy, Palatal obturator, Dental implants, Quality of life.

Introduction

Tumors of minor salivary glands are unusual pathologies, and they form a heterogeneous

group of tumors. The incidence of salivary gland tumors is approximately 3% of all head and neck cancers. Among those, 8% originate from minor salivary glands and can be found with high prevalence in the junction of hard palate and soft palate, lips, tongue, cheeks, and mouth floor. Salivary glands neoplasms are rare in children compared with adults¹⁻³. The pleomorphic adenoma (PA), also known as mixed tumor, is the most common type of benign salivary glands' neoplasms. In children, it represents 66.6-90% of benign salivary glands diseases: only 5-10% of minor salivary glands PA occurs in 20 years old or younger patients, with most of the cases occurring in the second decade of life. Parotid glands are the first PA occurring sites, presenting an incidence of 70-85%. Minor salivary glands are interested too: the palate is the most commonly affected site, followed by upper and lower lips, oral mucosa, gingiva and tongue⁴. The World Health Organization classified pleomorphic adenoma as a benign salivary glands' neoplasm, characterized by cellular and architectural pleomorphism. Microscopically, it is composed by epithelial and myoepithelial elements immersed either in a mucoid, myxoid, or chondroid matrix. A fibrous capsule can be found^{5,6}. Most of the jaw tumors originated from paranasal sinuses and palatal epithelium, and minor salivary glands are treated with either partial or total maxillectomy, depending on the lesion location and extension. Maxillectomy is classified into 3 types: with preservation of orbital floor, with the loss of orbital support, and with orbital exenteration and ethmoidectomy. The former can be further divided as low or high, depending on the osteotomy extension, and also as below or above the infra-orbital foramen^{3,7,8}.

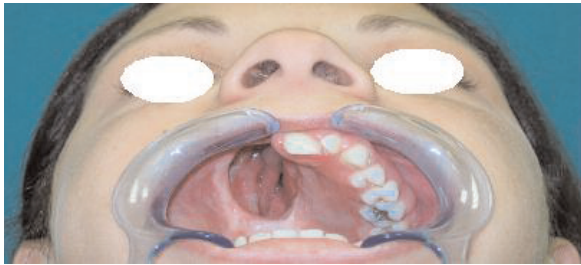

Figure 1. Patient with right hemi-maxillectomy, intraoral view.

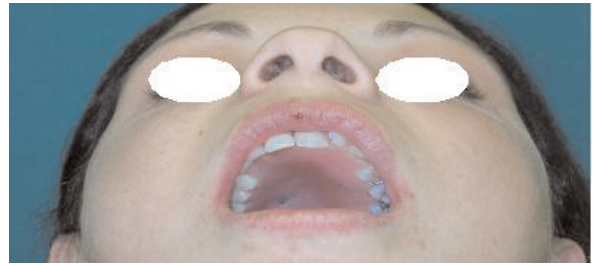


Figure 2. Patient with right hemi-maxillectomy wearing a palatal obturator, intraoral view.

The surgical defect frequently affects the hard and soft palate, producing an oronasal communication. When this occurs, the possibility of site's reconstruction should always be considered⁹. A postoperative obturator prosthesis is a good option in patients who underwent maxillectomy. The obturator prosthesis aims to restore both masticatory and speaking functions, as well as aesthetic appearance. Obturator prostheses can be built before surgery, which can cause a prosthesis misfit caused by after surgery anatomy modifications. Nevertheless, when the obturator prosthesis is delivered during the transoperative phase, it can improve the patient's postoperative conditions. Thus, the obturator allows to protect the operated area and optimize the healing process^{3,10,11}.

This article aims to underline the importance of implant-supported prosthesis rehabilitation in post-oncological patients.

Case Report

In this study is reported the case of a patient whose clinic history started in 1994. She was 4 years old when palate neoplastic mass was diagnosed. One year later the neof ormation mass was surgically removed. The histologic examination revealed the mass to be a pleomorphic adenoma of hard palate's minor salivary glands.

During the following years, the patient underwent several surgeries – in different hospitals – to remove recurring pleomorphic adenomas (Pas).

Six years later, in 2000, ablative surgery of right hard palate and alveolar process was performed, and a first obturator prosthesis was placed (Figures 1, 2, 3). Afterward, many obturators were necessary because of patient's young age: she was still growing up, and easily replaceable devices were needed in order to support

anatomy changes due to growth processes.

In 2005 the patient underwent left hemi-maxillectomy to remove recurred PA; during the surgery, ipsilateral lower orbital margin, orbital floor anterior area, upper, medium and part of lower turbinates and part of the nasal septum were removed. Fibula free flap was used to rebuild the surgical area (Figure 4). Vascular anastomosis between facial and peroneal arteries, left medial canthopexia and cutaneous left inguinal graft were performed in order to repair the donor site.

After this surgery, obturator prosthesis was no longer required. A mobile prosthesis was applied waiting for the possibility to provide a firmer and

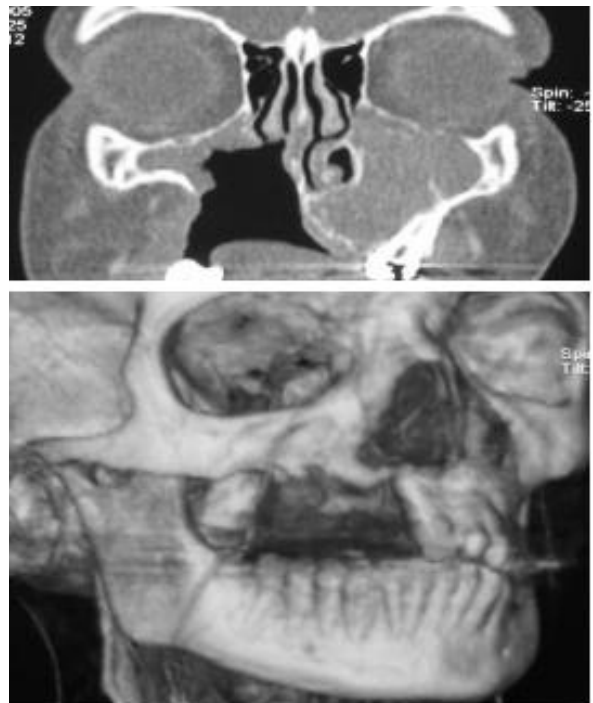


Figure 3. Patient with right hemi-maxillectomy, CT.

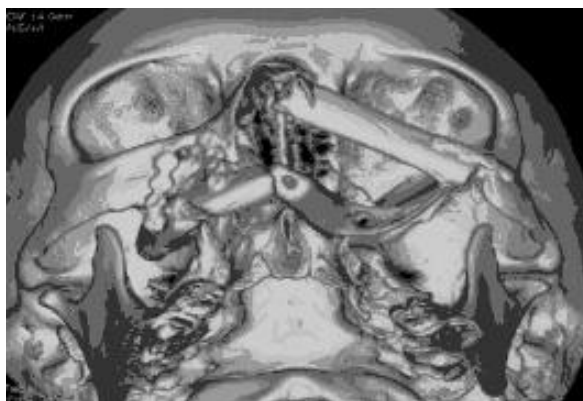

Figure 4. Patient after reconstruction with fibula free flap, CT.

more efficient prosthetic rehabilitation, such as fixed prosthesis. The patient did not undergo any radiotherapy.

When the patient was eighteen years old, three implants were placed in the restored left upper jaw, and four implants were placed in the right upper jaw in consideration of definitive prosthetic rehabilitation (Figure 5).

In 2009 the patient underwent another surgery: fornix deepening and paracrestal incision were performed, implants were exposed and healing caps were placed.

Implants were strengthened by solidarizing them with a titanium bar (Figure 6). This bar was welded to a second metal structure covering an extended part of the hard palate in order to sustain the upper prosthesis and guarantee its stability and efficiency by restricting its movements (Figure 7A-D)¹².

In the present clinical report, the patient presented a surgical defect – a communication between oral and nasal cavities – as a result of maxillectomy performed to remove a pleomorphic adenoma of minor salivary glands of the palate. To decrease the changes in patients' chewing, speech and swallowing promoted by hemi-maxillectomy, an obturator denture was required until the surgical site was restored.

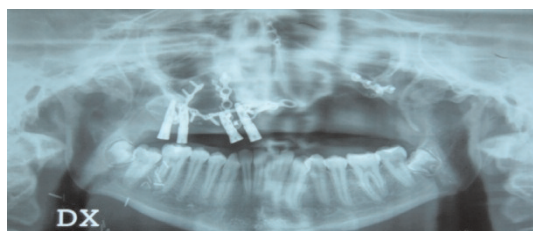


Figure 5. Patient with implants placed, OPG.

The obturator prosthesis guaranteed optimal tissues' healing, function and aesthetics restoration and separation of oral and nasal cavities.

Denture base with palatal obturator is a device built during the preoperative and installed in the transoperative period. A temporary obturator is required during postoperative period to enhance the healing process and to allow patients to speak and swallow; after healing of surgery site is completed, a final obturator can be provided.

The obturator prosthesis has several advantages: it provides a matrix to guide the healing process, reduces contamination of the oral surgical defect, restores partition between oral and nasal cavities, rehabilitates oral functions (speech and mastication), restores facial contour, reduces drooping and enhances patients' self-esteem due to the aesthetic improvement¹³.

Although it is an excellent device in terms of speech, mastication, swallowing and appearance rehabilitation, some factors can affect obturator's efficiency. Size of the maxillectomy defect can promote regurgitation of fluids or solids while drinking or eating, especially if it affects also the soft palate; in these cases, it is difficult to imitate the movement of the soft palate through a stiff device such as a prosthesis. In large defects it may be difficult to correct the nasal voice, especially if the prosthesis is incongruous and does not close the margins properly. Moreover, increased prosthesis' weight can affect obturator's retention and balance^{3,13}.

According to many studies, the reestablishment of function (swallowing and speech) and quality of life of maxillectomy patients is higher in cases of surgical reconstruction when compared with rehabilitation with palatal obturator. However, other papers^{3,14} reported no statistically significant difference in the quality of life in patients either treated surgically or with obturator.

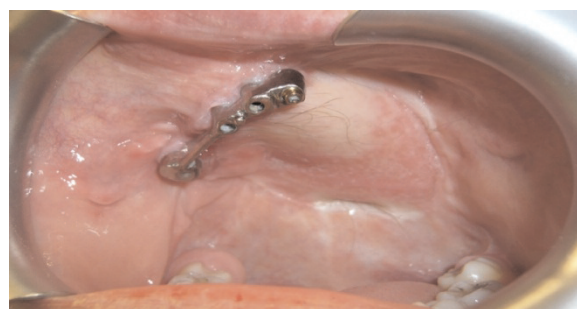

Figure 6. Implants solidarized with a titanium bar, intraoral view.

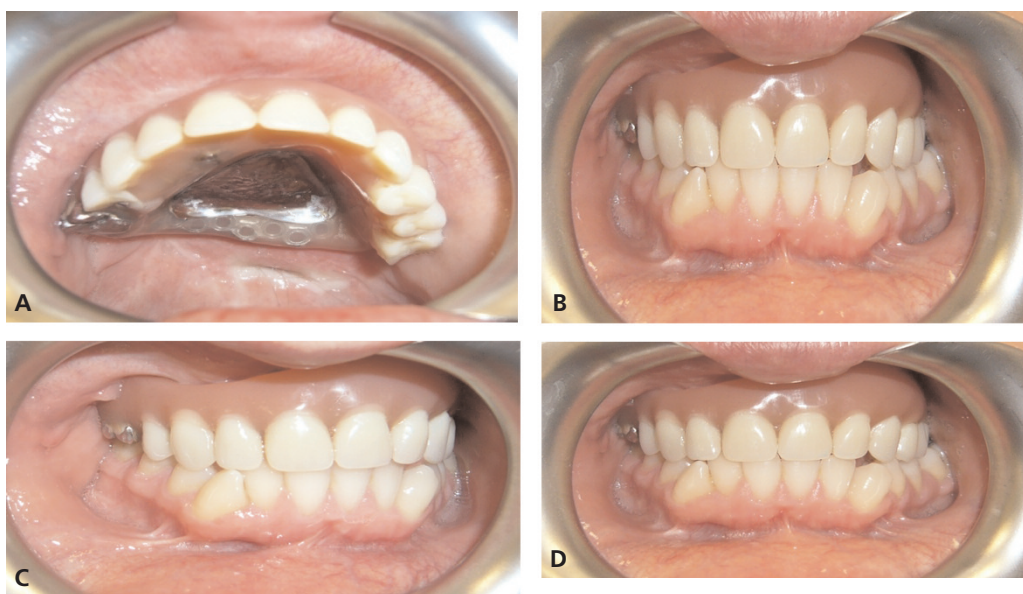


Figure 7. A-D, Patient with prosthesis inserted, intraoral view.

Therefore, it is impossible to plan a standard treatment for maxillectomy patients due to individual factors conditioning medical case and prognosis.

Nevertheless, the immediate rehabilitation after partial maxillectomy using a denture base with a palatal obturator is an excellent provisional option of oral rehabilitation for patients who underwent maxillectomy. This technique promotes several clinical benefits in the immediate postoperative period. Also, it enhances patients' quality of life and working activities; it facilitates patients' social reinclusion, minimizes the sequelae of surgical treatment and contributes to the success of further oral rehabilitation in sites where a second reconstruction is performed.

Conclusions

In these maxillectomized patients, such a complex prosthesis can be very useful and it can provide numerous advantages. Due to implants, it confers a degree of stability to rehabilitation that the oral structures, deformed by surgical treatment, are no longer able to provide. Because of these structures' modifications, a simple mobile prosthesis can show less efficiency. Fixed prostheses are the best option, because they guarantee stability, reduce mucosal inflammation and properly restore functional, mechanical and aesthetic

properties^{15,16}. Otherwise, these devices should be made so that the operator can remove them whenever necessary, to periodically check the health of the oral tissues underneath them, in order to intercept any relapse of the tumor^{17,18}.

Obtaining satisfactory results allows the patients to improve their quality of life. The choice of rehabilitation is always influenced by the clinical situation, patient expectations and economic possibilities.

Conflict of Interest

The Authors declare that they have no conflict of interests.

References

- 1) REDDY V, WADHWAN V, AGGARWAL P, SHARMA P, REDDY M. A benign salivary gland tumor of minor salivary gland mimicking an epithelial malignancy. *Contemp Clin Dent* 2015; 6: 247-249.
- 2) KHANDEKAR S, DIVE A, MUNDE P, WANKHEDE ND. Pleomorphic adenoma of the buccal salivary glands. *J Oral Maxillofac Pathol* 2015; 19: 111.
- 3) GOIATO MC, TAMAE AC, SILVA PIS, DOS SANTOS DM, LYDA MG, MORENO A, MAGRO-FILHO O, BERTOZ APM. Oral rehabilitation after surgical removal of pleomorphic adenoma. *J Craniofac Surg* 2011; 22: 1996-1999.
- 4) DANIELS JSM, ALI I, AL BAKRI IM, SUMANGALA B. Pleomorphic adenoma of the palate in children and

- adolescents: a report of 2 cases and review of the literature. *J Oral Maxillofac Surg* 2007; 65: 541-549.
- 5) MANSUR R, ORZEDALA-KOSZEL U, CZUPKALLO L, LOBACZ M. Pleomorphic adenoma of the palate: a case report and review of the literature. *Wspolczesna Onkol* 2013; 17: 103-106.
 - 6) KAWAHARA A, HARADA H, KAGE M, YOKOYAMA T, KOJIRO M. Characterization of the epithelial components in pleomorphic adenoma of the salivary gland. *Acta Cytol* 2002; 46: 1095-1100.
 - 7) BARNES L, EVESON JW, REICHART P, SIDRANSKY D, EDS. *World Health Organization Classification of Tumours. Pathology and Genetics of Head and Neck Tumours*. Lyon, France: IARC Press, 2005.
 - 8) SHARMA AB, BEUMER J III. Reconstruction of maxillary defects: the case for prosthetic rehabilitation. *J Oral Maxillofac Surg* 2005; 63: 1770-1773.
 - 9) CASSONI A, VALENTINI V, DELLA MONACA M, POMPA G, IANNETTI G. Keratocystic odontogenic tumor surgical management: retrospective analysis on 77 patients. *Eur J Inflammation* 2014; 12: 209-215.
 - 10) PARK KT, KWON HB. The evaluation of the use of a delayed surgical obturator in dentate maxillectomy patients by considering days elapsed prior to commencement of postoperative oral feeding. *J Prosthet Dent* 2006; 96: 449-453.
 - 11) GOIATO MC, SANTOS DM, VILLA LM. Obturator for rehabilitation of cleft palate with implant-supported retention system. *J Craniofac Surg* 2010; 21: 151-154.
 - 12) MISCH CE. Bone classification training keys. *Dent Today* 1989; 8: 39-44.
 - 13) BRAUNER E, JAMSHIR S, PAPI P, DI CARLO S, POMPA G. Obturator prostheses in post-oncological maxillofacial patients: our experience. *Senses Sci* 2014; 1: 119-122.
 - 14) CHEN HH, LEE LY, CHIN SC, CHEN IH, LIAO CT, HUANG SF. Carcinoma ex pleomorphic adenoma of soft palate with cavernous sinus invasion. *World J Surg Oncol* 2010; 8: 24.
 - 15) BRAUNER E, GUARINO G, JAMSHIR S, PAPI P, VALENTINI V, POMPA V, POMPA G. Evaluation of highly porous dental implants in postablative oral and maxillofacial cancer patients: a prospective pilot clinical case series report. *Implant Dentistry* 2015; 24: 631-637.
 - 16) POMPA G, SACCUCCI M, DI CARLO G, BRAUNER E, VALENTINI V, DI CARLO S, GENTILE T, GUARINO G, POLIMENI A. Survival of dental implants in patients with oral cancer treated by surgery and radiotherapy: a retrospective study. *BMC Oral Health* 2015; 15: 5.
 - 17) BRAUNER E, VALENTINI V, JAMSHIR S, BATTISTI A, GUARINO G, CASSONI A. Two clinical cases of prosthetical rehabilitation after a tumor of the upper maxilla. *Eur Rev Med Pharmacol Sci* 2012; 16: 1882-1890.
 - 18) BRAUNER E, VALENTINI V, GUARINO G, CASSONI A, JAMSHIR S, MINASI R. Osteoradionecrosis of a mandible: a case report of implant-supported rehabilitation. *Eur J Inflammation* 2013; 11: 565-571.