

PUBLISHED BY

INTECH

open science | open minds

World's largest Science,
Technology & Medicine
Open Access book publisher



2800+
OPEN ACCESS BOOKS



96,000+
INTERNATIONAL
AUTHORS AND EDITORS



89+ MILLION
DOWNLOADS



BOOKS
DELIVERED TO
151 COUNTRIES

AUTHORS AMONG
TOP 1%
MOST CITED SCIENTIST



12.2%
AUTHORS AND EDITORS
FROM TOP 500 UNIVERSITIES



Selection of our books indexed in the
Book Citation Index in Web of Science™
Core Collection (BKCI)

Chapter from the book *From Bench to Bedside - Trauma, Tumors, Spine, Functional Neurosurgery*

Downloaded from: <http://www.intechopen.com/books/from-bench-to-bedside-trauma-tumors-spine-functional-neurosurgery>

Interested in publishing with InTechOpen?
Contact us at book.department@intechopen.com

Surgical Treatment of Spinal Meningiomas

Antonino Raco, Alessandro Pesce and
Massimo Miscusi

Additional information is available at the end of the chapter

<http://dx.doi.org/10.5772/64421>

Abstract

Spinal meningiomas are common spinal tumors; in most cases they are benign and with a good surgical prognosis. However, specific location, infiltration of spinal cord, vascular encasement, or spinal root involvement can bring to a less favorable prognosis. We reviewed a series of 173 consecutive patients with spinal meningiomas treated from 1976 to 2011 in our institution, and data were stratified according to sex, age, symptoms, axial location, Simpson resection grade, and functional pre-/postoperative status. Particular attention was paid to description of those factors leading to a poor outcome. Functional improvement at follow-up was observed in 86.7% of cases, 6.4% of patients resulted stable, and 6.9% worsened; a low functional grade before surgery was connected to a lesser improvement after. Anterolateral meningiomas were the most represented (42.2%); a gross total resection (Simpson grade I and II) was conducted in 98.8% and a macroscopically complete removal without dural resection or coagulation (Simpson grade III) was performed in 1.2%. According to data from our series, negative prognostic factors seem to be: anterior or anterolateral axial implant, long-lasting symptoms before diagnosis, WHO grade > I, Simpson grade II and III resection, sphincter involvement, and worse functional grade at onset.

Keywords: spinal meningiomas, surgery, spinal tumors, recurrence, surgical outcome

1. Introduction

Spinal meningiomas (SM) account for 1.2–12% of CNS meningiomas, being relatively uncommon [1–3]. The typical clinical presentation consists of pain [4], followed by gait, sensory, and sphincter disturbances. The constant improvement of neuroimaging techniques, the use of intraoperative neuromonitoring, and the increasing reliability of the contemporary surgical

tools have further improved the prognosis of SM, already recognized as excellent by Cushing and Eisenhardt [5], more than 80 years ago, in their historical monograph. Since this cornerstone in SM literature, many series confirmed this finding [1, 6–9]. However, cases of anteriorly located or calcified lesions, cases of recurrences, and cases in which there is violation of the arachnoidal layer, invasion of spinal cord parenchyma, and encasement of vascular structure stand as exceptions to this rule.

2. Incidence, location, and subtypes

SM count for 25–46% of the intradural-extramedullary lesions, second to spinal schwannomas, which is the most frequent entity of this location [10]. SM favor females [4, 6, 11, 12], its incidence is significantly higher in Caucasians and Asian Pacific islanders than in Afro-Americans and Native Americans [13].

Despite being described at every age [14, 15], the highest incidence is in the fifth and sixth decade age group [4, 6, 7, 11]. Below the age of 18, predilection for female sex is not present. This feature, matched with a peak of incidence during peri-menopausal period, is consistent with the widely described and recognized neoplastic cells responsivity to female sex hormones, similar to what happens for intracranial meningiomas [11, 12]. The exact incidence of SM is not known even though is estimated about 0.5–2 cases per 100,000 persons per year [3].

The relatively higher incidence in the thoracic spine is also noted in current literature compared to the other biomechanically active segments [6–8, 16]. The dural attachment is most frequently found in the anterior/anterolateral dura. Our series (**Figure 1** and **Table 1**) confirms these data [1, 2, 6, 7].

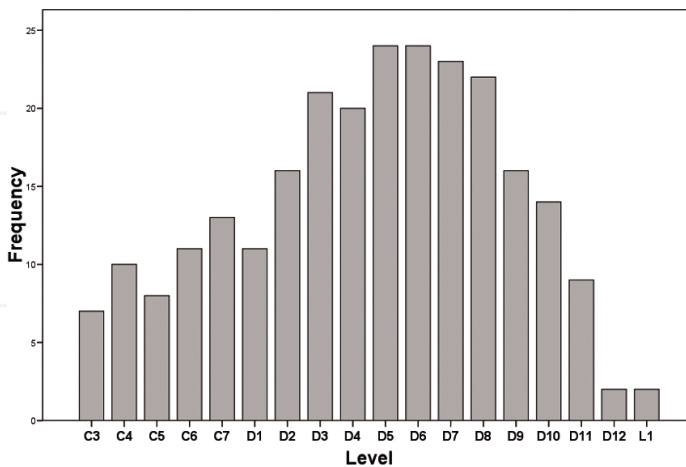


Figure 1. Incidence of spinal meningiomas in our cohort according to sagittal topography.

Total no. of patients	224
Lost to follow-up	15
Incomplete report (clinical and surgical)	22
Lesion involving CVJ	14
Residual cohort	173
Sex	
Woman	138 (79.8%)
Men	35 (20.2%)
Age	55.6 ± 13.1 years
Clinical presentation	
Pain	57 (32.9%)
Motor or gait disorders	55 (31.8%)
Paresthesias	53 (30.6%)
Sensory deficit	8 (4.6%)
Mean duration of preoperative symptoms	20.01 ± 18.86 months (range, 0–120 months)
Axial topography	
Posterior	11 (6.4%)
Posterolateral	42 (24.3%)
Anterolateral	73 (42.2%)
Anterior	15 (8.7%)
Lateral	32 (18.5%)
Simpson grade of resection	
I	52 pts (30%)
II	119 pts (68.8%)
III	2 pts (1.2%)
Neurological status at follow-up	
Improved	150 (86.7%)
Stable	11 (6.4%)
Worsened	12 (6.9%)
Sagittal topography according to biomechanical levels of the spine	
Subaxial cervical	14.2%
Cervicothoracic Junction	9.5%
Thoracic spine	75.5%
Thoracolumbar Junction	0.8%
Complications	
Total complication rate	7 (4.04%)
CSF leakage	3 (1.73%)
Spinal epidural hematoma	2 (1.15%)
Syringomyelia	1 (0.58%)
Adverse reaction to dural sealant	1 (0.58%)
WHO grading of the lesions	
I	170 pts (98.3%)
II	2 pts (1.15%)
III	1 pt (0.58%)

Table 1. Details of the final cohort.

SM histological subtypes are the same as their intracranial counterpart. The percentage of atypical/anaplastic SM is significantly lower than intracranial meningiomas [12]. In our series, WHO Grade I (**Table 1**) was the most represented subgroup of lesions in our cohort (98.3% of the lesions). These data are similar to other series [4, 6, 11, 12].

A higher incidence of SM is also well documented in patients suffering from neurofibromatosis. When a SM is detected in early life, it should raise suspicion of neurofibromatosis, especially in patients below the fourth decade and with extrathoracic sagittal location [12].

3. Diagnosis

3.1. Symptoms and physical findings

Literature recognize pain as the typical symptom at clinical onset of SM [6, 7, 17]. Pain can be axial, radicular, or radiating to upper or lower limbs, depending on the location of the tumor; it is commonly associated with paresthesias, hot and cold sensations, and sensory disturbances, followed by gait instability evolving in an obvious motor deficit, which is usually late due to the typical growth slowness of this lesions [2]. Sphincter impairment is a late finding and involves from 15 to 40% of the patients [18].

In our cohort, the most common disturbance at clinical onset was pain in 32.9% of cases (57 patients), followed by motor and gait disorder in 31.8% of cases, (55 patients); less frequently we observed paresthesias (30.6%, 53 patients), and occasionally a pure sensory disturbance was detectable (4.6%, 8 patients). Only 18.5% of patients complained a single disturbance at onset. The second disturbance in order of appearance was a motor disorder (61 patients, 35.3%) and occasionally a sphincter disturbance (10 patients, 5.8%). The average duration of symptoms was 20.01 ± 18.86 months (range, 0–120 months) (**Table 1**).

Pain was described as axial (cervical or thoracic; 30 patients; 17.34%), radicular (radiating to corresponding dermatome; 5 patients; 2.89%), or radiating to distant dermatomes (e.g. thoracic cord meningiomas with pain radiating to lower limbs; 22 patients; 12.71%). A total of 21 patients (12.13%) were retrospectively estimated to suffer from a pure radiculopathy, 37 from a pure myelopathy (21.38%), and 115 from myeloradiculopathy (66.47%).

3.2. Radiology

Standard X-ray plain film is of limited value, it may demonstrate pedicle or soma erosion, abnormalities in the normal spine curvatures [18]. X-ray standard myelography may outline a contrast block at the level of the extradural lesion, but it has been disused in the common everyday clinical practice. Spine contrast-enhanced CT scans provide detailed information about bony anatomy; it finds a contemporary huge value while investigating extensively calcified lesions or in defining the detailed anatomy of recurrent SM [6, 17].

Since its introduction (at our Institution in 1991), a preoperative magnetic resonance imaging (MRI) scans have become the gold standard in defining this pathology. T1w, T2w, T1w

gadolinium-enhanced sequences are routinely performed to investigate anatomical details of the lesions (**Figure 2A, B, E, and F**). Gadolinium-enhanced MRI imaging demonstrated an homogeneously enhanced mass delocating spinal cord parenchyma and nerve roots, intra-extradural extension of the lesion, and dural tail; it may not sufficiently help the differential diagnosis between spinal schwannomas and meningiomas [14].

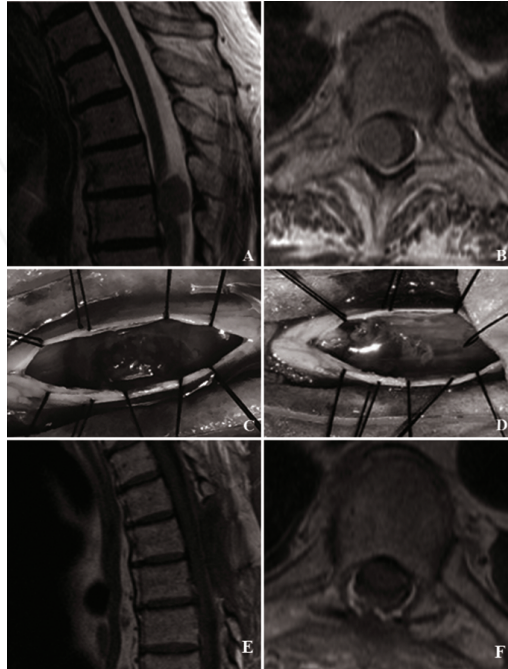


Figure 2. A. Sagittal T2w and B. Axial T1w gadolinium enhanced images of a thoracic spinal meningioma causing spinal cord dislocation. C. Intraoperative pre- and D. post- total resection of the lesion. Dura mater was extensively coagulated with no remnant of the disease, realizing a Simpson Grade of Resection II. E. Sagittal and F. Axial T1w gadolinium enhanced postoperative MRI demonstrating complete resection of the tumor and spinal cord decompression.

4. Surgical treatment—technical standards, pitfalls, and advances

Standard prone position is commonly used to approach a SM. Mayfield clamp may prove useful in cases of high subaxial cervical SM. A preoperative radioscopic localization of the involved levels is routinely carried out. After a standard midline skin incision and hypodermal tissues sharp dissection, fascia is incised in a standard midline fashion, and subperiosteal exposure of laminae and articular processes is performed. A standard laminotomy (or hemilaminectomy) exposes the dural sac. In case of thoracic spine anterior/anterolateral axially located lesion, a costo-trasversectomy to enlarge surgical corridor can be performed. Midline

temporary 4 or 5-0 silk tack-up sutures lead to a safer midline dural opening. Under magnification of the operative microscope, a microsurgical lesionectomy is performed (**Figure 2C and D**). Regardless of the potential infiltrative pattern or encasement of spinal vascular structures and nerve roots, a CUSA debulking is made to avoid any traction on the spinal cord.

Total removal is the target in all posteriorly located lesions, dural attachment must be removed, and a duraplasty completes the procedure. For anterior/anterolateral lesions, macroscopically complete excision is always associated with generous coagulation of the dural attachment.

Experience and literature have led us to strongly prefer laminotomy over laminectomy to perform a standard posterior midline approach for the evidence-based risk of iatrogenic postoperative instability. In order to clarify the difference between laminectomy and laminotomy, we use the term “laminotomy” to describe a “partial laminectomy” sparing of the medial facet of the articular process.

The reported incidence of postoperative instability in cervical spine is as high as 56% in more than four-level laminectomies and 11% in less than four level [19], whereas in thoracolumbar spine, instability appears in 25% of patients receiving more than two-level laminectomies [20]. Postoperative deformity is reported in 9.4% of patients receiving laminectomy compared to 3% of patients receiving laminotomy [21].

In most cases, a standard posterior approach allows surgeon to work in an adequate surgical corridor to achieve complete excision even for anterior/anterolateral lesions. In our experience, standard posterior approach is the gold standard in huge number of cases. However, intraextradural lesion with infiltration of the vertebral body, massively calcified lesions, anterior/anterolateral lesions, or recurrent tumors with spinal cord invasion stand as notable exceptions to this rule. In these cases, lateral or anterior approaches, with generous arthrectomy, pedicle resection, and partial/total vertebrectomy, performed to gain an optimal attachment control and safer spinal cord manipulation may be required [8, 16, 22, 23].

5. Neurological and functional outcome and complications

SM are slowly growing lesion, typically benign. Usually, they carry a fair neurological and functional prognosis [1, 6–9]. However, cases of anteriorly located or calcified lesions, recurrences, and cases in which there is violation of the arachnoidal layer, invasion of spinal cord parenchyma, and encasement of vascular structure stand as exceptions to this rule.

For this reason, one of the major efforts in SM surgery research and literature has historically been to preoperatively identify cases with a worse functional and neurological prognosis.

With the same aforementioned purpose, we critically reviewed our entire cohort of patients operated on for SM excision through a detailed retrospective analysis. Functional and neurological data about the outcome of each patient were recoded with Frankel [24] and McCormick [25] scales.

Frankel scale is a functional evaluation scale, initially conceived for spinal cord injury (SCI) but capable of assessing residual function “below” the level of a lesion. It is extremely easy

and extremely sensitive with respect to coarse variations of the spinal cord function. McCormick scale, designed for intramedullary neoplasms, provides information about spinal cord function in relation to the quality of life and patient’s independence (e.g. walking ability and the degree of impairment in the upper limbs). In our cohort, these scales appear to be strongly associated (Pearson’s bivariate correlation $p < 0.01$; $r = -0.820$ McCormick Pre-Frankel, Frankel -0.934 McCormick at Follow-Up), validating each other.

The scales are reported in **Table 2**.

Frankel scale	
A	Complete neurological injury—no motor or sensory function below the level of the injury
B	Preserved sensation only—no motor function below the level of the injury
C	Preserved motor nonfunctional—some motor function observed below the level of the injury
D	Preserved motor function—useful motor function below the level of the injury
E	Normal motor—no clinically detected abnormality in motor or sensory function with normal sphincter function; abnormal reflexes and subjective sensory abnormalities may be present
McCormick scale	
1	Intact neurologically, normal ambulation, and minimal dysesthesia
2	Mild motor or sensory deficit and functional independence
3	Moderate deficit, limitation of function, and independent w/external aid
4	Severe motor or sensory deficit, limited function, and dependent
5	Paraplegia or quadriplegia, even w/flickering movement

Table 2. Frankel and McCormick scales.

The preoperative Frankel functional classes most represented in our cohort were classes A, B, and C (respectively 15, 9, and 91 patients, amounting to 66.5% of the total). These classes reflect a deeper neurological impairment. Preoperative McCormick grade III, IV, and V was recorded, respectively, in 76, 36, and 18 patients (75.1% of the sample), whereas in the postoperative period, A, B, and C and III, IV, and IV classes were represented by 28.3% (49 patients) and 28.6% (53 patients).

The number of patients who experienced a significant improvement at follow-up amounted to 150 (86.7%), 11 were stable (6.4%) and the remaining 12 worsened (6.9%). In this cohort, the worst functional preoperative status showed a clear tendency to more modest improvements both on Frankel and McCormick scales (Pearson’s bivariate correlation, both $p < 0.01$, $r = 0.511$ and 0.618).

In our sample, a long duration of preoperative symptoms and severe preoperative impairment are related to worse outcomes; this result is similar to other reports [8, 26]. The author (A.R.) has previously reported a clear possibility of recovery even in patients harboring deep

functional preoperative impairment [26], outlining that age (under 60) and duration of preoperative impairment stand as the most important predictors of neurological recovery.

Anteriorly located lesions imply the most difficult setting in SM surgery [4, 7, 8, 12]. Consistent with the literature [7, 8], in our series, anterior/anterolateral lesions were identified as a subgroup with worse outcome compared to different axial topographies. Purely anterior lesions with arachnoidal adhesions to spinal cord and vascular encasement lead to an increased risk of spinal cord traction and surgical damage.

Some authors report massive calcification of the lesion as a predictor of neurological postoperative deterioration [6, 8]. In our series, only three patients harbored massively calcified spinal meningiomas, and thus this feature failed to reach statistical significance to confirm these findings.

Recurrence of SM in our sample was predictive of worse outcome. Our recurrence rate was 2.3% (4/173 cases). In the current literature, this rate varies between 1.3 and 13% [2, 4, 6, 9, 14, 18, 27, 28]. Obviously, WHO grading of the lesions is correlated with the probability of local relapses. In recurrent SM surgery, arachnoidal scarring caused by the first procedure can make tumor debulking harder and, despite the regular use of intraoperative neuromonitoring and CUSA, can lead to a worse outcome. In our cohort, patients harboring recurrent lesions were 4, a total of just two patients underwent a second SM excision surgery, and, although under-represented compared to the entire sample (2 of 4 patients on 173 patients of the entire cohort), showed a statistical association with worse outcomes. Therefore, whenever feasible, our experience suggests, according to Literature, that first surgery should always be as aggressive as possible [7, 23].

No postoperative death was recorded in our sample. Mortality rate in SM surgery is usually extremely low, ranging between 0.8 and 2% in series reported after 1999 [6–8].

6. Complications

In SM surgery, complications can be coarsely divided in two subgroups: neurological postoperative worsening and surgical complications causing neurological impairment. Among the last subgroup, most common surgical complications include spinal epidural hematoma, CSF leakage with or without deep or superficial infections, syringomyelia, and iatrogenic instability [2, 6, 7, 19–21].

The first subgroup was extensively discussed in the previous paragraph as well as concerns about iatrogenic instability are described in surgical treatment section.

Surgical complications counted for a total of 7/173 cases (4.04% of patients). A total of four patients (two postoperative spinal epidural hematoma, one syringomyelia, and one adverse reaction to dural sealant) required a revision surgery. The remaining underwent conservative treatments (three patients with CSF leakage resolved with lumbar drainage).

Lumbar drainage is reserved for the management of at least 4–5 days of persistent wound CSF leakage. In this series, three patients suffered from wound CSF leakage and were treated

conservatively by bedrest and lumbar drainage positioning. These complications were completely resolved in 5–7 days and did not require a surgical revision. Lumbar drainage use for CSF leakages treatment is hugely validated by experience and literature [29, 30].

No case of deep or superficial infection was recorded in our series. According to contemporary Literature, at present, deep and superficial infections are exceptional complications [7, 17].

7. Simpson grade of resection and recurrences

In the spinal compartment, recurring lesions are less common than meningiomas rising within the intracranial compartment (10–26%) [4]. Mirimanoff et al. [28] showed that the long-term follow-up of patients operated on for spinal meningioma removal can indicate up to 13% of recurrence at 10 years. However, the main limitation of this study is the small size of the cohort investigated (18 patients). Nakamura et al. [23] reported a recurrence rate as high as 30% at 12-year follow-up for patients who received a Simpson grade II resection. Setzer et al. [16] reported a stratification of recurrence probability by WHO histological grading: 1.4% for grade I, 50% for grade II, and 100% for grade III and IV, in 43.5 ± 24.8 months of follow-up.

As previously mentioned, recurrence of SM in our sample was predictive of worse outcome. Our recurrence rate was 2.3% (4/173 cases). In the current literature, this rate varies between 1.3 and 13% [2, 4, 6, 9, 14, 18, 27, 28].

Simpson grade I was obtained in 52 patients (30%). In all these cases, dural attachment, mainly posterior or posterolateral, was removed and a duraplasty with eterologous dural patch was performed. The rationale for this procedure is that literature analysis reveals a difference in terms of recurrence probability for Simpson grade I and II [2, 18, 23], and these data are confirmed in our series. In case of duraplasty, dural sealant was routinely used, since its use is substantially supported by literature [31].

Our routine postoperative SM follow-up protocol consists of a minimum 4 years of clinical and radiological follow-up reserved for patients with Simpson grade of resection I and WHO grade I lesions. Simpson grade of resection > I and WHO grade > I patients underwent a closer clinical and radiological follow-up. Such a follow-up protocol appears justified in relation to the natural history of SM, an extremely slowly growing lesion, which favors fifth/sixth decade. Some recurrences may be ignored because they never reach clinical significance in the lifespan of the patient. Our policy toward recurrent lesions is to reoperate only on those with MRI-demonstrated progressive regrowth tendency, because, according to literature and experience, operating a recurrent SM is often technically challenging [7, 8, 32, 33].

8. Conclusions

Spinal meningiomas are common primary spinal tumors, in most cases benign and with a good surgical prognosis. However, specific location, infiltration of spinal cord, vascular encasement,

or spinal root involvement can bring on to a less favorable prognosis. We can affirm that the negative prognostic factors in our study were: anterior or anterolateral axial location, protracted symptoms before diagnosis, WHO Grade > I, Simpson grade II and III resection, sphincter involvement, and worse functional grade at onset.

Author details

Antonino Raco¹, Alessandro Pesce^{1*} and Massimo Miscusi²

*Address all correspondence to: ale_pesce83@yahoo.it

1 "Sapienza" University, Rome, Italy

2 "ICOT" Hospital, Latina – "Sapienza" University, Rome, Italy

References

- [1] Bret P, Lecuire J, Lapras C, Deruty R, Dechaume JP, Assaad A. Intraspinal meningiomas. A series of 60 cases. *Neurochirurgie*. 1976; 22:5–22.
- [2] Solero CL, Fornari M, Giombini S, Lasio G, Oliveri G, Cimino C, Pluchino F. Spinal meningiomas: review of 174 operated cases. *Neurosurgery*. 1989; 25:153–160.
- [3] Westwick HJ, Shamji MF. Effects of sex on the incidence and prognosis of spinal meningiomas: a Surveillance, Epidemiology, and End Results study. *J Neurosurg Spine*. 2015; 29:1-6.
- [4] Maiuri F, De Caro ML, de Divitiis O, Vergara P, Mariniello G. Spinal meningiomas: Age-related features, *Clin Neurol Neurosurg*. 2011; 113(1):34–38.
- [5] Cushing H, Eisenhardt L. *Meningiomas: Their Classification, Regional Behavior, Life History, and Surgical End Results*. Springfield, IL, Charles C Thomas, 1938.
- [6] Sandalcioğlu EI, Hunold A, Müller O, Bassiouni H, Stolke D, Asgari S. Spinal meningiomas: Critical review of 131 surgically treated patients. *Eur Spine J*. 2008; 17:1035–1041.
- [7] Klekamp J, Samii M. Surgical results for spinal meningiomas. *Surg Neurol*. 1999; 52(6): 552–562.
- [8] Westwick HJ, Yuh SJ, Shamji MF. Complication avoidance in the resection of spinal meningiomas. *World Neurosurg*. 2015; 83(4):627-634.

- [9] Roux FX, Nataf F, Pinaudeau M, Borne G, Devaux B, Meder JF. Intraspinal meningiomas: review of 54 cases with discussion of poor prognosis factors and modern therapeutic management. *Surg Neurol*. 1996; 46(5):458–463.
- [10] Albanese V, Platania N. Spinal intradural extramedullary tumors. *J Neurosurg Sci*. 2002; 16:18–24.
- [11] Yoon SH, Chung CK, Jahng TA. Surgical outcome of spinal canal meningiomas, *J Kor Neurosurg Soc*. 2007; 42(4):300-304.
- [12] Saracenia C, Harrop J. Spinal meningioma: Chronicles of contemporary neurosurgical diagnosis and management. *Clin Neurol Neurosurg*. 2009; 111(3):221–226.
- [13] Kshetry VR, Hsieh JK, Ostrom QT, Kruchko C, Benzel EC, Barnholtz-Sloan JS. Descriptive epidemiology of spinal meningiomas in the United States. *Spine (Phila Pa 1976)*. 2015; 40(15):E886-E889.
- [14] Cohen-Gadol AA, Zikel OM, Koch CA, Scheithauer BW, Krauss WE. Spinal meningiomas in patients younger than 50 years of age: a 21-year experience. *J Neurosurg*. 2003; 98(3 Suppl):258–263.
- [15] Fortuna A, Nolletti A, Nardi P, Caruso R. Spinal neurinomas and meningiomas in children. *Acta Neurochir (Wien)*. 1981. 55(3-4), 329-341.
- [16] Setzer M, Vatter H, Marquardt G, Seifert V, Vrionis FD. Management of spinal meningiomas: surgical results and a review of the literature. *Neurosurg Focus*. 2007; 23(4):E14.
- [17] Kleklamp J, Samii M. “Extramedullary Tumors” in *Surgery of Spinal Tumors*. 1st ed. Springer-Verlag Berlin Heidelberg. 2007. p. 248-260.
- [18] Levy WJ Jr, Bay J, Dohn D. Spinal cord meningioma. *J Neurosurg*. 1982; 57(6):804–812
- [19] Katsumi Y, Honma T, Nakamura T: Analysis of cervical instability resulting from laminectomies for removal of spinal cord tumor. *Spine (Phila Pa 1976)*. 1989; 14(11): 1171-1176.
- [20] Papagelopoulos PJ, Peterson HA, Ebersold MJ, Emmanuel PR, Choudhury SN, Quast LM. Spinal column deformity and instability after lumbar or thoracolumbar laminectomy for intraspinal tumors in children and young adults. *Spine (Phila Pa 1976)*. 1997; 22(4):442-451.
- [21] McGirt MJ, Garces-Ambrossi GL, Parker SL, et al. Short-term progressive spinal deformity following laminoplasty versus laminectomy for resection of intradural spinal tumors: analysis of 238 patients. *Neurosurgery*. 2010; 66(5):1005-1012.
- [22] Arima H, Takami T, Yamagata T, et al. Surgical management of spinal meningiomas: A retrospective case analysis based on preoperative surgical grade. *Surg Neurol Int*. 2014; 5(Suppl 7): S333–S338.

- [23] Nakamura M, Tsuji O, Fujiyoshi K, et al. Long-term surgical outcomes of spinal meningiomas. *Spine (Phila Pa 1976)*. 2012; 37(10):E617-E623.
- [24] Frankel HL, Hancock DO, Hyslop G, et al. The value of postural reduction in the initial management of closed injuries of the spine with paraplegia and tetraplegia. *Paraplegia*. 1969; 7(3):179-192.
- [25] McCormick PC, Stein BM: Intramedullary tumors in adults. *Neurosurg Clin N Am*. 1990;1(3):609-630.
- [26] Ciappetta P, Domenicucci M, Raco A. Spinal meningiomas: prognosis and recovery factors in 22 cases with severe motor deficits. *Acta Neurol Scand*. 1988; 77(1):27-30.
- [27] Schick U, Marquaedt G, Lorenz R. Recurrence of benign spinal neoplasm. *Neurosurg Rev*. 2001; 24(1):20-25.
- [28] Mirimanoff RO, Dosoretz DE, Linggood RM, Ojemann RG, Martuza RL. Meningioma: analysis of recurrence and progression following neurosurgical resection. *J Neurosurg* 1985; 62:18–24.
- [29] Khan M, Rihn J, Steele G. et al. Postoperative management protocol for incidental dural tears during degenerative lumbar spine surgery: A review of 3,183 consecutive degenerative lumbar cases. *Spine (Phila Pa 1976)*. 2006; 31(22): 2609-2613
- [30] Shapiro SA, Scully T. Closed continuous drainage of cerebrospinal fluid via a lumbar subarachnoid catheter for treatment or prevention of cranial/spinal cerebrospinal fluid fistula. *Neurosurgery* 1992; 30(2):241-245.
- [31] Weinstein JS, Liu KC, Delashaw JB Jr, et al. The safety and effectiveness of a dural sealant system for use with nonautologous duraplasty materials. *J Neurosurg*. 2010;112(2):428-433
- [32] Caroli E, Acqui M, Roperto R, Ferrante L, D'Andrea G. Spinal en plaque meningiomas: a contemporary experience. *Neurosurgery* 2004; 55:1275–1279.
- [33] Gezen F, Kahraman S, Canakci Z, Beduk A. Review of 36 cases of spinal cord meningioma. *Spine (Phila Pa 1976)*. 2000; 25:727-731.