

Accepted Manuscript

Spontaneous Sealing of a Type Ia Endoleak after Ovation[®] Stentgraft Implantation in a Patient with On-Lable Aortic Neck Anatomy

Chiara Pranteda, Pasqualino Sirignano, Laura Capoccia, Wassim Mansour, Nunzio Montelione, Francesco Speciale

PII: S0890-5096(16)30212-6

DOI: [10.1016/j.avsg.2015.12.012](https://doi.org/10.1016/j.avsg.2015.12.012)

Reference: AVSG 2752

To appear in: *Annals of Vascular Surgery*

Received Date: 26 October 2015

Revised Date: 14 December 2015

Accepted Date: 17 December 2015

Please cite this article as: Pranteda C, Sirignano P, Capoccia L, Mansour W, Montelione N, Speciale F, Spontaneous Sealing of a Type Ia Endoleak after Ovation[®] Stentgraft Implantation in a Patient with On-Lable Aortic Neck Anatomy, *Annals of Vascular Surgery* (2016), doi: 10.1016/j.avsg.2015.12.012.

This is a PDF file of an unedited manuscript that has been accepted for publication. As a service to our customers we are providing this early version of the manuscript. The manuscript will undergo copyediting, typesetting, and review of the resulting proof before it is published in its final form. Please note that during the production process errors may be discovered which could affect the content, and all legal disclaimers that apply to the journal pertain.



1 **SPONTANEOUS SEALING OF A TYPE Ia ENDOLEAK**
2 **AFTER OVATION® STENTGRAFT IMPLANTATION**
3 **IN A PATIENT WITH ON-LABEL AORTIC NECK ANATOMY**

4
5 Chiara Pranteda, Pasqualino Sirignano, Laura Capoccia,
6 Wassim Mansour, Nunzio Montelione and Francesco Speciale

7
8 Vascular and Endovascular Surgery Division,
9 Department of Surgery “Paride Stefanini”,
10 Policlinico Umberto I, “Sapienza” University of Rome, Italy

11
12
13
14
15
16
17
18 *Corresponding Author:*

19 Chiara Pranteda, MD
20 Vascular and Endovascular Surgery Division,
21 Department of Surgery “Paride Stefanini”
22 “Sapienza” University of Rome
23 Policlinico Umberto I
24 Viale del Policlinico, 155
25 00161 – Rome, Italy
26 Tel/Fax: 0039 06 4940532
27 email: chiara.pranteda@gmail.com

28
29
30
31 **Key words:** Abdominal aortic aneurysms, AAA, EVAR complications, Type Ia endoleak,
32 Ovation Stentgraft

ABSTRACT

We report a case of an early type Ia endoleak after endovascular aneurysm repair (EVAR) of an abdominal aortic aneurysm by Ovation stentGraft implantation and spontaneously resolved without further reintervention.

Patient present a conic aortic neck but EAVR was performed within the instruction for use proposed by manufactory. At completion angiography a low flow type Ia endoleak was present and left untreated. Computed tomographic angiography (CTA) performed in 3rd postoperative day showed infolding of the two sealing rings. Patient was dismissed without further treatment. At 3-month follow-up the leak appeared spontaneously sealed with partial expansion of the two rings.

1 INTRODUCTION

2 Nowadays endovascular repair (EVAR) for abdominal aortic aneurysms (AAA) has
3 become the standard of practice, and a huge variety of endografts is now available to the
4 Vascular Physicians^{1,2}. Among those, the Ovation StentGraft (Trivascular, Inc, Santa
5 Rosa, CA, USA) offers the lowest profile (14F introducer sheath) of any commercially
6 available endograft increasing the number of patients suitable for EVAR including those
7 with smaller and tortuous common iliac arteries (CIAs)^{3,4}. Currently, Ovation StentGraft is
8 indicated for treatment of patients with AAA with a vascular morphology suitable for EVAR,
9 including: adequate iliac/femoral access, proximal aortic landing zone (inner wall diameter
10 between 16 and 30mm at 13mm below the lowest renal artery, and aortic angle of $\leq 60^\circ$ if
11 proximal neck is ≥ 10 mm and $\leq 45^\circ$ if proximal neck is < 10 mm), and distal iliac la nding zone
12 (at least 10mm in length, and with an inner wall diameter from 8 to 20mm).

13 This device has a technology characterized by two polymer-filled rings that conform
14 to the perimeter of the aortic neck. Rings are designed to ensure the sealing of the
15 endoprosthesis in order to reduce the risk of type Ia endoleak without the radial force of
16 other prostheses on the market. Despite this, the risk of type Ia endoleak due to
17 inadequate sealing of the endograft leading to sac repressurization and enlargement, with
18 a subsequent risk of wall rupture and death, is still present^{5,6,7,8}, although rare^{9,10}. In all
19 reported experiences, type Ia endoleaks has required reintervention or endograft
20 removal^{5,6,7,8}.

21 We report a case of spontaneous sealing of a type Ia endoleak after deployment of
22 an Ovation stentgraft in a patient with on-label aortic neck anatomy.

CASE REPORT

A 75-year-old man was admitted to our Unit for an asymptomatic AAA detected by duplex ultrasound scan (DUS). His medical history was significant for smoking, hypertension, hypercholesterolemia and previous laparoscopic cholecystectomy. On physical examination a pulsatile epigastric mass was evident; femoral and distal pulses were normally present on both sides.

Computed tomographic angiography (CTA) confirmed the presence of a saccular infrarenal AAA not extending above the aortic carrefour (maximum transversal diameter 45mm) with a huge amount of intraluminal thrombus and a short, conical proximal neck (Fig.1). Iliac axes and common femoral arteries were patent without stenosis, dilatation, and severe angulation.

EVAR procedure was planned using a non conventional endograft (Ovation StentGraft) to achieve a good proximal sealing. According to standard preoperative planning for Ovation³, diameters of the aorta were assessed at infrarenal (IR) level 19.6mm, IR-35 23.1mm, IR+13 28mm and IR+16 30.7mm.

Endovascular procedure was performed by Vascular Surgeons in an operating theatre equipped with a portable fluoroscopy unit (Euroamplin Alien, Eurocolumbus – Milan, Italy), under local anaesthesia via percutaneous access to common femoral artery at both groins.

Subsequently to femoral access, the tri-modular stent graft was delivered and deployed in three stages: unsheathing the 34mm main body, deploying the suprarenal bare-metal stent, and engaging the polymer to be delivered expanding the stent graft main body rings and adapting to the aortic neck. The iliac rings along the main body provide support for both limbs. The extra-support guidewire was partially retracted during polymer delivering. Contralateral gate was engaged during polymerization time. Iliac limbs were subsequently deployed (12x120mm in both sides) above the iliac bifurcations. After ballooning of the docking zones and the distal iliac landing zones, a completion angiography showed the presence of an early, high-flow type Ia endoleak. Therefore, proximal rings were dilated by 40mm compliant balloon catheter (Coda, Cook Inc, Bloomington, IN, USA). Completion angiography demonstrated a significant reduction of the proximal endoleak. At that time, no additional procedure was performed. Access haemostasis was achieved by percutaneous closure devices (Proglide, Abbott, Abbott Park, IL, USA).

1 Postoperative course was uneventful even in presence of type Ia endoleak
2 confirmed by DUS and CTA. Partial infolding of the two sealing rings was clearly evident at
3 postoperative CTA (Fig.2). Patient refused any further procedure and was then discharged
4 on 4th postoperative days in good general condition.

5 After 1 month, scheduled DUS control showed the absence of any endoleak with
6 complete thrombosis of the aneurismal sac.

7 A further CTA performed at 3 months from EVAR procedure, confirmed the
8 aneurysm exclusion with initial shrinkage of the sac (maximum diameter 43mm). As
9 showed in figure 3, the two sealing rings appeared much more expanded respect to the
10 first CTA performed in 3rd post-operative day.

11
12
13
14

DISCUSSION

Since first implantation, EVAR treatment aimed to prevent AAA rupture and consequent patient's death¹¹. Therefore, an perfused aneurismal sac after a completion angiography is considered as a technical failure¹¹. The most significant cause of persistent sac pressurization after EVAR and aneurysms enlargement until rupture is represented by type Ia endoleak¹². Although rare, with an estimated intraprocedural incidence of 3.3%, type Ia endoleak could lead to devastating results¹³. For those reasons, an aggressive management of intraoperative type Ia endoleak is supported by current evidence¹⁴, although not universally accepted^{15,16,17}.

Several adjunctive procedures have been proposed to correct type Ia endoleak including proximal stent graft extension, insertion of a Palmaz stent (Cordis, Miami Lakes, FL, USA), and coil embolization¹². Recently, fenestrated stent graft¹⁸, chimney technique¹⁹, and EndoAnchors (Aptus Endosystems Inc, Sunnyvale, Calif)²⁰ have been proposed. Conversion to open repair is still considered the last chance procedure to solve a type I endoleak²¹.

Despite this general agreement and the great variability of proposed solutions, type Ia endoleaks are not treated in all published EVAR experience. Bastos-Gonçalves et al reported spontaneous sealing of all but one type Ia endoleaks that developed after stent graft placement and ballooning of the sealing zones in a cohort of 15 patients¹⁵. Another study by Terramani et al on a series of 10 patients reported spontaneous resolution of type I endoleaks in 7 of them²¹. Recently, Millen et al in a series of persisting type Ia endoleaks after EVAR procedures reported that 94% of patients demonstrated spontaneous resolution on the first surveillance CTA. In their experience, recurrence of the endoleak is not reported, and no aneurysm-related deaths occurred (median follow-up of 27 months)¹⁷.

Nonetheless, despite those encouraging results Bastos-Gonçalves et al reported that at a median follow-up of more than 3 years, there was a higher recurrence of type Ia endoleaks, migration, secondary intervention, and conversion to open repair compared with a control group, although without statistically significant differences¹⁵.

Notably, Ovation stentgraft was never implanted in those series. This stentgraft represents a new concept of sealing by nonexpansive circumferential apposition of polymer-filled rings to aortic wall, and creates no outward force at the infrarenal aortic level. Ovation stentgraft's sealing mechanism is completely different from Nitinol based stentgrafts. It's therefore possible that Authors' conclusions^{15,17,21} could be considered unreliable for a different, not Nitinol depending sealing.

1 Occurrence of type Ia endoleak after Ovation stentgraft implantation is rare,
2 particularly in highly selected patients. Mehta, in the pivotal study on 161 patients,
3 reported no early case and only 2 cases during a one-year follow-up⁹. Those two patients
4 and all other reported in published series have been treated by open conversion or redo
5 endovascular procedures^{5,6,7,8,9}.

6 In our case the early onset of a type Ia endoleak was due to infolding of the two
7 sealing rings of the graft, as showed in postoperative CTA.

8 Our findings look very similar to the case recently reported by Gandini et al after 7
9 months from index EVAR procedure⁵. So the infolding of the polymer ring was the primary
10 cause of both the endoleaks. They explained the appearance of the late endoleak as
11 consequence of the continuous and prolonged stress on the aortic wall, resulting in aortic
12 cleft and loss of sealing⁵. Such considerations could not be applied to our case, due the
13 fact that the endoleak was evident since the completion angiography.

14 Moulakakis et al reported that an excessive oversizing (more frequently with the use
15 of the largest main-body available) in specific anatomical situation (conical and heavily
16 calcified proximal neck) could lead to device failure²². Nonetheless, in our case a 34mm
17 main-body was implanted in a conical, not calcified neck, ranging in diameter between 28
18 and 30.7mm, and the estimated oversizing of 21% was very close to the value
19 recommended by the manufactory (15-20%).

20 Our failure happened in the very early period and in a suitable aortic neck in
21 contrast with those experiences^{5,22}, so other causes should be identified to explain
22 immediate ring infolding. Our empiric idea was that in some way a packaging defect could
23 have conditioned an abnormal and insufficient distension of the two sealing rings, leading
24 to material failure. Of course, as the graft was not explanted we have not conclusive
25 evidences. From a speculative point of view, to send the delivery system to Trivascular for
26 a deep analysis could have been a valuable tool to better address the possible causes of
27 the device failure.

28 According with existing literature^{5,6,7,8}, we proposed a new endovascular approach
29 to the patient but he refused our strategy, deciding to wait the scheduled 30-day follow-up
30 prior of any further decision.

31 Despite this occurrence, after 30 days, type Ia disappeared at DUS and sealing
32 was correctly achieved. The 3-month follow-up CTA confirmed the sealing of the sac, and
33 showed the sealing rings to be much more distended compared to the first postoperative
34 CTA, yet not completely expanded. We could speculate that in some ways the polymer of

1 the sealing rings has undergone a further process of expansion associated with a
2 simultaneous aortic wall retraction ensuring a good proximal sealing, even in absence of
3 reintervention.

4 In conclusion, we could not reach conclusive evidences from the analysis of an
5 anecdotal case, but it could be interesting to evaluate the effect of an initial less
6 aggressive approach for tipe Ia endoleak after Ovation stentgraft deployment in larger
7 series.

8
9

10 FIGURES LEGEND

11
12

13 **Figure 1:** preoperative CTA. A: MPR reconstruction of the short, conic proximal
14 neck of the aneurysm; B: diameter of the aorta at infrarenal (IR) level 19.6mm; C: IR+13
15 28mm; D: IR+16 30.7mm.

16
17

18 **Figure 2:** pre discharge CTA. A: 3D volume rendering reconstruction whit evidence
19 of a type Ia endoleak; B: correctly deployment of the Ovation endograft in the infrarenal
20 level; C: partial infolding of the first sealing ring; D: partial infolding of the second sealing
21 ring

22
23

24 **Figure 3:** CTA after 3 months. A: 3D Volume rendering reconstruction whit
25 evidence of spontaneous resolution of the type Ia endoleak; B: absence of the migration of
26 the endograft in the infrarenal level; C, D partial expansion of the infolding of the both
27 sealing rings.

28
29

30
31

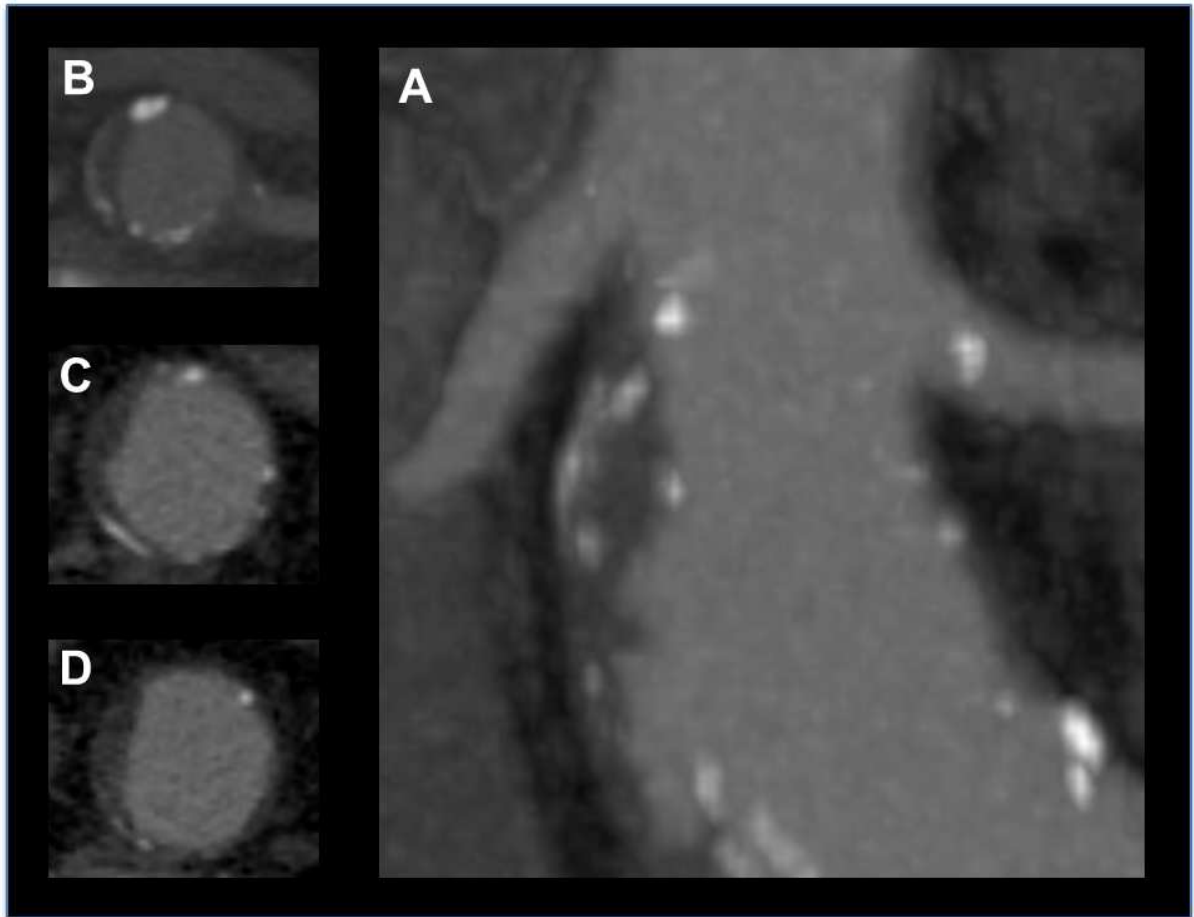
32
33

34

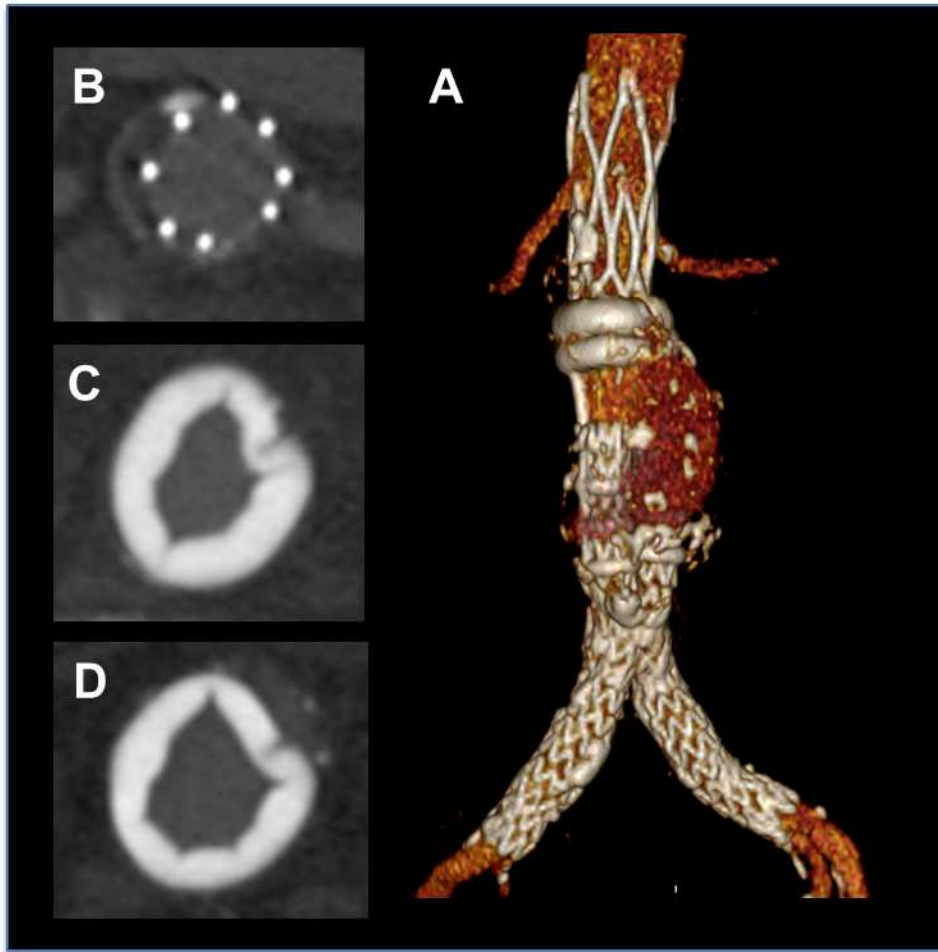
1
2
3**REFERENCES**

-
- ¹Carpenter JP, Baum RA, Barker CF, et al. Impact of exclusion criteria on patient selection for endovascular abdominal aortic aneurysm repair. *J Vasc Surg* 2001;34:1050-4.
- ²Choi ET, Wyble CW, Rubin BG, et al. Evolution of vascular fellowship training in the new era of endovascular techniques. *J Vasc Surg* 2001;33:S106-10.
- ³de Donato G, Setacci F, Sirignano P, et al. Ultra-low profile Ovation device: is it the definitive solution for EVAR? *J Cardiovasc Surg (Torino)*. 2014 Feb;55(1):33-40. Review.
- ⁴Trellopoulos G, Georgakarakos E, Pelekas D, et al. Initial single-center experience with the ovation stent-graft system in the treatment of abdominal aortic aneurysms: application to challenging iliac access anatomies. *Ann Vasc Surg*. 2015 Jul;29(5):913-9.
- ⁵Gandini R, Del Giudice C, Abrignani S, et al. Inexplicable late type Ia endoleak associated with the low-profile ovation endograft in a patient with favorable neck anatomy: treatment with transcaval coil embolization. *J Endovasc Ther*. 2015 Jun;22(3):426-30.
- ⁶Mangialardi N, Ronchey S, Kasemi H, et al. Percutaneous endovascular aneurysm repair with the ultra-low profile Ovation Abdominal Stent-Graft System. *J Cardiovasc Surg (Torino)*. 2013 Oct;54(5):581-7.
- ⁷de Donato G, Setacci F, Bresadola L, et al; TriVascular Ovation Italian Study. Aortic neck evolution after endovascular repair with TriVascular Ovation stent graft. *J Vasc Surg* 2015, *in press*.
- ⁸Mazzaccaro D, Stegher S, Occhiuto MT, et al. Immediate and Late Open Conversion after Ovation Endograft. *Ann Vasc Surg*. 2015 Oct;29(7):1450-9.
- ⁹Mehta M, Valdés FE, Nolte T, et al. One-year outcomes from an international study of the Ovation Abdominal Stent Graft System for endovascular aneurysm repair. *J Vasc Surg*. 2014 Jan;59(1):65-73.
- ¹⁰Sirignano P, Capoccia L, Menna D, et al. Pushing forward the limits of EVAR: new therapeutic solutions for extremely challenging AAAs using the Ovation[®] stent graft.
- ¹¹Chaikof EL, Blankensteijn JD, Harris PL, et al; Ad Hoc Committee for Standardized Reporting Practices in Vascular Surgery of The Society for Vascular Surgery/American Association for Vascular Surgery. Reporting standards for endovascular aortic aneurysm repair. *J Vasc Surg* 2002;35:1048-60.

- ¹²Candell L, Tucker LY, Goodney P, et al. Early and delayed rupture after endovascular abdominal aortic aneurysm repair in a 10-year multicenter registry. *J Vasc Surg* 2014;60:1146-53.
- ¹³Harris PL, Vallabhaneni SR, Desgranges P, et al. Incidence and risk factors of late rupture, conversion, and death after endovascular repair of infrarenal aortic aneurysms: the EUROSTAR experience. European Collaborators on Stent/graft techniques for aortic aneurysm repair. *J Vasc Surg* 2000;32:739-49.
- ¹⁴Veith FJ, Baum RA, Ohki T, et al. Nature and significance of endoleaks and endotension: summary of opinions expressed at an international conference. *J Vasc Surg* 2002;35:1029-35.
- ¹⁵Bastos Gonçalves F, Verhagen HJ, Vasanthanathan K, et al. Spontaneous delayed sealing in selected patients with a primary type-Ia endoleak after endovascular aneurysm repair. *Eur J Vasc Endovasc Surg* 2014;48:53-9.
- ¹⁶Kim SM, Ra HD, Min SI, Jae HJ, Ha J, Min SK. Clinical significance of type I endoleak on completion angiography. *Ann Surg Treat Res*
- ¹⁷Millen AM, Osman K, Antoniou GA, et al. Outcomes of persistent intraoperative type Ia endoleak after standard endovascular aneurysm repair. *J Vasc Surg*. 2015 May;61(5):1185-91.
- ¹⁸Katsargyris A, Yazar O, Oikonomou K, et al. Fenestrated stent-grafts for salvage of prior endovascular abdominal aortic aneurysm repair. *Eur J Vasc Endovasc Surg*. 2013;46:49.
- ¹⁹Montelione N, Pecoraro F, Puipe G, et al. A 12-Year Experience With Chimney and Periscope Grafts for Treatment of Type I Endoleaks. *J Endovasc Ther*. 2015 Aug;22(4):568-74.
- ²⁰Jordan WD Jr, Mehta M, Varnagy D, et al. Early results of the ANCHOR prospective, multicenter registry of EndoAnchors for type Ia endoleaks and endograft migration in patients with challenging anatomy. *J Vasc Surg* 2014;60:1460-7.
- ²¹Terramani TT, Chaikof EL, Rayan SS, et al. Secondary conversion due to failed endovascular abdominal aortic aneurysm repair. *J Vasc Surg* 2003;38:473-7.
- ²² Moulakakis KG, Mylonas SN, Kakisis J, et al. Commentary: Implications of Ovation's unique sealing mechanism. *J Endovasc Ther*. 2014 Dec;21(6):839-40.

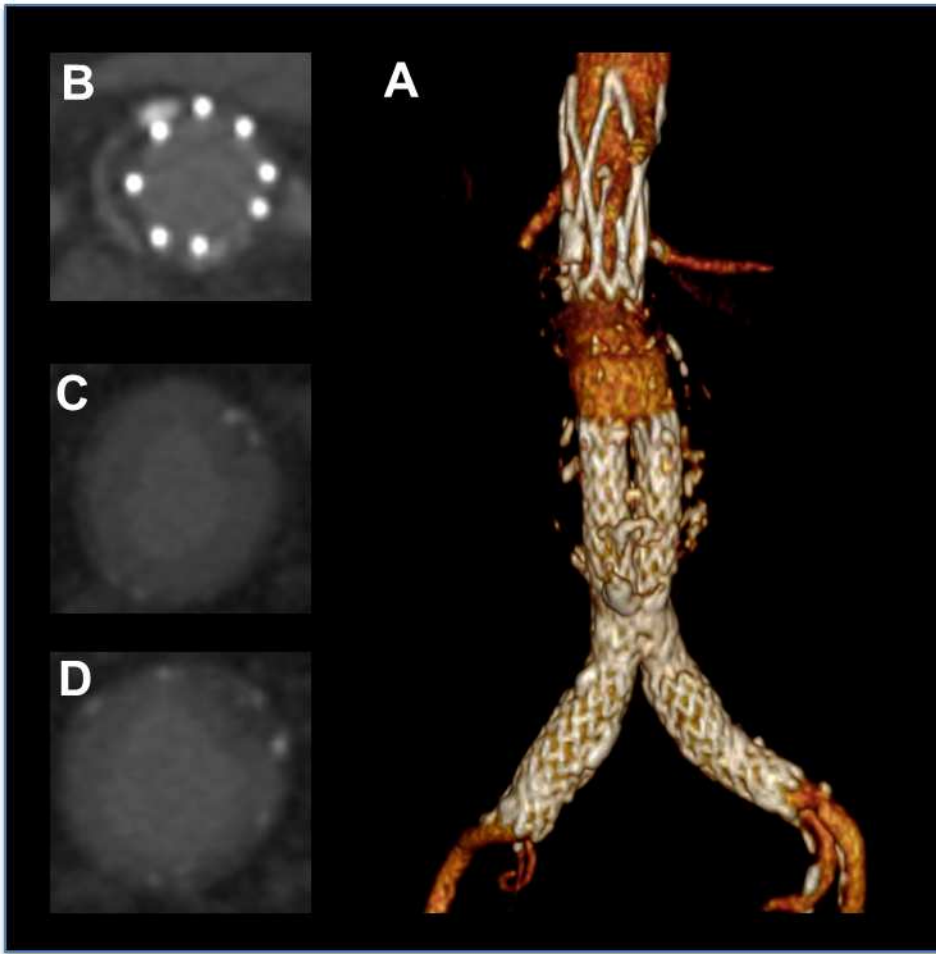


ACCEPTED



ACCEPTED

ACCEPTED



ACCEPTED

ACCEPTED