

## Marked Efficacy of Rituximab in Multifocal Motor Neuropathy Associated with Chronic Lymphocytic Leukemia

Laura Fionda; Tiziana De Santis; Elisabetta Bucci; Stefania Morino; Antonella Di Pasquale; Francesca Mauro; Giovanni Antonini\*

### \*Prof Giovanni Antonini, MD

Department of Neurological Sciences, Mental Health and Sensory Organs (NESMOS), "Sapienza" University of Rome, Italy

Tel: 00351 9349 48284; Email: daniela.amorim@sapo.pt

### Abstract

The authors describe a patient who presented a multifocal motor neuropathy (MMN) associated with a high anti-ganglioside antibody (anti-GM1 and anti-GD1) titer at the clinical onset of a B-cell chronic lymphocytic leukemia (B-CLL). Immunomodulation (IVIg plus cyclosporine) resulted in a neurological improvement and reduced anti-ganglioside antibody titers, both of which remained stable for at least six years. After this period, the patient had a severe relapse of the neuropathy, which was independent of the clinical course of the B-CLL. Both IVIg and cyclophosphamide were ineffective, and the patient became tetraplegic within six months; in the meantime, the patient displayed an increased antiganglioside antibody titer. Treatment with rituximab (RTX), which is designed to selectively inhibit B cell function, resulted in a dramatic, prompt and long-lasting neurological improvement as well as a reduced anti-ganglioside antibody titer. Although there are no previous reports of MMN in patients with B-CLL, the efficacy of RTX in the treatment of MMN in this patient may be considered remarkable. The expansion of B-cell clones may be a prerequisite for RTX effectiveness in MMN, and in dysimmune neuropathies in general.

### Keywords

B-cell chronic lymphocytic leukemia; autoimmunity; multifocal motor neuropathy; rituximab

### Introduction

B-cell chronic lymphocytic leukemia, besides being a malignant hematologic disease, is also considered a complex immunologic disorder that is characterized by a paradoxical coexistence of an excess of autoimmune phenomena and a status of immune deficiency [1]. In particular, patients with CLL have a high prevalence of autoimmune hematologic diseases, caused by autoantibodies produced by clonal or polyclonal B-cells [2, 3], and progressively develop a susceptibility to infections because of severe hypogammaglobulinemia. These immune-mediated mechanisms have even been called into question in the pathogenesis of peripheral neuropathies associated with CLL, believed to be related to the nerve infiltration of malignant cells [4, 5].

Rituxan (Rituximab-RTX) is a chimeric (mouse/human) monoclonal antibody that eliminates B lymphocytes by targeting the CD20 antigen and inducing apoptosis and complement- and antibody-dependent cytotoxicity [6]. It drastically reduces peripheral CD19-positive B lymphocytes and prevents the

formation of new antibody-secreting cells. RTX has proved to be effective in the treatment of both B-cell lymphoid malignancies and B-cell-mediated autoimmune diseases [3, 7, 8, 9]. Evidence showing that B cells and autoantibodies are involved in the pathogenesis of several neurological diseases has prompted a therapeutic strategy based on the selective inhibition of B-cell function to treat a large number of neurological dysimmune conditions [10]. In this regard, several reports have suggested that RTX may be beneficial to patients with multifocal motor neuropathy (MMN) [11, 12]. RTX is, however, considered an “add on” treatment in MMN [13] because its efficacy has been defined as “quite modest, delayed in time, and confined to some instances” [14, 15] and it could not show a long term response [16].

This study documents a case of MMN associated with CLL (the first in the literature to our knowledge) in which RTX induced a dramatic, prompt and long-lasting response.

We hypothesize that the expansion of B-cell clones may be a prerequisite for RTX efficacy in dysimmune neuropathies. Despite being anecdotal, the case we describe lends support to this hypothesis.

## Case Report

A 69-year-old patient with MMN and B-CLL was admitted to our department because his neurological disease had worsened. His clinical history is summarized in Figure 1.

He had, nine years before, presented a painless, progressive weakness in the right hand, followed, two months later, by weakness in the left hand and skin eruptions in his trunk, arms and legs. The patient did not complain of sensory symptoms. Nerve conduction studies (NCS) had shown motor conduction blocks in the median and ulnar nerves. A skin biopsy had shown vasculitic urticaria, while a hematological evaluation had revealed a B-cell CLL. Grade 4/5 weakness (MRC) in right/left hand muscles and wrist extensors, and fasciculation on the triceps brachii and quadriceps femoris, without sensory impairment, had been detected at the neurological examination. The cerebrospinal fluid had been unremarkable, while the blood IgM anti-GM1 antibody titer had been 1:19.200 (ELISA n.v. <1:600). A diagnosis of MMN associated with CLL had been made.

Prednisone (50 mg/day) and oral cyclophosphamide (CTX) (2mg/kg/day), had initially effectively treated the CLL and vasculitic urticaria; however, the weakness had subsequently worsened, involving the proximal muscles of the upper limbs and left quadriceps (Rankin scale: 2-3). The start of intravenous immunoglobulin (IVIg) (2g/Kg) plus cyclosporine (CSA 3mg/kg/day) had been followed both by an improvement in strength (Rankin scale: 1) and a decrease in anti-GM1 antibody titer (1:500) within one year. During the following six years both the hematological and the neurological picture had remained stable, and both prednisone and cyclosporine had been tapered to 5 mg/day and 1.5 mg/kg/day respectively. In September 2010, the patient's muscle strength began to deteriorate again and, one month later, he was admitted to our department. He showed a slight/moderate disability (Rankin 3-4). The neurological examination revealed weakness in the proximal and distal muscles of the upper and lower limbs (MRC sum-score 60/90: left deltoid 4/5, right/left biceps and extensor digitorum 4/5, right opponens pollicis and abductor pollicis brevis and right/left intrinsic muscle 3/5, right ileopsoas 4/5, right/left gluteus maximus 4/5, tibialis anterior 4/5, extensor allucis longus 4/5, extensor and flexor digitorum 4/5) and atrophy of the right/left interosseous and right thenar muscles; moreover, deep tendon reflexes were absent, while sensory functions were normal.

NCS showed low distal CMAP amplitude, motor conduction blocks, motor temporal dispersion, reduction of motor conduction velocity and increased F wave latency in the right ulnar and left median nerves (table 1 and figure 1). Sensory potential amplitude was normal in right ulnar and left median nerves, and slightly reduced in right sural nerves was (11 uv; 18 uv; 6 uv respectively); sensory conduction velocity in these nerves was normal (51 m/s; 50 m/s; 42 m/s respectively). The EMG study showed neurogenic damage to the proximal and distal muscles in the upper and lower limbs.

The immunological study revealed a high titer of IgM anti-GM1 antibodies (ELISA 231 Eu/ml. n.v.<25 Eu/ml) and anti-GD1b IgM antibodies (41.7 Eu/ml. n.v.<25 Eu/ml). CSF was unremarkable (cell 1/mm<sup>3</sup> protein 30 mg/dl, glucose 61 mg/dl). An extensive hematological re-evaluation confirmed the diagnosis of B-cell CLL in a stable phase.

A sural nerve biopsy showed an axonal neuropathy without evidence of cell infiltration.

Two monthly courses of IVIg (2g/kg) and two monthly courses of IVIg (2g/Kg) plus IV CTX (1g/m<sup>2</sup>) were of no benefit. In the meantime, the patient had become unable to walk, feed and dress himself (Rankin scale: 5; MRC sum-score 45/90).

We started RTX (375 mg/m<sup>2</sup>, once a week for 4 weeks) plus prednisone (25 mg/day). Within one month, the patient showed an improvement in muscle strength, which progressed in the following months. Three RTX courses were repeated, respectively at 6, 12 and 24 months. All the RTX infusions were well tolerated. One year after the start of treatment, the patient was able to get up from a chair, walk without any aid, feed and dress himself; he started driving and participating in social activities again (Rankin scale: 2). IgM anti-GM1 antibodies had dropped to 127.7 Eu/ml. The electrophysiological study showed a reduction of motor conduction blocks (Table 1).

At present the patient is under clinical observation, and is being treated with low prednisone dosages (5 mg/alternate day). He continues to feel well and leads an almost normal everyday life.

## Discussion

The clinical and electrophysiological characteristics in this case (i.e. motor, asymmetric neuropathy, with predominant upper limb involvement and multifocal motor conduction blocks) fulfil the diagnostic criteria for MMN [17]. We excluded the hypothesis of a neoplastic infiltration of the nerves on the basis of the course the neuropathy (which was independent of the course of the CLL), the prevalent motor involvement and, lastly, the results of both the nerve biopsy and CSF examination [18]. On the other hand, we considered the hypothesis of an immune-mediated neuropathy strongly supported by the high titer of both the anti-GM1 IgM and anti-GD1b IgM, as well as by the good clinical response to immunomodulating therapy. Similarly, the effect of immunomodulating treatment upon nerve temporal dispersion has been reported in one or more nerve segments in eight of nine patients with MMN [19].

Though MMN has not previously been reported in patients with CLL, autoreactivity against different types of gangliosides has been observed in CLL [20]. A high anti-GM1 IgM antibody titer, while not specific to MMN, is more frequent in this neuropathy than in other neuropathies [21]. Moreover, anti-GD1b IgM antibodies are associated with an immune-mediated neuropathy in over 80% of patients [17]. IgM reactivity to GD1b has been associated with a predominant involvement of sensory fibers [22, 23], which may explain the moderate loss of sensory nerve fibers detected in the sural nerve of our patient.

Since the introduction of IVIg as first-line treatment for MMN, the majority of MMN patients benefit from this treatment, which has negligible side effects [24]. However, the effectiveness of IVIg in some patients may decline over time [25]. Cyclophosphamide, if necessary combined with IVIg, is the main therapeutic alternative in such cases [26], but even this may, as happened in our patient, be ineffective.

Given its ability to markedly deplete B-cells, RTX has been exploited to disrupt the production of antibodies in primary autoimmune cytopenias, as well as in autoimmune cytopenias related to CLL as well as other chronic lymphoproliferative diseases [7, 9, 27]. Recent years have witnessed growing interest in the use of RTX to treat autoimmune neuropathies related to IgM antibody anti-gangliosides or glycolipids, in which autoreactive B cells play a central role. The efficacy of RTX however remains a controversial issue [11, 12]. Rituximab has been reported to be effective in some patients with MMN [11, 28], as well as in small groups of IVIg-resistant MMN patients [14, 29]. Moreover, RTX was effectively used to stabilize a patient with MMN who was becoming increasingly less responsive to IVIg [14, 30]. By contrast, RTX was unable improve the clinical symptoms in six patients with an IVIg-dependent relapsing polyneuropathy [31] or to reduce the mean total IVIg dosage in six patient with MMN [28]. However, in the same study, the authors stress that RTX may be effective in isolated cases, depending on the pathogenic role of CD20 lymphocytes.

Our patient showed a marked and long-lasting clinical improvement following treatment with RTX, accompanied by a significant reduction in anti-ganglioside IgM antibodies. Other authors have described a CLL patient with a severe axonal neuropathy, which was refractory to immunosuppressive therapies but improved significantly after RTX was started [3].

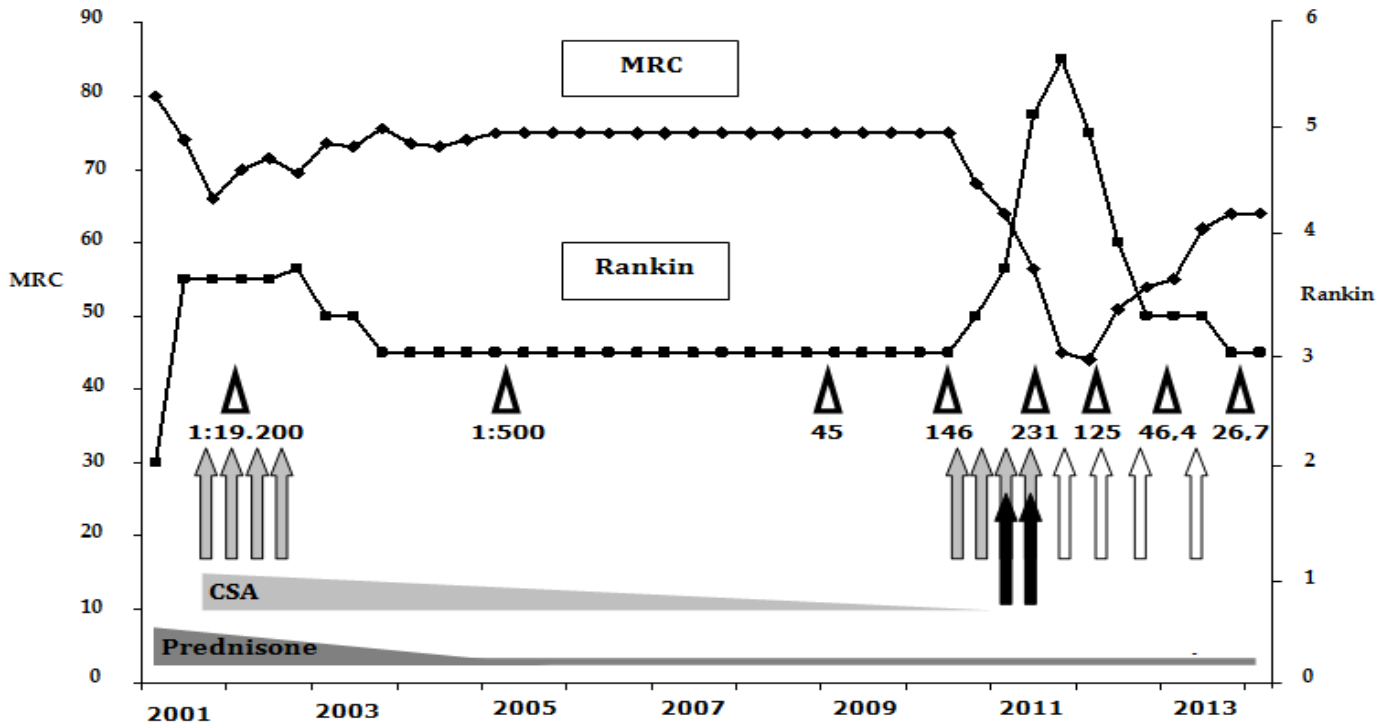
We hypothesize that the marked efficacy of RTX in both cases was conditioned by the underlying B-CLL.

The role of leukemic cells in the pathogenesis of CLL-associated autoimmune disorders has yet to be fully understood. Indeed, most of the antibodies involved in autoimmune disorders are polyclonal IgG, produced by non-clonal B cells, while leukemic cells express monoclonal IgM antibodies. Moreover, immunosuppressive treatment may inhibit autoimmune manifestations, without affecting the clonal expansion of CLL. Finally, leukemic cells often express antibodies with a polyreactive affinity for different antigens. In conclusion, several elements point to a predominantly indirect role of leukaemic clones in the pathogenesis of CLL-associated autoimmune disorders [7]. However, RTX may act either on clonal or polyclonal B-cells, as demonstrated in cold agglutinine disease and in cryoglobulinemia, both of which are sustained by a B-cell clonal expansion [7, 32].

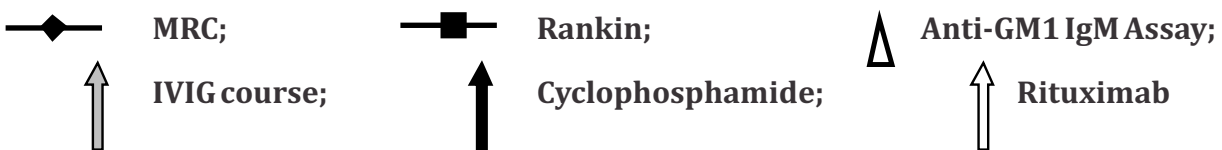
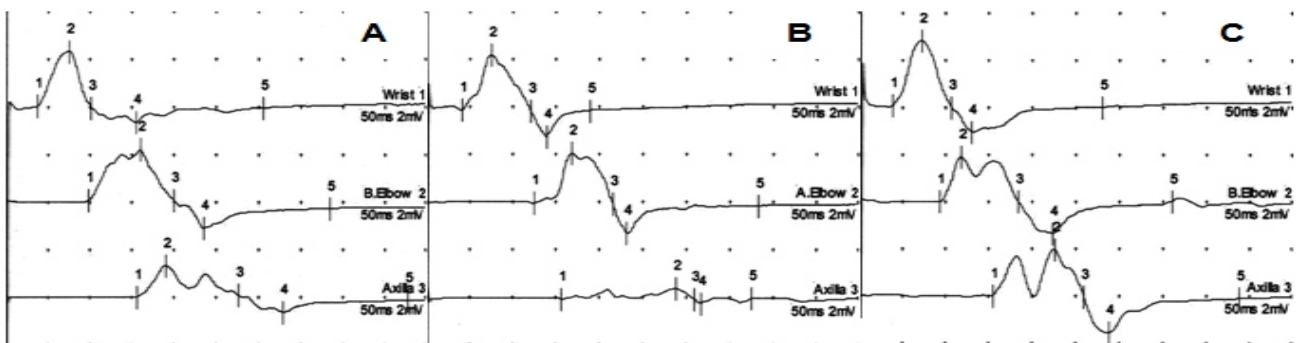
Whatever the underlying mechanism of the immunological disorder is, it seems reasonable to hypothesize that the elimination of monoclonal or polyclonal autoreactive CD20+ lymphocyte clones may explain the therapeutic activity of RTX in this and other similar cases of Ig-M immune-mediated neuropathy, as well as in other neurological disorders and autoimmune cytopenias associated with CLL [31, 33, 34]. Noteworthy, the comparison of IgM anti-GM1 antibodies from patients with Guillain-Barré syndrome and MMN demonstrated a much restricted clonal diversity in the latter, suggesting that therapies aimed to target the autoreactive clones may be useful in MMN [35].

The dosage interval and duration of therapy in our case was the recommended dose of 375 mg/m<sup>2</sup> IV administered weekly for 4 weeks [36], and subsequently followed by repeated courses according to the patient's clinical condition. The therapy was well tolerated, with no adverse effects being recorded either during or after treatment; this finding provides further proof of the safety of this drug [37].

**Figures**



RIGHT ULNAR NCS		A-Oct 2010	B-May 2011	C-Jan 2013
Motor NCV	m/s	37,4	32,1	43,2
Distal Latency	msec	3,7	4,2	3,8
CMAP amplitude	mv	2,4	2,3	2,8
F wave latency	msec	42,9	54,8	37,4
Prox/Dist CMAP ampl	%	56,4	20,7	68,2



**Figure 1:** Clinical course described by MRC and Rankin Scales, associated with the anti-GM1 IgM assays done during the follow up visits and the treatments occurred (A); electrophysiological findings: note Motor NCV increase and F wave latency reduction, especially in the last recording in January 2013 (B).

## Table

**Table 1:** Nerve conduction study of median and ulnar nerves at October 2010 (A), May 2011 (B), January 2013 (C).

Nerve	Distal CMAP amplitude (mv)			Ratio Prox/Dist CMAP (%)			Distal latency (ms)			Motor NCV m/s			F wave ms		
	A	B	C	A	B	C	A	B	C	A	B	C	A	B	C
R Ulnar	2.4	2.3	2.8	56.4	20.7	68.2	3.7	4.2	3.8	37.4	32.1	43.2	42.9	54.8	37.4
L Median	2.5	2.5	2.4	60.5	4.0	45.8	4.2	4.0	4.1	41.5	40.0	45.0	40.2	absent	38.4

## References

- Diehl LF, Ketchum LH. Autoimmune disease and chronic lymphocytic leukemia: autoimmune hemolytic anemia, pure red cell aplasia, and autoimmune thrombocytopenia. *Semin Oncol* 1998;25(1):80-97.
- Hamblin TJ. Autoimmune complications of chronic lymphocytic leukemia. *Semin Oncol* 2006;33(2):230-9.
- Zaja F, Vianelli N. Anti-CD20 therapy for chronic lymphocytic leukemia-associated autoimmune diseases. *Leuk Lymphoma* 2003;44(11):1951-5.
- Nakano S, Ohnishi A, Oishi T, Murai Y, Nagata K. A case of adult T cell leukemia/lymphoma with motor and sensory polyneuropathy. *Rinsho Shinkeigaku* 1991;31(8):853-7.
- Umehara F, Hagiwara T. Enlarged, multifocal upper limb neuropathy with HTLV-I associated myelopathy in a patient with chronic adult T-cell leukemia. *J Neurol Sci* 2008;266:167-70.
- Perosa F, Favoino E, Caragnano MA, Prete M, Dammacco F. CD20: a target antigen for immunotherapy of autoimmune diseases. *Autoimmun Rev* 2005;4(8):526-31.
- Zaja F, Iacona I. B-cell depletion with rituximab as treatment for immune hemolytic anemia and chronic thrombocytopenia. *Haematologica* 2002 Mar;87(2):189-95.
- Pamuk GE, Turgut B. The successful treatment of refractory autoimmune hemolytic anemia with rituximab in a patient with chronic lymphocytic leukemia. *Am J Hematol* 2006;81:631-3.
- D'Arena G, Laurenti L. Rituximab therapy for chronic lymphocytic leukemia-associated autoimmune hemolytic anemia. *Am J Hematol* 2006;81:598-602.
- Dalakas MC. Invited article: inhibition of B cell functions: implications for neurology. *Neurology* 2008;70(23):2252-60.
- Pestronk A, Florence J. Treatment of IgM antibody associated polyneuropathies using rituximab. *J Neurol Neurosurg Psychiatry* 2003;74:485-9.
- Renaud S, Gregor M. Rituximab in the treatment of polyneuropathy associated with anti-MAG antibodies. *Muscle Nerve* 2003;27:611-5.
- Renaud S, Fuhr P, Gregor M, Schweikert K, Lorenz D, Daniels C, et al. High-dose rituximab and anti-MAG-associated polyneuropathy. *Neurology* 2006;66(5):742-4.
- Ruegg SJ, Fuhr P, Steck AJ. Rituximab stabilized multifocal motor neuropathy increasingly less responsive to IVIg. *Neurology* 2004;63:2178-9.
- Finsterer J. Treatment of immune-mediated, dysimmune neuropathies. *Acta Neurol Scand* 2005;112:115-25.

16. Nobile-Orazio E, Cappellari A, Priori A. Multifocal motor neuropathy: current concepts and controversies. *Muscle Nerve* 2005;31(6):663-80.
17. European Federation of Neurological Societies/Peripheral Nerve Society guideline on management of multifocal motor neuropathy. Report of a joint task force of the European Federation of Neurological Societies and the Peripheral Nerve Society--first revision. Joint Task Force of the EFNS and the PNS. *J Peripher Nerv Syst*. 2010 Dec;15(4):295-301.
18. Duchesne M, Mathis S, Corcia P, Richard L, Ghorab K, Jaccard A, et al. Value of nerve biopsy in patients with latent malignant hemopathy and peripheral neuropathy: a case series. *Medicine (Baltimore)*. 2015;94(3):e394.
19. Ghosh A, Virgincar A, Kennett R, Busby M, Donaghy M. The effect of treatment upon temporal dispersion in IVIg responsive multifocal motor neuropathy. *J Neurol Neurosurg Psychiatry* 2005;76:1269–1272.
20. Mitsui Y, Kusunoki S. Sensorimotor polyneuropathy associated with chronic lymphocytic leukemia, IgM antigangliosides antibody and human T-cell leukemia virus I infection. *Muscle Nerve* 1999;220:1461-5.
21. Nobile-Orazio E, Gallia F, Terenghi F, Allaria S, Giannotta C, Carpo M. How useful are anti-neural IgM antibodies in the diagnosis of chronic immune-mediated neuropathies? *J Neurol Sci* 2008;266(1-2):156-63.
22. Takada K, Shimizu J, Kusunoki S. Apoptosis of primary sensory neurons in GD1b-induced sensory ataxic neuropathy. *Exp Neurol* 2008;209:279-83.
23. Shihashi G, Yagi T, Suzuki S, Seki M, Kohashi S, Ueda T, et al. Immune-mediated Neuropathy with Anti-disialosyl IgM Antibodies in Diffuse Large B-cell Lymphoma: A Case Report and Literature Review. *Intern Med* 2015;54:1647-51.
24. Léger JM, Chassande B, Musset L, Meininger V, Bouche P, Baumann N. Intravenous immunoglobulin therapy in multifocal motor neuropathy: a double-blind, placebo-controlled study. *Brain* 2001;124(Pt 1):145-53.
25. Terenghi F, Cappellari A, Bersano A, Carpo M, Barbieri S, Nobile-Orazio E. How long is IVIg effective in multifocal motor neuropathy? *Neurology* 2004;62(4):666-8.
26. Umapathi T, Hughes RAC, Nobile-Orazio E, Léger JM. Immunosuppressant and immunomodulatory treatments for multifocal motor neuropathy (Review). *The Cochrane Library* 2015, Issue 3.
27. Karlsson C, Hansson L. Treatment of severe refractory autoimmune hemolytic anemia in B-cell chronic lymphocytic leukemia with alemtuzumab (humanized CD52 monoclonal antibody). *Leukemia* 2007;21:511-4.
28. Grillo-Lopez AJ, Hedrick E. Rituximab: ongoing and future clinical development. *Semin Oncol* 2002;29:105-12.
29. Stieglbauer K, Topakian R, Hinterberger G, Aichner FT. Beneficial effect of rituximab monotherapy in multifocal motor neuropathy. *Neuromuscular Disorders* 2009;19(7):473-475.
30. Chaudhry V, Cornblath DR. An open-label trial of rituximab (Rituxan®) in multifocal motor neuropathy. *J Peripher Nerv Syst*. 2010 Sep;15(3):196-201.
31. Gorson KC, Natarajan N. Rituximab treatment in patients with IVIg-dependent immune polyneuropathy: a prospective pilot trial. *Muscle Nerve* 2007;35:66-9.
32. De Vita S, Quartuccio L, Isola M, Mazzaro C, Scaini P, Lenzi M, et al. A randomized controlled trial of rituximab for the treatment of severe cryoglobulinemic vasculitis. *Arthritis Rheum*. 2012 Mar;64(3):843-53.
33. Hassan S, Popalzai M, Yu E, Wrzolec M, Odaimi M. A 61-year-old man presented with myopathy, neuropathy, and inflammatory dermatitis responsive to chronic lymphocytic leukemia treatment. *International Journal of General Medicine* 2012;5:647–653.

34. Kosmidis ML, Dalakas MC. Practical considerations on the use of rituximab in autoimmune neurological disorders. *Ther Adv Neurol Disord* 2010;3(2):93-105.
35. Cats EA, van der Pol W-L, Tio-Gillen AP, Diekstra FP, van den Berg LH, Jacobs BC. Clonality of anti-GM1 IgM antibodies in multifocal motor neuropathy and the Guillain-Barre syndrome. *J Neurol Neurosurg Psychiatry* 2014;86:502-504.
36. Madhavi J, Vinay C. Treatment of Multifocal Motor Neuropathy. *Curr Treat Options Neurol* 2014;16:269
37. Plosker GI, Figgitt DP. Rituximab. *Drugs* 2003;63:803-43.

**Manuscript Information:** Received: June 19, 2016; Accepted: September 17, 2016; Published: September 19, 2016

**Authors Information:** Laura Fionda<sup>1</sup>; Tiziana De Santis<sup>1</sup>; Elisabetta Bucci<sup>1</sup>; Stefania Morino<sup>1</sup>; Antonella Di Pasquale<sup>1</sup>; Francesca Mauro<sup>2</sup>; Giovanni Antonini<sup>1\*</sup>

<sup>1</sup>Department of Neurological Sciences, Mental Health and Sensory Organs (NESMOS), "Sapienza" University of Rome, Italy

<sup>2</sup>Department of Cellular Biotechnologies and Hematology, Division of Hematology, "Sapienza" University of Rome, Italy

**Citation:** Fionda L, De Santis T, Bucci E, Morino S, Di Pasquale A, Antonini, et al. Marked efficacy of Rituximab in multifocal motor neuropathy associated with chronic lymphocytic leukemia. *Open J Clin Med Case Rep.* 2016; 1163

**Copy right statement:** Content published in the journal follows Creative Commons Attribution License (<http://creativecommons.org/licenses/by/4.0>). © Antonini G 2016

**Journal:** Open Journal of Clinical and Medical Case Reports is an international, open access, peer reviewed Journal focusing exclusively on case reports covering all areas of clinical & medical sciences.

Visit the journal website at [www.jclinmedcasereports.com](http://www.jclinmedcasereports.com)

For reprints & other information, contact editorial office at [info@jclinmedcasereports.com](mailto:info@jclinmedcasereports.com)