

# A case of Barrett's oesophagus in pernicious anaemia: acid is not the only culprit!

Marilia Carabotti, Edith Lahner, Carola Severi and Bruno Annibale

## Case history

A 46-year-old female presented at our department with the onset of episodic dyspeptic symptoms, mainly postprandial fullness and bloating, as well as paresthesia. A blood test revealed the presence of mild macrocytic anaemia (haemoglobin 11.3 g/dl; mean corpuscular volume 119 fl), a reduced level of vitamin B12 (60 pmol/l; normal 200–750 pmol/l), hypergastrinaemia (1363 pg/ml; normal for female <100 pg/ml), a low level of pepsinogen I (<2.6 pg/ml; normal 30–100 pg/ml), and positivity for antibodies against parietal cells (>1:100). The upper endoscopy showed in oesophagus a single linear erosion (grade A according to Los Angeles Classification), with an absence of macroscopic gastric abnormalities. At histology, mucosal severe atrophy with moderate intestinal metaplasia was found in fundus and gastric corpus with spared antrum, in the absence of *Helicobacter pylori* infection. A diagnosis of autoimmune gastritis with pernicious anaemia was therefore made, and the patient started vitamin B12 intramuscular injections. Due to the absence of specific symptoms such as heartburn and/or regurgitation and to the presence of autoimmune gastritis, the erosive oesophagitis was not treated. After 4 weeks of treatment with vitamin B12, the haemoglobin, mean corpuscular volume and vitamin B12 values were restored, paresthesia improved, while dyspepsia remained stable, with sporadic symptoms about once a week.

The patient was affected from the age of 16 by Hashimoto's thyroiditis under treatment with levothyroxine (100 µg daily). Two or three times a month she took nonsteroidal anti-inflammatory drugs for headache. She presented a family history of autoimmune diseases, with her sister being affected by autoimmune thyroid disease and her brother by vitiligo, while no family history of gastrointestinal diseases was reported. The patient's body mass index was 24.4 kg/m<sup>2</sup> (55 kg; 150 cm). She was a nonsmoker. She did not undergo abdominal surgery.

The dyspeptic symptoms remained stable in intensity and frequency for about 2 years, after which the patient experienced a progressive worsening of dyspeptic symptoms, with daily early satiety and onset of augmented salivation, troublesome nausea with sporadic vomiting (mostly post-prandial), and thoracic pain. The results of a physical examination and abdominal ultrasound were unremarkable. To investigate this new pattern of symptoms a second endoscopy was performed, 3 years after the first. A short tongue of columnar lined mucosa (1 cm) was detected at distal oesophagus, and at histology a focal area of intestinal metaplasia without dysplasia was found, confirming the presence of Barrett's oesophagus. At histology, the severe mucosal atrophy with intestinal metaplasia in fundus and corpus was confirmed. Treatment with domperidone (10 mg three times a day) was undertaken with a partial reduction of symptoms, mainly the nausea, vomiting and dyspepsia, but it was interrupted after the onset of breast pain. Due to the persistence of troublesome dyspepsia, a further endoscopy was performed about 6 months later. During the endoscopy a spot sample of gastric juice was titrated, showing a pH of 7.5. The presence of metaplastic columnar epithelium at distal oesophagus (C0 M1, according to Prague Classification) with intestinal metaplasia, and fundus/corpus severe atrophy were reconfirmed, thus providing new strong evidence of the coexistence of pernicious anaemia and Barrett's oesophagus. A new abdominal ultrasound gave unremarkable findings.

To assess the presence of reflux or oesophageal dysmotility, a 24-hour pH-impedance measurement and a high-resolution oesophageal manometry was performed. The pH data showed an acid exposure time of 0% and no acid reflux episodes were identified. The DeMeester score was 0.8% (normal value <14.7%). The median value of registered intragastric pH was 6.56. Analysis of impedance signals showed 30 episodes of reflux, 20 of weakly acidic, 9 of gas weakly acidic and 1 of gas weakly alkaline.

*Ther Adv Gastroenterol*

2016, Vol. 9(3) 419–421

DOI: 10.1177/  
1756283X16637530

© The Author(s), 2016.  
Reprints and permissions:  
[http://www.sagepub.co.uk/  
journalsPermissions.nav](http://www.sagepub.co.uk/journalsPermissions.nav)

Correspondence to:  
**Marilia Carabotti, MD**  
Department of Internal  
Medicine and Medical  
Specialties, Sapienza  
University of Rome, Viale  
del Policlinico 155, Rome  
00161, Italy  
[mariliacarabotti@gmail.com](mailto:mariliacarabotti@gmail.com)

**Carola Severi, MD, PhD**  
Department of Internal  
Medicine and Medical  
Specialties, Sapienza  
University of Rome, Rome,  
Italy

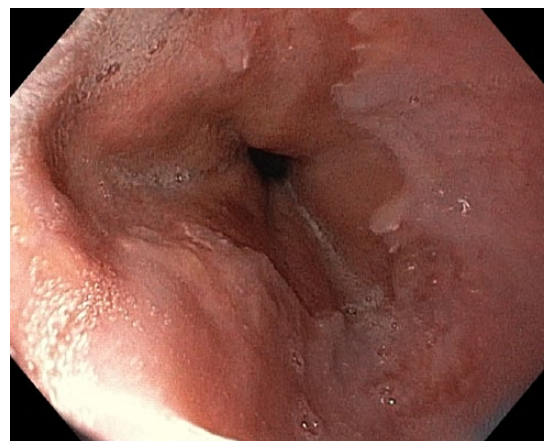
**Edith Lahner, MD, PhD**  
**Bruno Annibale, MD**  
Department of Medical  
and Surgical Sciences and  
Translational Medicine,  
Sant'Andrea Hospital,  
Sapienza University of  
Rome, Rome, Italy

Proximal extent of reflux was detected in 12 refluxes. A positive symptom index and symptom association probability for weakly acid reflux (50% and 100%, respectively) were found. A high-resolution manometry demonstrated a normotonic lower oesophageal sphincter (23.3 mmHg), in the absence of significant alterations of oesophageal motility.

Treatment with alginic acid was undertaken up to now, with benefits in terms of the augmented salivation, nausea and thoracic pain, but the dyspeptic symptoms persisted, mainly epigastric pain, which occurred about twice a week. A follow-up endoscopy (with narrow band imaging) was performed, 6 years after the diagnosis of autoimmune gastritis, and 3 years after that of Barrett's oesophagus. The short Barrett's oesophagus (C0 M1) with intestinal metaplasia and the atrophic gastritis was still confirmed (Figure 1).

### Discussion

This case report shows for the first time the unusual copresence of two conditions: autoimmune atrophic gastritis with pernicious anaemia, and Barrett's oesophagus, contrasting with the common belief that these two conditions are mutually exclusive. In this hypochlorhydric patient, we documented conditions associated with gastro-oesophageal reflux disease (GORD), from a mild erosive oesophagitis to the Barrett's oesophagus, during a follow up of 6 years. Both erosive oesophagitis and Barrett's oesophagus are considered acid-related conditions, and it has been reported that patients with Barrett's oesophagus have a greater degree of oesophageal acid exposure than patients with erosive oesophagitis, non-erosive reflux disease, or is the case with normal subjects [Loughney *et al.* 1998; Fass *et al.* 2001; Martinez *et al.* 2003]. In this case, impedance pH-metry revealed that acid exposure time and acid reflux episodes were absent, and an analysis of impedance signals showed the presence of weakly acidic refluxes, suggesting that this type of reflux is able to induce oesophageal mucosal inflammation, even Barrett's damage. Currently, the role of weakly acidic reflux alone in Barrett's oesophagus is not established. Farré and colleagues demonstrated that oesophageal perfusion with weakly acidic solutions provoked identical changes as those observed after perfusion with acid solutions, in terms of dilated intercellular spaces [Farré *et al.* 2010]. However, it should be kept in mind that weakly acidic reflux covers a



**Figure 1.** Endoscopic image of a tongue of columnar lined mucosa at distal oesophagus, the classical presentation of Barrett's oesophagus.

wide pH range, between 4 and 7, and the pathogenic role of the different pH values in GORD and its complications is not defined.

Accurate research concerning GORD and its complications associated with pernicious anaemia has been made, and a few related articles have been found. In a 1960 article, 22 patients with documented achlorhydria of different aetiology, from atrophic gastritis to gastrectomy, reported an endoscopic diagnosis of erosive oesophagitis [Palmer, 1960]. In 2006, a single case report described the combination of autoimmune gastritis with pernicious anaemia and gastro-oesophageal reflux symptoms, due to weakly acidic and weakly alkaline refluxes [Bredenoord *et al.* 2006]. However, this patient had undergone cholecystectomy a few years earlier, and this may have facilitated the entry of bile into the stomach. The role of the bile reflux in the development of heartburn was also described in another case of pernicious anaemia, and the authors described the resolution of symptoms through the use by the patient of cholestyramine [Orlando and Bozyski, 1973]. Although our patient did not undergo gallbladder surgery, she had one gas weakly alkaline reflux, but we believe that bile reflux played only a minor role in this case of Barrett's oesophagus.

Finally, a 2016 paper by Tenca and colleagues investigates, for the first time, the presence of GORD with pH-impedance monitoring in a notable cohort of patients affected by chronic autoimmune gastritis [Tenca *et al.* 2016]. The study notes that 24% of patients were found as GORD positive at pH-impedance monitoring,

confirming the occurrence of this phenomenon in autoimmune gastritis. Interestingly, no differences in pH-impedance parameters were observed between symptomatic and asymptomatic patients. Moreover, the long-term antisecretory treatment (both proton-pump inhibitors and H<sub>2</sub> antagonists) did not influence control of the symptoms, indicating the inappropriate prescription of these drugs in autoimmune gastritis with GORD symptoms. However, no information about endoscopic oesophageal findings was given.

In the literature, a strong negative association has been reported between severe gastric atrophy and both reflux oesophagitis (OR 0.17) and Barrett's oesophagus (OR 0.13) [Anderson *et al.* 2008]. This observation is consistent with the role of gastric acid secretion in the development of oesophagitis and Barrett's oesophagus, and consequently a reduction of acidic secretion had a protective role against these conditions. Our patient presents many supposed protective factors against Barrett's oesophagus, i.e. absence of acid reflux, normotonic lower oesophageal sphincter, normal oesophageal motility, female gender, normal weight, no smoking and no family history of Barrett's oesophagus. The eventual presence of delayed gastric emptying should be considered as a possible factor which might have contributed to the development of oesophageal reflux. In fact, it has been demonstrated that achlorhydria and an increased gastrin serum level are associated with a delayed gastric emptying of solid meals [Tosetti *et al.* 2000]. This clinical case presents an unsolved question about the treatment choices. These are very limited, since no medications are available for non-acid reflux. Prokinetics may represent an option, but the patient presented adverse effects; however, treatment with alginic acid has been undertaken with a partial resolution of symptoms. This case report suggests that Barrett's oesophagus may originate even in a hypochlorhydric patient, strengthening the hypothesis that acid is not the sole culprit of oesophageal damage.

### Acknowledgements

We thank Professor Vincenzo Savarino and Professor Patrizia Zentilin (University of Genova) and Professor Michele Cicala (University Campus, Bio-Medico Roma) for the performance of diagnostic tests and for their expertise.

### Funding

This work was supported by Bruno Annibale, MD, Sapienza University of Rome (grant numbers 000323\_2013 and 000323\_2014).

### Conflict of interest statement

The authors declare no conflicts of interest in preparing this letter.

### References

- Anderson, L., Murphy, S., Johnston, B., Watson, R., Ferguson, H., Bamford, K. *et al.* (2008) Relationship between *Helicobacter pylori* infection and gastric atrophy and the stages of the oesophageal inflammation, metaplasia, adenocarcinoma sequence: results from the FINBAR case-control study. *Gut* 57: 734–739.
- Brendenoord, A., Baron, A. and Smout, A. (2006) Symptomatic gastro-oesophageal reflux in a patient with achlorhydria. *Gut* 55: 1054–1055.
- Farré, R., Fornari, F., Blondeau, K., Vieth, M., De Vos, R., Bisschops, R. *et al.* (2010) Acid and weakly acidic solutions impair mucosal integrity of distal exposed and proximal non-exposed human oesophagus. *Gut* 59: 164–169.
- Fass, R., Hell, R., Garewal, H., Martinez, P., Pulliam, G., Wendel, C. *et al.* (2001) Correlation of oesophageal acid exposure with Barrett's oesophagus length. *Gut* 48: 310–313.
- Loughney, T., Maydonovitch, C. and Wong, R. (1998) Esophageal manometry and ambulatory 24-hour pH monitoring in patients with short and long segment Barrett's esophagus. *Am J Gastroenterol* 93: 916–919.
- Martinez, S., Malagon, I., Garewal, H., Cui, H. and Fass, R. (2003) Non-erosive reflux disease (NERD)-acid reflux and symptom patterns. *Aliment Pharmacol Ther* 17: 537–545.
- Orlando, R. and Bozyski, E. (1973) Heartburn in pernicious anemia – a consequence of bile reflux. *N Engl J Med* 289: 522–523.
- Palmer, E. (1960) Subacute eroive (“peptic”) esophagitis associated with achlorhydria. *N Engl J Med* 262: 927–929.
- Tenca, A., Massironi, S., Pugliese, D., Consonni, D., Mauro, A., Cavalcoli, F. *et al.* (2016). Gastro-oesophageal reflux and antisecretory drugs use among patients with chronic autoimmune atrophic gastritis: a study with pH-impedance monitoring. *Neurogastroenterol Motil* 28: 274–280.
- Tosetti, C., Stanghellini, V., Tucci, A., Poli, L., Salvioli, B., Biasco, G. *et al.* (2000) Gastric emptying and dyspeptic symptoms in patients with nonautoimmune fundic atrophic gastritis. *Dig Dis Sci* 45: 252–257.