

How does a cadaver model work for testing ultrasound diagnostic capability for rheumatic-like tendon damage?

Iustina Janta¹ · Julio Morán² · Esperanza Naredo¹ · Juan Carlos Nieto¹ ·
Jacqueline Uson³ · Ingrid Möller⁴ · David Bong⁴ · George A. W. Bruyn⁵ ·
Maria Antonietta D'Agostino⁶ · Emilio Filippucci⁷ · Hilde Berner Hammer⁸ ·
Annamaria Iagnocco⁹ · Lene Terslev¹⁰ · Jorge Murillo González¹¹ ·
José Ramón Mérida¹¹ · Luis Carreño¹

Received: 20 October 2015 / Accepted: 7 March 2016 / Published online: 19 March 2016
© Springer-Verlag Berlin Heidelberg 2016

Abstract To establish whether a cadaver model can serve as an effective surrogate for the detection of tendon damage characteristic of rheumatoid arthritis (RA). In addition, we evaluated intraobserver and interobserver agreement in the grading of RA-like tendon tears shown by US, as well as the concordance between the US findings and the surgically induced lesions in the cadaver model. RA-like tendon damage was surgically induced in the tibialis anterior tendon (TAT) and tibialis posterior tendon (TPT) of ten ankle/foot fresh-frozen cadaveric specimens. Of the 20 tendons examined, six were randomly assigned a surgically induced partial tear; six a complete tear; and eight left undamaged. Three rheumatologists, experts in musculoskeletal US, assessed from 1 to 5 the quality of US imaging of the cadaveric models on a Likert scale. Tendons were then categorized as having either no damage, (0); partial tear,

(1); or complete tear (2). All 20 tendons were blindly and independently evaluated twice, over two rounds, by each of the three observers. Overall, technical performance was satisfactory for all items in the two rounds (all values over 2.9 in a Likert scale 1–5). Intraobserver and interobserver agreement for US grading of tendon damage was good (mean κ values 0.62 and 0.71, respectively), with greater reliability found in the TAT than the TPT. Concordance between US findings and experimental tendon lesions was acceptable (70–100 %), again greater for the TAT than for the TPT. A cadaver model with surgically created tendon damage can be useful in evaluating US metric properties of RA tendon lesions

Keywords Tendon tear · Tendon damage · Ultrasound · Cadaver · Specimen

Electronic supplementary material The online version of this article (doi:10.1007/s00296-016-3460-0) contains supplementary material, which is available to authorized users.

✉ Iustina Janta
iustinajanta@yahoo.com

¹ Department of Rheumatology, Faculty of Medicine, Hospital General Universitario Gregorio Marañón, Universidad Complutense, Doctor Esquerdo 46, 28007 Madrid, Spain

² Department of Traumatology and Orthopaedic Surgery, Faculty of Medicine, Hospital General Universitario Gregorio Marañón, Universidad Complutense, Madrid, Spain

³ Department of Rheumatology, Hospital Universitario de Móstoles, Madrid, Spain

⁴ Department of Rheumatology, Instituto Poal, Barcelona, Spain

⁵ Department of Rheumatology, MC Groep, Lelystad, The Netherlands

⁶ Department of Rheumatology, Hôpital Ambroise Paré, APHP, Université Paris Ouest-Versailles-Saint Quentin en Yvelines, Boulogne-Billancourt, France

⁷ Department of Rheumatology, Clinica Reumatologica, Università Politecnica delle Marche, Jesi, Ancona, Italy

⁸ Department of Rheumatology, Diakonhjemmet Hospital, Oslo, Norway

⁹ Department of Rheumatology, Sapienza Università di Roma, Rome, Italy

¹⁰ Department of Rheumatology, Center for Rheumatology and Spine Diseases, Rigshospitalet - Glostrup, Copenhagen, Denmark

¹¹ Department of Human Anatomy and Embryology, Faculty of Medicine, Universidad Complutense, Madrid, Spain

Introduction

The tendons of the wrist/hand and ankle/foot are frequently involved in degenerative, traumatic and rheumatic diseases. In rheumatoid arthritis (RA) and other chronic inflammatory arthritis, synovial proliferation and angiogenesis in the tendon synovial sheaths, i.e. tenosynovitis, can produce structural tendon damage with consequent tendon ruptures at the sheath-covered areas, mainly in the wrists and ankles [1–4].

Over the last decades, musculoskeletal (MS) ultrasound (US) has been successfully validated for the diagnosis of tendon injuries at the wrist/hand and ankle/foot [5–13], with an accuracy comparable to that of magnetic resonance imaging (MRI) [6, 8, 10, 11]. Both imaging techniques are especially useful in the detection of partial tendon tears, which are much more challenging to diagnose by clinical assessment than complete tears [8]. US, however, is more available and patient friendly and cost effective than MRI.

US has played a key role in helping the physician understand the extent to which tendons are affected in RA. For example, US has shown a greater sensitivity than clinical examination in identifying inflammatory and structural tendon changes [14–17]. Several studies have focused on the reliability of US in detecting and grading tendon damage in RA, resulting in good interobserver agreement [18–20]. The only way imaging data can be corroborated definitively is by inspecting the tendon *in vivo*, which would be unethical. Therefore, if we could reproduce tendon damage in a cadaveric model, we hypothesize that US imaging should be able to show up similar results for tendon damage in both cadaveric and live specimens. If this hypothesis proves to be correct, this will enable us to conclude that the cadaveric model is an effective surrogate for the evaluation of US performance in the detection of RA lesions. The main objective of this study therefore was to establish whether US images reflect artificially induced RA-like tendon tears in cadaveric models in the same way as those in living patients. The secondary objective was to test the intra- and interobserver agreement in the grading of tendon lesions as well as to evaluate the concordance between the US findings and the artificially induced lesions in this cadaver model

Methods

This study was designed by members of the Working Group on Anatomy for the Image.

Specimens

Ten ankle and foot specimens (5 right specimens, 5 left specimens) from five fresh-frozen human cadavers (2 men, 3 women; age of death range 79–93 years) were used for

the study. Each specimen was sectioned and removed from the distal third of the calf and thawed for 24 h at room temperature. Institutional approval (Universidad Complutense de Madrid) was obtained for use of nonembalmed cadavers for research.

Tendons

We selected ten tibialis anterior tendons (TAT) and ten tibialis posterior tendons (TPT) for the study. Both are covered by synovial sheath at the ankle level where the TAT runs in a straighter line than the TPT which curves behind the medial malleolus.

Procedure for surgical creation of tendon lesions

Prior to the day of surgical intervention, we asked experts in US evaluation of tendon damage in RA patients (i.e. some of the authors of the definition and scoring system for tendon damage [20]) to send images of US-detected tendon damage in patients with RA seen in clinical practice. These images, together with the experience of the orthopaedic surgeon, helped him create the RA-like tendon lesions.

Prior to surgical intervention, an US expert (IJ) performed a MSUS evaluation of all tendons to check for existing lesions. No tendon was found to have structural damage. The sonographer played no further part in the detection and scoring of tendon damage. The 20 tendons were randomly assigned to undergo either: a surgically induced partial tear (6); a surgically induced complete tear (6); or to be left intact (8).

For the TAT, both partial and complete tears were induced proximally or distally to the superior extensor retinaculum. For the TPT, tears were induced proximally or distally to the flexor retinaculum.

All procedures were performed by the same orthopaedic surgeon (JM), expert in surgery of RA tendon lesions. To mask the artificially induced tendon involvement, all specimens underwent the same procedure, including those tendons which were to be left intact.

A longitudinal incision of 10 cm was made for each tendon at the same anatomical points. To avoid suture artefacts, special care was taken to ensure the incision did not overlap the tendon. In the TAT case, this was achieved through an antero-lateral incision made approximately 3 cm parallel to the tendon. For the TPT, the surgeon performed a retromalleolar incision approximately 3 cm to the rear of the tendon. With the incision made and the tendon located, part of proximal or distal retinaculum (i.e. superior extensor retinaculum and flexor retinaculum) was sectioned and removed. Tendon integrity was checked by pulling first one end and then the other, beneath the retinaculum (Online Resource 1). The tendon sheath was then sectioned

longitudinally, and the macroscopic integrity of the tendon was checked. Gel was inserted around the tendons on the assumption that air would enter between the tendon sheath and tendon upon sectioning which might impair US data.

To induce partial tendon tears, the bistoury was inserted lengthwise to the centre of the tendon and rotated from side to side. Then, the medial or the lateral part of the tendon was sectioned. For complete tendon tears, the tendon was sectioned in a transversal plane through its entire thickness. A small segment of the sectioned tendon was then cut and removed to prevent occlusion at the tips, which would not otherwise happen with a living model where contraction is present. Then, to produce typical RA lesion the tendons ends were fringed and frayed (Online Resource 2).

By this stage, the tendons took a more undulating form than might otherwise be expected in living models which may distort US findings. To redress this, corresponding muscles were manually strained.

US assessment

The day following the surgical procedures, US examination was carried out by a team of three rheumatologists, experts in MSUS (EN, JCN and JU), masked to the previous day's surgical intervention. US evaluation took place in one morning session with foot samples being randomly allocated a 10-min slot allowing each expert to evaluate US findings and assess tendon damage. The same process was repeated in an afternoon session, meaning that all observers had evaluated each tendon twice. An independent researcher, not involved in US evaluation (IJ), was responsible for the evaluation timetabling and random sample allocation.

US scanning was carried out with five real-time scanners (LOGIQ E9, GE Medical Systems Ultrasound and Primary Care Diagnostics, Wauwatosa, WI, USA) equipped with a multifrequency linear matrix array transducer (6–15 MHz). B-mode machine settings were optimized before the study and standardized for the duration. These settings were as follows: B-mode frequency 15 MHz, B-mode gain 51 dB and dynamic range 57 dB.

The US examination consisted in a systematic longitudinal and transverse scanning of the synovial sheath-covered area of the tendons following a standardized scanning protocol [21, 22]. To scan the TAT, the foot was positioned at rest over its plantar aspect and supported by a towel. The probe was placed transversely and longitudinally to the long axis of the leg and moved from the proximal to the distal and from the medial to the lateral aspect of the tendon. To scan the TPT, the foot was placed lying on the plantar aspect in slight eversion and supported by a towel. The probe was placed transversely and longitudinally to the long axis of the leg over the medial malleolus and then

moved carefully to the posterior aspect of the malleolus tibialis. The probe was moved from the proximal to the distal aspect of the medial malleolus following the tendon course. The probe was moved in line with the tendon fibres so as to avoid anisotropy. Dynamic manoeuvres such as slight dorsal and plantar flexion of the ankle were performed to optimize US imaging.

Researchers rated US quality performance on the cadaver models using a Likert scale as follows: (1) overall technical quality of the US image (1 = very bad; 5 = excellent); (2) presence of tendon anisotropy (1 = maximal; 5 = minimal); (3) presence of other artefact (different to anisotropy) outside or inside the tendons (1 = maximal; 5 = minimal); (4) visualization of the internal structure and limits of the tendons (1 = very bad; 5 = excellent); (5) visualization of tendon-related structures such as synovial sheath and retinaculum (1 = very bad; 5 = excellent); (6) confidence in judgment of the presence and type of lesion or in the absence of lesion (1 = very low; 5 = very high).

Tendon damage was defined on B-mode as an internal and/or peripheral tendon defect (i.e. the absence of fibres) in the region enclosed by tendon sheath, seen in two perpendicular planes [20]. A three-grade semi-quantitative scoring system for RA tendon damage was used to evaluate tendon damage. The scores were as follows: grade 0, normal; grade 1, partial tendon tear; and grade 2, complete tendon rupture [20]. This scoring system has been recommended by the Outcome Measures in Rheumatology (OMERACT) MSUS group. Each investigator was given a maximum of 10 min to scan each specimen and fill in a standardized report sheet with the investigation results.

Statistical analysis

Statistical analysis was performed with IBM SPSS Statistics 21.0 (IBM Corp. SPSS, Armonk, NY, USA). Quantitative variables were presented as the mean, SD and range and categorical variables as absolute frequencies and percentages. Intraobserver agreement for US grading of tendon damage was assessed by unweighted Cohen's κ . Interobserver agreement for US grading of tendon damage was assessed by Fleiss's κ . κ Values of 0–0.20 were considered poor, >0.20–0.40 fair, >0.40–0.60 moderate, >0.60–0.80 good and >0.80–1 excellent [23]. *P* values ≤ 0.05 were considered significant.

Results

A total of 20 tendons (10 TAT and 10 TPT) were evaluated twice by the three investigators. Samples of tendon damage are shown in Figs. 1 and 2.

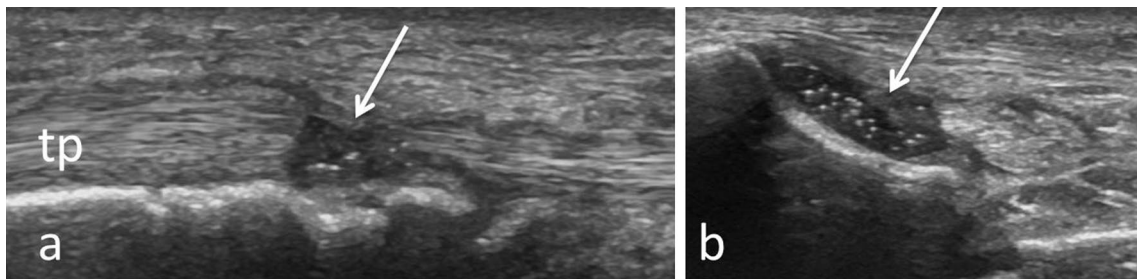


Fig. 1 Longitudinal (a) and transversal (b) view over the tibialis posterior tendon showing complete tear (arrows); tp tibialis posterior

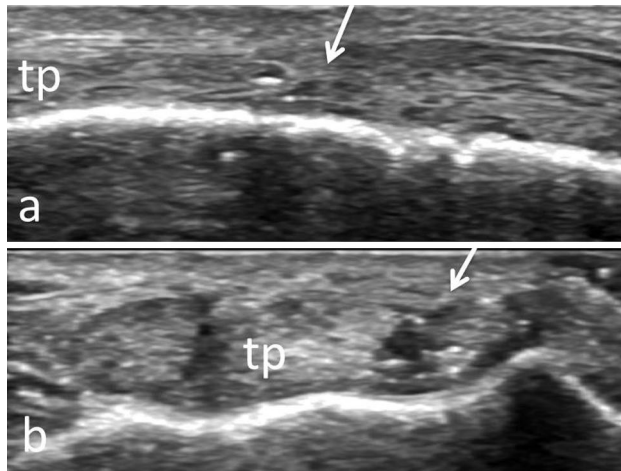


Fig. 2 Longitudinal (a) and transversal (b) view over the tibialis posterior tendon showing partial tear (arrows); tp tibialis posterior

US technical performance

Table 1 displays the results (mean values from the two rounds) from the US imaging quality parameters assessed by each investigator. Overall, quality performance was considered satisfactory for all US technical criteria of image findings assessed over the two sessions.

Table 1 Technical performance of US in the cadaver model

| Items | Investigator 1 Mean (SD, 95 % CI) | Investigator 2 Mean (SD, 95 % CI) | Investigator 3 Mean (SD, 95 % CI) | All investigators Mean (SD, 95 % CI) |
|-------------------------------------|--------------------------------------|--------------------------------------|--------------------------------------|---|
| Overall quality (1–5) | 4.4 (0.8, 4.0–4.7) | 3.4 (0.8, 3.0–3.8) | 4.1 (0.8, 3.7–4.5) | 4.0 (0.5, 3.7–4.2) |
| Tendon anisotropy (1–5) | 4.2 (0.9, 3.8–4.6) | 2.9 (0.9, 2.5–3.3) | 4.0 (1.0, 3.5–4.5) | 3.7 (0.6, 3.4–4.0) |
| Other artefacts (1–5) | 4.1 (0.9, 3.6–4.5) | 2.9 (0.9, 2.5–3.3) | 3.6 (1.1, 3.1–4.1) | 3.5 (0.7, 3.2–3.9) |
| Internal structure and limits (1–5) | 4.3 (0.7, 4.0–4.6) | 3.6 (0.9, 3.1–4.0) | 4.5 (0.7, 4.1–4.8) | 4.1 (0.5, 3.9–4.3) |
| Tendon-related structures (1–5) | 4.3 (0.6, 4.0–4.5) | 3.4 (0.6, 3.1–3.7) | 4.0 (0.8, 3.6–4.4) | 3.9 (0.4, 3.7–4.1) |
| Confidence in judgement (1–5) | 4.5 (0.8, 4.1–4.8) | 3.5 (1.1, 3.0–3.9) | 4.7 (0.8, 4.3–5.0) | 4.2 (0.6, 3.9–4.5) |

CI confidence interval

Intraobserver agreement for US grading of tendon damage

The κ values and CI for intraobserver agreement in grading tendon damage for each tendon and for both tendons are shown in Table 2. Agreement was excellent for the TPT and good for both tendons together. However, it was only moderate for the TPT.

Interobserver agreement for US grading of tendon damage

Table 3 displays the κ values and CI for interobserver agreement in grading tendon damage for each tendon and for both tendons in the two rounds. Again, the results were excellent for the TAT, good for both tendons and moderate for the TPT.

Concordance between US findings and surgically created lesions

Table 4 shows the concordance between the scored tendon damage and the tendon involvement in the surgically manipulated cadaver model. The concordance was acceptable, being better for the TAT than for the TPT.

Table 2 Intraobserver reliability

| Observers | TAT κ value (CI) (<i>p</i>) | TPT κ value (CI) (<i>p</i>) | TAT and TPT κ value (CI) (<i>p</i>) |
|----------------|---|---|---|
| Investigator 1 | 0.85 (0.56–1.00) (<0.001) | 0.54 (0.10–0.97) (0.015) | 0.69 (0.42–0.96) (<0.001) |
| Investigator 2 | 1.00 (0.56–1.00) (<0.001) | 0.55 (0.12–0.98) (0.012) | 0.77 (0.54–1.00) (<0.001) |
| Investigator 3 | 0.70 (0.33–1.00) (0.002) | 0.41 (–0.02–0.84) (0.051) | 0.55 (0.26–0.85) (<0.001) |
| Mean | 0.85 | 0.50 | 0.62 |

TAT tibialis anterior tendon, TPT tibialis posterior tendon, CI confidence interval

Table 3 Interobserver reliability

| | TAT κ value (CI) (<i>p</i>) | TPT κ value (CI) (<i>p</i>) | TAT and TPT κ value (CI) (<i>p</i>) |
|---------|---|---|---|
| Round 1 | 0.90 (0.64–1.00) (<0.001) | 0.45 (0.19–0.70) (<0.001) | 0.67 (0.49–0.85) (<0.001) |
| Round 2 | 0.80 (0.54–1.00) (<0.001) | 0.70 (0.44–0.95) (<0.001) | 0.75 (0.57–0.93) (<0.001) |
| Mean | 0.85 | 0.57 | 0.71 |

TAT tibialis anterior tendon, TPT tibialis posterior tendon, CI confidence interval

Table 4 Concordance between US findings and surgically created tendon lesions

| Concordance | TTA <i>n</i> (%) | TTP <i>n</i> (%) | TAT and TPT <i>n</i> (%) |
|------------------------------|---------------------|---------------------|-----------------------------|
| Investigator 1, first round | 9 (90) | 6 (60) | 15 (75) |
| Investigator 1, second round | 10 (100) | 9 (90) | 19 (95) |
| Investigator 2, first round | 10 (100) | 10 (100) | 20 (100) |
| Investigator 2, second round | 10 (100) | 7 (70) | 17 (85) |
| Investigator 3, first round | 10 (100) | 7 (70) | 17 (85) |
| Investigator 3, second round | 8 (80) | 7 (70) | 15 (75) |

TAT tibialis anterior tendon, TPT tibialis posterior tendon

Discussion

Over the last decade, the OMERACT MSUS group has assessed the metric properties of US in detecting and scoring potential endpoint in rheumatic diseases for clinical trials and practice [24–28]. The group has worked on validation of US-detected and graded tendon damage in RA [19, 20], which is an essential component of the structural damage in this disease [19, 20]. This comes in the wake of proven US capability in the diagnosis of superficial tendon lesions, as shown in a number of studies [5–13], most using surgical findings [6–8] or cadaver models [9, 11, 12] as criterion standard. In particular, concurrent validity of US in detecting hand tendon tears in RA was shown using surgical findings as criterion standard [8]. Both interobserver and intraobserver reliability of US for detecting and grading tendon damage have been demonstrated in patients with RA [18–20].

MSUS validation studies performed on cadaveric specimens, as opposed to living patients, offer several advantages. For example, in studies involving multiple assessors, data gathering is faster and more practical, as is the ability to evaluate a wide spectrum of lesions. However, both US technical performance and surgically induced lesions in cadaveric models are not necessarily equivalent to those in the living.

We tested the technical performance of US in a cadaver model with surgically created RA-like tendon damage. We used two different ankle/foot tendons, the TAT and the TPT, the latter being more curved. The three MSUS experts involved in the study reported tendon visualizations as well as other related structures to be satisfactory. Artefact impairment was also considered acceptable. In addition, researchers rated diagnostic confidence as high.

There are some procedural issues in cadaver model preparation that we would like to address. Firstly, the cadaver should be completely thawed when the US examination is performed to allow optimal visualization of anatomical structures; otherwise, a partially frozen specimen prevents proper US transmission. Secondly, air bubbles entering from the surgical incision and skin sutures produce shadowing artefacts that can prevent optimal visualization of tendons. Thus, a generous amount of gel should be inserted around the tendons and used during the examination to optimize US imaging. In addition, surgical incisions should not overlay the target tendons. Thirdly, experimental handling of tendons produces a ripple effect in structure resulting in anisotropy; this can be offset by manually straining the corresponding muscles.

To assess further the consistency of the cadaver model, we tested the agreement between the MSUS experts in grading tendon damage. We also tested the concordance between the tendon lesions detected by the investigators and the surgically created lesions. Our results on intraobserver and interobserver agreement were similar or slightly worse than those reported in living patients [18–20].

There are several important limitations to using cadaveric models that may explain these results. Firstly, there is a lack of muscle contraction and consequent torn tendon retraction which may hamper US detection of tendon tears. In addition, US scanning is more likely to detect tendon lesions in living specimens due to the dynamic of movement; a lack of secondary signs, such as hypoechoic fluid filling the tendon defect, or the thickening of the proximal end of the torn tendon. Nevertheless, to enhance US diagnostic capability, we cut and removed a small portion of the sectioned tendons during the surgical procedure and performed dynamic scanning as best we could during the US assessment.

The concordance between the US findings and the surgically created tendon lesions was acceptable and similar to those obtained in similar studies on cadaver models [9, 11]. Both, the intra- and interobserver agreement and the concordance between US and the experimental model were notably better for the TAT than for the TPT. This may be due to greater difficulty in handling the curved TPT tendon, resulting in anisotropic enhancement.

In conclusion, an experimental cadaver model can serve as an alternative reference method for testing US metric properties in RA-like tendon damage.

Acknowledgments Supported by a grant from Cátedra Extraordinaria UCM/MSD Prof. Luis Carreño, Faculty of Medicine, Universidad Complutense de Madrid, Madrid, Spain.

Author contributions Esperanza Naredo, Julio Morán, Ingrid Möller, David Bong, George AW Bruyn, Maria Antonietta D'Agostino, Emilio Filippucci, Hilde Berner Hammer, Annamaria Iagnocco, Lene Terslev, José Ramón Mérida, Luis Carreño were involved in study design. Iustina Janta, Julio Morán, Esperanza Naredo, Juan Carlos Nieto, Jacqueline Uson contributed to acquisition of data. Esperanza Naredo, Julio Morán, Ingrid Möller, David Bong, George AW Bruyn, Maria Antonietta D'Agostino, Emilio Filippucci, Hilde Berner Hammer, Annamaria Iagnocco, Lene Terslev, were involved in analysis and interpretation of data. Esperanza Naredo, Julio Morán, Iustina Janta, José Ramón Mérida, Luis Carreño were involved in manuscript preparation.

Compliance with Ethical Standards

Conflict of interest Emilio Filippucci has received speaker fees from Abbvie, Bristol-Myers Squibb, MSD, Pfizer, Roche and UCB. Juan Carlos Nieto-González has received speaker fees from Abbvie, Roche Farma, Pfizer, MSD. Iustina Janta, Julio Morán, Esperanza Naredo, Jacqueline Uson, Ingrid Möller, David Bong, George AW Bruyn, Maria Antonietta D'Agostino, Hilde Berner Hammer, Annamaria Iagnocco, Lene Terslev, Jorge Murillo González, José Ramón Mérida, Luis Carreño have not competing interest to declare.

Ethical approval This article does not contain any studies with human participants or animals performed by any of the authors.

Informed consent This study includes only cadaver models, so it is not necessary for an informed consent in Spain.

References

- Pap T, Distler O (2005) Linking angiogenesis to bone destruction in arthritis. *Arthritis Rheum* 52:1346–1348
- Boutry N, Larde A, Lapegue F, Solau-Gervais E, Flipo RM, Cotten A (2003) Magnetic resonance imaging appearance of the hands and feet in patients with early rheumatoid arthritis. *J Rheumatol* 30:671–679
- Eshedi E, Feist CE, Althoff Hamm B, Konen E, Burmester GR, Backhaus M, Hermann KG (2009) Tenosynovitis of the flexor tendons of the hand detected by MRI: an early indicator of rheumatoid arthritis. *Rheumatology* 48:887–891. doi:10.1093/rheumatology/kep136
- Jain A, Nanchahal J, Troeberg L, Green P, Brennan F (2001) Production of cytokines, vascular endothelial growth factor, matrix metalloproteinases and tissue inhibitor of metalloproteinases by tenosynovium demonstrates its potential for tendon destruction in rheumatoid arthritis. *Arthritis Rheum* 44:1754–1760
- Fornage BD, Rifkin MD (1988) Ultrasound examination of tendons. *Radiol Clin N Am* 26(1):87–107
- Rockett MS, Waitches G, Sudakoff G, Brage M (1998) Use of ultrasonography versus magnetic resonance imaging for tendon abnormalities around the ankle. *Foot Ankle Int* 19:604–612
- Waitches GM, Rockett M, Brage M, Sudakoff G (1998) Ultrasonographic-surgical correlation of ankle tendon tears. *J Ultrasound Med* 17:249–256
- Swen WA, Jacobs JW, Hubach PC, Klasens JH, Algra PR, Bijlsma JW (2000) Comparison of sonography and magnetic resonance imaging for the diagnosis of partial tears of finger extensor tendons in rheumatoid arthritis. *Rheumatology* 39:55–62
- Kovacs P, Behensky H, Lottersberger C, Bodner G, Brenner E, Moriggl B (2001) Can the dimensions of artificial tendon lesions be predicted ultrasonographically? A cadaveric study. *J Ultrasound Med* 20:459–464
- Premkumar A, Perry MB, Dwyer AJ, Gerber LH, Johnson D, Venzon D, Shawker TH (2002) Sonography and MR imaging of posterior tibial tendinopathy. *AJR Am J Roentgenol* 178:223–232
- Gerling MC, Pfirrmann CW, Farooki S, Kim C, Boyd GJ, Aronoff MD, Feng SA, Jacobson JA, Resnick D, Brage ME (2003) Posterior tibialis tendon tears: comparison of the diagnostic efficacy of magnetic resonance imaging and ultrasonography for the detection of surgically created longitudinal tears in cadavers. *Investig Radiol* 38:51–56
- Ravnic DJ, Galiano RD, Bodavula V, Friedman DW, Flores RL (2011) Diagnosis and localisation of flexor tendon injuries by surgeon-performed ultrasound: a cadaveric study. *J Plast Reconstr Aesthet Surg* 64:234–239. doi:10.1016/j.bjps.2010.04.035
- Martinoli C, Derchi LE, Pastorino C, Bertolotto M, Silvestri E (1993) Analysis of echotexture of tendons with US. *Radiology* 186:839–843
- Coakley FV, Samanta AK, Finlay DB (1994) Ultrasonography of the tibialis posterior tendon in rheumatoid arthritis. *Br J Rheumatol* 33:273–277
- Grassi W, Filippucci E, Farina A, Cervini C (2000) Sonographic imaging of tendons. *Arthritis Rheum* 43:969–976
- Filippucci E, Gabba A, Di Geso L, Girolimetti R, Salaffi F, Grassi W (2012) Hand tendon involvement in rheumatoid

- arthritis: an ultrasound study. *Semin Arthritis Rheum* 41:752–760. doi:[10.1016/j.semarthrit.2011.09.006](https://doi.org/10.1016/j.semarthrit.2011.09.006)
17. Alcalde M, D'Agostino MA, Bruyn GAW, Möller I, Iagnocco A, Wakefield RJ, Naredo E (2012) A systematic literature review of ultrasound definitions, scoring systems and validity according to the OMERACT filter for tendon lesion in rheumatoid arthritis and other inflammatory joint disease. *Rheumatology* 51:1246–1260. doi:[10.1093/rheumatology/kes018](https://doi.org/10.1093/rheumatology/kes018)
 18. Micu M, Serra S, Crespo M, Naredo E (2011) Interobserver reliability of ultrasound detection of tendon abnormalities at the wrist and ankle in patients with rheumatoid arthritis. *Rheumatology* 50:1120–1124. doi:[10.1093/rheumatology/keq441](https://doi.org/10.1093/rheumatology/keq441)
 19. Bruyn GA, Möller I, Garrido J, Bong D, D'Agostino MA, Iagnocco A, Karim Z, Terslev L, Swen N, Balint P, Baudoin P, van Reesema DS, Pineda C, Wakefield RJ, Naredo E (2012) Reliability testing of tendon disease using two different scanning methods in patients with rheumatoid arthritis. First step towards an ultrasonography scoring index. *Rheumatology* 51:1655–1661. doi:[10.1093/rheumatology/kes103](https://doi.org/10.1093/rheumatology/kes103)
 20. Bruyn GA, Hanova P, Iagnocco A, d'Agostino MA, Moller I, Terslev L, Backhaus M, Balint PV, Filippucci E, Baudoin P, van Vugt R, Pineda C, Wakefield R, Garrido J, Pecha O, Naredo E, OMERACT Ultrasound Task Force (2014) Ultrasound definition of tendon damage in patients with rheumatoid arthritis. Results of a OMERACT consensus-based ultrasound score focussing on the diagnostic reliability. *Ann Rheum Dis* 73:1929–1934. doi:[10.1136/annrheumdis-2013-203596](https://doi.org/10.1136/annrheumdis-2013-203596)
 21. Backhaus M, Burmester GR, Gerber T, Grassi W, Machold KP, Swen WA, Wakefield RJ, Manger B, Working Group for Musculoskeletal Ultrasound in the EULAR Standing Committee on International Clinical Studies including Therapeutic Trials (2001) Guidelines for musculoskeletal ultrasound in rheumatology. *Ann Rheum Dis* 60:641–649
 22. Naredo E, Rodriguez M, Campos C, Rodríguez-Heredia JM, Medina JA, Giner E, Martínez O, Toyos FJ, Ruíz T, Ros I, Pujol M, Miquel X, García L, Aznar JJ, Chamizo E, Páez M, Morales P, Rueda A, Tuneu R, Corominas H, de Agustín JJ, Moragues C, Mínguez D, Willisch A, González-Cruz I, Aragón A, Iglesias G, Armas C, Pablo Valdazo J, Vargas C, Calvo-Alén J, Juan-Mas A, Salvador G, Puigdollers A, Galíndez E, Garrido N, Salaberri J, Raya E, Salles M, Díaz C, Cuadra JL, Garrido J, Ultrasound Group of The Spanish Society of Rheumatology (2008) Validity, reproducibility, and responsiveness of a twelve-joint simplified power doppler ultrasonographic assessment of joint inflammation in rheumatoid arthritis. *Arthritis Rheum* 59:515–522. doi:[10.1002/art.23529](https://doi.org/10.1002/art.23529)
 23. Landis JR, Koch GG (1977) The measurement of observer agreement for categorical data. *Biometrics* 33:159–174
 24. Wakefield RJ, D'Agostino MA, Iagnocco A, Filippucci E, Backhaus M, Scheel AK, Joshua F, Naredo E, Schmidt WA, Grassi W, Moller I, Pineda C, Klauser A, Szkudlarek M, Terslev L, Balint P, Bruyn GA, Swen WA, Jousse-Joulin S, Kane D, Koski JM, O'Connor P, Milutinovic S, Conaghan PG (2007) The OMERACT Ultrasound Group: status of current activities and research directions. *J Rheumatol* 34:848–851
 25. D'Agostino MA, Conaghan PG, Naredo E, Aegerter P, Iagnocco A, Freeston JE, Filippucci E, Moller I, Pineda C, Joshua F, Backhaus M, Keen HI, Kaeley G, Ziswiler HR, Schmidt WA, Balint PV, Bruyn GA, Jousse-Joulin S, Kane D, Moller I, Szkudlarek M, Terslev L, Wakefield RJ (2009) The OMERACT Ultrasound Task Force—advances and priorities. *J Rheumatol* 36:1829–1832
 26. Naredo E, Wakefield RJ, Iagnocco A, Terslev L, Filippucci E, Gandjbakhch F, Aegerter P, Aydin S, Backhaus M, Balint PV, Bruyn GA, Collado P, Finzel S, Freeston JE, Gutierrez M, Joshua F, Jousse-Joulin S, Kane D, Keen HI, Moller I, Mandl P, Ohrndorf S, Pineda C, Schmidt WA, Szkudlarek M, Conaghan PG, D'Agostino MA (2011) The OMERACT ultrasound task force. Summary of advances and priorities. *J Rheumatol* 38:2063–2067. doi:[10.3899/jrheum.110425](https://doi.org/10.3899/jrheum.110425)
 27. Iagnocco A, Naredo E, Wakefield R, Bruyn GAW, Collado P, Jousse-Joulin S, Finzel S, Ohrndorf S, Delle Sedie A, Backhaus M, Berner-Hammer H, Gandjbakhch F, Kaeley G, Loeuille D, Moller I, Terslev L, Aegerter P, Aydin S, Balint PV, Filippucci E, Mandl P, Pineda C, Roth J, Magni-Manzoni S, Tzaribachev N, Schmidt WA, Conaghan PG, D'Agostino MA (2014) Responsiveness in rheumatoid arthritis. A report from the OMERACT 11 Ultrasound Workshop. *J Rheumatol* 41:379–382. doi:[10.3899/jrheum.131084](https://doi.org/10.3899/jrheum.131084)
 28. Bruyn GA, Naredo E, Iagnocco A, Balint PV, Backhaus M, Gandjbakhch F, Gutierrez M, Filer A, Finzel S, Ikeda K, Kaeley GS, Magni Manzoni S, Ohrndorf S, Pineda C, Richards B, Roth J, Schmidt WA, Terslev L, D'Agostino MA (2015) OMERACT Ultrasound Task Force. The OMERACT Ultrasound Working Group 10 Years On: Update at OMERACT 12. *J Rheumatol* 42(11):2172–2176