

Research article – Histology and cell biology

## Endocrine cells distribution in human proximal small intestine: an immunohistochemical and morphometrical study

 Rosa Vaccaro<sup>1</sup>, Carola Severi<sup>2</sup>, Giuditta Serrao<sup>3</sup>, Marilia Carabotti<sup>2</sup>, Arianna Casini<sup>1\*</sup>, Piero Chirletti<sup>3,4</sup>, Paolo Onori<sup>1,4</sup>

 Departments of: <sup>1</sup>Anatomical, Histological, Forensic Medicine and Orthopedics Sciences; <sup>2</sup>Internal Medicine and Medical Specialties; and <sup>3</sup>Surgical Sciences, Interdisciplinary Surgery Section; Sapienza University of Rome, Italy.

<sup>4</sup> P. Chirletti and P. Onori share the senior authorship

### Abstract

Atrophy of the pancreatic remnant after pancreaticoduodenectomy might be consequent to deregulation of pancreatic endocrine stimuli after duodenal removal. Relative technical surgical solution could be the anastomosis of the 1<sup>st</sup> jejunal loop to the stomach and the 2<sup>nd</sup> to the pancreatic stump. Data on the distribution of endocrine cells within the proximal intestine might represent the lacking tile of the problem. Our aims were to investigate the distribution pattern of serotonin, cholecystokinin and secretin cells in the duodenum, the 1<sup>st</sup> and 2<sup>nd</sup> jejunal loops of humans. Bowel specimens of ten patients submitted to pancreaticoduodenectomy were collected; immunohistochemical reactions and morphometric analyses were performed. A general ab-oral decrease of enteroendocrine cells was found. The rate of serotonin cells showed a significant  $30.67 \pm 8.13\%$  reduction starting from the 1<sup>st</sup> jejunal loop versus duodenum. The rate of both cholecystokinin and secretin cells in the duodenum was superimposable to that in the 1<sup>st</sup> jejunal loop, with a significant  $62.88 \pm 4.80\%$  loss of cholecystokinin and  $39.5 \pm 9.31\%$  of secretin cells in the 2<sup>nd</sup> loop. After removal of duodenum, preservation of the 1<sup>st</sup> jejunal loop could impact the function of pancreatic remnant maintaining the physiological enteroendocrine stimulus for pancreatic secretion that can compensate, at least in part for the abolished duodenal hormonal release.

### Key words

Cholecystokinin, enteroendocrine cells, human, secretin, serotonin, small intestine

### Introduction

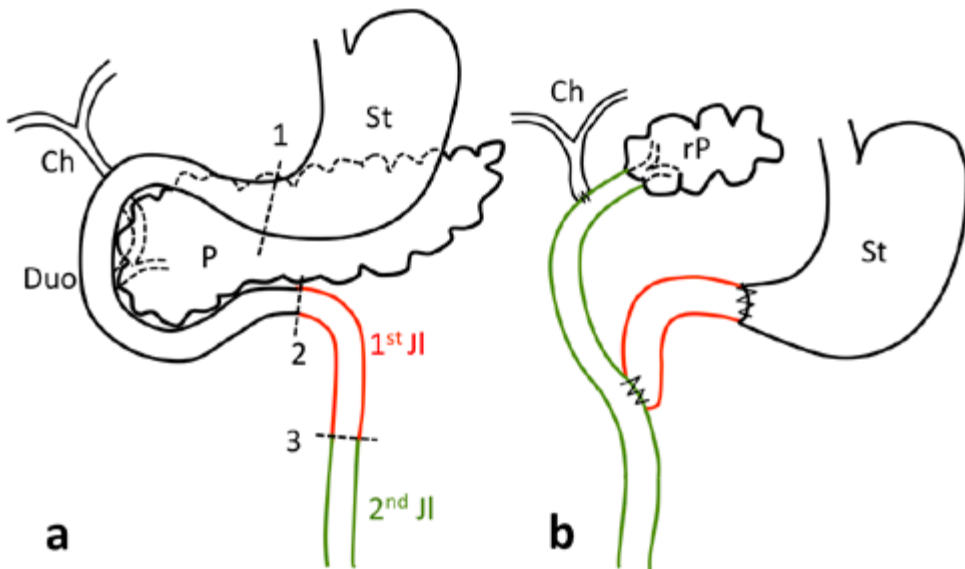
The digestive phase of human exocrine pancreatic secretion occurring after ingestion of a meal is regulated by a network of neurohumoral regulatory systems activated by the duodenal luminal content. Among hormones, the main peptides driving this phase are secretin and cholecystokinin (CCK). The stimulant of secretin is the gastric hydrogen ion entering in the duodenum (Hegyi and Petersen, 2013) while that of CCK is the intraluminal content of fatty acids and aminoacids (Raybould, 2002). Furthermore pancreatic exocrine secretion is stimulated by release of serotonin (5HT) from enterochromaffin (EC) cells through a vagal-mediated mechanism occurring through activation of enteric afferent neurons (Li et al., 2000; Zhu et al., 2001).

\* Corresponding author. E-mail: arianna.casini@uniroma1.it

A deregulation of pancreatic neurohormonal stimulatory factors for pancreatic head secretion resulting from gastric and duodenal removal occurs after pancreaticoduodenectomy (PD) (Bini, 2007). Post-surgical atrophy of the pancreatic remnant is a common evolution one year after PD (Kawamoto et al., 2006; Sikkens et al., 2012). The impact of reconstruction procedure should then be considered in the evaluation of morphologic and functional changes of the remnant pancreas after PD.

The best surgical technique for pancreatic anastomosis after PD is still debated. Gastric preservation might favor a normal acid secretion that acts as a physiologic stimulus to promote the secretion of CCK and secretin. When possible, as stated since the nineteen-eighties (Traverso and Longmire, 1978; Takada et al., 1989; Klinkenbijn et al., 1992) and then confirmed (Ito, 2005), it is recommended to preserve pylorus and duodenal bulb in pancreatic head resection to stimulate and maintain pancreatic exocrine function. The type of pancreatic anastomosis (gastric or enteric) might also influence the function of the pancreatic remnant (Inoue, 1987). Indeed, the preservation of the 1<sup>st</sup> jejunal loop in the reconstruction of the alimentary circuit (Fig. 1) might maintain the physiologic jejunal secretion of secretin and CCK subsequent to alimentary transit and compensate, at least in part, for the abolished duodenal hormonal release (Chirletti et al., 2010a).

Data on the distribution of endocrine cells within the intestinal wall might represent the lacking tile of the problem. Studies on the endocrine cells in the human small intestine date back to the nineteen-seventies (Polak et al., 1971; Buffa et al., 1976;



**Figure 1** – Schematic normal anatomy (a) and surgical reconstruction of the alimentary tract (b) after pancreaticoduodenectomy with anastomosis of the 1<sup>st</sup> jejunal loop to the stomach and of the 2<sup>nd</sup> loop to the pancreatic stump. Ch = choledochus; Duo = duodenal loop; JI = jejunal loop; P = pancreas; rP = residual pancreas; St = stomach. Lines 1, 2, 3 indicate the sites of sampling; 1 = duodenal bulb; 2 = 1<sup>st</sup> jejunal loop; 3 = 2<sup>nd</sup> jejunal loop.

Capella et al., 1978) but morphometric data on their distribution along the proximal small intestine are not available. The aim of our work has been then to investigate the immunohistochemical distribution pattern of 5HT, CCK and secretin cells in the duodenum and early 30 cm jejunum after Treitz in humans.

## Materials and Methods

The study was performed following the guidelines for experimental investigation with human subjects required by Sapienza University of Rome.

### Tissue

Specimens of intestinal wall were collected from duodenal bulb, 1<sup>st</sup> jejunal loop (at the level of duodenojejunal flexure) and 2<sup>nd</sup> jejunal loop (30 cm from the duodenojejunal flexure) (Fig. 1a). Histological samples were obtained from surgical specimens from ten patients (seven males, three females) 45 to 84 years old, submitted to PD for pancreatic head cancer. All patients gave informed consent.

Tissue specimens were fixed with cold 4% paraformaldehyde solution in 0.01 M saline phosphate buffer (PBS) for 24-48 hours at +4 °C, washed, dehydrated, paraffin embedded and cut into 5-7  $\mu$ m thick serial sections which were mounted on albumin-coated slides.

### Immunohistochemistry

In order to block endogenous peroxidase activity the sections were pretreated with PBS containing 0,1% sodium azide and 0,5% H<sub>2</sub>O<sub>2</sub> for 30 min at room temperature. To avoid unspecific antibody binding, sections were preincubated with normal goat serum (Vector Laboratories, Burlingame, CA) diluted 1: 30 in PBS containing 1% bovine serum albumin (BSA; Sigma, Saint Louis, MO). Sections were incubated in a moisted chamber for 48 h at +4 °C with polyclonal antisera to 5HT (Chemicon International, Temecula, CA), diluted 1: 30,000, CCK (Peninsula Laboratories International Inc., San Carlos, CA), diluted 1: 10,000, and secretin (Milab, Malmö, Sweden), diluted 1: 10,000. Sections were then incubated for 1 h at room temperature with biotinylated goat anti-rabbit immunoglobulin (Vector), diluted 1: 1,000 with PBS/BSA and then incubated for 1 h at room temperature with streptavidin-biotin-peroxidase complex (ABC, Elite Kit; Vector), diluted 1: 2,000 with 0.05 M Tris-HCl buffer, pH 7.6, containing 0.8% NaCl. Peroxidase activity was evidenced by reaction with a solution containing 0.04% 3-3' diaminobenzidine tetrahydrochloride (DAB; Fluka, Buchs, Switzerland), 0.4% nickel-ammonium sulfate, and 0.003% H<sub>2</sub>O<sub>2</sub> in 0.05 M Tris-HCl buffer, pH 7.6, for 3 min at room temperature. For specificity control the primary antiserum was substituted with PBS alone or with suitably diluted normal rabbit serum.

Immunohistochemical observations were made with a light microscope (Olympus, Tokyo, Japan). Five fields for each sample were digitalized on the screen (Videocam, Diagnostic Instrument, Sterling Heights, MI) and analyzed with an Image Analysis System (Delta Sistemi, Rome, Italy). The total number of epithelial cells of the mucosa

including villi and glands was counted in each field and the percentage of immunoreactive cells was calculated.

#### Data and statistical analysis

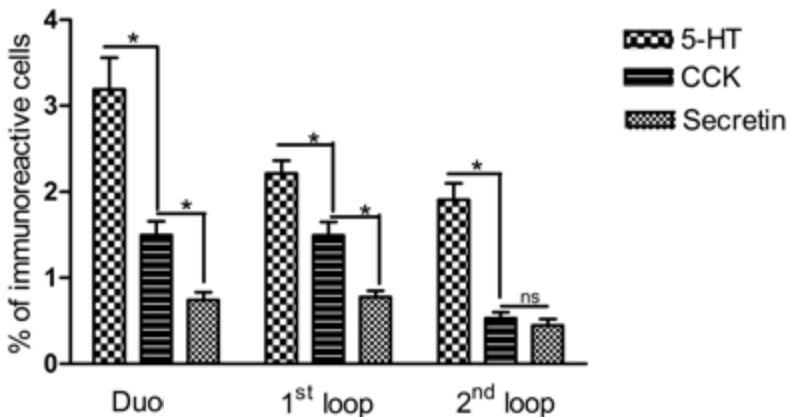
Results are expressed as mean  $\pm$  standard error (SE) of quintuple examinations of  $n$  specimens,  $n$  referring to the number of individual patients from whom the mucosal samples were obtained. Statistical analysis was performed by parametric ANOVA test.  $p$  values less than 0.05 were considered as significant.

### Results

Endocrine cells were found, in both crypts and villi, in all studied tracts. The numbers of cells immunoreactive for 5HT, CCK and secretin presented significant regional differences along human proximal intestinal tract, with major differences occurring between the 1<sup>st</sup> and 2<sup>nd</sup> jejunal loops (Tab. 1). Generally their number decreased along the proximo-distal axis, but the behavior of each endocrine population proceeded following its own specific features (Fig. 2).

#### Serotonin

The 5HT immunoreactive cell population was the most numerous among the populations studied (Fig. 2) and presented a progressive, statistically significant decrease in ab-oral direction. The percentage of 5HT immunoreactive cells showed a significant  $30.67 \pm 8.13$  reduction in the 1<sup>st</sup> jejunal loop versus duodenal bulb and a further non-significant small reduction in the 2<sup>nd</sup> versus the 1<sup>st</sup> jejunal loop (Tab. 1). The 5HT cells had the classical flask-like shape, with a clear connection to the lumen (Fig. 3 a-c).



**Figure 2** - Number of serotonin (5HT), cholecystokinin (CCK) and secretin cells per 100 epithelial lining cells in duodenal bulb (Duo) and 1<sup>st</sup> and 2<sup>nd</sup> jejunal loops. Asterisks mean  $p < 0.005$  for each indicated difference.

**Table 1** – Percentage of serotonin (5HT), cholecystokinin (CCK), and secretin immunoreactive cells lining the villi and glands in specimens from mucosa of duodenal bulb, 1<sup>st</sup> and 2<sup>nd</sup> jejunal loops.

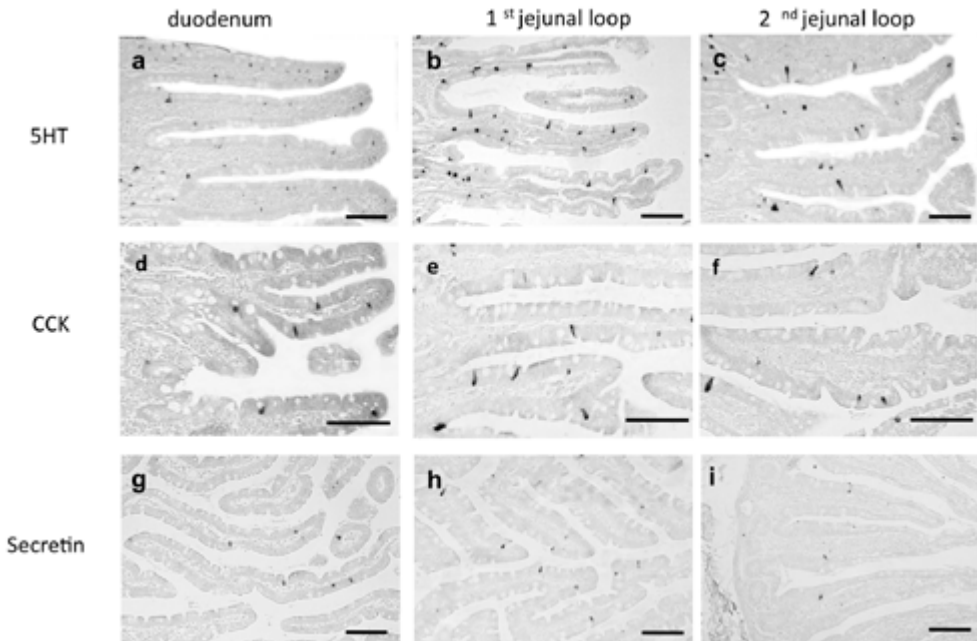
|          | Duodenal bulb<br>% positive cells ± SE | Jejunum (1 <sup>st</sup> loop)<br>% positive cells ± SE | Jejunum (2 <sup>nd</sup> loop)<br>% positive cells ± SE |
|----------|--|---|---|
| 5HT      | 3.337± 0.282                           | 2.144 ± 0.095*  | 1.942 ± 0.120*  |
| CCK      | 1.530 ± 0.108                          | 1.521 ± 0.098   | 0.535 ± 0.054*°   |
| SECRETIN | 0.745 ± 0.056                          | 0.785 ± 0.052   | 0.463 ± 0.046*°   |

\* p < 0.0001 jejunum against duodenum

° p < 0.0001 jejunum (2<sup>nd</sup> loop) against jejunum (1<sup>st</sup> loop)

**Cholecystokinin**

The CCK immunoreactive cells represented the second group, for number, among endocrine cells studied. The frequency of CCK immunoreactive cells in the duodenum was superimposable to that present in the 1<sup>st</sup> jejunal loop and then it decreased along proximo-distal axis, with a significant loss of 62.88 ± 4.80% in the 2<sup>nd</sup> loop (Tab. 1). The CCK immunoreactive cells showed an open type appearance, with an apical extension to the luminal surface (Fig. 3 d-f). The number rate of CCK immunoreactive



**Figure 3** – Immunohistochemical localization of endocrine cells in upper small intestine. Serotonin (a-c), cholecystokinin (d-f) and secretin (g-i) immunoreactive cells are shown in the duodenal bulb (a, d, g), 1<sup>st</sup> jejunal loop (b, e, h) and 2<sup>nd</sup> jejunal loop (c, f, i). (bar = 100 µm).

cells was higher than that of secretin positive cells both in duodenum and 1<sup>st</sup> jejunal loop while the two cell types were equally present in the 2<sup>nd</sup> jejunal loop (Fig. 2).

### Secretin

The secretin immunoreactive cells were the less represented, for number, among the endocrine cells studied (Fig. 2). Similarly to CCK cells, the frequency of secretin immunoreactive cells was similar in the duodenal bulb and in the 1<sup>st</sup> jejunal loop and showed a significant decrease, with a loss of  $39.05 \pm 9.31\%$  in the 2<sup>nd</sup> loop (Tab. 1). The secretin immunoreactive cells had a round shape and sometimes showed contact with the gut lumen. In the 2<sup>nd</sup> jejunal loop they were very few (Fig. 3 g-i).

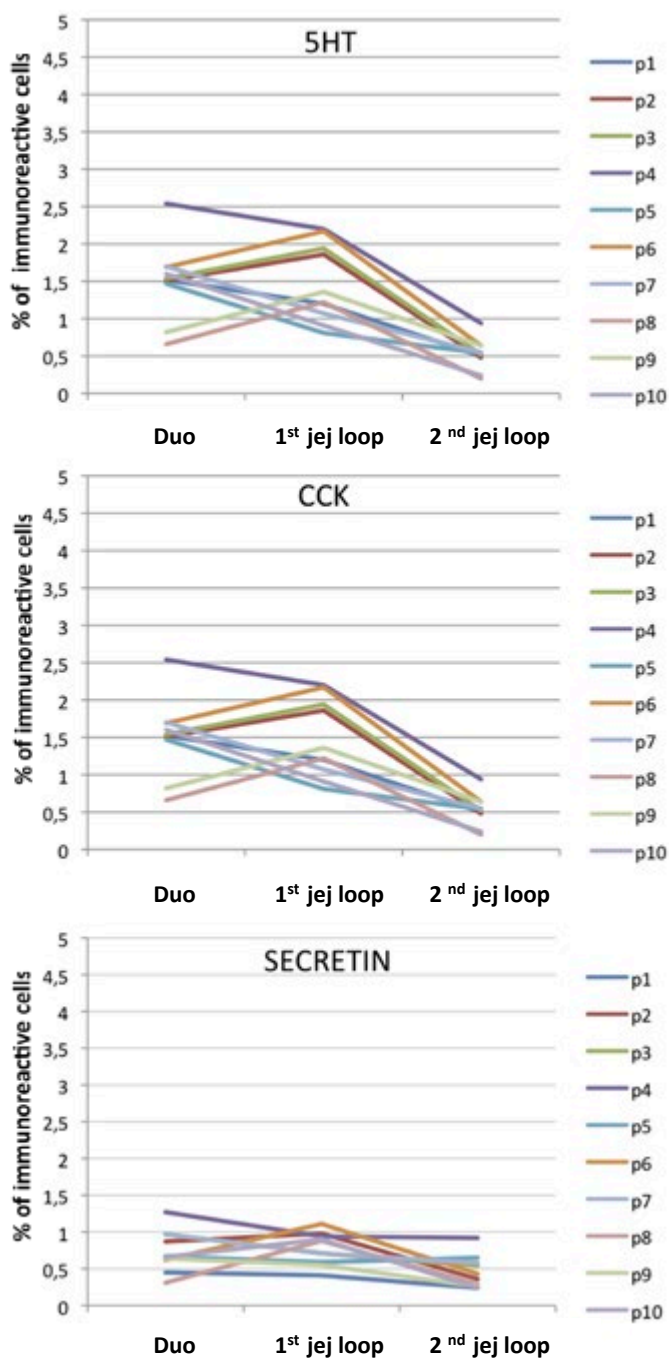
### Comparative analysis

By comparative analysis of the distribution of each type of labeled cells (Fig. 4), the progressive decrease of 5HT immunoreactive cells resulted even more evident and in almost all patients the frequency of 5HT cells was lower in the 2<sup>nd</sup> loop compared to duodenal bulb. The more drastic decrease was observed in the 1<sup>st</sup> jejunal loop where the analysis of the distribution of 5HT immunoreactive cells showed a frequency homogeneity higher than other tracts. In all tracts of each patient the values of 5HT cells were always higher than those of the other types of immunoreactive cells. In single analysis of CCK immunoreactive cells, a dual behavior was observed in the 1<sup>st</sup> loop, with either increase or decrease compared to duodenal bulb, while in the totality of patients there was a decrease in the 2<sup>nd</sup> loop where the frequency of CCK immunoreactive cells showed a higher homogeneity compared with other tracts. Finally, the numbers of secretin immunoreactive cells presented lower regional variations and showed a higher homogeneity in each tract studied. The differences between the duodenal bulb and the 1<sup>st</sup> loop were small ( $\leq 0,5\%$ ), either in decrease or increase, while a frequency decrease of secretin cells was regularly found in the 2<sup>nd</sup> loop. The frequency of CCK immunoreactive cells was always higher than that of secretin positive ones in the duodenal bulb and in the 1<sup>st</sup> loop of each patient, while sometimes it was similar to or lower than that of secretin positive cells in the 2<sup>nd</sup> loop.

In summary, no difference in CCK and secretin immunoreactive cells were found between duodenum and 1<sup>st</sup> jejunal loop whereas their content significantly decreases in the 2<sup>nd</sup> jejunal loop, both in respect to duodenal and 1<sup>st</sup> jejunal loop.

### Discussion

The present study shows that the distribution pattern of enteroendocrine cells in the duodenal-jejunal human tract presents regional differences. The highest overall number of studied endocrine cells was found in the duodenum and a progressive ab-oral decrease was observed along the digestive tract. However, CCK and secretin immunoreactive cells, involved in the regulation of pancreatic secretion, were equally numerous throughout the entire duodenal tract and the 1<sup>st</sup> jejunal loop, with a significant decrease, exceeding 60%, occurring in the 2<sup>nd</sup> loop. These results provide new morphological evidence that need to be taken into account in the pros and cons for each kind of anastomosis after PD (Morera-Ocon et al., 2014).



**Figure 4** – Frequencies of serotonin (5HT), cholecystokinin (CCK) and secretin cells in duodenal bulb (Duo) 1<sup>st</sup> and 2<sup>nd</sup> jejunal loops. Each line represents the values of a single patient (p1-p10).

Pancreatic exocrine insufficiency can follow major pancreatic resection. The extent of insufficiency following pancreatic resection relies on many factors concerning low luminal pH, pancreatic fibrosis and atrophy because of pancreatic duct occlusion, extent and type of surgical resection (Ghaneh and Neoptolemos, 1999). Atrophy of the remaining gland can also represent a consequence of the decrease in neurohumoral stimulatory factors likely related to the reconstruction of the digestive pathway (Pezzilli, 2011). With the resection of the largest part of the duodenum, the major digestive processes are disturbed and the controlled gastric-duodenal-pancreatic digestive chain is disrupted. Deficiency of gastrointestinal hormones may worsen the exocrine pancreatic insufficiency (Jang et al., 2003).

Our evidence on duodenal and proximal jejunal mucosa confirmed previous studies reporting 5HT cells in crypts and villi throughout human small intestine (Wang et al., 2007), CCK cells in crypts and villi of duodenal and jejunal loops (Buffa et al., 1976; Buchan et al., 1978) and secretin cells, also confined to the duodenal and jejunal mucosa, occurring preferentially in the villi (Polak et al., 1971; Capella et al., 1976). However, in the present study their gradient along the proximal gastrointestinal tract has been studied showing similarity in their content between the duodenum and 1<sup>st</sup> jejunal loop.

Almost all the endocrine cells studied showed the typical open shape compatible with their function as chemo sensitive cells and mucosal transducers in response to various luminal stimuli (Grider et al., 1996; Raybould, 2002; Deportere, 2014). The preservation of their early contact with the gastric chymus could then favor endocrine stimulation of the pancreatic remnant. Therefore, after removal of duodenum during PD, the preservation of the 1<sup>st</sup> jejunal loop in continuity with the stomach and the 2<sup>nd</sup> jejunal loop to the pancreatic stump (end-to-end pancreatic jejunostomy) appears more suitable to preserve a physiologic stimulus to promote the secretion of secretin and CCK (Chirletti et al., 2009; Caronna et al., 2012). Indeed, following this reconstruction with double jejunal loop after PD, it was shown that 80% of patients present a good residual pancreatic function, studied with secretin-stimulated dynamic magnetic resonance imaging and fecal elastase (Chirletti et al., 2010b). The importance of the 1<sup>st</sup> jejunal loop (Takada et al., 1989) as well as Billroth I type of anastomosis (Inoue et al., 1978) have already been suggested as relevant to maintain a physiologic postprandial pancreatic stimulus after PD.

The number of 5HT immunoreactive cells was always higher in comparison with other endocrine cells in all tracts studied. They were more numerous in the duodenal bulb, where their number was highly variable, and then they decreased starting from the 1<sup>st</sup> jejunal loop. A decrease of the number of 5HT cells along the ab-oral axis of the human small intestine was already reported (Wang et al., 2007).

In conclusion, the distribution pattern of enteroendocrine cells has to be taken into account in the choice of gastro intestinal reconstruction after PD in order to maintain pancreatic exocrine secretion and to reduce the incidence of pancreatic remnant atrophy.

## Acknowledgements

No conflict of interest has to be declared and the study has been performed following all the guidelines for experimental investigation with human subjects required by Sapienza University of Rome. The authors thank Mr. Simone Iannacone for his



technical support. The study was supported by a grant from Italian Ministry of Education, University and Research (PRIN 2009: B81J11002260001) to RV and CS and by a grant from Associazione Sapienza Pancreas Club onlus – Rome Italy (Pancreasclub-sapienza@uniroma1.it).

## References

- Bini L., Fantini L., Pezzilli R., Campana D., Tomassetti P., Casadei R., Calculli L., Corinaldesi R. (2007) Medical therapy of malabsorption in patients with head pancreatic resection. *JOP* 8: 151-155.
- Buchan A.M.J., Polak J.M., Solcia E., Capella C., Hudson D., Pearse A.G.E. (1978) Electron immunocytochemical evidence for the human intestinal I cells as the source of CCK. *Gut* 19: 403-407.
- Buffa R., Solcia E., Go V.L.M. (1976) Immunohistochemical identification of cholecystokinin cell in the intestinal mucosa. *Gastroenterology* 70: 528-532.
- Capella C., Solcia E., Frigerio B., Buffa R. (1976) Endocrine cells in the human intestine. An ultrastructural study. In: Fujita T. *Gut and Pancreas*: Elsevier, Amsterdam. Pp 42-59.
- Caronna R., Peparini N., Cosimo Russillo G., Rogano A.A., Dinatale G., Chirletti P. (2012). Pancreaticojejuno anastomosis after pancreaticoduodenectomy: brief pathophysiological considerations for a rational surgical choice. *Int. J. Surg. Oncol.* 2012: 636824.
- Chirletti P., Caronna R., Fanello G., Schiratti M., Stagnitti F., Peparini N., Benedetti M., Martino G. (2009) Pancreaticojejunostomy with application of fibrinogen/thrombin-coated collagen patch (TachoSil®) in Roux-en-Y reconstruction after pancreaticoduodenectomy. *J. Gastrointest. Surg.* 13: 1396-1398.
- Chirletti P., Peparini N., Caronna R., Fanello G., Delogu G., Meniconi R.L. (2010a) Roux-en-Y end-to-end and end-to-side double pancreaticojejunostomy: application of the reconstructive method of the Berger procedure to central pancreatectomy. *Arch. Surg.* 395: 89-93.
- Chirletti P., Peparini N., Caronna R., Papini F., Vietri F., Gualdi G. (2010b) Monitoring fibrosis of the pancreatic remnant after a pancreaticoduodenectomy with dynamic MRI: are the results independent of the adopted reconstructive technique? *J. Surg. Res.* 164: e49-e52.
- Deportere I. (2014) Taste receptors of the gut: emerging roles in health disease. *Gut* 63: 179-190.
- Ghaneh P., Neoptolemos J.P. (1999) Exocrine pancreatic function following pancreatectomy. *Ann. N.Y. Acad. Sci.* 880: 308-318.
- Grider J.R., Kuemmende J.F., Jin J.G. (1996). 5HT released by mucosal stimuli initiates peristalsis by activating 5HT4/5-HT1p receptors on sensory CGRP neurons. *Am. J. Physiol.* 270: G778-G782.
- Hegyi P., Petersen O.H. (2013) The exocrine pancreas: the acinar-ductal tango in physiology and pathophysiology. *Rev. Physiol. Biochem. Pharmacol.* 165: 1-30.
- Inoue K, Tobe T, Suzuki T. (1987) Plasma cholecystokinin and pancreatic polypeptide response after radical pancreatoduodenectomy with Billroth I and Billroth II type of reconstruction. *Ann. Surg.* 206: 148-154.

- Ito K. (2005) Duodenum preservation in pancreatic head resection to maintain pancreatic exocrine function (determined by pancreatic function diagnostic test and cholecystokinin secretion). *J. Hepatobiliary Pancreat. Surg.* 12: 123-128.
- Jang J.Y., Kim S.W., Han J.K., Park S.J., Park Y.C., Ahn Y.J., Park Y.-H. (2003) Randomized prospective trial of the effect of induced hypergastrinemia on the prevention of pancreatic atrophy after pancreatoduodenectomy in humans. *Ann. Surg.* 237: 522-529.
- Kawamoto M., Konomi H., Kobayashi K., Shimizu S., Yamaguchi K. (2006) Type of gastrointestinal reconstruction affects postoperative recovery after pancreatic head resection. *J. Hepatobiliary Pancreat. Surg.* 13: 336-343.
- Klinkenbijl J.H.G., van der Schelling G.P., Hop W.C.J., van Pel R., Bruining H.A., Jeekel J. (1992) The advantages of pylorus preserving pancreaticoduodenectomy in malignant disease of the pancreas and periampullary region. *Ann. Surg.* 216: 142-145.
- Li Y., Hao Y., Zhu J., Owyang C. (2000) Serotonin released from intestinal enterochromaffin cells mediates luminal non-cholecystokinin-stimulated pancreatic secretion in rats. *Gastroenterology* 118: 1197-1207.
- Morera-Ocon F.J., Sabater-Orti L., Muñoz-Forner E., Pérez-Griera J., Ortega-Serrano J. (2014) Considerations on pancreatic exocrine function after pancreaticoduodenectomy. *World J. Gastrointest. Oncol.* 6: 325-329.
- Pezzilli R. (2011) Pancreatic exocrine insufficiency following pancreatic resection. *Pancreatic Dis. Ther.* 1:1.
- Polak J.M., Coulling I., Bloom S., Pearse A.G. (1971) Immunofluorescent localization of secretin and enteroglucagon in human intestinal mucosa. *Scand. J. Gastroenterol.* 6: 739-744.
- Raybould H.E. (2002) Visceral perception: sensory transduction in visceral afferents and nutrients. *Gut* 51(suppl): 111-114.
- Sikkens E.C.M., Cahen D.L., van Eijck C., Kuipers E.J., Bruno M.J. (2012) The daily practice of pancreatic enzyme replacement therapy after pancreatic surgery: a northern European survey. *J. Gastrointest. Surg.* 16: 1487-1492.
- Takada T., Yashuda H., Shikata J-I., Watanabe S-I., Shiratori K., Takeuchi T. (1989) Postprandial plasma gastrin and secretin concentration after a pancreatoduodenectomy. *Ann. Surg.* 210: 47-51.
- Traverso L.W., Longmire J.P. (1978) preservation of the pylorus pancreaticoduodenectomy. *Surg. Gynecol. Obstet.* 146: 959-962.
- Wang S-H., Dong L., Luo J-Y., Gong J., Li L., Lu X-L., Han S-P. (2007) Decreased expression of serotonin in the jejunum and increased numbers of mast cells in the terminal ileum in patients with irritable bowel syndrome. *World J. Gastroenterol.* 13: 6041-6047.
- Zhu J. X., Wu X. Y., Owyang C., Li Y. (2001) Intestinal serotonin acts as paracrine substance to mediate vagal signal transmission evoked by luminal factors in the rat. *J. Physiol.* 530: 431-442.