

Successful Treatment of Cerebral Arterial Gas Embolism Following Uneventful TBNA

Monica Rocco¹, Antonio D'Andrilli², Alessandro Bozzao³, Luigi Maggi^{1*}, Erino Angelo Rendina² and Roberto Alberto De Blasi¹

¹Department of Surgical and Medical Science and Translational Medicine, Anesthesia and Intensive Care, Sapienza University of Rome, Italy

²Department of Surgical and Medical Science and Translational Medicine, Thoracic Surgery, Sapienza University of Rome, Italy

³Department of NESMOS (Neurosciences, Mental Health and Sensory Organs), Neuroradiology Unit, Sapienza University of Rome, Italy

Abstract

Fibrobronchoscopy is commonly considered a safe procedure with a low major complication rate not including cerebral arterial gas embolism (CAGE) a severe life threatening iatrogenic complication. Several cases of transbronchial needle aspiration (TBNA) has been related with CAGE when patient happens to have the high airway pressure that exceeds the pressure of the pulmonary veins allowing the air to enter the systemic circulation through the left heart. HBOT is the only effective treatment available for CAGE that provides 100% oxygen at high pressure, which accelerates nitrogen reabsorption and improves oxygenation of ischemic tissue.

We reported a case of successful treatment with full recovery after early Hyperbaric Oxygen therapy of CAGE induced by an uneventful transbronchial biopsy during fibrobronchoscopy.

Keywords: Bronchoscopy; Trans bronchial needle aspiration; Hyperbaric Oxygen Therapy; Cerebral Arterial gas embolism

Background

Fibrobronchoscopy is commonly considered a safe procedure with a low major complication rate of 0.74% [1] that does not include CAGE [2], a severe life threatening iatrogenic complication occasionally reported during invasive procedures, including fibrobronchoscopy [3-5].

HBOT is the only effective treatment [6] available for Cerebral arterial gas embolism (CAGE) that provides 100% oxygen at high pressure, which accelerates nitrogen reabsorption and improves oxygenation of ischemic tissue.

We reported a case of successful treatment with Hyperbaric oxygen therapy (HBOT) of CAGE induced by transbronchial biopsy during fibrobronchoscopy.

Case Report

A 75-year-old man with history of hemoptysis underwent computed tomography (CT) scanning and was found to have two lung opacities with irregular margins involving the hilar portion of the right upper and middle lobes. Associated hilar and subcarinal enlarged lymph nodes were also found.

An outpatient flexible bronchoscopy showed a normal right bronchial tree, except for a mild restriction of the anterior segment branch of the upper lobar bronchus due to external compression. A Trans bronchial needle aspiration (TBNA) was performed at the level of the subcarinal and hilar nodes at the site of the mild bronchial restriction. Endo-bronchial ultrasound (EBUS) was not used. Procedures were easy and rapid to perform, and no significant endobronchial bleeding was observed. At the end of the procedures, the patient was unconscious with a Glasgow Coma Score of 4, but all brainstem reflexes were maintained with no hemodynamic or respiratory alterations. The patient was rapidly intubated and admitted to the intensive care unit where an episode of epilepsy occurred. Brain CT scan showed frontalsided cerebral air embolism (Figure 1a). High doses of oxygen and a bolus of 5 mg of midazolam followed by continuous infusion of 0.05 mg/Kg/h of midazolam were prescribed and the patient was transferred to the hyperbaric center.

U.S. Navy [7] was initiated within 2 hours from bronchoscopy and

continued for 360 minutes. The day after HBOT, the patient recovered neurological signs (Glasgow Coma Score 15) and a brain CT scan showed a complete resolution of the cerebral air embolism (Figure 1b). On day 4, the patient was discharged from the intensive care unit. Cytological finding was: chronic inflammatory tissue with some "Actinomices" like colonies. Final diagnosis was a slowly resolving pneumonia.

Discussion

We reported a case of a severe CAGE following an uneventful fibrobronchoscopy and biopsies. Despite embolism not being included in fibrobronchoscopy guidelines as a major complication, CAGE associated with this procedure has been previously documented [5]. At the beginning of the twentieth century, Van Allen et al. [8] described two mechanisms for arterial gas embolism: arterIALIZATION of venous bubbles via a patent foramen ovale, and infusion into the pulmonary vein. There is an abundance of literature describing venous iatrogenic embolism resulting from many different procedures [9] that can produce cerebral symptoms in the presence of cardiac right to left shunts, or pulmonary arteriovenous malformation.

Other invasive procedures cause iatrogenic CAGE by introducing air directly into the left circulation [10]. Among these, transbronchial needle aspiration could cause a fistula between pulmonary veins and the airway [10] when the needle traverses both a pulmonary vein and an adjacent airway. If the airway pressure is elevated, as during cough in a semi-recumbent position, it exceeds the pulmonary venous pressure allowing the air to enter the pulmonary vein, reaching the systemic

***Corresponding author:** Luigi Maggi, Department of Surgical and Medical Science and Translational Medicine, Anesthesia and Intensive Care, Sapienza University of Rome, Italy, Tel: 00393895820203; Fax: 003933775400; E-mail: maggi.medicina@libero.it

Received October 27, 2015; **Accepted** December 14, 2015; **Published** December 18, 2015

Citation: Rocco M, Andrilli AD, Bozzao A, Maggi L, Rendina EA, et al. (2015) Successful Treatment of Cerebral Arterial Gas Embolism Following Uneventful TBNA. J Pulm Respir Med 5: 302. doi:[10.4172/2161-105X.1000302](https://doi.org/10.4172/2161-105X.1000302)

Copyright: © 2015 Rocco M, et al. This is an open-access article distributed under the terms of the Creative Commons Attribution License, which permits unrestricted use, distribution, and reproduction in any medium, provided the original author and source are credited.

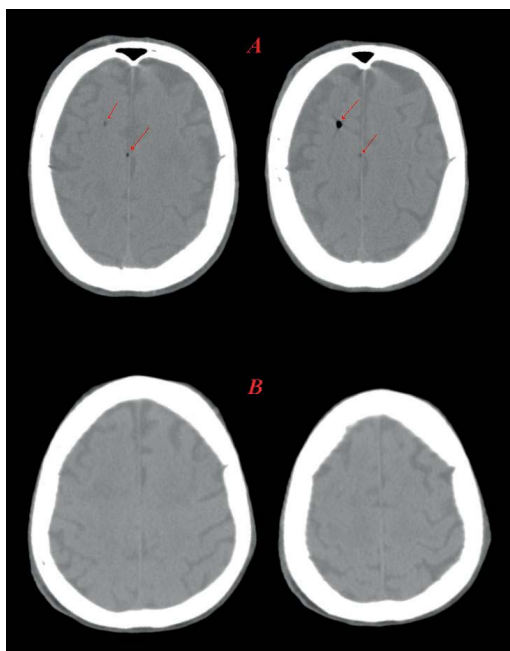


Figure 1: a) Right frontal subarachnoid air bubbles showed by computed tomography scans early after an uneventful fibrobronchoscopy. b) Complete resolution of the cerebral air embolism after hyperbaric therapy.

circulation through the left heart.

There seems to be no relationship between the gas volume and neurological symptoms. Usually, there are small bubbles that reach 30-60 μm of diameter in the cerebral arteries, leading to ischemia and endothelial injury [11]. This dynamic process determines a wide variability in the clinical presentation and difficult diagnosis [12] with a possible delay in the treatment. In the case of suspected CAGE, it is currently recommended to administer pure oxygen and, thereafter, to refer the patient to a hyperbaric facility as soon as possible [6].

The high oxygen tension promotes the reabsorption of nitrogen from the bubbles and the elevated ambient pressure reduces their size in accordance with Boyle's law. At a pressure of 282 kPa, the spherical gas bubble diameter is reduced to 82% with a resulting 45% decrease in volume with resolution of embolic phenomena.

Weenick et al. [13] failed to demonstrate a positive effect of HBOT administered 2 or 4 hours after CAGE in pigs, but their experimental strategy caused very severe CAGE irrespective to any HBOT effects

and they avoided administering oxygen prior to HBOT. In a prospective study however, Bessereau et al. [14] reported that a longer time interval between CAGE and the first HBOT did not affect mortality but aggravated neurological sequelae at 1-year follow-up.

In our case, we reported an early hyperbaric treatment of a severe CAGE induced by fibrobronchoscopy. Full neurological recovery confirms the opinion of Souday [11] that CAGE is a race against time. Surely guidelines should provide awareness of potential CAGE complications after fibrobronchoscopy for a rapid diagnosis.

References

1. Jin F, Mu D, Chu D, Fu E, Xie Y, et al. (2008) Severe complications of bronchoscopy. *Respiration* 76: 429-433.
2. Du Rand IA, Blaikley J, Booton R, Chaudhuri N, Gupta V, et al. (2013) British Thoracic Society guideline for diagnostic flexible bronchoscopy in adults. *Thorax* 68: 786-787.
3. Erickson AD, Irwin RS, Teplitz C, Corrao WM, Tarpey JT (1979) Cerebral air embolism complicating transbronchoscopic lung biopsy. *Ann Intern Med* 90: 937-938.
4. Evison M, Crosbie PA, Bright-Thomas R, Alaloul M, Booton R (2014) Cerebral air embolism following transbronchial lung biopsy during flexible bronchoscopy. *Respir Med Case Rep* 12: 39-40.
5. Azzola A, von Garnier C, Chhajed PN, Schirp U, Tamm M (2010) Fatal cerebral air embolism following uneventful flexible bronchoscopy. *Respiration* 80: 569-572.
6. Moon RE (2005) Bubbles in the brain: what to do for arterial gas embolism? *Crit Care Med* 33: 909-910.
7. Moon RE (1997) Treatment of decompression sickness and arterial gas embolism. In: Bove AA editor. *Bove and Davis diving medicine*. Philadelphia: WB Saunders: 184-204.
8. Van Allen CM, Hrdina LS, Clark J (1929) Air embolism from the pulmonary vein. *Arch Surg* 1929; 19: 567-599.
9. Tekle WG, Adkinson CD, Chaudhry SA, Jadhav V, Hassan AE, et al. (2013) Factors Associated with Favorable Response to Hyperbaric Oxygen Therapy among Patients Presenting with Iatrogenic Cerebral Arterial Gas Embolism. *Neurocrit Care* 18: 228-233.
10. Ashizawa K (2005) Possible airflow around needle in lung biopsy. *AJR Am J Roentgenol* 185: 553.
11. Souday V, Radermacher P, Asfar P (2013) Cerebral arterial gas embolism—a race against time! *Crit Care Med* 41: 1817-1819.
12. Dexter F, Hindman BJ (1997) Recommendations for hyperbaric oxygen therapy of cerebral air embolism based on a mathematical model of bubble absorption. *Anesth Analg* 84: 1203-1207.
13. Weenink RP, Hollmann MW, Vrijdag XC, Van Lienden KP, De Boo DW, et al. (2013) Hyperbaric oxygen does not improve cerebral function when started 2 or 4 hours after cerebral arterial gas embolism in swine. *Crit Care Med* 41: 1719-1727.
14. Bessereau J, Genotelle N, Chabbaut C, Huon A, Tabah A, et al. (2010) Long-term outcome of iatrogenic gas embolism. *Intensive Care Med* 36: 1180-1187.

Citation: Rocco M, Andrioli AD, Bozzao A, Maggi L, Rendina EA, et al. (2015) Successful Treatment of Cerebral Arterial Gas Embolism Following Uneventful TBNA. *J Pulm Respir Med* 5: 302. doi:10.4172/2161-105X.1000302