

## Neuronavigational Approach for Orbital Neurofibroma Excision: A Case Report

Marco Marenco<sup>1\*</sup>, Valentino Vellone<sup>2</sup>, Luca Scuderi<sup>1</sup>, Antonietta Moramarco<sup>1</sup>, Piero Cascone<sup>2</sup> and Alessandro Lambiase<sup>1</sup>

<sup>1</sup>Department of Sense Organs, University of Rome "Sapienza", Italy

<sup>2</sup>Department of Maxillo-facial surgery, University of Rome "Sapienza", Italy

\*Corresponding author: Marco Marenco, MD, PhD, Department of Sense Organs, University of Rome "Sapienza" Viale del Policlinico 15500161 Rome, Italy, Tel: +390649975413; E-mail: marco.marenco@uniroma1.it

Received date: Oct 08, 2015; Accepted date: Dec 15, 2015; Published date: Dec 17, 2015

Copyright: © 2015 Marenco M, et al. This is an open-access article distributed under the terms of the Creative Commons Attribution License, which permits unrestricted use, distribution, and reproduction in any medium, provided the original author and source are credited.

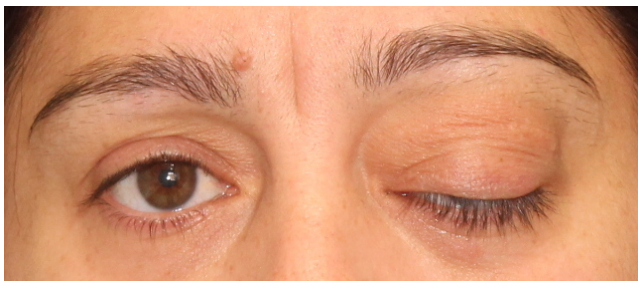### Abstract

Orbital neurofibromas are uncommon in adults, accounting for approximately 1%-3% of all space occupying lesions of the orbit. The complex anatomy of the orbital region, with the pronounced vulnerability of its neurovascular structures, requires particular surgical precautions. Neuronavigation, as a high-tech device for intraoperative safety, represents a valuable option for the confined orbital space. However, the application of neuronavigation in orbital surgery has been rarely reported. The authors present a case report of a 32-year-old female with an isolated localized neurofibroma surgically approached by intraoperative navigation and a review of the literature.

**Keywords:** Neuronavigation; Orbit; Neurofibromatosis proptosis

### Clinical Report

A 32-year-old female presented with a 2-year history of left upper lid swelling and progressive onset of proptosis and double vision (Figure 1). She had no family history of neurofibromatosis.



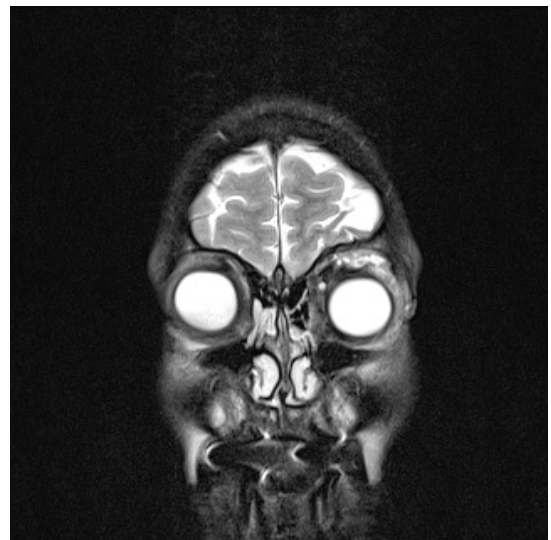
**Figure 1:** Picture shows the clinical finding of the patient showing left upper lid swelling and progressive onset of proptosis and double vision.

Ophthalmologist's examination revealed a decreased visual acuity 7/10 associated with ptosis, unilateral exophthalmos with restricted eyeball movement on upward and lateral gaze in the left eye. The visual field examination was normal.

Magnetic resonance imaging (MRI) of the orbits showed multiple soft tissue density masses in the left orbit measuring from few up to 15 mm, and showing post-contrastographic enhancement (Figure 2). Specifically, the larger lesion of 15 mm was localized in the superomedial part, between the orbital roof and the superior rectus muscle.

The patient was admitted in our Department of Maxillofacial surgery for a biopsy in general anesthesia.

The histological examination described a sparsely cellular neoplasm composed of spindled cells scattered throughout a loose to coarsely collagenous stroma was identified. Wagner–Meissner bodies were present in regions of denser stroma. Neoplastic cells and Wagner–Meissner bodies were S100 positive. Epithelial membrane antigen was negative, ruling out other lesions associated with whorled structures such as perineurioma and meningioma. Neurofilament protein was used to high-light the scattered axons within the neurofibroma.

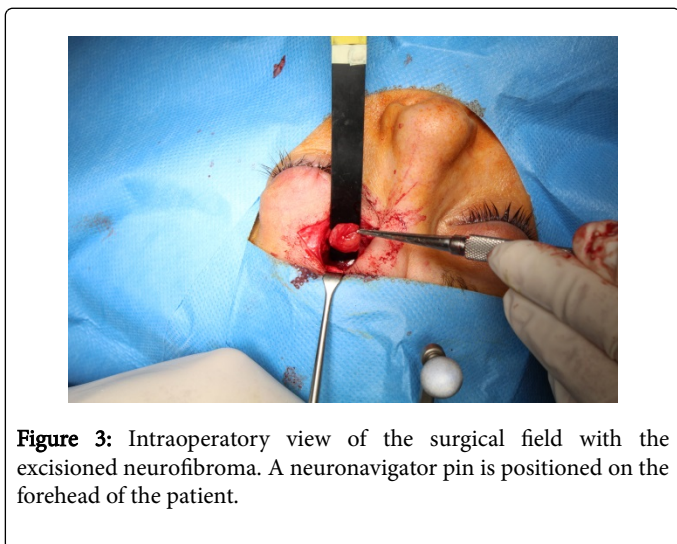


**Figure 2:** Magnetic resonance imaging (MRI) showed a lesion of 15 mm localized in the superomedial part, between the orbital roof and the superior rectus muscle, associated with multiple soft tissue density masses.

The patient was re-scheduled for excisional biopsies under general anesthesia.

A multidisciplinary approach including a neurosurgeon, an ophthalmologist, a maxillofacial surgeon, radiologists and anaesthesiologists was necessary to achieve the correct management of the lesion.

A navigation system was used to facilitate locating and removing the neoplasms to overcome intraoperative difficulties owing to the small size and its anatomic location (Figure 3).



**Figure 3:** Intraoperative view of the surgical field with the excised neurofibroma. A neuronavigator pin is positioned on the forehead of the patient.

For preoperative and navigation planning, MRI scans were obtained after 5 reference markers had been attached to the patient's skin. These markers were spread in a different axial plane, to limit the scanning area.

Data were recorded in Digital Imaging and Communications in Medicine (DICOM) format and transferred through the hospital network to a BrainLAB VectorVision workstation (BrainLAB, Westchester, IL), where the neof ormation was targeted and marked. Preoperative planning was performed using iPlan Cranial 2.5 software (BrainLAB).

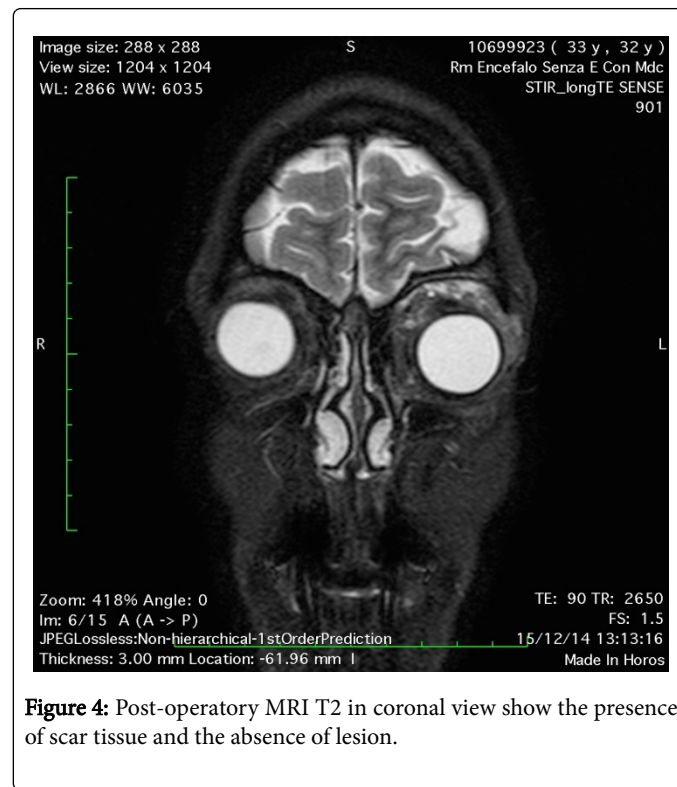
In the next step, the images and treatment plan were imported to the workstation of the navigation system unit in the operating room. The navigation system has an optical platform to localize the patient in space and a flat-panel monitor to show image data; the surgeon interacts with the system using a touch screen.

Before navigation, patient-to-MRI data registration was performed with the aid of a surface laser scanner and pinpointing of the reference markers fixed to the skin. The reference markers were the same markers that had been left attached to the skin in the same position after the MRI scan. The accuracy of registration was checked visually by repeatedly pinpointing anatomic landmarks, such as the nasal spine, medial canthus. The error of the system, measured using the computer, did not exceed 1 mm.

An upper eyelid skin crease [1] and more extensive incision were performed on the scar of the previous biopsy and white neoplasms were removed by blunt dissection.

During removal of the superomedial mass it appeared grossly cystic but was found to have a gelatinous center. It was partially encapsulated and easily separated from most surrounding tissues.

MRI performed after 1 year (Figure 4), showed a complete disappearance of the orbital mass. The patient showed left palpebral ptosis and was re-scheduled for surgical correction [2,3].



**Figure 4:** Post-operative MRI T2 in coronal view show the presence of scar tissue and the absence of lesion.

## Discussion

The exact incidence of true solitary or isolated neurofibromas of the orbit is difficult to evaluate because of its relation to neurofibromatosis; however, it is relatively uncommon [4].

It most frequently occurs in young to middle-aged adults. The majority of patients reported in the literature shared several clinical findings including palpable mass, proptosis, normal sensory function and mildly decreased visual function [5-8]. However, Shields et al. reported a patient with 3 separate right orbital lesions who showed no clinical manifestations of neurofibromatosis [8].

Orbital neurofibroms are typically located in the superior part of the orbit and arises from sensory branches of the frontal nerve.

Garrity and Henderson described 9 cases of orbital neurofibromas, arising usually from the supraorbital frontal branch of the trigeminal nerve [9]. Rose and Wright reported a 93% incidence of benign neurilemmoma or neurofibroma among orbital peripheral nerve sheath tumors [10]. They found a positive family history of systemic neurofibromatosis in one-quarter of patients with solitary neurofibroma. Krohel et al. also reported 8 cases with histopathological features identical to those of our case [11].

Excision of localized neurofibroma mostly leads to a complete recovery of patients with return to normal globe position, visual acuity, and sensation after surgery. However, there is a risk of 72% for postoperative nerve anesthesia, likely attributable to damage to the involved sensory nerves during removal [4].

Imaging may show rim enhancement with contrast computed tomography and increased signal intensity on MRI in areas of degeneration or loose stroma and can be used to favor a diagnosis of neurofibroma. However, surgical resection may be the only way to reach a definitive diagnosis for some orbital masses [12].

The CT scan show a typical smooth contour with orbital wall expansion and possible extension through the superior orbital fissure in 41% of the cases [13] which can limit the surgical resection.

Neuronavigation is a high-tech device with a proven value in contemporary neurosurgery. Intraoperatively, neuronavigation provides with meticulous coregistration between the processed virtual image space and the real anatomical space. In this way the frameless stereotaxy allows precise localization, safe dissection guidance and exact orientation for the extent of tumour resection. Nowadays, neuronavigation, although widely used in cranial surgery, is also rarely reported in orbital surgery. Neuronavigation in cranial neurosurgery was introduced in 1986, while the first application in the field of orbital surgery was in 2001 and, up to now, only 9 ophthalmic patients has reported in literature [14].

Enchev et al. [15] reported 7 patients who underwent surgery for orbital tumor using a navigation system and they emphasized that this system does not replace anatomical knowledge but has a complementary role during surgery.

In our opinion, CT-based navigation is useful for bone tumors such as osteoma and fibrous dysplasia while MRI-based navigation is important for soft tumors such as gliomas, lymphomas or metastasis. CT-angiography based navigation may be used in vascular lesions. Regarding orbital tumors, MRI-based navigation is useful especially for soft tumors.

The appropriate navigation system and imaging method should be selected preoperatively by the surgeon. Currently, the set-up and use of a navigation system are very fast and comfortable for the patient and surgeon. However, this system becomes unreliable after opening of the periorbita due to protrusion of the orbital fat and muscles. Intraoperative imaging systems therefore help the surgeon after the periorbital opening.

In conclusion, we think that this technique has the advantages to provide better safety and effectiveness compared to standard endoscopic or microscopic approaches for orbital tumors, but some disadvantages such as higher cost and potential increase of the surgical procedure' time [15].

## References

1. Li J, Lin M, Shao C, Ge S, Fan X (2014) Blepharoplasty techniques in the management of orbito-temporal neurofibromatosis. *J Plast Reconstr Aesthet Surg* 67: 1496-1501.
2. Scuderi N, Chiummariello S, Gado, FD, Scuderi G, Recupero, SM (2008) Surgical correction of blepharoptosis using the levator aponeurosis-Müller's muscle complex readaptation technique: A 15-year experience. *Plast Reconstr Surg* 121: 71-78.
3. Gabrieli CB, Recupero SM, Contestabile MT, Pacella E, Abdolrahimzadeh S (1996) Fox's modified technique using the Mersilene mesh sling in the management of blepharoptosis. *Ophthalmic Surg Lasers* 27: 924-928.
4. Alkatan HM (2007) Solitary neurofibroma in the absence of neurofibromatosis. *Can J Ophthalmol* 42: 628-629.
5. Evans JJ, Wilkinson MJ, Specht CS (2012) Solitary orbital neurofibroma presenting as a cystic mass. *Can J Ophthalmol* 47: e39-41.
6. Lee LR, Gigantelli JW, Kincaid MC (2000) Localized neurofibroma of the orbit: a radiographic and histopathologic study. *Ophthal Plast Reconstr Surg* 16: 241-246.
7. Alkatan HM (2007) Solitary neurofibroma in the absence of neurofibromatosis. *Can J Ophthalmol* 42: 628-629.
8. Shields JA, Shields CL, Lieb WE, Eagle RC (1990) Multiple orbital neurofibromas unassociated with von Recklinghausen's disease. *Arch Ophthalmol* 108: 80-83.
9. Oystreck DT, Morales J, Chaudhry I, Alorainy IA, Elkhamary SM, et al. (2012) Visual loss in orbitofacial neurofibromatosis type 1. *Ophthalmology* 119: 2168-2173.
10. Garrity JA, Henderson JW (2007) Tumors of peripheral nerve sheath origin: Henderson's Orbital Tumors (4th edn) Lippincott Williams and Wilkins, Philadelphia, USA.
11. Rose GE, Wright JE (1991) Isolated peripheral nerve sheath tumours of the orbit. *Eye (Lond)* 5: 668-673.
12. Krohel GB, Rosenberg PN, Wright JE, Smith RS (1985) Localized orbital neurofibromas. *Am J Ophthalmol* 100: 458-464.
13. Khan SN, Sepahdari AR (2012) Orbital masses: CT and MRI of common vascular lesions, benign tumors, and malignancies. *Saudi J Ophthalmol* 26: 373-383.
14. Enchev Y, Tzekov C, Ferdinandov D, Cekov A, Spiriev T (2011) Neuronavigation in craniorbital neurosurgery - do we really need it? *Turk Neurosurg* 21: 119-126.
15. Hodaj I, Kutlay M, Gonul E, Solmaz I, Tehli O, et al. (2014) The use of neuronavigation and intraoperative imaging systems in the surgical treatment of orbital tumors. *Turk Neurosurg* 24: 549-557.