

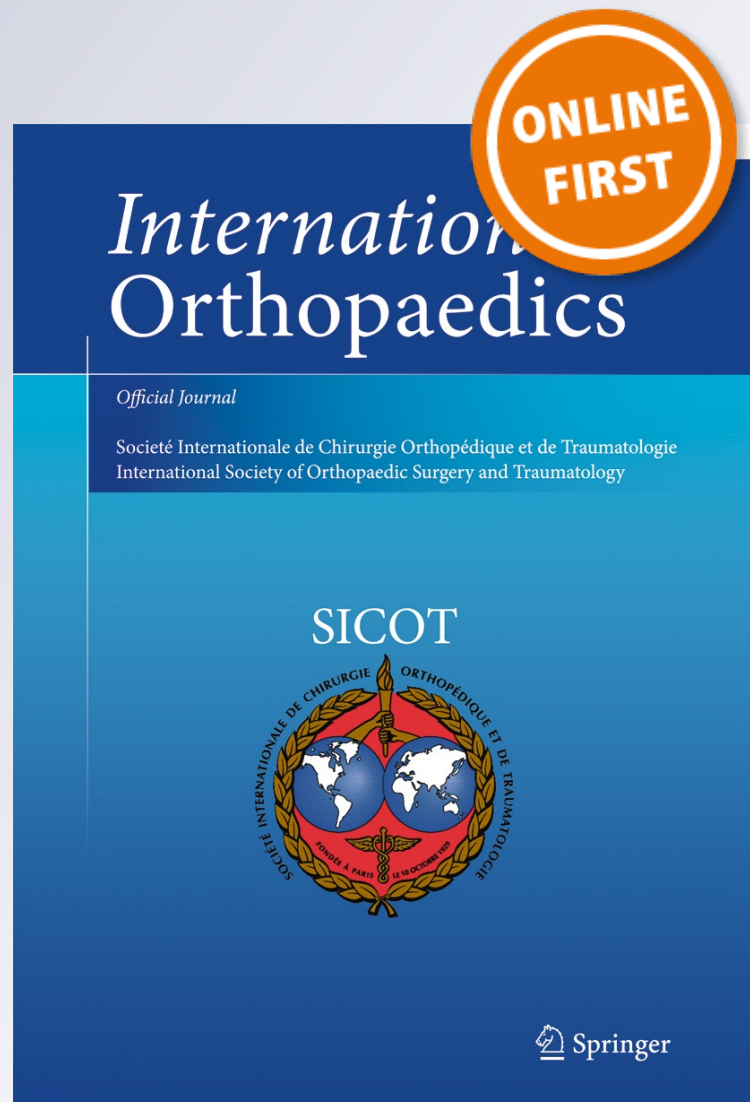
# *Reverse shoulder prosthesis in patients with rheumatoid arthritis: a systematic review*

**Roberto Postacchini, Stefano Carbone,  
Gianfranco Canero, Maurizio Ripani &  
Franco Postacchini**

**International Orthopaedics**

ISSN 0341-2695

International Orthopaedics (SICOT)  
DOI 10.1007/s00264-015-2916-2



**Your article is protected by copyright and all rights are held exclusively by SICOT aisbl. This e-offprint is for personal use only and shall not be self-archived in electronic repositories. If you wish to self-archive your article, please use the accepted manuscript version for posting on your own website. You may further deposit the accepted manuscript version in any repository, provided it is only made publicly available 12 months after official publication or later and provided acknowledgement is given to the original source of publication and a link is inserted to the published article on Springer's website. The link must be accompanied by the following text: "The final publication is available at [link.springer.com](http://link.springer.com)".**

# Reverse shoulder prosthesis in patients with rheumatoid arthritis: a systematic review

Roberto Postacchini<sup>1</sup> · Stefano Carbone<sup>2</sup> · Gianfranco Canero<sup>3</sup> · Maurizio Ripani<sup>1</sup> · Franco Postacchini<sup>4</sup>

Received: 5 April 2015 / Accepted: 1 July 2015  
© SICOT aisbl 2015

## Abstract

**Purpose** To obtain detailed information on the outcomes of patients with rheumatoid arthritis (RA) undergoing reverse shoulder arthroplasty (RSA)

**Methods** A literature search was conducted for studies reporting on the use of RSA in RA patients from 1990 to 2014. The inclusion criteria were a report of sufficient information on pre-operative status and surgical outcome allowing evaluation of the therapeutic potential of RSA in RA. The literature search resulted in 586 hits, but only five studies that met the inclusion criteria were assessed.

**Results** There were 100 shoulders that had been operated on, of which 87 were followed for a mean of 55.4 months, the longest follow-up being 11.9 years. Most patients had glenohumeral erosive lesions of Larsen Grade III or IV. The Delta III prosthesis was implanted in most cases and in three studies bone graft was used for severe glenoid lesions. The main outcome measures employed were the Constant score (Cs) and ASES questionnaire. The mean increase in Cs and ASES score after surgery was 42.4 and 54 points, respectively. The mean post-operative forward elevation was 120.6°, the average increment being 51° and the mean increase of abduction was 58.5°. The mean prevalence of scapular notching was 35.4 %. The rate of adverse events was 31 %, but the vast

majority were of minor severity. Eight prostheses underwent revision, due to infection in four.

**Conclusions** RSA implanted in RA patients would appear to give similar results to those obtained in massive cuff tears with or without arthropathy.

**Keywords** Reverse shoulder arthroplasty · Reverse shoulder prosthesis · Rheumatoid arthritis · Outcomes · Revisions

## Introduction

In the 1970s to 1990s, the surgical treatment for patients with rheumatoid arthritis (RA) needing an arthroplasty was a hemiarthroplasty (HA) or total shoulder arthroplasty (TSA) [1]. However, in the long-term, patients with HA have worsening of arm function if a large cuff tear occurs or an already present tear increases in size due to destructive changes of periarticular soft tissues inherent to RA. In these cases, progressive anterosuperior instability of the implant may occur [2]. This results in loss of varying severity of active shoulder motion and in destructive changes of the humeral head and glenoid, which overlap possible erosive bone changes that RA entails. It was found, in fact, that 48 % of rheumatoid patients followed for 15 years develop even severe glenohumeral erosive changes [3]. On the other hand, when a TSA is implanted, there is a high risk of glenoid loosening in the presence of a massive cuff tear [4].

With the advent of the reverse shoulder arthroplasty (RSA) [5], rheumatoid patients with pain and severe shoulder dysfunction resulting from massive cuff tear began to be treated with RSA due to its ability to decrease shoulder pain and restore arm motion in the absence of a functioning rotator cuff. However, little is yet known on the outcomes of

✉ Stefano Carbone  
stefcarbone@yahoo.it

<sup>1</sup> Italian University of Sports and Movement, Roma, Italy

<sup>2</sup> Department of Molecular Medicine, University of Rome, Roma, Italy

<sup>3</sup> Orthopaedic Surgery, Clinica San Feliciano, Roma, Italy

<sup>4</sup> Sapienza University of Rome, Roma, Italy

RSA in rheumatoid patients because a limited number of cases appear to have been treated with reverse prosthesis. Furthermore, the numerous studies assessing the results of RSA included no rheumatoid patients or, when they were present, no or only scant information was provided on their outcomes.

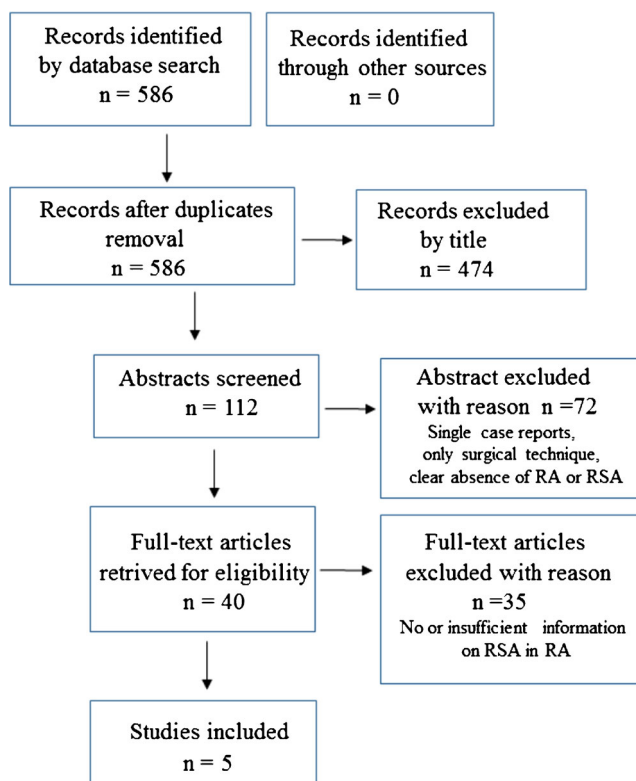
This review was aimed at providing detailed information on the various aspects of treatment of rheumatoid patients undergoing RSA.

## Materials and methods

### Literature search

This review was performed according to the PRISMA statement [6] (Fig. 1). A search of the literature was conducted by two independent reviewers (S.C., G.C.) in Pubmed, EMBASE and Cochrane Central Register of Controlled Trials to identify relevant publications from 1990 to 2014.

The following keywords were used: shoulder prosthesis, hemiarthroplasty, reverse, inverse, delta, Grammont arthroplasty, total shoulder prosthesis or arthroplasty, rheumatoid arthritis, outcomes, complications, revisions, infections. The Medline and EMBASE search was performed by using combinations of the selected keywords.



**Fig. 1** Flow chart of the search for studies that met the inclusion criteria

### Criteria of inclusion

The studies had to provide sufficient information on RSA in patients with RA, in terms of pre-operative conditions and outcomes of surgery. The reported cases in each study had to be not less than three. The mean follow-up should be at least 36 months, provided that the longest was carried out at a minimum of five years. This decision was taken because the intra-operative or early post-operative complications were independent of the length of follow-up, whereas those related to implant, such as wear or loosening, might depend on the length of follow-up. The studies had to provide the results using one or more widely employed outcome measures assessing pain and shoulder function and to include the pre-operative and post-operative data.

### Study selection

A total of 586 citations were screened. The titles were selected to identify studies dealing with: (1) reverse or inverse shoulder prosthesis or arthroplasty in rheumatoid arthritis; (2) shoulder arthroplasty (RSA or TSA) in patients undergoing surgery for various aetiologies; these publications were selected because their patient populations might include cases with RA who had had RSA.

The abstracts of 112 publications were assessed, but 72 were excluded because they were not eligible for our review. A full-text article was retrieved for 40 studies (Fig. 1). Of the latter, 33 were excluded. In 19 reporting on patients who had undergone RSA or TSA, there were no rheumatoid patients with RSA [7–25]; nine studies on patients who had had an RSA for various aetiologies included one or more rheumatoid patients, but no or insufficient information was provided on their outcomes [26–34]; three review articles on RSA in patients with various conditions gave very little information, contained in a short paragraph [35, 36], or limited information [37], for the RA group; there were also two articles of general information on shoulder arthroplasty reporting no own case series [38, 39]. Two additional studies reported enough pertinent and useful information on several [40] or many [41] RA patients undergoing RSA, but they were excluded because the mean follow-up was less than 36 months and the longest did not reach five years. This review was thus based on the five studies that met the inclusion criteria [42–46]: all dealing exclusively with RA patients.

### Data extraction

A checklist was used to extract data from each study that met the inclusion criteria. The data included the number, age and gender of patients, number of shoulders undergoing arthroplasty, number of patients followed-up and the mean, and range of, follow-up. The clinical outcome measures and

the grade of the rheumatoid changes of the involved shoulder were recorded. Surgical approach, type of RSA implanted, use of bone graft and intra-operative complications, as well as rehabilitation protocols and post-operative radiographic findings were also recorded. The protocol included the clinical results based on the outcome measures, degrees of shoulder motion, post-operative complications including implant wear or loosening and revision surgeries.

**Selection or exclusion bias**

In all studies selected, the mean age of patients was similar as was, for the majority, the ratio of females to males. All were case series with no comparison group. In three studies a single outcome measure, the Constant and Murley score [47] (Cs), was used. In one, three measures, including the Cs, were employed and in another the American Society of Elbow Surgeons (ASES) system was adopted. The percentage of cases (operated-on shoulders) lost to final follow-up ranged from 12 to 23 %. It thus appeared that there was no or only minor potential for selection or exclusion bias in the review.

**Results**

**Demographic and pathological data**

The demographic data of the cohorts of patients, total number of patients and length of follow-up are reported in Table 1. The number of patients included in the review was 91 and the number of operated-on shoulders was 100, of which 87 were followed-up. The total mean follow-up of the five studies was 46.4 months, i.e. slightly less than five years, including two studies [43, 45] in which the latest follow-up was carried at nine and 11.9 years after surgery, respectively (Table 1).

All 91 patients had RA associated with cuff tears of varying size. The vast majority had full-thickness tears of two cuff tendons or massive irreparable tears and destructive changes of the shoulder joint. In three studies [42–44] the erosive lesions were graded according to the classification of Larsen et al. [48], which distinguishes six grades (0–V). The majority of patients had lesions of Larsen Grade III or IV and a minority of Grade II or V. In two studies the joint changes were assessed using the Lévigne classification [49], which identifies six types (C1, C2, A1, A2, D1, D2) indicating progressive severity of lesions: in one [45] most patients had Type C2 or A1 lesions and in the other [46] the majority had Type A1 or A2. In the only report [44] in which upward migration of the humeral head with respect to the glenoid was assessed pre-operatively, most patients had subluxations of 0–25 % or 25–50 %.

**Surgical technique and types of RSA**

In almost all cases the deltopectoral approach was carried out, whereas in three patients of one study [42] a transacromial approach was performed and in most primary arthroplasties of another cohort [45] a superior deltoid splint was used.

The Delta III prosthesis (DePuy, Warsaw, IN, USA) was implanted in all cases of the two oldest studies [42, 43], an Aequalis (Tornier, Amsterdam, The Netherlands) in one [46] and a DJO prosthesis (DJO Surgical, Vista, CA, USA) in another one [44]. Ekelund and Nyberg [45] initially implanted the Delta III and subsequently the Delta Xtend. In two studies [45, 46] the glenoid baseplate was placed, when possible, in a low position. The size of the glenosphere was mostly 36 mm. In most studies the humeral stem was cemented and implanted in 0–30° of retroversion, but mostly in 0 or 10°.

In three studies [44–46], patients who had severe defects of the central glenoid or peripheral erosions underwent bone grafting. The graft was either cancellous or structural. Both types were obtained from the resected humeral head or a

**Table 1** Demographic data, number of patients and operated shoulders, patients followed-up and length of follow-up

Reference		Age		Gender		Operated-on patients (n)	Operated-on shoulders (n)	Shoulders followed-up (n)	Follow-up (months)	
		Mean	Range	M	F				Mean	Range
Riitmeister [42]	(2001)	60.2	34–86	2	6	7	8	8	54	48–73
Woodruff [43]	(2003)	64	43–72	1	14	15	17	13	87	60–110
Holcomb [44]	(2010)	70.4	53–80	5	16	24	24	<sup>a</sup> 21	36	24–74
Ekelund [45]	(2011)	68	45–80	7	22	29	33	<sup>b</sup> 27	56	18–143
Young [46]	(2011)	70.1	46–86	2	14	16	18	18	44	25–84
Total						91	100	87	55.4	18–143

<sup>a</sup> 18 primary RSA and 3 revisions of HA, TSA or bipolar HA to RSA

<sup>b</sup> 18 primary RSA and 9 revisions of HA or TSA to RSA, NR, value not reported

structural allograft was used [45]. The cancellous bone was impacted in the central portion of the glenoid for central defects. Structural grafts were also used for central defects, but were more often employed to reconstruct peripheral defects. They were temporarily stabilised with K wires and definitively secured using the screws employed for fixation of the glenoid baseplate [45]. Occasionally, independent cannulated screws were used [44].

### Postoperative rehabilitation

Holcomb et al. [44] immobilised the patients in adduction and internal rotation for 6 weeks, after which the activities of daily living were permitted. Other authors [46] allowed passive motion immediately after surgery, but prescribed the use of a sling for 1 month. Ekelund and Nyberg [45], when using the deltopectoral approach, permitted immediate active motion, but did not allow efforts with the operated-on shoulder for six weeks.

### Clinical outcomes

Six outcome measures were used (Table 2). The most employed was the Cs method (0–100 score), utilised in four studies [42, 43, 45, 46]. The next most used were the VAS (visual analogue scale) followed by the ASES (American Shoulder and Elbow Surgeons) questionnaire (0–50 score for each of the two sections) the SST (simple shoulder test) (one section with 12 questions, and one with 6 and 15 questions) and SSV (simple shoulder value) (0–100 score) employed in two studies.

In the studies using the Cs (Table 2), the mean pre-operative score ranged from 3 [45] to 22 [46] with a mean of 17.1 points and the post-operative scores from 52 [45] to 64 [46], with a mean of 59.5, the average increase being 42.4 points. The most recent studies [45, 46] reported statistically

significant differences between the pre-operative and post-operative scores. Holcomb et al. [44] provided the total ASES mean score, which increased on average from 28 pre-operatively to 82 post-operatively, with a mean increment of 54 points. They also used the ASES pain and ASES function, and VAS pain and VAS function scales. The former increased by 30 points on average, parallel to the mean decrease in VAS pain of 6 points, and the mean ASES function increased on average by 24 points, whereas the VAS function improved by 3 points. The differences were significant for all outcome measures.

The SST, used by Holcomb et al. [44], increased on average by 6 points after surgery. The mean SSV was 85 after primary arthroplasty and 64 after revision surgery in the Ekelund and Nyberg study [45].

Shoulder range of motion (ROM) was reported in detail in the three most recent studies [44–46]. One of the oldest studies [42] reported the scores obtained in the ROM section (0–40 points) of Cs method, whereas in the other [43] no specific information was provided (Table 3).

In the most recent studies, the pre-operative flexion ranged from 33 to 77°, mean 69.6°, and the post-operative motion from 101 to 138°, with a mean of 120.6°, the average increment being 51°. Pre-operatively the mean range of abduction was 26–65°, on average 49.7°, and post-operatively it ranged from 95 to 119°, with a mean of 108.2°, the increase reaching 58.5° on average. In all three studies the differences for both motions were significant. Comparable values for external rotation (ER) were reported in two studies [44, 46], because one [45] provided the degrees of movement based on the points obtained in the ROM section of the Cs. Of the former two studies, one [46] assessed the degrees of motion both with the arm at the side and at 90° of abduction. Before surgery the mean ER was 19° [44] and 15° [46] with the arm at the side and 16 at 90° of abduction. After surgery, the average ER with the arm at the side was 19 and 45°, respectively, mean of

**Table 2** Mean value and (range) of outcome measures used for assessment of clinical results

Riitmeister [42]	Cs					
	Pre 17 (4–25)					
	Post 63 (41–79)					
Woodruff [43]	Cs					
	Pre 17 (4–25)					
	Post 59 (37–86)					
Holcomb [44]	ASES Total	ASES pain	ASES function	VAS pain	VAS function	SST
	Pre 28 (5–65)	Pre 15 (2–42)	Pre 13 (0–30)	Pre 7 (1–9)	Pre 3 (0–9)	Pre 1 (0–2)
	Post 82 (23–100)	Post 45 (0–50)	Post 37 (8–50)	Post 1 (0–10)	Post 6 (0–10)	Post 7 (0–12)
Ekelund [45]	Cs	VAS	SSV			
	Pre 3 (2–34)	Pre 8 (4–10)	85 ± 16 primary surgery			
	Post 52 (15–77)	Post 1 (0–9)	64 ± 26 revision surgery			
Young [46]	Cs					
	Pre 22 (8–47)					
	Post 64 (28–85)					

Cs Constant score, ASES American shoulder elbow surgeons (score), VAS visual analogue scale, SST simple shoulder test, SSV simple shoulder value

**Table 3** Mean (range) pre-operative and post-operative motions, and patient's satisfaction

Reference	FE Preop Postop	ABD Preop Postop	ER Preop Postop	IR Preop Postop	Subjective outcome (no. of patients)
Riitmeister [42] <sup>a</sup>	5.3 (0–8) 28 (16–36)				6 satisfactory
Woodruff [43]	NR	NR	NR	NR	NR
Holcomb [44]	52° (10–87°) 126° (0°–180°)	55° (10–93°) 116° (0°–180°)	19° (–5 to 90°) 33° (–10 to 75)	S1 L4	12 excellent 6 good 2 satisfactory 1 unsatisfactory
Ekelund [45]	33° (0–110°) 115° (0–160°)	26° (0–80°) 103° (20–180°)	<sup>b</sup> 0.6 ± 1.2 5.8 ± 3.0	<sup>b</sup> 2.1 ± 2.2 2.9 ± 2.4	NR
Young [46]	77° (30–170°) 138° (40–170°)	NR NR	Arm at side 15° (–10° to 80°) 19° (0–80°)  Arm at 90° 16° (–10 to 80°) 46° (0–90°)	Sacrum (thigh-T10) L3 (buttock-T7)	11 excellent 6 good 1 unsatisfactory SSV mean 68 (20–100)

FE forward elevation, ABD abduction, ER external rotation, IR internal rotation, Preop preoperative, Postop post-operative, NR value not reported, SSV simple shoulder value

<sup>a</sup> Movements assessed all together according to points in the Constant score

<sup>b</sup> Movement assessed according to points in the Constant score

32.3°, the average increase being 10.3°, whereas with the arm in abduction the mean increment reached 30°. As for the internal rotation (IR), in two investigations [44, 46] the post-operative mean increment was 2 and 3 levels, respectively, and in the study which calculated the movement based on Cs, the mean increment was approximately of 1 point. In the Riitmeister and Kerschbaumer study [42], who provided the entire shoulder ROM as points obtained in the Cs, there was a mean increment of 22.7 points post-operatively (Table 3).

In three series [42, 44, 46], including 45 cases, the subjective outcome of surgery was considered excellent or good by 77.7 % of patients, satisfactory by 17.7 % and unsatisfactory by 2.2 % (Table 3).

**Radiographic results**

Scapular notching was detected in two studies [45, 46] (Table 4). In one [45], the notching was assessed according to Nerot's classification [49], whereas the other used the Sirvaux's classification [50]. Both classifications identify 5 grades of notching. The mean prevalence in these studies was 53.6 %. The majority of shoulders for which the Nerot classification was used had notching Grade 3 or 4. In the study using the Sirvaux classification, most shoulders had Grade 1 or 2. Both studies found the scapular notching not to affect the clinical outcome. Holcomb et al. [44], however, detected no

notching in the 21 shoulders that they followed-up. The overall prevalence of notching was thus 35.4 %.

In the three series [44–46], in which bone graft was impacted on the glenoid, the graft healed with certainty [46] or presumably healed since no contrary information was provided for the other two series.

**Complications, reoperations other than revisions, and revisions**

Adverse events, of minor or major severity, were recorded in 31 of the 100 operated-on shoulders.

There were seven intraoperative complications [43–46] (Table 5), i.e. 7 % of operated-on shoulders. The most frequent was a fracture of the glenoid, which occurred in three patients, the cause of which, however, was reported only for one case [45], in which the fracture occurred during reaming of the glenoid, without preventing implantation of the glenoid baseplate. Another glenoid fracture required osteosynthesis with a screw, which allowed stable fixation of the glenoid baseplate. The remaining four complications occurred in the patients of a single study [46]. They included an avulsion fracture of the coracoid process, repaired with non-absorbable sutures, two avulsions of the greater tuberosity identified on immediate post-operative radiographs that did

**Table 4** Prevalence of scapular notching

12 shoulders [45] out of 23 checked	(52 %) Nerot Grade: 1–2 in 1; 3 in 7; 4 in 4
10 shoulders [46] out of 18	(55 %) Sirveaux Grade: 1 in 4; 2 in 4; 3 in 1; 4 in 1
No shoulders [44] out of 21 checked	(0 %)

Percentage calculated on the number of cases followed-up

not require further surgery and an axillary nerve neuroapraxia which recovered in 4 months.

The 13 post-operative complications (14.9 %) included fractures, glenoid radiolucencies and aseptic glenoid loosening (Table 5). Of the three fractures, two involved the scapular spine and one the acromion [44, 46]. Both scapular injuries, although causing prolonged pain and limitation of abduction, were treated conservatively. The acromial fracture resulted in inferior tilt of the fragment, but the patient had no dysfunction. Three periglenoid radiolucencies and one aseptic glenoid loosening underwent no specific treatment.

Re-operations were carried out in the three patients of the Riimeister and Kerschbaumer series [42] in whom a transacromial approach had been performed (Table 5). They had failure of fixation and underwent repeat osteosynthesis of the acromion.

Arthroplasty revisions (Table 5) were carried out in eight shoulders (9.1 %). One patient with periprosthetic glenoid fracture, resulting from a fall, underwent internal fixation of the fracture and revision to hemiarthroplasty [44]. One of the patients with aseptic glenoid loosening had replacement of the glenoid component [42]. Of the four patients with infection,

one underwent debridement and exchange of the humerus socket with no recurrence of infection [44] and one patient, who developed the infection six years after RSA, had removal of the prosthesis and implantation of a cemented hemiarthroplasty spacer [44]. Another patient, who had undergone RSA for revision of a failed TSA, required revision to a second RSA [45]. In the fourth of the infected cases, the prosthesis was removed [42]. In one patient, who started to have prosthetic instability five years after surgery due to wear of the polyethylene insert; a new retentive insert was implanted with no subsequent instability [45]. One shoulder that had breakage of the central screw connecting the glenosphere to the glenoid baseplate underwent replacement of the glenoid component [45].

**Discussion**

This review has several limitations. A limited number of studies has been published on RSA in RA, only few met the criteria to be included in the review and one of them [42] reported a small number of cases. A few studies provided

**Table 5** Complications, re-operations other than revisions and revisions

Complications		
Intraop. 7 % (100 Op. Sh.)	Postop., with no further surgery	14.9 % (87 Sh. FU)
Fracture	Fracture	
Glenoid 3 [43, 44, 45]	Scapular spine	2 [44, 46]
Coracoid 1 [46]	Acromion	1 [46]
GT 2 [46]	Glenoid	1 [46]
Nerve injury 1 [46]		
	Glenoid radiolucencies	3 [43]
	Aseptic glenoid loosening	6 [42, 43]
	Reoperations 2.7 % (87 Sh. FU)	
	Osteosynthesis of acromion after transacromial approach	3 [42]
	Revisions 9.1 % (87 Sh. FU)	
Periprosthetic glenoid Fx, osteosyntesis and HA		1 [44]
Aseptic glenoid loosening, exchange glenoid		1 [42]
Infection, exchange polyethylene humerosocket		1 [44]
Infection, cemented HA spacer		1 [44]
Infection after revision of TSA, new RSA		1 [45]
Infection, prosthesis removed		1 [42]
Humerus socket wear, exchange of insert		1 [45]
Breakage glenosphere screw, exchange of glenoid		1 [45]

FU followed-up; Intraop. intraoperative, Postop. postoperative, Op. operations, Sh. shoulders



incomplete information on the pre-operative and post-operative functional status. The length of follow-up in some reports was relatively short for the assessment of survivorship of an RSA, although the mean follow-up of the whole group reached almost five years and in two studies [43, 45] a few patients were followed for approximately nine and 12 years, respectively. Nevertheless, this review appears to be valuable because it allowed assessment of the outcome of 87 shoulders out of the 100 that underwent RSA in a condition for which little is known on the outcomes of the reverse prosthesis.

Guery et al. [28] stated that extreme caution is needed regarding the use of RSA in patients with RA because they have the highest percentage of implant revisions, which were two, both due to infection, in the eight rheumatoid cases in their series. Similarly, Favard et al. [27] found the post-operative Cs and functional improvement to be significantly poorer in cases with RA than in those operated on for other aetiologies. However, of the 18 rheumatoid patients in their series, only six had undergone RSA; the remaining 12 had TSA or HA and the authors do not specify whether the poor results were found in those with RSA or also in the other rheumatoid patients. Nevertheless, the statements in these two studies have generated concern about the use of RSA in rheumatoid patients.

In the four studies of this review that used the Cs as outcome measure [42, 43, 45, 46], the mean score increased from 17.1 to 60.7, with a mean increment of 42.4 points. Such increase compares well with the mean total ASES score [44], which reached 82 points post-operatively, with a mean increase of 54 points. Shoulder pain showed a considerable improvement, as reflected by VAS pain scores reported in two studies [44, 45], in which there was a mean decrement of 7 and 6 points, respectively. As for function, in the studies that reported the pre-operative and post-operative ROM [44–46], the arm flexion increased on average by 51° and the abduction by 58.5°. The results found in this review, in terms of mean scores in the outcome measures, arm flexion and abduction, and pain relief, are similar to those in studies analysing the results of RSA in large cohorts of patients with massive rotator cuff tear or cuff tear arthropathy (CTA). In the series of 80 shoulders of Sirveaux et al. [51], the mean Cs increased by 43 points and the flexion by 65°. In the cohort of Frankle et al. [13], the mean total ASES score improved by 33.9 points, the VAS score for pain by 3.3 points, and the mean flexion and abduction by 50.1 and 59.6°, respectively. Wall et al. [34], in a cohort of 103 shoulders followed for a mean of 39.9 months, found a mean improvement in Cs of 39.5 points. In 71 shoulders undergoing RSA for CTA assessed by Nolan et al. [52] the Cs improved by 34 points, the ASES score by 50 points and the SSV was 77, on average, whereas the mean flexion increased by 60° and ER did not change. Of the 45 patients of this review for whom the subjective outcome of surgery was reported [42, 44, 46], 77 % considered their results as

excellent or good. This rate is comparable to that obtained recorded in several studies in which the RSA was mostly implanted for massive cuff tears or CTA [10, 13, 31, 51].

In one study of this review [45] in which there were three revisions (out of 23 shoulders), post-operatively the revised cases had a mean Cs of 43 and a mean SSV of 64 points compared to 57 and 84 points, respectively, of the patients with primary arthroplasty. This finding is consistent with the lower mean Cs found in patients with different conditions than RA who underwent revision of HA or TSA to RSA [11, 34, 50, 53] compared with those who had RSA as primary arthroplasty.

The mean prevalence of scapular notching was 35 %, which is similar to the percentages reported in several studies [13, 31, 33, 34] in which the rate ranged from 43 to 51 %, and lower than the 68 % found by Boileau et al. [9]. As in other studies [30, 33], the notching did not appear to affect the clinical outcome.

In a comprehensive review of the literature on complications of RSA, Scarlat [54] described 20 types of complications, that he classified into four categories, and analysed the causes and possible solutions for some of them. In our review, in which many of those situations were found, we distinguished three types of adverse events, identified as complications, re-operations other than revisions, and revisions. The scapular notching was not included among the adverse events because it is not peculiar of TSA in RA and appears to depend, to a large extent, on the height of implantation of the glenosphere and/or the use of a concentric, rather than the more recent eccentric, glenosphere [55].

The mean rate of adverse events in the studies of this review was 32 %, which is comparable to the 33.3 % found by Zumstein et al. [53] in a review of 782 cases of RSA carried out for various aetiologies.

Many of those that we termed complications were adverse events of minor severity, requiring no surgery and mostly not affecting the clinical outcome. The vast majority were intra-operative or post-operative fractures related to the increased bone fragility of the rheumatoid patients.

The re-operations other than revisions were performed in three patients operated on in the 1990s when a transacromial approach was used by many surgeons, but subsequently almost completely abandoned.

The major complications needing arthroplasty revision were 7.4 %, a rate that is within the range of the rates reported in studies on RSA, not dealing with RA, that included a high number of patients. In four of such studies the rate of revisions was 4.5 % [34], 7.5 % [28], 12 % [13] and 14.8 % [27]. In this review, infection was the cause of revision in four of eight cases. This high infection rate in patients with RA is likely related to the disturbances of the immune system responsible for this autoimmune disease. Rheumatoid patients thus need special precautions in this regard, such as the administration of

antibiotics one or more days before surgery [45] or the use of antibiotic-loaded bone cement, able to reduce the risk of infection in shoulder arthroplasty [15].

The results of this review appear to indicate that the clinical outcomes of RSA in RA are comparable to those obtained in patients with massive rotator cuff tears with or without arthropathy. Anyhow, it should be highlighted that the follow-up of many patients in this study was relatively short to evaluate the implant-related adverse events (revision, severe glenoid loosening), which tend to increase in number with increasing time from surgery [28, 54]. However, the survival rate of the implant in the entire group of studies was 90.8 % at a mean of almost five years, which is an encouraging figure, though not so high as to give the patients sound certainty of long-term good results. Our findings support the belief of Favard et al. [27] that young patients with RA are better candidates for HA, whereas an RSA can be indicated in older subject as, on the other hand, it is still the rule in the most common indications for RSA.

**Conflict of interest** The authors declare that they have no conflict of interest.

## References

- Sperling JW, Cofield RH, Schleck CD, Harmsen WS (2007) Total shoulder arthroplasty versus hemiarthroplasty for rheumatoid arthritis of the shoulder: results of 303 consecutive cases. *J Shoulder Elbow Surg* 16:683–690
- Field LD, Dines DM, Zabinski SJ, Warren RF (1997) Hemiarthroplasty of the shoulder for rotator cuff arthropathy. *J Shoulder Elbow Surg* 6:18–23
- Lehtinen JT, Belt EA, Lybäck CO, Kauppi MJ et al (2000) Subacromial space in the rheumatoid shoulder: a radiographic 15-year follow-up study of 148 shoulders. *J Shoulder Elbow Surg* 9: 183–187
- Franklin JL, Barrett WP, Jackins SE, Matsen FA 3rd (1988) Glenoid loosening in total shoulder arthroplasty. Association with rotator cuff deficiency. *J Arthroplasty* 3:39–46
- Baulot E, Garron E, Grammont PM (1999) Grammont prosthesis in humeral head osteonecrosis. Indications-results. *Acta Orthop Belg* 65(Suppl 1):109–115
- Moher D, Liberati A, Tetzlaff J, Altman DG, PRISMA Group (2009) Preferred reporting items for systematic reviews and meta-analyses: the PRISMA statement. *BMJ* 339:b2535. doi:10.1136/bmj.b2535
- Abdel MP, Hattrup SJ, Sperling JW, Cofield RH et al (2013) Revision of an unstable hemiarthroplasty or anatomical total shoulder replacement using a reverse design prosthesis. *Bone Joint J* 95 Br:668–672. doi:10.1302/0301-620X.95B5.30964
- Baulot E, Chabernaud D, Grammont PM (1995) [Results of Grammont's inverted prosthesis in omarthrosis associated with major cuff destruction. Apropos of 16 cases]. *Acta Orthop Belg* 61(Suppl 1):112–119
- Boileau P, Watkinson D, Hatzidakis AM, Hovorka I (2006) Neer Award 2005: the Grammont reverse shoulder prosthesis: results in cuff tear arthritis, fracture sequelae, and revision arthroplasty. *J Shoulder Elbow Surg* 15:527–540. doi:10.1016/j.jse.2006.01.003
- Boulahia A, Edwards TB, Walch G, Baratta RV et al (2002) Early results of a reverse design prosthesis in the treatment of arthritis of the shoulder in elderly patients with a large rotator cuff tear. *Orthopedics* 25:129–133
- Castagna A, Delcogliano M, de Caro F, Ziveri G et al (2013) Conversion of shoulder arthroplasty to reverse implants: clinical and radiological results using a modular system. *Int Orthop* 37: 1297–1305. doi:10.1007/s00264-013-1907-4
- Cuff D, Pupello D, Virani N, Levy J et al (2008) Reverse shoulder arthroplasty for the treatment of rotator cuff deficiency. *J Bone Joint Surg Am* 90:1244–1251. doi:10.2106/JBJS.G.00775
- Frankle M, Siegal S, Pupello D, Saleem A et al (2005) The Reverse shoulder prosthesis for glenohumeral arthritis associated with severe rotator cuff deficiency. A minimum two-year follow-up study of sixty patients. *J Bone Joint Surg Am* 87:1697–1705
- Levy JC, Virani N, Pupello D, Frankle M (2007) Use of reverse shoulder prosthesis for the treatment of failed hemiarthroplasty in patients with glenohumeral arthritis and rotator cuff deficiency. *J Bone Joint Surg (Br)* 89:189–195. doi:10.1302/0301-620X.89B2.18161
- Nowinski RJ, Gillespie RJ, Shishani Y, Cohen B et al (2012) Antibiotic-loaded bone cement reduces deep infection rates for primary reverse total shoulder arthroplasty: a retrospective, cohort study of 501 shoulders. *J Shoulder Elbow Surg* 21:324–328. doi: 10.1016/j.jse.2011.08.072
- Ortmaier R, Resch H, Matis N, Blocher M et al (2013) Reverse shoulder arthroplasty in revision of failed shoulder arthroplasty—outcome and follow-up. *Int Orthop* 37:67–75. doi:10.1007/s00264-012-1742-z
- Patel DN, Young B, Onyekwelu I, Zuckerman JD et al (2012) Reverse total shoulder arthroplasty for failed shoulder arthroplasty. *J Shoulder Elbow Surg* 21:1478–1483. doi:10.1016/j.jse.2011.11.004
- Rahme H, Mattsson P, Wikblad L, Larsson S (2006) Cement and press-fit humeral stem fixation provides similar results in rheumatoid patients. *Clin Orthop Relat Res* 448:28–32
- Richards J, Inacio MCS, Beckett M, Navarro RA et al (2014) Patient and procedure-specific risk factors for deep infection after primary shoulder arthroplasty. *Clin Orthop Relat Res* 472:2809–2815. doi:10.1007/s11999-014-3696-5
- Schairer WW, Zhang AL, Feeley BT (2014) Hospital readmissions after primary shoulder arthroplasty. *J Shoulder Elbow Surg* 23:1349–1355. doi:10.1016/j.jse.2013.12.004
- Seebauer L, Walter W, Keyl W (2005) Reverse total shoulder arthroplasty for the treatment of defect arthropathy. *Oper Orthop Traumatol* 17:1–24
- Vanhove B, Beugnies A, Grammont PM (2004) Reverse shoulder prosthesis for rotator cuff arthropathy. A retrospective study of 32 cases. *Acta Orthop Belg* 70:219–233
- Walch G, Boileau P, Noël E (2010) Shoulder arthroplasty: evolving techniques and indications. *Joint Bone Spine* 77:501–505. doi:10.1016/j.jbspin.2010.09.004
- Walker M, Willis MP, Brooks JP, Pupello D et al (2012) The use of the reverse shoulder arthroplasty for treatment of failed total shoulder arthroplasty. *J Shoulder Elbow Surg* 21:514–522. doi:10.1016/j.jse.2011.03.006
- Werner CM, Steinmann PA, Gilbert M, Gerber C (2005) Treatment of painful pseudoparesis due to irreparable rotator cuff dysfunction with the Delta III reverse-ball-and-socket total shoulder prosthesis. *J Bone Joint Surg Am* 87:1476–1486. doi:10.2106/JBJS.D.02342
- Dillon MT, Inacio MC, Burke MF, Navarro RA et al (2013) Shoulder arthroplasty in patients 59 years of age and younger. *J Shoulder Elbow Surg* 22:1338–1344. doi:10.1016/j.jse.2013.01.029

27. Favard L, Katz D, Colmar M, Benkalfate T et al (2012) Total shoulder arthroplasty—arthroplasty for glenohumeral arthropathies: results and complications after a minimum follow-up of 8 years according to the type of arthroplasty and etiology. *Orthop Traumatol Surg Res* 98:541–547
28. Guery J, Favard L, Sirveaux F, Oudet D et al (2006) Reverse total shoulder arthroplasty. Survivorship analysis of eighty replacements followed for five to ten years. *J Bone Joint Surg Am* 88:1742–1747
29. Jiang JJ, Toor AS, Shi LL, Koh JL (2014) Analysis of perioperative complications in patients after total shoulder arthroplasty and reverse total shoulder arthroplasty. *J Shoulder Elbow Surg* 23:1852–1859. doi:10.1016/j.jse.2014.04.008
30. Lévigne C, Boileau P, Favard L, Gaeaud P et al (2008) Scapular notching in reverse shoulder arthroplasty. *J Shoulder Elbow Surg* 17:925–935. doi:10.1016/j.jse.2008.02.010
31. Muh SJ, Streit JJ, Wanner JP, Lenarz CJ et al (2023) Early follow-up of reverse total shoulder arthroplasty in patients sixty years of age or younger. *J Bone Joint Surg Am* 95:1877–1883. doi:10.2106/JBJS.L.10005
32. Sershon RA, Van Thiel GS, Lin EC, McGill KC et al (2014) Clinical outcomes of reverse total shoulder arthroplasty in patients aged younger than 60 years. *J Shoulder Elbow Surg* 23:395–400. doi:10.1016/j.jse.2013.07.047
33. Walch G, Bacle G, Lädermann A, Nové-Josserand L et al (2012) Do the indications, results, and complications of reverse shoulder arthroplasty change with surgeon's experience? *J Shoulder Elbow Surg* 21:1470–1477. doi:10.1016/j.jse.2011.11.010
34. Wall B, Nové-Josserand L, O'Connor DP, Edwards TB et al (2007) Reverse total shoulder arthroplasty: a review of results according to etiology. *J Bone Joint Surg Am* 89:1476–1485. doi:10.2106/JBJS.F.00666
35. Mahmood A, Malal JJ, Waseem M (2013) Reverse shoulder arthroplasty—a literature review. *Open Orthop J* 7:366–372. doi:10.2174/1874325001307010366
36. Smith CD, Guyver P, Bunker TD (2012) Indications for reverse shoulder replacement: a systematic review. *J Bone Joint Surg (Br)* 94:577–583. doi:10.1302/0301-620X.94B5.27596
37. Khan WS, Longo UG, Ahrens PM, Denaro V et al (2011) A systematic review of the reverse shoulder replacement in rotator cuff arthropathy, rotator cuff tears, and rheumatoid arthritis. *Sports Med Arthros* 19:366–379. doi:10.1097/JSA.0b013e318224e44e
38. Hedtmann A, Werner A (2007) [Shoulder arthroplasty in rheumatoid arthritis]. *Orthopade* 11:1050–1061
39. Wiater JM, Fabing MH (2009) Shoulder arthroplasty: prosthetic options and indications. *J Am Acad Orthop Surg* 17:415–425
40. Irlenbusch U, Forke L, Fuhrmann U, Gebhardt K et al (2010) Establishing the differential indication for anatomical and reversed shoulder endoprostheses in rheumatoid arthritis. *Z Rheumatol* 69:240–249. doi:10.1007/s00393-009-0441-7
41. John M, Pap G, Angst F, Flury MP et al (2010) Short-term results after reversed shoulder arthroplasty (Delta III) in patients with rheumatoid arthritis and irreparable rotator cuff tear. *Int Orthop* 34:71–77. doi:10.1007/s00264-009-0733-1
42. Rittmeister M, Kerschbaumer F, Grammont PM (2001) Reverse total shoulder arthroplasty in patients with rheumatoid arthritis and nonreconstructible rotator cuff lesions. *J Shoulder Elbow Surg* 10:17–22
43. Woodruff MJ, Cohen AP, Bradley JG (2003) Arthroplasty of the shoulder in rheumatoid arthritis with rotator cuff dysfunction. *Int Orthop* 27:7–10
44. Holcomb JO, Hebert DJ, Mighell MA, Dunning PE et al (2010) Reverse shoulder arthroplasty in patients with rheumatoid arthritis. *J Shoulder Elbow Surg* 19:1076–1084. doi:10.1016/j.jse.2009.11.049
45. Ekelund A, Nyberg R (2011) Can reverse shoulder arthroplasty be used with few complications in rheumatoid arthritis? *Clin Orthop Relat Res* 469:2483–2488. doi:10.1007/s11999-010-1654-4
46. Young AA, Smith MM, Bacle G, Moraga C et al (2011) Early results of reverse shoulder arthroplasty in patients with rheumatoid arthritis. *J Bone Joint Surg Am* 93:1915–1923. doi:10.2106/JBJS.J.00300
47. Constant CR, Murley AH (1987) A clinical method of functional assessment of the shoulder. *Clin Orthop Relat Res* 214:160–164
48. Larsen A, Dale K, Eek M (1997) Radiographic evaluation of rheumatoid arthritis and related conditions by standard reference films. *Acta Radiol Diagn (Stockh)* 18:481–491
49. Lévigne C (2002) Classifications et évolutions radiographiques de l'épaule rhumatoïde. *Rev Rhum [Ed Fr]* 69(Suppl 3):108–112
50. Valenti P, Boutens D, Nerot C (2001) Delta 3 reversed prosthesis for osteoarthritis with massive rotator cuff tear: long term results (>5 years). In: Walch G, Boileau P, Molé D (eds) 2000 shoulder prostheses two to ten year follow-up. Sauramps Medical, Montpellier, pp 253–259
51. Sirveaux F, Favard L, Oudet D, Huquet D et al (2004) Grammont inverted total shoulder arthroplasty in the treatment of glenohumeral osteoarthritis with massive rupture of the cuff. Results of a multicentre study of 80 shoulders. *J Bone Joint Surg (Br)* 86:388–395
52. Nolan BM, Ankerson E, Wiater JM (2011) Reverse total shoulder arthroplasty improves function in cuff tear arthropathy. *Clin Orthop Relat Res* 469:2476–2482. doi:10.1007/s11999-010-1683-z
53. Zumstein MA, Pinedo M, Old J, Boileau P (2011) Problems, complications, reoperations, and revisions in reverse shoulder arthroplasty: a systematic review. *J Shoulder Elbow Surg* 20:146–157. doi:10.1016/j.jse.2010.08.001
54. Scarlat MM (2013) Complications with reverse total shoulder arthroplasty and recent evolutions. *Int Orthop* 37:843–851. doi:10.1007/s00264-013-1832-6
55. De Biase CF, Ziveri G, Delcogliano M, De Caro F et al (2013) The use of an eccentric glenosphere compared with a concentric glenosphere in reverse total shoulder arthroplasty: two-year minimum follow-up results. *Int Orthop* 37:1949–1955. doi:10.1007/s00264-013-1947-9