

Preliminary Study on Electrophysiological Changes After Cellular Autograft in Age-Related Macular Degeneration

Paolo Giuseppe Limoli, MD, PhD, Enzo Maria Vingolo, Marco Ulisses Morales, MD, PhD, Marcella Nebbioso, MD, and Celeste Limoli, MD, PhD

Abstract: Evolving atrophic macular degeneration represents at least 80% of all macular degenerations and is currently without a standardized care. Autologous fat transplantation efficacy was demonstrated by several studies, as these cells are able to produce growth factors. The aim of the work was to demonstrate possible therapeutic effect of the joined suprachoroidal graft of adipocytes, adipose-derived stem cells (ADSCs) in stromal vascular fractions (SVFs) of adipose tissue, and platelet-rich plasma (PRP).

Twelve eyes in 12 dry age-related macular degeneration (AMD) patients, aged 71.25 (SD \pm 6.8) between 62 and 80 years, were analyzed. A complete ocular evaluation was performed using best corrected visual acuity (BCVA), retinographic analysis, spectral-domain optical coherence tomography, microperimetry, computerized visual field, and standard electroretinogram (ERG). Each eye received a cell in graft between choroid and sclera of mature fat cells and ADSCs in SVF enriched with PRP by means of the variant second Limoli (Limoli retinal restoration technique [LRRT]). In order to test if the differences pre- and post-treatment were significant, the Wilcoxon signed-rank test has been performed.

Adverse effects were not reported in the patients. After surgery with LRRT, the most significant increase in the ERG values was recorded by scotopic rod-ERG (answer coming from the rods), from 41.26 to 60.83 μ V with an average increase of 47.44% highly significant ($P < 0.05$). Moderately significant was the one recorded by scotopic maximal ERG (answer coming from the rods and cones), from 112.22 to 129.68 μ V with an average increase of 15.56% ($P < 0.1$).

Cell-mediated therapy based on growth factors used appears interesting because it can improve the retinal functionality responses

in the short term. The ERG could, therefore, be used to monitor the effect of cell-mediated regenerative therapies.

(*Medicine* 93(29):e355)

Abbreviations: μ V = microvolts, ADSCs = adipose derived stem-cells, AFT = Autologous fat transplantation, AMD = age-related macular degeneration, BCVA = best corrected visual acuity for far distance, bFGF = basic fibroblast growth factor, Close up = visual acuity for near vision, EGF = epidermal growth factor, ERG = electroretinogram, ETDRS = early treatment diabetic retinopathy study, G0 phase = cell quiescence abandonment, G1 phase = cell entry in the phase growth, GM-CSF = granulocyte-macrophage colony-stimulating factor, IGF-1 = insulin-like growth factor-1, IL = interleukin, logMAR = logarithm of the minimum angle of resolution, LRRT = Limoli retinal restoration technique, M-CSF = macrophage colony-stimulating factor, NS = not statistically significant, PDAF = platelet-derived angiogenesis factor, PDGF = platelet-derived growth factor, PEDF = pigment-epithelium-derived factor, PIGF = placental growth factor, PRP = platelet rich plasma, Pts = points, RPEs = retinal pigment epithelial cells, SD = standard deviation, SVF = stromal vascular fractions, T0 = time before of autograft cells, T30 = time after 30 days of autograft cells, TGF- β = transforming growth factor- β , TSP = thrombospondin, VEGF = vascular endothelial growth factor.

INTRODUCTION

Evolving atrophic macular degeneration represents at least 80% of all macular degenerations and is currently without a standardized care. However, since the 1990s, a series of studies using growth factors to block or slow retinal atrophy has begun.¹⁻⁹ The eredodistrophic guinea pigs allow to note the photoreceptor survival promotion, counting the nuclear layer thickness after intravitreal injection of growth factor.^{10,11}

Application of therapy for regenerative purpose in humans is hampered by the rapid half-life of these factors that would require intraocular injections at least every 2 months, with the potential implications that it entail. In fact, some serious side effects have been noted including macular hemorrhages, vitreoretinal interface alterations, intravitreal hemorrhages, retinal detachment, cataract, proliferative vitreoretinopathy, and endophthalmitis.^{1,12,13}

One possible source of autologous growth factors is represented by adipose tissue.¹⁴⁻¹⁷

Autologous fat transplantation efficacy was demonstrated by Filatov's¹⁸ work and Pelaez's¹⁹ work first and from those of Meduri et al²⁰ and Limoli^{21,22} later.

The authors describe functional stabilization in 60% of cases, functional improvement in 15% to 20% of cases, and worsening in 20% of cases. The clinical results, even though interesting, do not last, and after 6 to 18 months, according to the authors' opinion and the type of patient being treated,

Editor: Zhenyong Zhang.

Received: August 23, 2014; revised: November 6, 2014; accepted: November 12, 2014.

From the Low Vision Research of Milan (PGL, CL), Milan; Department of Ophthalmology (EMV), A. Fiorini Hospital, Terracina; Polo Pontino (EMV); CenterVue (MUM), Padova; and Department of Sense Organs (MN), Faculty of Medicine and Odontology, Sapienza University of Rome, Rome, Italy.

Correspondence: Marcella Nebbioso, Department of Sense Organs, Ocular, Electrophysiology Center, Policlinico Umberto I, Sapienza University of Rome, V. le del Policlinico, 155, 00161 Rome, Italy (e-mail: marcella.nebbioso@uniroma1.it).

PGL, EMV, and CL have contributed to the conception and design of the research. MUM and MN have contributed to the analysis and interpretation of the data.

The authors have no funding to disclose.

The authors have no proprietary interest in any materials or methods described within this article. This submission has not been published anywhere previously, and it is not simultaneously being considered for any other publication. All figures submitted are owned solely by the authors.

Copyright © 2014 Wolters Kluwer Health, Inc. All rights reserved.

This is an open access article distributed under the Creative Commons Attribution License 4.0, which permits unrestricted use, distribution, and reproduction in any medium, provided the original work is properly cited. ISSN: 0025-7974

DOI: 10.1097/MD.0000000000000355

degenerative disease and apoptotic processes linked to it resume their destructive action against the retina.

Other useful autologous sources are derivable from platelet-rich plasma (PRP) and adipose-derived stem cells (ADSCs) included in stromal vascular fractions (SVF) of adipose tissue.^{23–27}

These elements, surgically grafted into suprachoroidal space, might delay retinal cell apoptosis through an almost pharmacological modulation of their secretions.^{23–27}

Trophic effects of growth factors on retina are shown by the histological examination in guinea pig, considering the nuclear layer thickness of photoreceptors compared with untreated eye.

Therefore, clinical study is not possible on retina in humans. Moreover, human pathological variables are much more complex than those encountered in genetically modified animal models and treated under standard conditions.^{5,28}

Moreover, similarly to the method of assessment used in animal models, we can use the electrophysiological testing also in the study of human retinal degeneration.^{29,30} In fact, these are noninvasive, objective, and reproducible examinations.

Schematically, for this study, we have divided the electroretinogram (ERG) into

1. scotopic rod-ERG that records the electrical response of the rods in the extrafoveal retinal areas;
2. scotopic maximal rod-cone-ERG that records the electrical response of the rods and cones of the entire retina;
3. photopic cone-ERG that records the electrical response of the cones in the foveal retinal area.

It represents a perfect indicator of cell viability, characterizes the quality of the cell electrical responses, and documents therapeutic effects during medical or surgical therapies.^{31–34}

The aim of this work was to demonstrate, through the objectivity of the assessment electrofunctional test, a possible therapeutic effect of the joined suprachoroidal graft of adipocytes, ADSCs in SVF, and PRP, which, according to the cited literature, are able to produce growth factors.^{14–17,23–27} These factors, pouring in choroidal blood flow, could reach the retinal cells that are on the opposite side of the choroid, interacting directly with photoreceptors through their membrane receptors or indirectly through the interaction with other cells such as retinal pigment epithelial cells (RPEs), Müller cells, and endothelial cells.

PATIENTS AND METHODS

The study protocol was approved by the *Ethical Committee*, Low Vision Research of Milan, and in accordance with Helsinki Declaration, written consent was obtained from all the patients.³⁵

For this purpose, we have included in the study, 12 eyes of 12 patients affected from dry age-related macular degeneration (AMD). They were identified and enrolled according to several characteristics. The inclusion criteria were as follows:

1. participants of whites classified as well-nourished;
2. AMD diagnosis with spectral domain optical coherence tomography (SD-OCT), fundus autofluorescence imaging, and fluorescein angiography in the presence of drusen and irregularities of RPEs in at least 1 eye;
3. good storage extrafoveal areas;
4. measurable visual acuity;
5. normal intraocular pressure;

6. acceptance of the clinical protocol by signing the informed consent.

The exclusion criteria from the study for possible cross-related interference with the test were as follows:

1. patients with signs of exudative AMD;
2. myopia with spherical equivalent >6 diopters;
3. cataract, chorioretinal disorders, such as macular pucker or neovascular membrane-associated and other ocular disorders (glaucoma, optic neuritis, ocular trauma, high refractive errors, etc.);
4. insufficient compliance in individuals affected by medical problems, such as hypovitaminoses, multiple sclerosis, epilepsy, Parkinson disease, diabetes, hypertension, vasculitis, renal and hepatic diseases, gastrointestinal malabsorption, hypothyroidism, malignant neoplasias, and other systemic chronic diseases.

For each patient, the diagnosis was confirmed by confocal scanning laser ophthalmoscope Nidek F10 (Nidek Inc, Fremont, CA), SD-OCT Cirrus (Carl Zeiss Meditec AG, Jena, Germany), and microperimetry Maia 100809 (CenterVue S.p.A., Padova, Italy) or standard automated perimetry Octopus 900 (Haag-Streit AG, Koeniz, Switzerland).

Before the graft (T0), for each patient we evaluated best corrected visual acuity (BCVA) for far and near distance. BCVA was measured with early treatment diabetic retinopathy study charts at 4 m in logarithm of the minimum angle of resolution (logMAR) and visual acuity for near vision (close-up) in points (Pts). Therefore, we recorded the electrical cell activity through ERG (electromedical system of ocular electrophysiology, Retimax; C.S.O. Srl, Scandicci, Italy) according to the standards set in 2009 by the International Society for Clinical Electrophysiology of Vision.³⁰

Each eye received a cell in graft between choroid and sclera called for convenience Limoli retinal restoration technique (LRRT), which is a variant of the intervention of Pelaez,¹⁹ who used a transplantation of autologous fat in subsclear space, obtaining interesting but transient results.^{21–27}

In the LRRT variant, the following changes have been made with the purpose of increasing the survival of autologous fat graft,^{36–38} triggering the proliferation of ADSCs to promote the growth of choroidal perfusion, and obtaining a more complete modulation of the action of the factors secreted by the fat only.^{39,25–27}

1. The distance between grafted autologous cells and choroid has been reduced by means of deep sclerectomy favoring the paracrine secretion of the autologous cells into the choroidal flow.
2. For the same reason, the area of contact between stalk and choroid has been expanded.
3. Suprachoroidal pocket has been built to accommodate the graft and saturated with a mixture of ADSCs and SVF obtained, according to the technique by Coleman et al³⁶ and Lawrence et al.³⁷
4. Adipose pedicle has been infiltrated with PRP gel obtained by centrifugation of the blood material, separation of the component, and its platelet degranulation.^{23,24}

The details are as follows:

1. A deep scleral door of about 5 × 5 mm has been opened by a radial zip in the inferotemporal quadrant to 8 mm from the

limbus. The sclerectomy must be deep enough to allow viewing of the slate color of the choroid.

2. Orbital fat is extracted from a gap above the inferior oblique muscle. The pedicle fat extracted must be sufficient to ensure the survival of vascular scaffold after its location.
3. The flap of autologous fat is laid gently on the bed and secured with choroidal vicryl 6/0 at the proximal edge of the door.
4. The scleral flap is then secured in order to avoid compression on the fat pedicle or on its nutrient vessels.
5. The remaining space between autologous fat graft, choroid, and scleral flaps are saturated with 0.5 cc. of SVF, previously prepared, full of ADSCs by venflon inserted into the scleral pocket.
6. Then, the stroma of the peduncle is infiltrated with 1 cc. of PRP using 25-gauge cannula.

Therefore, an autograft consisting of fat cells, ADSCs from SVF, and PRP has been realized.

A month after the LRRT (T30), we evaluated visual acuity and recorded cellular responses by scotopic, mesopic, and photopic ERG.

Statistical Analysis

Data were entered into an Access database and then analyzed with R. After internal consistency checks, statistical analyses and data visualization were performed before and after surgery LRRT. In order to test if the differences pre- and post-treatment were significant, the Wilcoxon signed-rank test has been performed. The test is well suited when the differences

between paired samples are not supposed to be normally distributed, as in this case. Then, the values of visual acuity, scotopic-ERG, and photopic-ERG were considered at the various stages of analysis, and the null hypothesis that there was no significant treatment effect was rejected if $P < 0.05$ or $P < 0.1$.

RESULTS

We have included in the study, 12 eyes (7 right and 5 left eyes) of 12 patients (6 men and 6 women) with dry AMD, belonging to patients aged 71.25 years, between 62 and 80 years ($SD \pm 6.8$).

The characteristics of the ocular functionality in surgery patients (Fig. 1) and the average values recorded before (T0) and after (T30) 30 days of autograft cells by variant second Limoli are shown in Tables 1 and 2. In any case, we reported adverse effects, and this highlights the nondangerousness of the procedure. Mean values recorded before (T0) and after (T30) surgery of the intraocular pressure were not changed significantly.

The results after surgery with LRRT indicated the following:

1. electrofunctional response from the scotopic rod-ERG (Fig. 2, left panel) has increased from 41.26 to 60.83 μV with an average increase of 47.44%, significant at 5% level ($P < 0.05$);
2. electrofunctional response from the whole retina, scotopic maximal rod-cone-ERG (Fig. 2, central panel), has increased from 112.22 to 129.68 μV with an average increase of 15.56%, moderately significant at 10% level ($P < 0.1$);

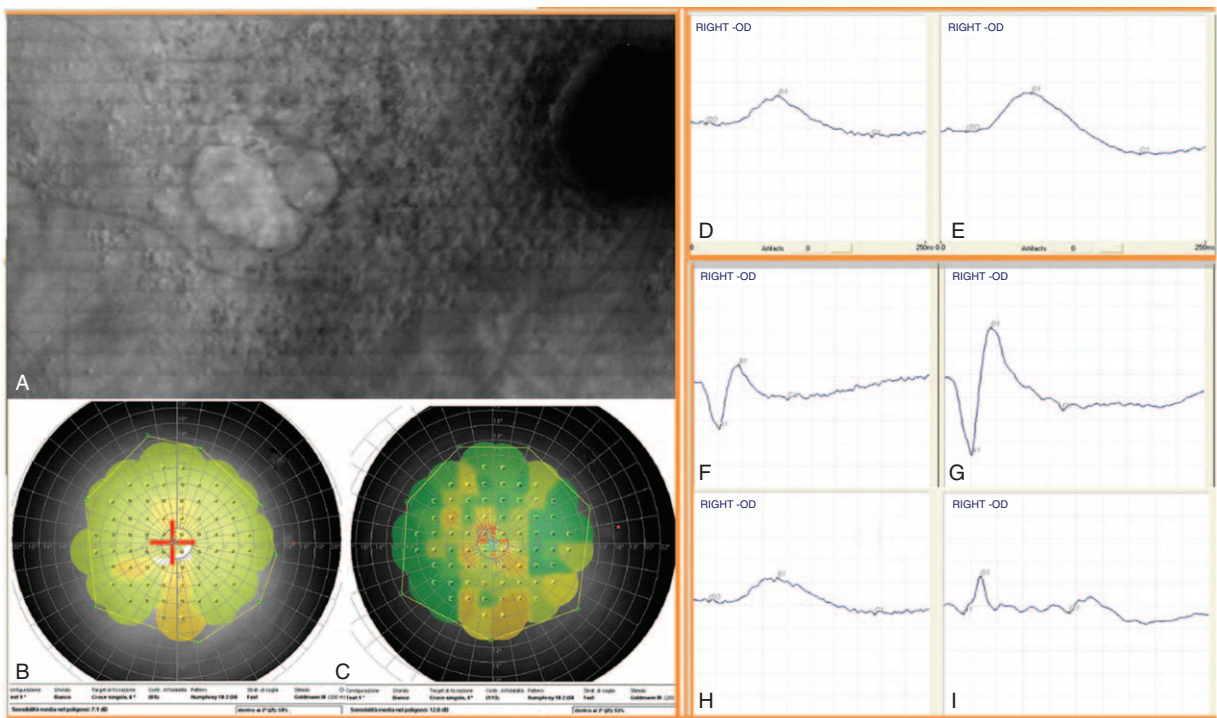


FIGURE 1. Panel (A) Patient affected from dry AMD. Panel (B–C) Microperimetric (increased from 7.1 to 12 dB) and ERG changes before and after 30 days of autograft cells by variant second Limoli. Scotopic rod-ERG (D–E); scotopic maximal rod-cone-ERG (F–G); photopic cone-ERG (H–I). AMD = age-related macular degeneration. ERG = electroretinogram.

TABLE 1. Mean Values Recorded Before (T0) and After (T30) Surgery With LRRT

Parameter	BCVA		Close-up V		Rod-ERG		Maximal-ERG		Photopic-ERG	
	T0	T30	T0	T30	T0	T30	T0	T30	T0	T30
Average	0.78	0.78	29.5	28.42	41.26	60.83	112.22	129.68	41.61	47.03
Max	1.70	1.70	70	70	74.57	91.75	210.35	179.78	69.90	113.75
Min	0.30	0.30	10	7	8.28	22.22	67.42	96.35	11.67	19.65
SD (±)	0.45	0.44	21.7	20.46	20.95	22.98	47.52	30.41	19.3	25.04

BCVA = best corrected visual acuity for far distance measured with ETDRS charts at 4 m in logMAR, Close-up V = visual acuity for near vision in Pts, ERG = electroretinogram amplitude in microvolts, ETDRS = early treatment diabetic retinopathy study, logMAR = logarithm of the minimum angle of resolution, LRRT = Limoli retinal restoration technique, Maximal-ERG = scotopic rod-cone-ERG, Photopic-ERG = cone-ERG, Pts = points, Rod-ERG = scotopic rod-ERG, SD = standard deviation.

TABLE 2. Mean Changes Pre- and Post-treatment and Statistical Significance of the Differences With Percentage Change of the Mean Values

Evaluation	Mean Changes	Percentage	P Value
BCVA	-0.004	-0.47	0.5539
Close-up V	-1.08	-3.67	0.7674
Scotopic rod-ERG	19.57	47.44	0.0299**
Maximal rod-cone-ERG	17.46	15.56	0.1047*
Photopic cone-ERG	5.41	13	0.5706

The Wilcoxon signed-rank test has been performed. BCVA = best corrected visual acuity for far distance in logMAR, Close-up V = visual acuity for near vision in Pts, ERG = electroretinogram (amplitude in microvolts), logMAR = logarithm of the minimum angle of resolution., Pts = points.
 *Statistical significance of scotopic maximal rod-cone-ERG ($P < 0.1$).
 **Higher statistical significance of scotopic rod-ERG ($P < 0.05$)

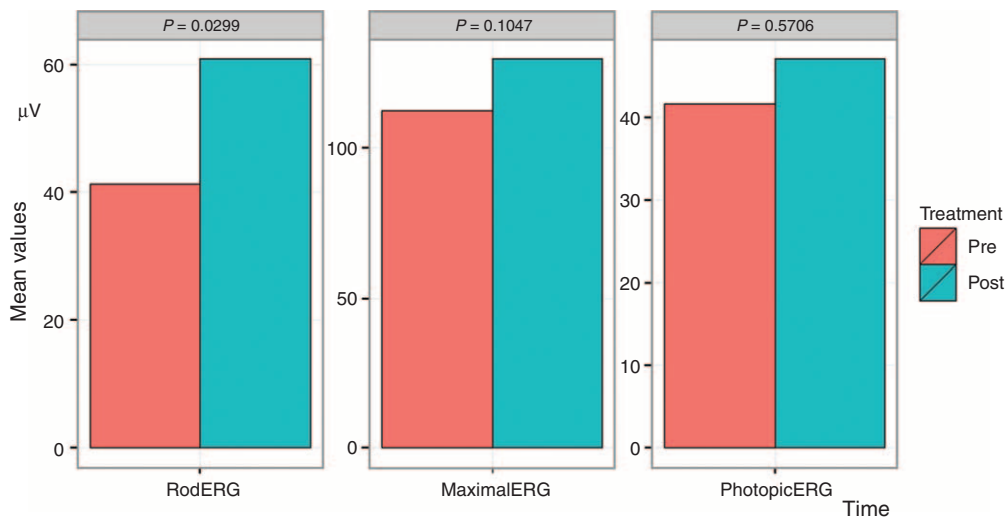


FIGURE 2. Electroretinographic changes. ERG before and after surgery with LRRT. Left Panel. Scotopic rod-ERG has increased from 41.26 to 60.83 µV with an average increase of 47.44%, significant at 5% level ($P < 0.05$). Central Panel. Scotopic maximal rod-cone-ERG has increased from 112.22 to 129.68 µV with an average increase of 15.56%, moderately significant at 10% level ($P < 0.1$). Right Panel. Photopic cone-ERG has increased from 41.61 to 47.03 µV with an average increase of 13%, not significant. ERG = electroretinogram, LRRT = Limoli retinal restoration technique.

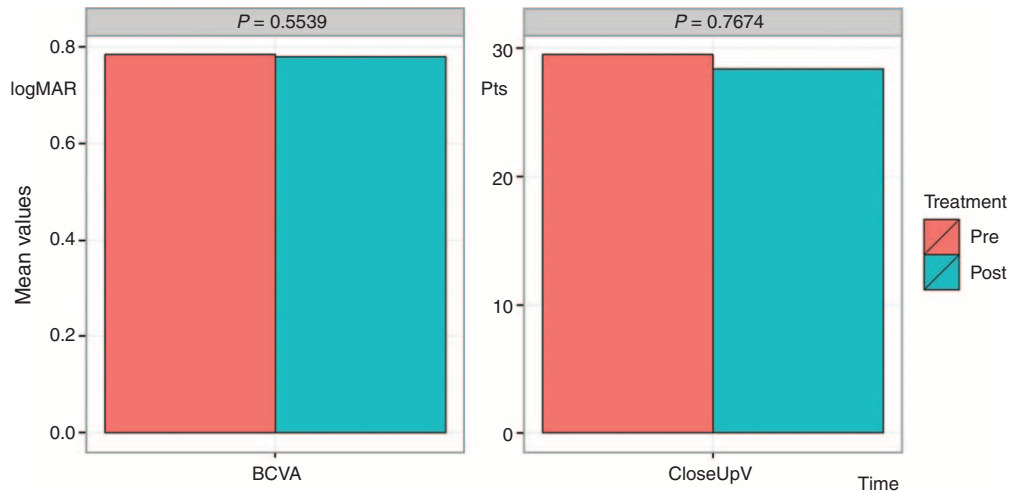


FIGURE 3. Visual acuity changes before and after surgery with LRRT were not statistically significant. Left Panel. BCVA for far distance in logMAR. Right Panel. Visual acuity for near in Pts. BCVA = best corrected visual acuity, logMAR = logarithm of the minimum angle of resolution, LRRT = Limoli retinal restoration technique, Pts = points.

3. electrofunctional answer coming from the photopic cone-ERG (Fig. 2, right panel) has increased from 41.61 to 47.03 μ V with an average increase of 13%, not significant ($P > 0.05$);
4. 0.78 logMAR BCVA remains practically unchanged, therefore, with no significant change (Fig. 3, left panel);
5. Close-up has gone up from 29.5 to 28.42 Pts with variation of 3.67%, not statistically significant (Fig. 3, right panel).

DISCUSSION

Therefore, the LRRT purpose, that is, the graft joint suprachoroidal adipose pedicle, of ADSCs in SVF, and intrapuduncular PRP, was as follows:

1. promote the vascular pedicle fat engraftment with the underlying choroid;
2. enhance the pedicle fat original vascularization, in order to ensure its volume and survival;
3. give a regenerative start-up to all the retinal elements, through the secretion of paracrine growth factors.

As it is well known, the dry AMD shows a damage starting from foveal area, populated by cones, which typically has a reduced cellularity.

Extrafoveal areas, mainly populated by rods, typically appear better preserved.

Scotopic ERG is an outer retina function, so an increase of it implies an improvement in the ability to respond to stimulation by the photoreceptors.

LRRT (grafting of mature fat cells and ADSCs in SVF enriched with PRP) seems to have a positive effect on the increase in the various ERG values. This effect may be exercised due to the paracrine secretion properties of these cells, we hypothesize, including growth factors.

Consequently, retinal electrofunctional tests, that record full-field ERG responses, show different results after 30 days from the LRRT surgery technique. Unfortunately, in this pilot study, it was not possible to show data of the multifocal ERG,

that records electrical responses from the different areas of the retina, because some patients had poor central fixation lack. Analogous difficulty was obtained for statistical analysis by microperimetry Maia and standard perimetry Octopus.

However, the most significant increase is recorded by scotopic ERG, whereas the less significant is the one recorded by photopic-ERG. The position of the graft near the choroid could allow at the product factors to flow into the choroidal flow, to reach receptors of endothelial cells, RPEs, Müller cells, photoreceptors, and potentially to interact with them. So, the mechanism of this effect may be due to the growth factors' action on trophic photoreceptors introduced at the level of the retinal choriocapillaris through its contact with cell autologous graft. The foveal damage, mainly in the dry AMD, and the resulting reduced presence of cones at this level would explain the less significant increase of photopic ERG. Conversely, the best preservation of extrafoveal areas, and the consequent increased presence of rods in those areas, would explain the most significant increase of the scotopic ERG recorded response. In fact, growth factors need still viable cells, which possess the corresponding membrane receptors.

Following the complex growth factor receptor formation, a limited number of second messengers are generated within the cell target. These in turn control a series of biochemical pathways within the cell, by regulating the enzyme activity and transcription factors, through a series of cascade of phosphorylation events.⁴⁰⁻⁴⁴ These signals, arrived in the nucleus of the cell, determine changes in the response of genes, increasing proteins, enzymes, and cytokine transcription that play their role in cell trophic control.⁴⁰⁻⁴⁴

The main function of growth factors is the external control of the cell cycle, by the cell quiescence abandonment (G0 phase) and the cell entry in the G1 phase (growth). However, this is not their only function; they can regulate the entry into mitosis, cell survival, migration, and cell differentiation.^{40,41}

The LRRT allows the grafting of 3 autologous components and each of the grafted elements has its own specific assets in growth factors useful from a point of view regenerative:

1. Fat cells, contained in the pedicle placed in the suprachoroidal space, produce basic fibroblast growth

- factor (bFGF), epidermal growth factor (EGF), insulin-like growth factor-1 (IGF-1), interleukin (IL), transforming growth factor- β (TGF- β), pigment-epithelium-derived factor (PEDF), and adiponectin.^{14–17}
- The ADSCs produce bFGF, vascular endothelial growth factor (VEGF), macrophage colony-stimulating factor (M-CSF), granulocyte-macrophage colony-stimulating factor (GM-CSF), placental growth factor (PIGF), TGF- β , hepatocyte growth factor, IGF-1, IL, and angiogenin.^{25–27,44}
 - Platelets produce platelet-derived growth factor (PDGF), IGF-1, TGF- β , VEGF, bFGF, EGF, platelet-derived angiogenesis factor (PDAF), and thrombospondin (TSP).^{23,24}

Some factors, such as VEGF, bFGF, angiogenin, PDAF, PIGF, PDGF, EGF, and TGF- β , promote endothelial regeneration and may contribute to the choriocapillaris reperfusion.^{42,43,45} VEGF introduced with the PRP stimulates ADSCs proliferation that in turn promote both the autologous fat and adipocytes survival.^{38,39,42}

Others, such as the TSP and the PEDF inhibit neovascular processes;^{46–48} bFGF acts directly on the photoreceptor, binding to the surface receptors and promotes their survival.^{46–48,10,49} The PEDF similarly to bFGF has neurotrophic activity in respect of the photoreceptors.⁵⁰

Some factors, however, as the EGF, act on Müller cells inducing endogenous bFGF transcription and strengthen the protective action of these cells toward the retina nerve cells.^{51–53} EGF also stimulates the ADSCs to increase its secretory activity.⁵⁴

Furthermore, bFGF, IGF-1, PEDF, PDGF, TGF- β , and VEGF are normally secreted by RPEs, which in the presence of maculopathy to atrophic evolution are pathologically deficient for the involution of RPEs/choriocapillaris system. Their paracrine secretion by cell graft helps to promote the photoreceptor and choriocapillaris survival.^{55–59}

Moreover, M-CSF, GM-CSF, and IL have an anti-inflammatory component and a chemotactic one toward macrophages that contribute to remove cell intraretinal debris and function normally carried out by RPEs.^{60–63} Also from an experimental point of view, increases in the number of macrophages have been observed after intravitreal injection of bFGF.^{11,44}

From the results of our study, with LRRT technique it seems possible to achieve, directly and indirectly, an increase in choroidal perfusion and a greater tropism of the photoreceptors through bFGF–receptor interactions and stimulation mediated by Müller cells, RPEs, and retinal photoreceptors. Successively, these events would allow a growth of the cellular activity to facilitate appropriate potentials of action.

It is possible affirm that an improved cell trophism translates into an electrical activity increase of the cell, which can be measured objectively through the classic electrofunctional testing as evidenced in our results. In the near future, we will continue the researches by the enrollment of the largest number subjects with more visual acuity and central fixed, through the statistical valuation of all the indispensable examinations to confirm technique validity and study of biochemical effects.

CONCLUSION

From a clinical point of view, cell-mediated therapy based on the use of growth factors appears interesting because they can improve the electrical cell responses in the short term. The

ERG could, therefore, be used to monitor in an objective manner in humans, similar to the guinea pigs, the effect of regenerative cellular-mediated therapies, including autologous fat orbital joint to cells derived from ADSCs in adipose tissue SVF and PRP (LRRT). It is possible to assume a greater effect even at foveal level provided that it is applied early, such as to allow a broader cytokine–receptor interaction, when most of the photoreceptors are still present. Therefore, we have to take into account that the cell-mediated administration of growth factors can be realized by using a scleral surgery.

In summary, it seems essential in the future to investigate the long-term effectiveness of this therapy, the cost-benefit ratio of the intervention, the best time of intervention, and the real security for the future visual acuity of our patients.

ACKNOWLEDGMENTS

We are grateful to Profs Pierpaolo D'Urso and Riccardo Massari, Sapienza University of Rome, for their help in supervising and guiding in statistical analysis.

REFERENCES

- Zhang K, Hopkins JJ, Heier JS, et al. Ciliary neurotrophic factor delivered by encapsulated cell intraocular implants for treatment of geographic atrophy in age-related macular degeneration. *Proc Natl Acad Sci U S A*. 2011;108:6241–6245.
- Okoye G, Zimmer J, Sung J, et al. Increased expression of brain-derived neurotrophic factor preserves retinal function and slows cell death from rhodopsin mutation or oxidative damage. *J Neuroscience*. 2003;23:4164–4172.
- Cham E. Retinal neuroprotection by growth factors: a mechanistic perspective. *J Cellular Biochem*. 2003;88:57–75.
- Thanos C, Emerich D. Delivery of neurotrophic factors and therapeutic proteins for retinal diseases. *Expert Opin Biol Ther*. 2005;5:1443–1452.
- Sakai T, Kuno N, Takamatsu F, et al. Prolonged protective effect of basic fibroblast growth factor-impregnated nanoparticles in royal college of surgeons rats. *Invest Ophthalmol Vis Sci*. 2007;48:3381–3387.
- Wen R, Song Y, Liu Y, et al. CNTF negatively regulates the phototransduction machinery in rod photoreceptors: implication for light-induced photostasis plasticity. *Adv Exp Med Biol*. 2008;613:407–413.
- Vergara NM, Del Rio-Tsonis K. Retinal regeneration in the *Xenopus laevis* tadpole: a new model system. *Mol Vis*. 2009;15:1000–1013.
- Daftarian N, Kiani S, Zahabi A. Regenerative therapy for retinal disorders. *J Ophthalmic Vis Res*. 2010;5:250–264.
- Wen R, Tao W, Luo L, et al. Regeneration of cone outer segments induced by CNTF. *Adv Exp Med Biol*. 2012;723:93–99.
- LaVail MM, Faktorovich EG, Hepler JM, et al. Basic fibroblast growth factor protects photoreceptors from light-induced degeneration in albino rats. *Ann N Y Acad Sci*. 1991;638:341–347.
- La Vail MM, Unok K, Yasumura D, et al. Multiple growth factors, cytokines, and neurotrophins rescue photoreceptors from the damaging effects of constant light. *Proc Natl Acad Sci USA*. 1992;89:11249–11253.
- Sampat KM, Garg SJ. Complications of intravitreal injections. *Curr Opin Ophthalmol*. 2010;21:178–183.
- Levine JP, Marcus I, Sorensen JA, et al. Macular hemorrhage in neovascular age-related macular degeneration after stabilization with antiangiogenic therapy. *Retina*. 2009;29:1074–1079.

14. Wang P, Mariman E, Renes J, et al. The secretory function of adipocytes in the physiology of white adipose tissue. *J Cell Physiol.* 2008;216:3–13.
15. Trayhurn P, Beattie JH. Physiological role of adipose tissue: white adipose tissue as an endocrine and secretory organ. *Proc Nutr Soc.* 2001;60:329–339.
16. Scherer PE. Adipose tissue: from lipid storage compartment to endocrine organ. *Diabetes.* 2006;55:1537–1545.
17. Tilg H, Moschen A. Adipocytokines: mediators linking adipose tissue, inflammation and immunity. *Nature Rev Immunol.* 2006;6:772–783.
18. Filatov VP. Tissue therapy. *Med Gen Fr.* 1951;11:3–5.
19. Pelaez O. Retinitis pigmentosa. Cuban experience. Editorial Científico Técnica. La Habana, 1997.
20. Meduri R, Scorolli L, Morara M, et al. Effect of basic fibroblast growth factor on the retinal degeneration of B6(A)-Rperd12/J (retinitis pigmentosa) mouse: a morphologic and ultrastructure study. ARVO 2007 Annual Meeting, Fort Lauderdale, May 6–10, 2007.
21. Limoli PG, Carpi R, Tassi, et al. Adipocytes subcleral implant. Growth factors may be considered a new therapy of atrophic retinal pathology? *Invest Ophthalmol Vis Sci.* 2011;52:437ARVO Meeting.
22. Limoli PG, Carpi R, Tassi, et al. Prognostic standard in growth factors therapy. *Invest Ophthalmol Vis Sci.* 2012;53:277ARVO Meeting.
23. Tischler M. Platelet rich plasma: the use of autologous growth factors to enhance bone and soft tissue grafts. *N Y State Dent J.* 2002;68:22.
24. Kevy SV, Jacobson MS, Blasetti L, et al. Preparation of growth factor enriched autologous platelet gel. Transactions of the Society for Biomaterials 27th Annual Meeting, St. Paul, Minnesota, USA. April 24–29, 2001.
25. Nakagami H, Morishita R, Maeda K, et al. Adipose tissue-derived stromal cells as a novel option for regenerative cell therapy. *J Atheroscler Thromb.* 2006;13:77–81.
26. Schaffler A, Buchler C. Concise review: adipose tissue-derived stromal cells-basic and clinical implications for novel cell-based therapies. *Stem Cells.* 2007;25:818–882.
27. Prunet-Marcassus B, Cousin B, Caton D, et al. From heterogeneity to plasticity in adipose tissues: site-specific differences. *Exp Cell Res.* 2006;312:727–736.
28. Mao H, James T Jr, Schwein A, et al. AAV delivery of wild-type rhodopsin preserves retinal function in a mouse model of autosomal dominant retinitis pigmentosa. *Hum Gene Ther.* 2011;22:567–575.
29. Gerth C. The role of the ERG in the diagnosis and treatment of age-related macular degeneration. *Doc Ophthalmol.* 2009;118:63–68.
30. Marmor MF, Fulton AB, Holder GE, et al. Standard for clinical electroretinography (2008 update). *Doc Ophthalmol.* 2009;118:69–77.
31. Skaat A, Solomon A, Moroz I, et al. Increased electroretinogram a-wave amplitude after intravitreal bevacizumab injection for neovascular age-related macular degeneration. *Acta Ophthalmol.* 2011;89:e269–e273.
32. Mackay AM, Brown MC, Hagan RP, et al. Deficits in the electroretinogram in neovascular age-related macular degeneration and changes during photodynamic therapy. *Doc Ophthalmol.* 2007;115:69–76.
33. Maturi RK, Bleau LA, Wilson DL. Electrophysiologic findings after intravitreal bevacizumab (Avastin) treatment. *Retina.* 2006;26:270–274.
34. Nebbioso M, Livani ML, Steigerwald RD, et al. Retina in rheumatic diseases: standard full field and multifocal electroretinography in hydroxychloroquine retinal dysfunction. *Clin Exp Optim.* 2010;94:276–283.
35. Werko L. Ethics committees bear a responsibility for patient information. Informed consent implies that the patient understands what he has consented to. *Lakartidningen.* 2002;99:1552–1555.
36. Coleman WP, Glogau RG, Klein JA, et al. Guidelines of care for liposuction. *J Am Acad Dermatol.* 2001;45:438–447.
37. Lawrence N, Coleman WP. Liposuction. *J Am Acad Dermatol.* 2002;47:105–108.
38. Luo S, Hao L, Li X, et al. Adipose tissue-derived stem cells treated with estradiol enhance survival of autologous fat transplants. *Tohoku J Exp Med.* 2013;231:101–110.
39. Chen G, Shi X, Sun C, et al. VEGF-mediated proliferation of human adipose tissue-derived stem cells. *PLoS One.* 2013;8:e73673.
40. Finklestein SP, Plomaritoglou A. Growth factors. In Miller LP, Hayes RL, eds. *Newcomb JK, co-editor. Head Trauma: Basic, Preclinical, and Clinical Directions.* New York: Wiley; 2001:165–187.
41. Limoli P. The retinal cell-neuroregeneration. Principles, applications and perspectives. The growth factors [Italian]. FGE Reg. San Giovanni 40, Canelli (AT). Ed. 2014, 159–206.
42. Bagchi M, Kim LA, Boucher J, et al. Vascular endothelial growth factor is important for brown adipose tissue development and maintenance. *FASEB J.* 2013;27:3257–3271.
43. Khurana R, Moons L, Shafi S, et al. Placental growth factor promotes atherosclerotic intimal thickening and macrophage accumulation. *Circulation.* 2005;111:2828–2836.
44. Sansone L, Reali V, Pellegrini L, et al. SIRT1 inhibition confers neuroresistance in vitro through IGF-1 pathway activation. *J Cell Physiol.* 2013;228:1754–1761.
45. Schreiber AB, Winkler ME, Derynck R. Transforming growth factor-alpha: a more potent angiogenic mediator than epidermal growth factor. *Science.* 1986;232:1250–1253.
46. Sheibani N, Sorenson CM, Cornelius LA, et al. Thrombospondin-1, a natural inhibitor of angiogenesis, is present in vitreous and aqueous humor and is modulated by hyperglycemia. *Biochem Biophys Res Commun.* 2000;267:257–261.
47. Carron JA, Hiscott P, Hagan S, et al. Cultured human retinal pigment epithelial cells differentially express thrombospondin-1, -2, -3, and -4. *Int J Biochem Cell Biol.* 2000;32:1137–1142.
48. Dawson DW, Volpert OV, Gillis P, et al. Pigment epithelium-derived factor: a potent inhibitor of angiogenesis. *Science.* 1999;285:245–248.
49. Sakaguchi DS, Janick LM, Reh TA. Basic fibroblast growth factor (FGF-2) induced transdifferentiation of retinal pigment epithelium: generation of retinal neurons and glia. *Dev Dyn.* 1997;209:387–398.
50. Kim SY, Mocanu C, McLeod DS, et al. Expression of pigment epithelium-derived factor (PEDF) and vascular endothelial growth factor (VEGF) in sickle cell retina and choroid. *Exp Eye Res.* 2003;77:433–445.
51. Ueki Y, Reh TA. EGF stimulates Müller glial proliferation via a BMP-dependent mechanism. *Glia.* 2013;61:778–789.
52. Hauck SM, Kinkl N, Deeg CA, et al. GDNF family ligands trigger paracrine neuroprotective signalling in retinal glial cells. *Cell Biol.* 2006;26:2746–2757.
53. Zack DJ. Neurotrophic rescue of photoreceptors: are Müller cells the mediators of survival? *Neuron.* 2000;26:285–286.
54. Li Q, Li PH, Hou DJ, et al. EGF enhances ADSCs secretion via ERK and JNK pathways. *Cell Biochem Biophys.* 2014;69:189–196.

55. Kozlowski MR. RPE cell senescence: a key contributor to age-related macular degeneration. *Elsevier Med Hypotheses*. 2012;78:505–510.
56. Bhutto I, Luttu G. Understanding age-related macular degeneration (AMD): relationships between the photoreceptor/retinal pigment epithelium/Bruch's membrane/choriocapillaris complex. *Mol Aspects Med*. 2012;33:295–317.
57. Campochiaro PA, Hackett SF, Viores SA, et al. Platelet-derived growth factor is an autocrine growth stimulator in retinal pigmented epithelial cells. *J Cell Sci*. 1994;107:2459–2469.
58. Slomiany MG, Rosenzweig SA. Autocrine effects of IGF-I-induced VEGF and IGFBP-3 secretion in retinal pigment epithelial cell line ARPE-19. *Am J Physiol Cell Physiol*. 2004;287:C746–753.
59. Tanihara H, Yoshida M, Matsumoto M, et al. Identification of transforming growth factor-beta expressed in cultured human retinal pigment epithelial cells. *Invest Ophthalmol Vis Sci*. 1993;34:413–419.
60. Nemunaitis J. Macrophage function activating cytokines: potential clinical application. *Crit Rev Oncol Hematol*. 1993;14:153–171.
61. Schneider A, Krüger C, Steigleder T, et al. The hematopoietic factor G-CSF is a neuronal ligand that counteracts programmed cell death and drives neurogenesis. *J Clin Invest*. 2005;115:2083–2098.
62. Dinarello CA. The IL-1 family and inflammatory diseases. *Clin Exp Rheumatol*. 2002;20 (S27):S1–S13.
63. Yin Y, Henzl MT, Lorber B, et al. Oncomodulin is a macrophage-derived signal for axon regeneration in retinal ganglion cells. *Nat Neurosci*. 2006;9:843–852.