

Sudden Cardiac Death in the Young: A Consensus Statement on Recommended Practices for Cardiac Examination by the Pathologist from the Society for Cardiovascular Pathology

Karen L. Kelly , Peter T. Lin , Cristina Basso , Melanie Bois , L. Maximilian Buja , Stephen D. Cohle , Giulia d'Amati , Emily Duncanson , John T. Fallon , Dennis Firchau , Gregory Fishbein , Carla Giordano , Charles Leduc , Silvio H. Litovsky , Shannon Mackey-Bojack , Joseph J. Maleszewski , Katarzyna Michaud , Robert F Padera , Stavroula A. Papadodima , Sarah Parsons , Stanley J Radio , Stefania Rizzo , Susan J. Roe , Maria Romero , Mary N. Sheppard , James R. Stone , Carmela D. Tan , Gaetano Thiene , Allard C. van der Wal , John P. Veinot

PII: S1054-8807(22)00090-4
DOI: <https://doi.org/10.1016/j.carpath.2022.107497>
Reference: CVP 107497

To appear in: *Cardiovascular Pathology*

Received date: 2 August 2022
Revised date: 3 November 2022
Accepted date: 4 November 2022

Please cite this article as: Karen L. Kelly , Peter T. Lin , Cristina Basso , Melanie Bois , L. Maximilian Buja , Stephen D. Cohle , Giulia d'Amati , Emily Duncanson , John T. Fallon , Dennis Firchau , Gregory Fishbein , Carla Giordano , Charles Leduc , Silvio H. Litovsky , Shannon Mackey-Bojack , Joseph J. Maleszewski , Katarzyna Michaud , Robert F Padera , Stavroula A. Papadodima , Sarah Parsons , Stanley J Radio , Stefania Rizzo , Susan J. Roe , Maria Romero , Mary N. Sheppard , James R. Stone , Carmela D. Tan , Gaetano Thiene , Allard C. van der Wal , John P. Veinot , Sudden Cardiac Death in the Young: A Consensus Statement on Recommended Practices for Cardiac Examination by the Pathologist from the Society for Cardiovascular Pathology, *Cardiovascular Pathology* (2022), doi: <https://doi.org/10.1016/j.carpath.2022.107497>

This is a PDF file of an article that has undergone enhancements after acceptance, such as the addition of a cover page and metadata, and formatting for readability, but it is not yet the definitive version of record. This version will undergo additional copyediting, typesetting and review before it is published in its final form, but we are providing this version to give early visibility of the article. Please note that, during the production process, errors may be discovered which could affect the content, and all legal disclaimers that apply to the journal pertain.

Highlights

- Sudden cardiac death in the young is often due to a genetically transmitted disease process.
- No consistent forensic pathology guidelines for cardiac examination in these cases.
- Collaboration of SCVP members and CV-trained, practicing forensic pathologists.
- These guidelines may result in life-saving medical intervention for family members.

Journal Pre-proof

Sudden Cardiac Death in the Young: A Consensus Statement on Recommended Practices for Cardiac Examination by Pathologists from the Society for Cardiovascular Pathology

Karen L. Kelly^a, Peter T. Lin^b, Cristina Basso^c, Melanie Bois^b, L. Maximilian Buja^d, Stephen D. Cohle^e, Giulia d'Amati^f, Emily Duncanson^g, John T. Fallon^a, Dennis Firchau^h, Gregory Fishbein^j, Carla Giordano^f, Charles Leduc^j, Silvio H. Litovsky^k, Shannon Mackey-Bojack^g, Joseph J. Maleszewski^b, Katarzyna Michaud^l, Robert F Padera^m, Stavroula A. Papadodimaⁿ, Sarah Parsons^o, Stanley J Radio^p, Stefania Rizzo^c, Susan J. Roe^q, Maria Romero^r, Mary N. Sheppard^s, James R. Stone^t, Carmela D. Tan^u, Gaetano Thiene^c, Allard C. van der Wal^v, John P. Veinot^w

^aEast Carolina University, Greenville, NC, USA

^bMayo Clinic, Rochester, MN, USA

^cUniversity of Padua, Padua, Italy

^dTexas Medical Center, Houston, TX

^eGrand Rapids, MI, USA

^fSapienza, University of Rome, Rome, Italy

^gJesse E. Edwards Registry of Cardiovascular Disease, St. Paul, MN, USA

^hUniversity of Iowa, Iowa City, IA, USA

ⁱDavid Geffen School of Medicine at UCLA, Los Angeles, CA, USA

^jUniversity of Montreal, Montreal, Quebec, Canada

^kUniversity of Alabama at Birmingham, Birmingham, AL, USA

^lUniversity of Lausanne, Lausanne, Switzerland

^mBrigham and Women's Hospital, Boston, MA, USA

ⁿUniversity of Athens, Athens, Greece

^oVictorian Institute of Forensic Medicine, Melbourne, Australia

^p University of Nebraska, Omaha, NE, USA

^q University of North Dakota, Fargo, ND, USA

^r CVPPath Institute, Gaithersburg, MD, USA

^s St. George's Medical School, University of London, London, United Kingdom

^t Massachusetts General Hospital, Boston, MA, USA

^u Cleveland Clinic, Cleveland, OH, USA

^v University of Amsterdam, Amsterdam, the Netherlands

^w University of Ottawa, Ottawa, Ontario, Canada

Journal Pre-proof

Abstract

Sudden cardiac death is, by definition, an unexpected, untimely death caused by a cardiac condition in a person with known or unknown heart disease. This major international public health problem accounts for approximately 15-20% of all deaths. Typically more common in older adults with acquired heart disease, SCD also can occur in the young where the cause is more likely to be a genetically transmitted process. As these inherited disease processes can affect multiple family members, it is critical that these deaths are appropriately and thoroughly investigated. Across the United States, SCD cases in those less than 40 years of age will often fall under medical examiner/coroner jurisdiction resulting in scene investigation, review of available medical records and a complete autopsy including toxicological and histological studies. To date, there have not been consistent or uniform guidelines for cardiac examination in these cases. In addition, many medical examiner/coroner offices are understaffed and/or underfunded, both of which may hamper specialized examinations or studies (eg. molecular testing). Use of such guidelines by pathologists in cases of SCD in decedents aged 1 to 39 years of age could result in life-saving medical intervention for other family members. These recommendations also may provide support for underfunded offices to argue for the significance of this specialized testing. As cardiac examinations in the setting of SCD in the young fall under ME/C jurisdiction, this consensus paper has been developed with members of the Society of Cardiovascular Pathology working with cardiovascular pathology-trained, practicing forensic pathologists.

I. Introduction

By definition, sudden cardiac death (SCD) is an unexpected death that occurs rapidly due to a cardiac cause. Most studies define “sudden” death as a death that occurs within one hour after the onset of symptoms, within 24 hours of last being seen alive in unwitnessed cases or those resuscitated after cardiac arrest dying during the same hospital admission¹⁻⁴. Other sources classify “sudden death” as “dead upon arrival” to a hospital⁵. Regardless of the definition, sudden cardiac death (SCD) is a major international public health problem accounting for approximately 15-20% of all deaths⁶. Estimates for the incidence of SCD in the United States range from 250,000 to 400,000 adults dying suddenly each year due to cardiac causes with an overall incidence of 1-2/1000 population per year⁷. SCD occurs most commonly in older (>35 years) adults with acquired heart disease. Many of these patients have known cardiac history, and while their sudden death is sudden and unexpected, their underlying disease process provided the substrate for sudden death. These cases often do not require a medicolegal investigation by the medical examiner/coroner due to previous documentation of their underlying disease process, which will be reflected on the death certificate generally completed by their treating clinician.

While significant advances in treatment of cardiovascular diseases have led to a significant decrease in SCD in patients with atherosclerotic coronary heart disease, the numbers of sudden deaths in those <35 years of age has shown marginal reduction.⁸ In multiple studies, the incidence of sudden cardiac death in the young varies widely owing to different age ranges of the study populations. In young people <30 years, the overall risk of SCD is approximately 1-2.8/100,000^{9,10}. Approximately 19%

of sudden natural deaths in children between 1 and 13 years are cardiac in origin, whereas in the 14-21-year age range, 30% are cardiac¹¹. In up to 33% of SCD cases among children and adults, there is no specific cause of death identified after a comprehensive autopsy examination^{12,13}. A definitive cause of death could not be determined in up to 50% of cases of sudden cardiac death in women 35-44 years old despite thorough investigation.¹⁴ The results from both studies exclude genetic studies.

Non-cardiac conditions can also cause sudden death that may be difficult to distinguish from SCD (Table I). SCD in the young most often occurs without prior symptoms or documented medical history. SCD often underlies cases of unexplained drowning and deaths during seizures and night terrors. These deaths are most often referred to medical examiners/ coroners for determination of cause and manner of death. Due to their age and typical lack of medical history, this group of patients make up a considerable proportion of the forensic pathologist/coroners responsibilities. While there is no uniform definition of the word "young", this article will focus on SCD in decedents from 1 to 39 years old. This document will not discuss Sudden Infant Death Syndrome (SIDS) specifically, however it is our opinion that in cases of unexpected and sudden deaths in infants less than one year of age, the heart should undergo the same thorough evaluation as other cases of sudden death. The heart examination in this age group should include consideration of complex congenital heart malformations.

In Europe and Australia, specific guidelines have been published and adopted by forensic practitioners for investigation, autopsy, toxicology, histology, cardiovascular examination and tissue retention in cases of sudden death in the young. These publications include guidelines for autopsy investigation of sudden cardiac death from the Association for European Cardiovascular Pathology,¹⁵ guidelines on autopsy practice in sudden death in the young endorsed by the Royal College of Pathologists of Australia and the National Heart Foundation of New Zealand⁵ and the Swiss Principles and Rules for Medico-legal Autopsy¹⁶ which includes guidelines for preserving autopsy material.

To date, no specific guidelines for evaluation of sudden cardiac death in the young have been published in the United States. The National Association of Medical Examiners (NAME) released a 2013 position paper¹⁷ on retaining postmortem samples for genetic testing in such cases. Members of the Society for Cardiovascular Pathology (SCVP) working with cardiovascular pathology-trained, practicing forensic pathologists determined that guidelines for the evaluation of sudden death in the young cases could lead to increased consistency in these examinations and maximize the opportunity to make specific diagnoses to guide treatment and genetic testing in living family members. It would provide families with the knowledge that the medical examiner/coroner has done their due diligence to determine the cause of death. Determination of the presence of a genetically-transmitted disease process can lead to life-saving testing and procedures in other family members.

2. Methods

Consensus committee membership was solicited from members of the Society for Cardiovascular Pathology (SCVP). SCVP members who were also practicing forensic pathologists/medical examiners were personally solicited. This multi-institutional committee identified the crucial role that autopsy evaluation plays in cases of sudden cardiac death in the young. It also recognized that increased standardization would be beneficial as death investigation, autopsy procedures and cardiovascular examination are highly variable between jurisdictions, particularly within the United States. This group also recognized the increasing importance of postmortem genetic testing for hereditary cardiovascular disease and that specific guidance for ordering tests and interpreting and communicating the results was needed. The committee members reviewed the appropriate literature and constructed consensus guidelines for best practices in the medicolegal, autopsy and cardiovascular investigation of sudden death in the young.

For the purpose of this consensus document, hereditary cardiovascular disease is considered a cardiovascular disease whose primary etiology is thought to be genetically transmitted based on current knowledge, although environmental factors may certainly modulate or exacerbate the underlying disease. Examples of hereditary cardiovascular diseases include familial hypercholesterolemia, familial dilated cardiomyopathy, hypertrophic cardiomyopathy, arrhythmogenic cardiomyopathy (arrhythmogenic right ventricular cardiomyopathy/dysplasia), long QT syndrome and others. Acquired cardiovascular diseases that are known to have a heritable component of susceptibility, such as essential hypertension or atherosclerotic coronary artery disease, are not considered hereditary cardiovascular disease for the purpose of this consensus statement. Congenital heart disease causes up to 11% of sudden deaths in young people and should be considered in determining the cause of death. Due to the advancements in treatment of CHD, these patients are living into adulthood, with the adult population with CHD surpassing the number of children with CHD. As these patients age, their risk for SCD increases such that by the age of 50, these patients have a 10% risk for a cardiac arrhythmia and 4% experience sudden death. We will not discuss examination of operated or unoperated complex congenital heart disease in this paper.

The recommendations put forth here do not necessarily reflect the opinions of all members of the SCVP. Areas with significant dissent within the committee are indicated in the text.

3. Recommendations for Cardiac Examination in Sudden Cardiac Death in the Young

3.0 Medical Examiners/Coroners and Sudden Cardiac Death

Medical examiners and coroners (ME/Cs) are often those primarily responsible for investigating sudden unexpected deaths. Scene investigation, medical record review, autopsy, histological examination and postmortem ancillary studies, such as toxicology and genetic testing, are important

components of an investigation of sudden unexpected death in the young. Determination of the cause and manner of death may be the primary goal of a forensic death investigation, but it is not the only goal.⁹⁹ The discovery of an inherited disease in the decedent may have clinical relevance for surviving family members and it is the responsibility of the ME/C to assess for and communicate this risk. This is particularly relevant for SCDs in the young where hereditary arrhythmia, cardiomyopathy, and aortopathy syndromes are frequently diagnosed at the time of autopsy. Even if the diagnosis is not firmly established following autopsy, the simple process of notifying the family of the possibility of hereditary disease may result in clinical screening and treatment of family members, preventing additional deaths.

A systematic examination of the heart for the presence of structural and/or acquired heart disease is a critical component of the autopsy evaluation of sudden cardiac death. Most anatomic pathologists are comfortable diagnosing common acquired heart diseases such as ischemic and hypertensive heart disease, but some may not be comfortable or are unfamiliar with the diagnosis of less common hereditary cardiomyopathies or complex congenital heart disease. Furthermore, hypertensive and ischemic heart disease may co-exist with, and even mimic, hereditary forms of cardiomyopathy. The discovery of left ventricular hypertrophy at autopsy should not be presumed to be secondary to hypertension, nor should it be presumed to be hypertrophic cardiomyopathy. A wide spectrum of diagnoses, including hereditary cardiomyopathies, need to be considered. A primary aim of this consensus paper is to provide a systematic approach to the autopsy evaluation of the heart in suspected SCD, with particular emphasis on documenting cardiovascular features that could be indicative of hereditary cardiovascular disease. An additional aim of this consensus paper is to provide guidance on appropriate steps to take after autopsy, especially if there is no obvious anatomic cause of death. Ideally, the most appropriate next step is to retain the majority of the heart and seek consultation from a fellowship-trained cardiovascular pathologist. In addition, ME/FPs should it is

important to ensure that appropriate samples for potential genetic testing are retained. Finally, the results of the autopsy and any additional testing are communicated to the family, with a recommendation to seek genetic counseling, if hereditary cardiovascular disease is suspected.

3.1. Scene Investigation

Scene investigation, including interview of witnesses, can provide vital clues to the cause of sudden unexpected death. The circumstances of the collapse, if witnessed, may point the investigation towards a cardiac or non-cardiac cause. A history of sudden collapse/loss of consciousness during vigorous physical or emotional events also suggests a sudden cardiac death. Cardiac disease may be a primary or contributory cause in swimming-related deaths where the decedent is known to be a strong swimmer and swimming conditions were fair. While drowning is generally determined to be the cause of death simply because the death occurred while in water, there may be an underlying cardiac abnormality that led to the event.^{18,19} Similarly, potential cardiac causes may also lead to motor vehicle collision deaths where the decedent was the operator and only had minor trauma. Further, cardiac abnormalities may lead to seizure-related deaths. The events immediately preceding the seizure should be carefully elicited from witnesses as the seizure may actually be secondary to cerebral ischemia due to a primary cardiac event. Furthermore, mutations in membrane-associated ion channels have been found in cases of sudden unexplained death in epilepsy (SUDEP).^{20,21} Symptoms preceding death such as syncope, dizziness, and chest pain are of particular importance as they could be indicative of cardiac dysfunction as the cause of the seizure and death. Interviews of emergency medical providers and law enforcement personnel or their reports can provide additional helpful details. Electrocardiographic tracings during resuscitation may also provide clues to an underlying cardiac cause.

3.2 Medical Record Review

Medical record review is important in cases of SCD in the young and should include investigation into a family history of sudden death. Family history of sudden premature death, syncope or seizure disorder may be significant as these conditions may lead to a diagnosis of familial cardiac conditions including arrhythmia syndromes, cardiomyopathies or connective tissue diseases. Prior medical workups with electrocardiogram (if available), prior surgical procedures/interventions, imaging studies, current medications, history of sports, lifestyle habits (e.g., smoking, alcohol), COVID-19 infection and/or vaccination status or any other pertinent decedent information are important in determining a differential diagnosis for the pathologist prior to performance of the autopsy.

3.3 General Autopsy Examination

In SCD, the autopsy examination follows the usual procedural steps including photographs as the body is received, clothing and personal effects inventory, documentation of evidence of medical intervention, photographs of the body unclothed and full examination of all organs. In sudden deaths associated with sports or vigorous activity, careful attention should be paid to documenting any non-resuscitative injuries to the sternal region that may be indicative of commotio cordis.²²⁻²⁴ Any significant injuries or unusual external findings should be photographed. However, it is important to remember that commotio cordis may occur without external injury and often is a diagnosis of exclusion.²²⁻²⁴ Best practice is to measure height and weight by scientific means (not estimated) after clothing has been removed. If organ/tissue donation has occurred prior to examination by the ME/C, the organ/tissue procurement agency should record the body height and weight prior to procurement. Alternatively, this information may be obtained from the medical record.

The internal examination of the body including the usual procedural steps including notation of any injury to the chest or abdominal wall musculature or ribs is completed. Prior to opening the chest cavity, the screening procedure to rule out a pneumothax (the examiner punctures the intercostal

muscles under water and observes whether there are bubbles formed) may be performed. It is important to note that artifactual injuries can occur secondary to resuscitation (especially with the use of a chest compression system) leading to blood in chest, abdominal and pericardial spaces. Blood found in any cavity should be measured by volume (milliliters) and should prompt an *in situ* inspection of the heart and ascending aorta for a rupture site. The presence of a fibrinous pericardial exudate, pericardial adhesions or calcifications should be noted. Dissection of the internal organs is directed towards identifying both cardiac and non-cardiac causes of sudden death (Table 1). Of particular importance, examination of the main left and right pulmonary arteries for thromboembolism and a detailed examination of the brain for neurological causes of sudden death such as a ruptured cerebral aneurysm or massive stroke may reveal a cause of sudden death.

If the decedent is an infant or if there is known or suspected congenital heart disease, the thoracic organs (heart, lungs, trachea and esophagus) should be removed *en bloc* to preserve any congenital anomalies such as trachea-esophageal fistula or anomalous pulmonary venous connection. Congenital cardiac causes of sudden death are beyond the scope of this consensus paper, but if congenital heart disease is suspected as the cause of death, consultation with a cardiovascular and/or pediatric pathologist is recommended.

In older children and adults without suspected congenital heart disease, the ascending aorta and main pulmonary artery may be transected at the level of the transverse sinus which runs posterior to the great arteries. The heart may then be excised completely from the pericardial cavity by sequentially incising through the inferior vena cava, left and right pulmonary veins, and superior vena cava. When incising these vessels within the pericardium, care should be taken to cut the vessels as close to the pericardium and as far from the heart as possible to avoid accidentally cutting into the heart and to preserve the vascular connections. The heart may then be examined as described below or prepared for consultation.

Once non-cardiac causes of death have been excluded, the autopsy can proceed towards an examination for hereditary (Table 2) and non-hereditary cardiovascular causes of sudden death (Table 3).

3.4 Gross Cardiac Examination

If hereditary cardiovascular disease is suspected, the heart may be retained for consultation with a cardiovascular pathologist, if allowed by local statutes. Families may also object to retention of the entire heart, but this objection can often be overcome with an explanation of the reasoning for retaining the heart. Multiple detailed photographs of the heart, with a ruler for scale, are recommended. Routine photographs of the heart should include a photograph of the anterior surface of the heart prior to dissection (Figure 1), and a photograph of the largest short-axis cross-section (Figure 2) and any other significant epicardial, myocardial, endocardial or valvular abnormalities. A photograph of the heart on the scale showing the weight of the heart may also be useful for documenting the heart weight.

A complete examination of the heart requires both gross and microscopic examinations. Most FP/Cs do not submit multiple microscopic sections of the heart in cases with an obvious cause of death (gunshot wounds, motor vehicle crash). However cases of unexplained death (eg: motor vehicle crash in a young person with minimal injuries) microscopic examination is important as some cases of SCD are not grossly evident. The following technique allows for optimal examination of the coronary arteries, cardiac valves and myocardium while preserving the conduction system and regions of the heart for additional expert examination. The technique described below is preferred for the routine cardiac pathologic examination.^{16, 25-28} Hearts with suspected or known congenital anomalies typically require case-specific dissection. The dissection of infant (> 1 year old) heart-lung blocks should also be case

specific as congenital anomalies are more common in this patient group. Online resources for viewing cardiac examinations performed by cardiovascular pathologists are available.

Accurate weight of the heart is critical in the overall cardiac pathologic assessment and is one of the most controversial issues of this document.²⁹ When weighed, heart should only include 1-2 centimeters of ascending thoracic aorta and pulmonary artery; the aortic arch and the descending thoracic aorta should not be included in the weight. The heart should be rinsed and weighed after cardiac dissection has been completed to ensure that all intra-cardiac postmortem clot has been removed before weighing. The weight of the heart can be compared to body-size reference tables.^{30-34,100} Many of these tables used to determine if a heart is abnormal are being challenged by cardiovascular and forensic communities due to the significant variability in the reported reference ranges of supposedly normal values. Several new modalities for determination of cardiac hypertrophy and cardiomegaly have been published for use.³⁵⁻³⁷ The body height is better for comparison to the reference tables as body weight determined at autopsy does not always accurately reflect pre-mortem body weight, particularly in the setting of anasarca or obesity³². If organ/tissue donation has occurred, the pre-procurement body weight and height provided by the procurement agency should be used for referencing the expected heart weight. Alternatively, the body weight and height can be obtained from the medical record.

Generally, a normal adult man's heart is 0.45% of body weight and a normal adult woman's heart is 0.40% of body weight.³⁸ In general, several studies have shown that a heart weight over 500 grams is abnormal.³⁴ This fact is particularly important in determining the presence of cardiac hypertrophy in obese decedents.^{39,40}

If the heart appears enlarged, the overall shape of the heart is noted with descriptions of any chamber-size enlargements. Description of the external appearance of the heart includes any congenital anomalies, pericardial changes and epicardial plaques, petechiae or nodules.

The next step in the process is the serial cross sectioning of the coronary arteries. All coronary arteries and large branches should be sectioned at 2-3-millimeter intervals. While uncommon as a cause of death in the young, the likelihood of finding atherosclerotic coronary artery disease increases with age. The presence of severe diffuse coronary atherosclerosis in a young person should prompt consideration of familial hypercholesterolemia. The degree of atherosclerotic narrowing/stenosis is determined by assessing the cross-sectional luminal narrowing of the coronary arteries. The coronary arteries should never be opened longitudinally, as this prevents determination of the cross-sectional luminal narrowing. The degree of luminal narrowing and its location within the arterial segment should be documented. Heavily calcified coronary arteries may require removal and decalcification to determine the amount of luminal narrowing. Artery segments with stents can be subjected to stent electrolysis to dissolve the stent prior to sectioning⁴¹ or may be sent to an outside laboratory for examination where stented segments are embedded in methacrylate and sectioned with a diamond knife. Determination of coronary arterial dominance is important to document (right or left dominance is determined by which artery gives rise to the posterior descending coronary artery).

Three to four cross sectional slices should be made across the ventricles beginning at the apex moving towards the base of the heart. The 1-2-centimeter-thick cross-sectional slices will terminate approximately at the tip of the papillary muscles. Care should be taken to ensure that the short-axis sections are cut parallel to the atrioventricular sulcus at the base of the heart and perpendicular to the ventricular walls as a tangential section may give the false appearance of asymmetrical ventricular hypertrophy. These cross-sectional slices of the ventricles maximize the examination of myocardial surface area while preserving the cardiac valves and overall cardiac structure. Examination of the myocardium includes documentation of the location and distribution of grossly identifiable lesions.

Ventricular wall thickness is not a reliable marker of cardiac hypertrophy because wall thickness may vary depending on the degree of cardiac dilatation. However, ventricular wall thickness

measurements may be useful for documenting the presence of asymmetrical ventricular hypertrophy. When measuring ventricular wall thickness, only the compact myocardium is measured; the papillary muscles and trabecular myocardium are excluded (Figure 2).

The remaining heart is then opened along lines of blood flow beginning with the right atrium, then proceeding to the right ventricular inflow and outflow tracts, the left atrium and the left ventricular inflow and outflow tracts. The first step is to make a horizontal incision adjacent to the inferior vena cava to the tip of the right atrial appendage. The superior vena cava is left intact to preserve the sinoatrial node, which lies within the crista terminalis at the junction of the superior vena cava and the right atrial appendage. The presence and size of thrombi within the right atrial appendage should be documented. Examination of the atrial septum includes determining patency of the foramen ovale or other congenital anomalies. The ostium of the coronary sinus should be evaluated as well as documentation of any residual embryologic structures (i.e. Chiari network).

The next step is to make an incision through the right ventricular inflow tract. The incision is made approximately 3 centimeters rightward of the ventricular septum through the posterior leaflet of the tricuspid valve. Any changes to the tricuspid valve should be noted. Documentation of mottling, fibrosis, fat or fibrofatty replacement of the right ventricular myocardium is important to document.

The right ventricular outflow tract incision is made through the anterior wall of the right ventricle and pulmonary valve. The number and any changes to the pulmonary valve cusps are noted. The ventricular septum, especially in the perimembranous region behind the septal leaflet of the tricuspid valve is examined. This dissection technique preserves the region of the atrioventricular node, should a cardiac conduction system study be required.

Dissection of the left atrium is best accomplished through by making a vertical incision between the left and right pulmonary veins from the dome to the posterior mitral annulus and extending the incision through the left atrial appendage. An alternative dissection technique involves a vertical

incision between the pulmonary veins to the dome of the atrium with a second incision at the base of the first (an inverted T) extending into the left atrial appendage. Any changes to the endocardium or thrombi within the left atrial appendage are documented.

Evidence of myxomatous thickening, perforation, or rupture of a tendinous chord of the mitral valve is important to document. The left ventricular inflow tract incision is made through the posterior leaflet of the mitral valve within the lateral wall between the two papillary muscles of the left ventricle (along the obtuse margin). Determination of left ventricular thickness is made on a straight, non-tangential cut of the wall measuring only the compact left ventricular myocardium at the mid-ventricular level, essentially at the level of the tip of the papillary muscles. Examination of the myocardium at the base of the ventricle beneath the posterior mitral valve can reveal a scoop-out appearance of a posterior basilar infarct.

The left ventricular outflow tract incision is the most technically difficult of the cardiac examination. The technique involves an incision posterior to the anterolateral papillary muscle, parallel to the ventricular septum, sparing the mitral valve and extending toward the aortic valve. Once this incision is made, the heart is then placed inverted on the dissecting table and the aortic valve visualized. The incision is extended upward through the commissure between the right and left aortic valve cusps. This technique allows for evaluation of all aortic valve cusps and coronary artery ostia while preserving all other left-sided structures.

Examination and documentation of any abnormalities of the aortic valve cusps, subvalvular region and aortic root such as a congenitally abnormal aortic valve or aortic root dilatation. The presence of significant endocardial fibrosis of the subaortic ventricular septum is important to note, especially if the pattern of the endocardial fibrosis appears to mirror the anterior leaflet of the mitral valve. This finding may indicate dynamic left ventricular outflow tract obstruction by the anterior mitral valve leaflet, a frequent indicator of hypertrophic cardiomyopathy.

Locations of the coronary artery ostia are crucial to document. There is a wide range of coronary artery ostial variants including multiple coronary artery ostia arising from either the right or left sinus of Valsalva, eccentric origin of the coronary arteries toward either commissure or ostia arising from the sinotubular ridge. Anomalous origins of the coronary arteries include those arising from the pulmonary artery, the wrong sinus of Valsalva, a single coronary artery ostium or high (greater than 2.5 millimeters above the sinotubular ridge) or acute angle of origin from the ascending aorta.⁴² Histologic sampling of the myocardium perfused by the anomalous coronary artery may be helpful for determining the significance of the coronary anomaly.

If the heart is to be sent for consultation (pre- or post-dissection), fixation of the heart in 10% neutral buffered formalin for a minimum of 72 hours after it has been irrigated with water to remove any post-mortem clot is required. The heart can then be loosely wrapped in a formalin-soaked disposable towel and sealed in a plastic bag. This bag can be transported overnight at room temperature to a referral center for further analysis.

3.5. Histologic Sections of the Heart

Adequate histologic sampling of myocardium in sudden unexpected cardiac deaths includes at least 5 full-thickness sections of ventricular myocardium (anterior left ventricle, lateral left ventricle, inferior/posterior left ventricle, interventricular septum and posterior right ventricle).²⁸ The most severely narrowed segment of each epicardial coronary artery, any gross abnormality in the ventricular or atrial myocardium (such as fibrosis or mottling) and at least one section of right ventricle are examined microscopically. Additional sections of right ventricle, particularly the anterior wall of the right ventricular outflow tract, may be submitted if significant fibrofatty infiltration is apparent on gross examination. Heart valves may be submitted for histology if there are features of infective endocarditis, myxomatous disease or unusual thickening (post-inflammatory heart disease). Generous sampling of the

myocardium (a minimum of 10 slides) is especially important when myocarditis is suspected. The cardiac conduction system may be submitted for histologic examination in cases of sudden cardiac death with a structurally normal heart at autopsy.^{43,44} If a current electrocardiogram is available, it may help provide information for the conduction system study.

3.6 Hereditary Aortopathies

Thoracic aortic dissection and rupture in a person younger than 40 years old, in the absence of a history of hypertension, stimulant substance abuse, congenitally bicuspid aortic valve, or trauma, should raise concern for a hereditary aortopathy such as Marfan syndrome, Loeys-Dietz syndrome, Ehlers-Danlos Type IV, or familial thoracic aortic aneurysm and dissection syndrome (FTAAD). Genetic testing for hereditary aortopathies may be useful for confirmation of suspected aortopathy discovered at autopsy.^{44,45} Even in the absence of a pathogenic mutation, aortopathy may be familial, so it is recommended that surviving family members be promptly notified that the decedent died from an aortic dissection or rupture, so that their own clinical providers may assess whether further clinical evaluation of family members for aortic dilatation or dissection is warranted.

At autopsy, a ruptured aortic dissection will first become apparent with the identification of blood in the pericardial cavity (hemopericardium) or in a pleural cavity (hemothorax). The amount of blood should be measured in milliliters. If blood is in the pericardium, the ascending aorta should be carefully examined *in situ* for an adventitial rupture site. If the blood is in a pleural cavity (usually left-sided), the descending thoracic aorta is examined for an adventitial rupture site. The heart may then be removed as described above. It is best practice to remove the ascending aorta, arch and descending thoracic and abdominal aorta together. The aorta may be opened by cutting anteriorly along the ascending aorta, antero-superiorly along the arch and then posteriorly along the descending thoracic and abdominal aorta. The intima is then examined for an intimal-medial tear. The location of the tear

(ascending thoracic aorta, aortic arch, descending thoracic aorta or abdominal aorta) and the presence or absence of medial dissection are important to note. If medial dissection is present, documentation of retrograde or antegrade extension from the intimal tear is noted. Dissection that travels retrograde to involve the coronary arteries may lead to an acute myocardial infarct. The proximal and distal extents of the dissection and whether the dissection terminates in another intimal tear (re-entry site) or adventitial rupture site are noted. The presence or absence of aortic dilatation or aneurysm are important details to note including the segment involved, length of involvement and widest diameter.

Histologic samples of the aorta including the dissection may be taken to assess the age of the thrombus in the false lumen. Histologic samples of the aorta away from the dissection and rupture site should also be taken to assess the uninvolved aorta for medial abnormality. The presence of severe medial degeneration with large pools of trans-lamellar mucoid extracellular matrix accumulation (T-MEMA) should raise concern for an underlying hereditary aortopathy.^{46,47}

3.7 Additional Ancillary Studies (Toxicology, Vitreous, and Metabolic Studies)

Anatomic and histologic abnormalities that are diagnostic for a cause of death are not always observed at autopsy. In such instances, ancillary laboratory testing may be useful for establishing, confirming, or ruling out a suspected cause of death. The utility of ancillary laboratory testing is especially important when the suspected cause of death is not demonstrable by other means. For example, deaths due to drug overdose or inherited arrhythmia syndromes (channelopathies) typically present with non-specific findings at autopsy and can only be demonstrated with ancillary studies. Sleep-related infant and child deaths and seizure-related deaths also typically present with non-specific findings at the time of autopsy. Ancillary studies are important for ruling out other potential causes of death.

The primary role of toxicological testing in the evaluation of sudden death is to rule out drug toxicity as an underlying or contributory cause of death. Comprehensive toxicology testing is particularly important in the setting of sudden death in young adults, because substance abuse often overlaps this same population. Furthermore, it may be necessary to perform an extended toxicology screen as many novel illicit substances of abuse are not detectable with routine assays, such as synthetic fentanyl analogues, synthetic cannabinoids and synthetic cathinones (“bath salts”).⁴⁸ With athletics-related deaths, toxicology screening for performance-enhancing substances such as anabolic steroids may be warranted.^{49,50} Failure to identify these substances on toxicology testing may result in misclassification of these deaths as sudden unexplained death.

The utility of postmortem vitreous fluid chemistry in the evaluation of sudden death is well-recognized in the forensic community.⁵¹ Elevated vitreous sodium, chloride, creatinine and urea nitrogen may be indicative of dehydration. Dehydration is particularly important to rule out as an alternative cause of death in athletes who die during vigorous exercise.⁵² Diabetic ketoacidosis may also rarely present as sudden unexpected death without a previous history of diabetes mellitus. A markedly elevated vitreous glucose along with an elevated blood beta-hydroxybutyrate or acetone would support a diagnosis of diabetic ketoacidosis. Hereditary metabolic disorders are rare but well-described causes of sudden unexpected death. Tandem mass-spectrometry of blood and bile spots may detect abnormalities in the metabolic profile and indicate a diagnosis of an inborn error of metabolism such as a fatty chain oxidation disorder⁵³, though expanded newborn screening has reduced the utility of this testing in the forensic setting. Undiagnosed lysosomal storage diseases and glycogen storage diseases may also present as sudden death, and the gross morphologic findings may mimic hypertrophic cardiomyopathy. The presence of diffuse sarcoplasmic vacuolization of cardiac myocytes on histology should raise concern for an underlying storage disorder such as Fabry disease⁵⁴ or glycogen storage

disease.⁵⁵ Postmortem ancillary studies that may help to confirm the diagnosis of an underlying storage disorder include transmission electron microscopy and enzymatic and genetic testing.

3.8 Role of Postmortem Genetic Testing in the Evaluation of Sudden Cardiac Death

Postmortem genetic testing (“molecular autopsy”) has become an important component of sudden cardiac death investigation.⁵⁶⁻⁶⁰ Genetic testing can be useful in the diagnosis of heritable cardiomyopathies (e.g., dilated, hypertrophic, arrhythmogenic and restrictive forms)⁵²⁻⁵⁴, channelopathies/arrhythmia syndromes (e.g., long QT syndrome, Brugada syndrome, etc.)⁵⁵, connective tissue diseases (e.g., Marfan syndrome, Loeys-Dietz syndrome, and Ehlers-Danlos syndromes)⁵⁶ and familial hypercholesterolemia.⁵⁷ Certain findings in the medical history, circumstances surrounding death documented by Emergency Medical Providers or Law Enforcement agencies or autopsy findings⁵⁸ should prompt retention of autopsy samples for cardiovascular genetic testing due to high possibility of hereditary cardiovascular disease (Table 4).

Panel genetic testing utilizing next generation sequencing (NGS) is becoming more widespread and affordable. It is currently the preferred method for postmortem genetic testing because it allows the analysis of large numbers of genes in a single assay. NGS technology can be performed on a variety of postmortem samples including liquid blood, blood spot cards, fresh frozen and formalin-fixed, paraffin-embedded tissue⁵⁹, because only short fragments of target DNA are needed for sequencing. Techniques for affordable genetic sequencing continue to advance at a rapid pace, but reliable methods to associate these newly discovered genetic variants with phenotypic profiles lags far behind. As a result, the clinical significance of many of these variants is uncertain. It is becoming increasingly important for pathologists to be familiar with the terminology associated with the clinical classification of genetic variants, particularly the so-called “variant of uncertain significance” (VUS). VUS designations are frequently encountered when interrogating cardiovascular diseases, making it difficult or impossible

to draw actionable conclusions from the results. This situation has been termed “genetic purgatory”⁶⁰ because the uncertain clinical significance of the discovered variant places the surviving family in a state of limbo between knowing and not knowing the cause of death.

In 2015, the American College of Medical Genetics (ACMG) and Genomic and the Association for Molecular Pathology published revised guidelines for interpreting and reporting of genomic sequence variants.⁶¹ The guidelines include a five-category system for classifying variants discovered at sequencing, depending on the certainty that the variant affects protein function. If the variant is well-characterized and not known to affect protein function, due to its frequency in healthy populations or its functional characterization, it is designated as *benign*. Conversely, if a variant is well-established in only diseased populations or has been shown to have deleterious effects in the laboratory, it is deemed *pathogenic*. Categories of *likely pathogenic* and *likely benign* are provided for variants where evidence is accumulating, but not yet sufficient to classify as benign or disease-causing. For those variants where there is insufficient information for further classification, a designation of “*variant of unknown significance*” (VUS) is given.

It is important to note that, though there is general consensus on the utility of the ACMG five-category system for classifying genetic variants, there is not yet a widely accepted consensus methodology for the classification of all variants, particularly those that are rare and previously not seen. Factors that are considered in assessing pathogenicity of a variant include whether the genetic variant is predicted by various software programs to result in a change in protein expression or conformation that would affect function, the existence of similar variants in the same or similar genes that have been shown to be pathogenic or benign by functional studies, or through multi-generational family segregation studies and evolutionary conservation of that particular genetic locus across species. Other factors that may also affect rare variant interpretation include pertinent positive and negative autopsy findings, circumstances of death, results of other ancillary studies, and the personal and family

history of the decedent. Previous individual case reports of the same or similar variants can also be helpful but should be interpreted with consideration of the lack of uniformity in interpreting the significance of newly discovered variants.

Because of the varying weights that may be accorded to each of these factors in assessing potential pathogenicity, there could be significant discrepancies between laboratories on the classification of variants. It is not uncommon for the performing laboratory's classification to be independently reviewed by the clinical care team. Of note, the rate of discrepancy between the laboratory and clinical team's interpretation of a genetic variant appears to be highest for cardiovascular diseases compared to other clinical specialties, such as oncology.⁶² Therefore, prudence is warranted when the ME/C is interpreting a genetic test report for sudden cardiac death. The presence of a pathogenic or likely pathogenic variant should not be assumed to be the cause of death. Conversely, the ME/C should not automatically conclude that a negative genetic test report rules out the presence of a hereditary cardiovascular disease. Consultation with a genetic counselor may be helpful should there be significant doubt about the clinical significance of a genetic variant.

3.8.1 Recommendation for Retention of Postmortem Samples for Genetic Analysis

The recommended postmortem sample to retain for potential genetic testing is 5 to 10 milliliters of blood with ethylenediaminetetraacetic acid (EDTA) preservative, which usually corresponds to one purple-top tube.¹⁷ If the sample is to be stored for less than 1 month after autopsy, the sample may be stored at 4°C. If the sample is to be saved for a longer time, the sample should be kept frozen at -80°C. The retention period for liquid or frozen blood samples will vary depending on the capability of FP/C offices to retain refrigerated or frozen samples.

Recently, technical advances have allowed postmortem genetic testing to be performed on blood spot cards and formalin-fixed paraffin-embedded (FFPE) tissue, typically in the form of a tissue

block for histology.⁵⁹ This technical advance allows a larger proportion of decedents with suspected hereditary cardiovascular diseases to receive genetic testing, since tissues routinely taken at autopsy are embedded in paraffin for histology. Furthermore, these samples can be stored at room temperature. Therefore, in addition to the retention of blood samples, it is recommended that a blood spot card and/or FFPE should be retained. The retention period will depend upon the storage capacity of each FP/C office, but we recommend a retention period of at least 5 years following autopsy. Of note, while it is possible to interrogate FFPE, dried blood spots, and frozen tissue, an EDTA tube of blood is still regarded as the optimum specimen for molecular genetic studies.

3.8.2 Communication of Genetic Test and Autopsy Results to Family

The primary responsibility of the pathologist is to simply notify the next of kin that a potential hereditary cardiac disease has been identified and that immediate family members may wish to discuss the need for additional screening with their clinical providers. Referral to a multidisciplinary team consisting of cardiologists and genetic counselors that specialize in cardiovascular genetics at a regional academic medical center would be ideal, but such centers are relatively rare in the U.S. Of note, communication to the family by the pathologist does **not** represent engagement in a traditional physician-patient role with the surviving family, but the pathologist may want and need to be available for consultation with the primary care givers should it be necessary. The autopsy report should include genetic test results and a list of autopsy specimens that have been retained for potential genetic testing.

3.8.3 Inclusion of Genetic Variants on the Death Certificate

Careful consideration by the FP/C is required when deciding whether to include a discovered genetic variant on the death certificate. This consideration should first include an independent review of

whether the reported variant is pathogenic or likely pathogenic, and secondly, whether that mutation was the underlying cause of death, contributory to other underlying cause(s), or completely incidental to the cause of death. This second consideration will require interpretation of the genetic test results within the context of the overall death investigation including autopsy and scene findings, circumstances of death, and other ancillary studies. For example, the pathologist should consider whether the variant found is consistent with the cardiovascular findings at autopsy and not automatically assume that the discovery of a variant on genetic testing is the actual cause of death.

Generally, benign variants, likely benign variants, and VUSs should not be listed on the death certificate as either the underlying cause of death (Part 1) or a contributory cause of death (Part 2). The pathologist may be inclined to include the VUS in Part 2 for posterity reasons due to the possibility of pathogenicity being proven in the future, but generally such practice is discouraged as it may lead to confusion and potentially unnecessary treatment of surviving family members. In natural deaths, the death certificate should be reserved for findings that have a reasonable likelihood of contributing to the death based on information available at the time of certification; the autopsy report is the appropriate record to include all findings, including genetic test results, for posterity. In cases where the pathologist suspects that a VUS may actually be pathogenic based on independent review, it would be appropriate to include that variant on the death certificate.

4. Conclusions

There are numerous obstacles that impede quality investigation of SCD in the young including lack of standardized autopsy practices across various jurisdictions and inadequate funding of ME/C offices that result in diversion of scarce resources towards cases that are more likely to result in criminal prosecution. It is our opinion that the work of ME/Cs should not only serve the criminal justice system, but should serve all communities through improved public health and safety initiatives, and perhaps

most importantly, by finding answers to questions that have direct impact on surviving family members. In the investigation of sudden cardiac death in the young, it is arguable that these pathologists have the greatest potential to discover a hereditary disease that will lead to clinical treatment of a surviving family member.

The purpose of this consensus statement is to provide guidance to pathologists in the investigation of SCD in the young, and to encourage standardization in the documentation of cardiac findings at autopsy. Additionally, this consensus statement provides a simple referral form for pathologists to send with cardiac specimens for examination by fellowship-trained cardiovascular pathologists. While pathologists examine the cardiovascular system and the heart with each and every autopsy, it is possible that a potentially significant finding may be overlooked. Fellowship-trained cardiovascular pathologists have additional training and experience that can lend assistance to these cases.

Technical advances and continual reduction in costs of postmortem genetic testing has made this important tool more available for pathologists, but routine access is still not available to the majority of offices. Therefore, it is of the utmost importance that appropriate samples for potential genetic testing are retained at the time of autopsy. It is important also to recognize the current limitations of postmortem genetic testing in the diagnosis of hereditary cardiovascular disease. Pathologists must learn how to convey an appropriate level of uncertainty to family members regarding the discovery of variants of uncertain significance and refer to an appropriate multidisciplinary clinical team for appropriate follow-up.

Declaration of interests

The authors declare that they have no known competing financial interests or personal relationships that could have appeared to influence the work reported in this paper.

References

1. Goldstein S. The necessity of a uniform definition of sudden coronary death: Witnessed death within 1 hour of the onset of acute symptoms. *Am Heart J* 1982;103:156-9.
2. Zipes DP, Wellens HJJ. Sudden cardiac death. *Circulation* 1998;98:2334-51.
3. Zaijia C et al. Sudden cardiac death. Report of a WHO Scientific Group. *World Health Organ Tech Rep Ser* 1985;726:5-25.
4. Vaartjes I, Hendrix A, Hertogh EM, Grobbee DE, Doevendans PA, Mosterd A, Bots ML. Sudden death in persons younger than 40 years of age: incidence and causes. *Eur J Cardiovasc Prev Rehabil* 2009;16:592-6.
5. Trans-Tasman Response AGAinst sudden death in the young (TRAGADY). Post-mortem in sudden unexpected death in the young: Guidelines on autopsy practice. 2008.
6. <https://www.cdc.gov/mmwr/preview/mmwrhtml/mm5106a3.htm>
7. Hayashi M, Shimizu W, Albert CM. The spectrum of epidemiology underlying sudden cardiac death. *Circ Res* 2015;116:1887-906.
8. Gillum RF. Sudden coronary death in the United States: 1980-1985. *Circulation* 1989;79:756-65
9. Isbister J, Semsarian C. Sudden cardiac death: an update. *Intern Med J* 2019;49:826-33.
10. Corrado D, Basso C, Thiene G. Sudden cardiac death in young people with apparently normal heart. *Cardiovasc Res* 2001;50:399-408.
11. Risgaard B. Sudden cardiac death: a nationwide cohort study among the young. *Dan Med J* 2016;63:B5321.
12. Virmani R, Burke AP, Farb A. Sudden cardiac death. *Cardiovasc Pathol* 2001;10:211-8.

13. Bagnall RD, Weintraub RG, Ingles J, Duflo J, Yeates L, Lam L, Davis AM, Thompson T, Connell V, Wallace J, Naylor C, Crawford J, Love DR, Hallam L, White J, Lawrence C, Lynch M, Morgan N, James P, du Sart D, Puranik R, Langlois N, Vohra J, Winship I, Atherton J, McGaughran J, Skinner JR, Semsarian C. A Prospective Study of Sudden Cardiac Death among Children and Young Adults. *N Engl J Med* 2016;374:2441-52.
14. Chugh SS, Chung K, Zheng ZJ, John B, Titus JL. Cardiac pathologic findings reveal a high rate of sudden cardiac death of undetermined etiology in younger women. *Am Heart J* 2003;146:635-9.
15. Basso C, Aguilera B, Banner J, Cohle S, d'Amati G, de Gouveia RH, di Gioia C, Fabre A, Gallagher PJ, Leone O, Lucena J, Mitrofanova L, Molina P, Parsons S, Rizzo S, Sheppard MN, Mier MPS, Kim Suvarna S, Thiene G, van der Wal A, Vink A, Michaud K; Association for European Cardiovascular Pathology. Guidelines for autopsy investigation of sudden cardiac death: 2017 update from the Association for European Cardiovascular Pathology *Virchows Arch* 2017;471:691-705.
16. Wilhelm M, Bolliger SA, Bartsch C, Fokstuen S, Gräni C, Martos V, Medeiros Domingo A, Osculati A, Rieubland C, Sabatasso S, Saguner AM, Schyma C, Tschui J, Wyler D, Bhuiyan ZA, Fellmann F, Michaud K. Sudden cardiac death in forensic medicine – Swiss recommendations for a multidisciplinary approach. *Swiss Med Wkly* 2015;145:w14129.
17. Middleton O et al. National Association of Medical Examiners position paper: Retaining postmortem samples for genetic testing. *Acad Forensic Pathol* 2013;3:191-4.
18. Kenny D, Martin R. Drowning and sudden cardiac death. *Arch Dis Child* 2011;96:5-8.
19. Tester DJ, Medeiros-Domingo A, Will ML, Ackerman MJ. Unexplained drownings and the cardiac channelopathies: a molecular autopsy series. *Mayo Clin Proc* 2011;86:941-7.

20. Devinsky O, Hesdorffer DC, Thurman DJ, Lhatoo S, Richerson G. Sudden unexpected death in epilepsy: epidemiology, mechanisms, and prevention. *Lancet Neurol* 2016;15:1075-88.
21. Coll M, Oliva A, Grassi S, Brugada R, Campuzano O. Update on the genetic basis of sudden unexpected death in epilepsy. *Int J Mol Sci* 2019;20:1979.
22. Madias C, Maron BJ, Weinstock J, Estes NA 3rd, Link MS. Commotio cordis--sudden cardiac death with chest wall impact. *J Cardiovasc Electrophysiol* 2007;18:115-22.
23. Veld MA, Craft CA, Hood RE. Blunt Cardiac Trauma Review. *Cardiol Clin* 2018;36:183-91.
24. Lupariello F, Di Vella G. The role of the autopsy in the diagnosis of commotio cordis lethal cases: Review of the literature. *Leg Med (Tokyo)* 2019;38:73-6.
25. Silver M, Silver M. Examination of the heart and of cardiovascular specimens in surgical pathology. In: Silver M, Gotlieb A, Schoen F (eds). *Cardiovascular Pathology*. 3rd ed. Philadelphia: Churchill Livingstone: 2001.
26. Duncanson E, Mackey-Bojack S. Adult heart dissection technique. *Academ Forensic Pathol* 2011;1:148-155.
27. Osborn M, Sheppard M. Guidelines on autopsy practice: Sudden death with likely cardiac pathology. <https://www.rcpath.org/asset/823DFCF4-8EBA-40F7-81B7E174675ECDD9/> July 2015 1-16.
28. Basso C, Burke M, Fornes P, Gallagher PJ, De Gouveia RH, Sheppard M, Thiene G, Van Der Wal A; Association for European Cardiovascular Pathology. Guidelines for autopsy investigation of sudden cardiac death. *Pathologica* 2010;102:391-404.

29. Basso C, Michaud K, d'Amati G, Banner J, Lucena J, Cunningham K, Leone O, Vink A, van der Wal AC, Sheppard MN; Association for European Cardiovascular Pathology. Cardiac hypertrophy at autopsy. *Virchows Arch* 2021;479:79-94.
30. Scholz DG, Kitzman DW, Hagen PT, Ilstrup DM, Edwards WD. Age-related changes in normal human hearts during the first 10 decades of life. Part I (Growth): A quantitative anatomic study of 200 specimens from subjects from birth to 19 years old. *Mayo Clin Proc* 1988;63:126-36.
31. Kitzman DW, Scholz DG, Hagen PT, Ilstrup DM, Edwards WD. Age-related changes in normal human hearts during the first 10 decades of life. Part II (Maturity): A quantitative anatomic study of 765 specimens from subjects 20 to 99 years old. *Mayo Clin Proc* 1988;63:137-46.
32. McCormack CA, Lo Gullo R, Kalra MK, Louissaint A Jr, Stone JR. Reliability of body size measurements obtained at autopsy: impact on the pathologic assessment of the heart. *Forensic Sci Med Pathol* 2016;12:139-45.
33. Molina DK, DiMaio VJ. Normal Organ Weights in Women: Part I-The Heart. *Am J Forensic Med Pathol* 2015;36:176-81.
34. Molina DK, DiMaio VJ. Normal organ weights in men: part I-the heart. *Am J Forensic Med Pathol* 2012;33:362-7.
35. Wingren CJ, Ottosson A. Postmortem heart weight modelled using piecewise linear regression in 27,645 medicolegal autopsy cases. *Forensic Sci Int* 2015;252:157-62.
36. de la Grandmaison GL, Clairand I, Durigon M. Organ weight in 684 adult autopsies: new tables for a Caucasoid population. *Forensic Sci Int* 2001;119:149-54.
37. Vanhaebost J, Faouzi M, Mangin P, Michaud K. New reference tables and user-friendly Internet application for predicted heart weights. *Int J Legal Med* 2014;128:615-20.

38. Hudson REB. Cardiovascular Pathology, Vol. 1. Williams and Wilkins, Baltimore (1965).
39. Alpert MA, Agrawal H, Aggarwal K, Kumar SA, Kumar A. Heart failure and obesity in adults: pathophysiology, clinical manifestations and management. *Curr Heart Fail Rep* 2014;11:156-65.
40. Finocchiaro G, Papadakis M, Dhutia H, Cole D, Behr ER, Tome M, Sharma S, Sheppard MN. Obesity and sudden cardiac death in the young: Clinical and pathological insights from a large national registry. *Eur J Prev Cardiol* 2018;25:395-401.
41. Bradshaw SH, Kennedy L, Dexter DF, Veinot JP. A practical method to rapidly dissolve metallic stents. *Cardiovasc Pathol* 2009;18:127-33.
42. Muriago M, Sheppard MN, Ho SY, Anderson RH. Location of the coronary arterial orifices in the normal heart. *Clin Anat* 1997;10:297-302.
43. Gulino SP. Examination of the cardiac conduction system: forensic application in cases of sudden cardiac death. *Am J Forensic Med Pathol* 2003;24:227-38.
44. Thiene G, Corrado D, Basso C. Sudden cardiac death in the young and athletes. *Atlas of Pathology and Clinical Correlates*. Springer-Verlag, Milan (2016).
45. Loeys BL, Schwarze U, Holm T, Callewaert BL, Thomas GH, Pannu H, De Backer JF, Oswald GL, Symoens S, Manouvrier S, Roberts AE, Faravelli F, Greco MA, Pyeritz RE, Milewicz DM, Coucke PJ, Cameron DE, Braverman AC, Byers PH, De Paepe AM, Dietz HC. Aneurysm syndromes caused by mutations in the TGF-beta receptor. *N Engl J Med* 2006;355:788-98.
46. Wooderchak-Donahue W, VanSant-Webb C, Tvrdik T, Plant P, Lewis T, Stocks J, Raney JA, Meyers L, Berg A, Rope AF, Yetman AT, Bleyl SB, Mesley R, Bull DA, Collins RT, Ojeda MM, Roberts A, Lacro R, Woerner A, Stoler J, Bayrak-Toydemir P. Clinical utility of a next generation

sequencing panel assay for Marfan and Marfan-like syndromes featuring aortopathy. *Am J Med Genet A* 2015;167:1747-57.

47. Halushka MK, Angelini A, Bartoloni G, Basso C, Batoroeva L, Bruneval P, Buja LM, Butany J, d'Amati G, Fallon JT, Gallagher PJ, Gittenberger-de Groot AC, Gouveia RH, Kholova I, Kelly KL, Leone O, Litovsky SH, Maleszewski JJ, Miller DV, Mitchell RN, Preston SD, Pucci A, Radio SJ, Rodriguez ER, Sheppard MN, Stone JR, Suvarna SK, Tan CD, Thiene G, Veinot JP, van der Wal AC. Consensus statement on surgical pathology of the aorta from the Society for Cardiovascular Pathology and the Association For European Cardiovascular Pathology: II. Noninflammatory degenerative diseases - nomenclature and diagnostic criteria. *Cardiovasc Pathol* 2016;25:247-257.
48. Concheiro M, Chesser R, Pardi J, Cooper G. Postmortem Toxicology of New Synthetic Opioids. *Front Pharmacol* 2018;9:1210.
49. Fanton L, Belhani D, Vaillant F, Tabib A, Gomez L, Descotes J, Dehina L, Bui-Xuan B, Malicier D, Timour Q. Heart lesions associated with anabolic steroid abuse: comparison of post-mortem findings in athletes and norethandrolone-induced lesions in rabbits. *Exp Toxicol Pathol*. 2009;61:317-23.
50. Hausmann R, Hammer S, Betz P. Performance enhancing drugs (doping agents) and sudden death--a case report and review of the literature. *Int J Legal Med* 1998;111:261-4.
51. Coe JI. Postmortem chemistries on human vitreous humor. *Am J Clin Pathol* 1969;51:741-50.
52. Madea B, Lachenmeier DW. Postmortem diagnosis of hypertonic dehydration. *Forensic Sci Int* 2005;155:1-6.

53. Rinaldo P, Yoon HR, Yu C, Raymond K, Tiozzo C, Giordano G. Sudden and unexpected neonatal death: a protocol for the postmortem diagnosis of fatty acid oxidation disorders. *Semin Perinatol* 1999;23:204-10.
54. Sheppard MN. The heart in Fabry's disease. *Cardiovasc Pathol* 2011;20:8-14.
55. Austin SL, Proia AD, Spencer-Manzon MJ, Butany J, Wechsler SB, Kishnani PS. Cardiac Pathology in Glycogen Storage Disease Type III. *JIMD Rep* 2012;6:65-72.
56. Fellmann F, van El CG, Charron P, Michaud K, Howard HC, Boers SN, Clarke AJ, Duguet AM, Forzano F, Kaufenstein S, Kayserili H, Lucassen A, Mendes Á, Patch C, Radojkovic D, Rial-Sebbag E, Sheppard MN, Tassé AM, Temel SG, Sajantila A, Basso C, Wilde AAM, Cornel MC; on behalf of European Society of Human Genetics, European Council of Legal Medicine, European Society of Cardiology working group on myocardial and pericardial diseases, European Reference Network for rare, low prevalence and complex diseases of the heart (ERN GUARD-Heart), Association for European Cardiovascular Pathology. European recommendations integrating genetic testing into multidisciplinary management of sudden cardiac death. *Eur J Hum Genet* 2019;27:1763-773.
57. Ingles J, Semsarian C. Sudden cardiac death in the young: a clinical genetic approach. *Intern Med J* 2007;37:32-7.
58. Rodríguez-Calvo MS, Brion M, Allegue C, Concheiro L, Carracedo A. Molecular genetics of sudden cardiac death. *Forensic Sci Int* 2008;182:1-12.
59. Tester DJ, Ackerman MJ. The role of molecular autopsy in unexplained sudden cardiac death. *Curr Opin Cardiol* 2006;21:166-72.
60. Tang Y, Stahl-Herz J, Sampson BA. Molecular diagnostics of cardiovascular diseases in sudden unexplained death. *Cardiovasc Pathol* 2014;23:1-4.

61. McKenna WJ, Maron BJ, Thiene G. Classification, Epidemiology, and Global Burden of Cardiomyopathies. *Circ Res* 2017;121:722-730.
62. Burkett EL, Hershberger RE. Clinical and genetic issues in familial dilated cardiomyopathy. *J Am Coll Cardiol*. 2005;45:969-81.
63. Masarone D, Kaski JP, Pacileo G, Elliott PM, Bossone E, Day SM, Limongelli G. Epidemiology and clinical aspects of genetic cardiomyopathies. *Heart Fail Clin* 2018;14:119-28.
64. Lahrouchi N, Raju H, Lodder EM, Papatheodorou E, Ware JS, Papadakis M, Tadros R, Cole D, Skinner JR, Crawford J, Love DR, Pua CJ, Soh BY, Bhalshankar JD, Govind R, Tfelt-Hansen J, Winkel BG, van der Werf C, Wijeyeratne YD, Mellor G, Till J, Cohen MC, Tome-Esteban M, Sharma S, Wilde AAM, Cook SA, Bezzina CR, Sheppard MN, Behr ER. Utility of post-mortem genetic testing in cases of sudden arrhythmic death syndrome. *J Am Coll Cardiol* 2017;69:2134-45.
65. Renard M, Francis C, Ghosh R, Scott AF, Witmer PD, Adès LC, Andelfinger GU, Arnaud P, Boileau C, Callewaert BL, Guo D, Hanna N, Lindsay ME, Morisaki H, Morisaki T, Pachter N, Robert L, Van Laer L, Dietz HC, Loeys BL, Milewicz DM, De Backer J. Clinical Validity of Genes for Heritable Thoracic Aortic Aneurysm and Dissection. *J Am Coll Cardiol* 2018;72:605-615.
66. Sturm AC, Knowles JW, Gidding SS, Ahmad ZS, Ahmed CD, Ballantyne CM, Baum SJ, Bourbon M, Carrié A, Cuchel M, de Ferranti SD, Defesche JC, Freiburger T, Hershberger RE, Hovingh GK, Karayan L, Kastelein JJP, Kindt I, Lane SR, Leigh SE, Linton MF, Mata P, Neal WA, Nordestgaard BG, Santos RD, Harada-Shiba M, Sijbrands EJ, Stitzel NO, Yamashita S, Wilemon KA, Ledbetter DH, Rader DJ; Convened by the Familial Hypercholesterolemia Foundation. Clinical Genetic Testing for Familial Hypercholesterolemia: JACC Scientific Expert Panel. *J Am Coll Cardiol* 2018;72:662-80.

67. Wilms HR, Midgley DJ, Morrow P, Stables S, Crawford J, Skinner JR. Evaluation of autopsy and police reports in the investigation of sudden unexplained death in the young. *Forensic Sci Med Pathol* 2012;8:380-9.
68. Baudhuin LM, Leduc C, Train LJ, Avula R, Kluge ML, Kotzer KE, Lin PT, Ackerman MJ, Maleszewski JJ. Technical Advances for the Clinical Genomic Evaluation of Sudden Cardiac Death: Verification of Next-Generation Sequencing Panels for Hereditary Cardiovascular Conditions Using Formalin-Fixed Paraffin-Embedded Tissues and Dried Blood Spots. *Circ Cardiovasc Genet* 2017;10:e001844.
69. Ackerman MJ. Genetic purgatory and the cardiac channelopathies: Exposing the variants of uncertain/unknown significance issue. *Heart Rhythm* 2015;12:2325-31.
70. Richards S, Aziz N, Bale S, Bick D, Das S, Gastier-Foster J, Grody WW, Hegde M, Lyon E, Spector E, Voelkerding K, Rehm HL; ACMG Laboratory Quality Assurance Committee. Standards and guidelines for the interpretation of sequence variants: a joint consensus recommendation of the American College of Medical Genetics and Genomics and the Association for Molecular Pathology. *Genet Med* 2015;17:405-24.
71. Wain KE, Azzariti DR, Goldstein JL, Johnson AK, Krautscheid P, Lepore B, O'Daniel JM, Ritter D, Savatt JM, Riggs ER, Martin CL. Variant interpretation is a component of clinical practice among genetic counselors in multiple specialties. *Genet Med* 2020;22:785-92.
72. Knight B, Zaini MR. Pulmonary embolism and venous thrombosis. A pattern of incidence and predisposing factors over 70 years. *Am J Forensic Med Pathol* 1980;1:227-32.
73. Currie GP, Alluri R, Christie GL, Legge JS. Pneumothorax: an update. *Postgrad Med J* 2007;83:461-5.

74. Tough SC, Green FH, Paul JE, Wigle DT, Butt JC. Sudden death from asthma in 108 children and young adults. *J Asthma* 1996;33:179-88.
75. Byard RW. Esophageal causes of sudden and unexpected death. *J Forensic Sci* 2006;51:390-5.
76. Cina SJ, Mims WW 3rd, Nichols CA, Conradi SE. From emergency room to morgue: deaths due to undiagnosed perforated peptic ulcers. Report of four cases with review of the literature. *Am J Forensic Med Pathol* 1994;15:21-7.
77. Tsokos M, Braun C. Acute pancreatitis presenting as sudden, unexpected death: an autopsy-based study of 27 cases. *Am J Forensic Med Pathol* 2007;28:267-70.
78. Ng CY, Squires TJ, Busuttil A. Acute abdomen as a cause of death in sudden, unexpected deaths in the elderly. *Scott Med J* 2007;52:20-3.
79. Randall B. Fatty liver and sudden death. A review. *Hum Pathol* 1980;11:147-53.
80. Black M, Graham DI. Sudden unexplained death in adults caused by intracranial pathology. *J Clin Pathol* 2002;55:44-50.
81. Gonsoulin M, Barnard JJ, Prahlow JA. Death resulting from ruptured cerebral artery aneurysm: 219 cases. *Am J Forensic Med Pathol*. 2002;23:5-14.
82. Matsuda M, Matsuda I, Sato M, Handa J. Superior sagittal sinus thrombosis followed by subdural hematoma. *Surg Neurol* 1982;18:206-11.
83. Riudavets MA, Colegial C, Rubio A, Fowler D, Pardo C, Troncoso JC. Causes of unexpected death in patients with multiple sclerosis: a forensic study of 50 cases. *Am J Forensic Med Pathol* 2005;26:244-9.

84. Abu Al Ragheb SY, Koussous KJ, Amr SS. Intracranial neoplasms associated with sudden death: a report of seven cases and a review of the literature. *Med Sci Law* 1986;26:270-2.
85. Büttner A, Winkler PA, Eisenmenger W, Weis S. Colloid cysts of the third ventricle with fatal outcome: a report of two cases and review of the literature. *Int J Legal Med* 1997;110:260-6.
86. Lear-Kaul KC, Coughlin L, Dobersen MJ. Sudden unexpected death in epilepsy: a retrospective study. *Am J Forensic Med Pathol* 2005;26:11-7.
87. Burke MP, Opeskin K. Adrenocortical insufficiency. *Am J Forensic Med Pathol* 1999;20:60-5.
88. Preuss J, Woenckhaus C, Schwesinger G, Madea B. Non-diagnosed pheochromocytoma as a cause of sudden death in a 49-year-old man: a case report with medico-legal implications. *Forensic Sci Int* 2006;156:223-8.
89. Pumphrey RS, Roberts IS. Postmortem findings after fatal anaphylactic reactions. *J Clin Pathol* 2000;53:273-6.
90. Graham JK, Mosunjac M, Hanzlick RL, Mosunjac M. Sickle cell lung disease and sudden death: a retrospective/prospective study of 21 autopsy cases and literature review. *Am J Forensic Med Pathol* 2007;28:168-72.
91. Ruschena D, Mullen PE, Burgess P, Cordner SM, Barry-Walsh J, Drummer OH, Palmer S, Browne C, Wallace C. Sudden death in psychiatric patients. *Br J Psychiatry* 1998;172:331-6.
92. Isner JM, Roberts WC, Heymsfield SB, Yager J. Anorexia nervosa and sudden death. *Ann Intern Med* 1985;102:49-52.
93. Gettes LS. Electrolyte abnormalities underlying lethal and ventricular arrhythmias. *Circulation* 1992;85:170-6.

94. Irwin J, Cohle SD. Sudden death due to diabetic ketoacidosis. *Am J Forensic Med Pathol* 1988;9:119-21.
95. Yunginger JW, Nelson DR, Squillace DL, Jones RT, Holley KE, Hyma BA, Biedrzycki L, Sweeney KG, Sturner WQ, Schwartz LB. Laboratory investigation of deaths due to anaphylaxis. *J Forensic Sci* 1991;36:857-65.
96. Devinsky O. Sudden, unexpected death in epilepsy. *N Engl J Med* 2011;365:1801-11.
97. Kark JA, Posey DM, Schumacher HR, Ruehle CJ. Sickle-cell trait as a risk factor for sudden death in physical training. *N Engl J Med* 1987;317:781-7.
98. Langlois NE. Sudden adult death. *Forensic Sci Med Pathol*. 2009;5:210-32.
99. Hanzlick, RL. The “Value-Added” Forensic Autopsy: Public Health, Other Uses, and Relevance to Forensic Pathology’s Future. *Academic Forensic Pathology (Table 2)*. 2015; 5 (2):177-185.
100. Bell MD et al. Updating Organ Weights Using a Large Current Sample Database. *Arch Path Lab Med* doi: [10.5858/arpa.2021-0287-OA](https://doi.org/10.5858/arpa.2021-0287-OA).

Figure Legends

Figure 1: External anterior surface of the heart prior to dissection. The heart is positioned in the correct anatomic position.

Figure 2: Largest short-axis section of heart, with scale, with wall thickness measurements. The double headed arrows indicate the compact muscle to be measured for the left ventricle (LV), interventricular septum (VS) and right ventricle (RV).

Figure 3: Routine histologic sections of myocardium. Full thickness sections are taken from the anterior left ventricle (LVA), lateral left ventricle (LVL), posterior/inferior left ventricle (LVI), interventricular septum (VS), and anterior and posterior right ventricle (RV).

REFERRAL FORM

Medical Examiner/Forensic Pathologist: _____

Address:

Phone number:

Email address:

Decedent name:

Date of birth:

Date of death:

Time of death:

Case number:

Sex: Male Female

Race: White African-American/Black Hispanic/Latino

Asian/Pacific Islander Other: _____

Last known alive:

Resuscitation: Yes No

By whom:

Witnessed event: Yes No

By whom:

Primary Care Physician:

Address:

Phone number:

Scene investigation including activity at the time of collapse (eg: exercise, sleep, sudden noise, paraphernalia at the scene):

Symptoms in the hours/days prior to event:

Medical history (medications, family history (including sudden death), prior cardiac work-up (?ECG):

PERTINENT AUTOPSY FINDINGS:

Body weight:

Body length:

Additional findings:

--

Prior cardiac intervention/surgery? Yes No

Type of intervention/date:

HEART FINDINGS:

Heart weight:

Base of heart retained in formalin for possible expert review: Yes NoPericardium: Normal Abnormal: _____Tricuspid valve: Normal Abnormal: _____

Tricuspid valve circumference: _____

Right ventricle thickness (compact myocardium): _____

Pulmonic valve: Normal Abnormal: _____

Pulmonic valve circumference: _____

Mitral valve: Normal Abnormal: _____

Mitral valve circumference: _____

Mid-wall left ventricular free-wall thickness (compact myocardium): _____

Mid-wall ventricular septal thickness (compact myocardium): _____

Aortic valve: Normal Abnormal: _____

Aortic valve circumference: _____

Coronary artery dominance: _____

Coronary arteries:

Number of ostia: Normal Abnormal: _____Locations of ostia: Normal Abnormal: _____Patency: Normal Abnormal: _____

Gross findings in myocardium: _____

Gross photographs taken? Yes No

Microscopic examination findings: _____

Tissues/blood retained for molecular analysis: Yes No

Types retained: EDTA tube of blood DNA standard on filter paper Frozen myocardium (-80°C) Spleen/kidney

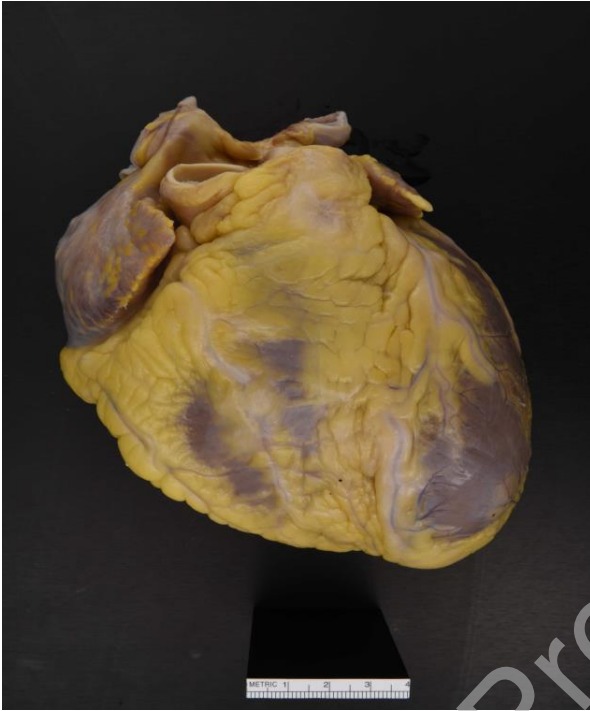


Figure 1. External anterior surface of the heart prior to dissection

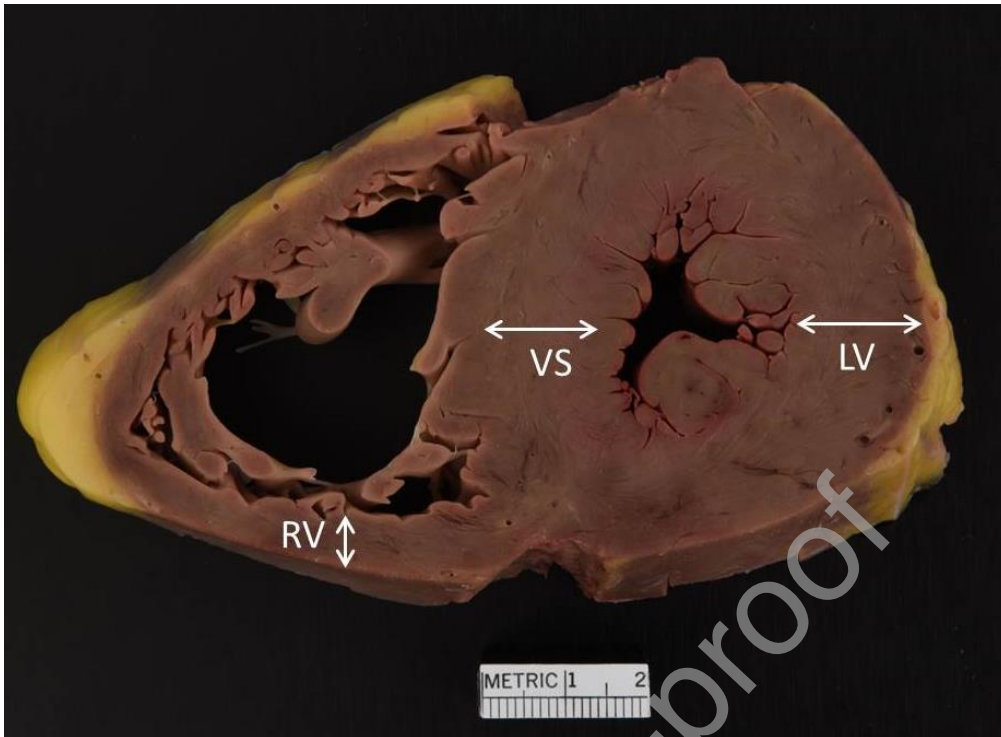


Figure 2. Largest short-axis section of heart, with scale, with wall thickness measurements

Figure 3. Routine histologic sections of myocardium

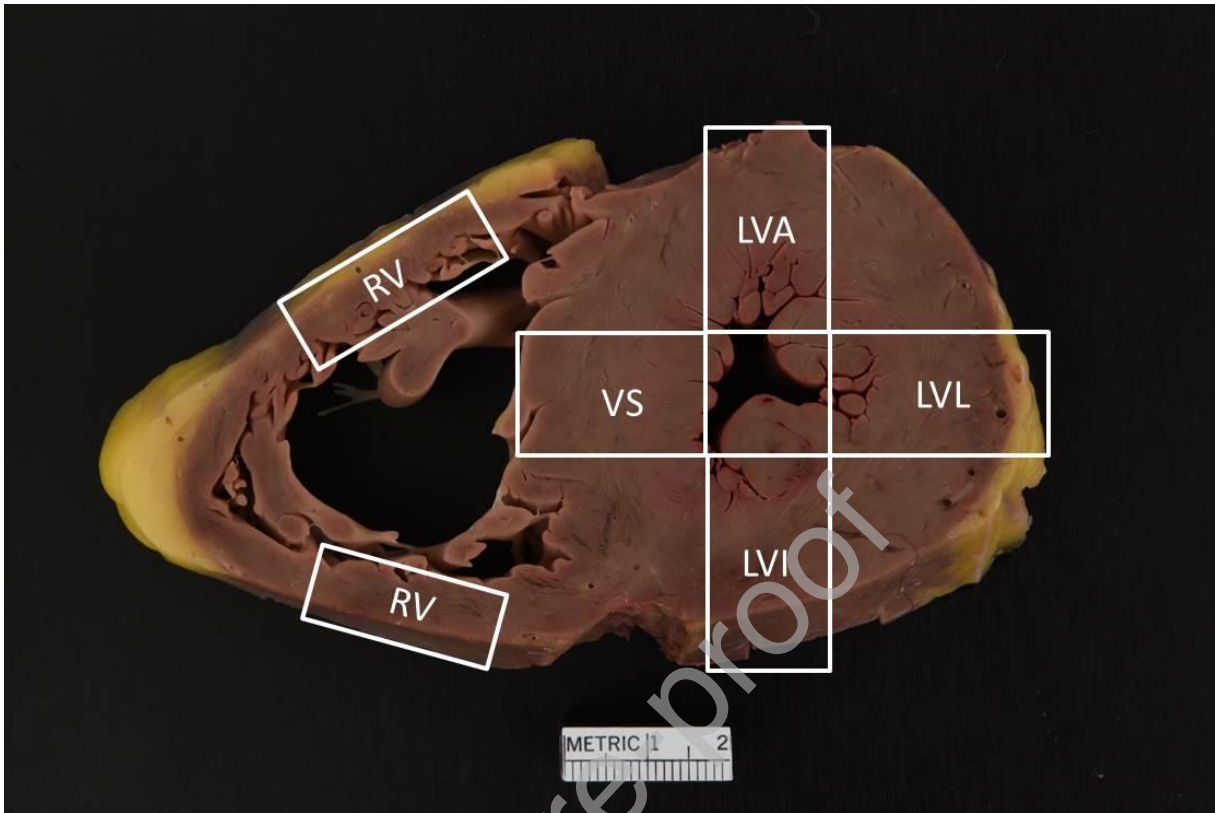


Table 1. Non-Cardiac Etiologies and Findings of Sudden Death at Autopsy⁷¹⁻⁹⁷

Neurological	Respiratory	Infectious/Miscellaneous
<ul style="list-style-type: none"> -Ruptured cerebral artery aneurysm -Hemorrhagic / ischemic stroke -Acute bacterial meningitis -Encephalitis -Colloid cyst of third ventricle -Arteriovenous malformation -Sagittal sinus thrombosis -Seizures/epilepsy -Intracranial tumors (primary and metastatic) -Multiple sclerosis 	<ul style="list-style-type: none"> -Pulmonary thromboembolism (consider genetic testing for hereditary coagulopathy, if unprovoked) -Asthma -Aspiration of foreign body -Pneumothorax -Hemorrhage (tumors, TB) -Airway obstruction 	<ul style="list-style-type: none"> -Waterhouse Friderichsen syndrome -Acute epiglottitis -Meningitis -Splenic rupture (mononucleosis) -Anaphylaxis -Electrolyte abnormalities
Gastrointestinal	Pregnancy	Metabolic/Endocrine
<ul style="list-style-type: none"> -Perforated or bleeding ulcer -Incarcerated hernia -Volvulus -Intussusception -Acute appendicitis -Acute pancreatitis -Mallory-Weiss tear -Gastroesophageal varices -Stomach rupture/necrosis 	<ul style="list-style-type: none"> -Ruptured ectopic pregnancy -Amniotic fluid embolism -Uterine rupture -Placental abruption 	<ul style="list-style-type: none"> -Diabetic ketoacidosis -Inborn error of metabolism -Addison disease -Pheochromocytoma -Thyrotoxicosis
Psychiatric	Hematologic	Non-cardiac cardiovascular
<ul style="list-style-type: none"> -Sudden death associated with schizophrenia -Eating disorders (anorexia nervosa, bulimia) 	<ul style="list-style-type: none"> -Acute leukemia -Sickle cell disease/trait 	<ul style="list-style-type: none"> -Aortic dissection (with or without rupture) -Abdominal aortic aneurysm

Table 2. Hereditary Cardiovascular Causes of Sudden Death in the Young

Diagnosis	Autopsy findings	Potential heritability
Hereditary Cardiomyopathies		
Hypertrophic cardiomyopathy	Cardiac hypertrophy; asymmetric left ventricular hypertrophy; mitral contact lesion of left ventricular outflow tract (mirror-image endocardial fibrosis of anterior mitral valve leaflet)	Hereditary disease associated with mutations in genes encoding sarcomeric proteins
Arrhythmogenic cardiomyopathy	Transmural fibrofatty infiltration of right ventricle, and subepicardial fibrofatty infiltration of left ventricle; lymphocytic infiltrates often seen on histology	Hereditary disease associated primarily with mutations in genes encoding desmosomal proteins
Dilated cardiomyopathy	Biventricular dilatation, with or without cardiac hypertrophy; no other etiology for dilatation (e.g. alcohol or other substance abuse, morbid obesity, myocarditis, previous chemotherapy, etc.); dilatation not due to decomposition artifact	Hereditary disease in 20-35% of cases associated with variety of cardiac gene mutations
Hereditary arrhythmia syndromes		
Long QT syndrome, Brugada syndrome, Catecholaminergic polymorphic ventricular tachycardia (CPVT), and others	Structurally normal heart, or only mild cardiac hypertrophy	Hereditary disease associated with mutations of genes encoding the cardiac ion channels.
Hereditary aortopathy syndromes		
Marfan, Loeys-Dietz, Ehlers Danlos IV, FTAAD, and others	Aortic dissection and rupture (usually thoracic aorta), with or without aortic dilatation, and without history of hypertension, substance abuse or trauma	Hereditary disease associated primarily with genes encoding proteins within the TGF- β pathway.

Table 3. Other Cardiovascular Autopsy Findings That May Be Associated with Sudden Cardiac Death

Diagnosis	Autopsy Findings	Strength of association with sudden cardiac death
Hypertension and atherosclerosis		
Coronary atherosclerosis/ Ischemic heart disease	Severe (>75%) stenosis of epicardial coronary artery; myocardial fibrosis, subendocardial to transmural; myocardial mottling	Strong association with sudden cardiac death. Consider familial hyperlipidemia if there is strong family history of premature coronary atherosclerosis.
Hypertensive heart disease	Increased heart weight; symmetric left ventricular hypertrophy; renal granularity	Moderate-strong association with sudden cardiac death (proportional to severity of hypertrophy)
Myocarditis		
Acute lymphocytic myocarditis	Depending on severity, gross findings may vary from no abnormality to diffuse mottling and hemorrhage; histologic findings include interstitial lymphocyte infiltration with adjacent myocyte injury (may be focal)	Strong association with sudden cardiac death if diffuse myocarditis present; weaker association with focal myocarditis, unless conduction system is involved; sparse inflammation without myocyte injury is likely incidental, though additional sampling should be considered
Giant cell myocarditis	Gross findings similar to severe acute lymphocytic myocarditis; histologic findings include prominent lymphohistiocytic infiltrate with multinucleated giant cells, and increased eosinophils	Strong association with sudden cardiac death following acute onset of heart failure
Cardiac sarcoidosis	Gross findings include infiltrative lesions of myocardium not within coronary artery distribution; histologic findings include multinucleated giant cells within a background of replacement-type fibrosis	Strong association with sudden cardiac death if cardiac conduction system is involved
Coronary artery abnormalities		
Anomalous left coronary artery arising from the pulmonary artery	Left coronary artery arises from pulmonary trunk; ischemic myocardial damage in distribution of left coronary circulation	Strong association
Anomalous coronary artery arising from wrong aortic sinus	Single coronary artery arises from wrong aortic sinus	Strong association if anomalous coronary artery runs between aorta and pulmonary artery; otherwise likely to be incidental finding
High coronary arterial origin	Coronary artery originates above sinotubular junction with a sharply angled intramural course	Possible association with sudden cardiac death; more likely if myocardial ischemia is present in distribution of coronary artery

Myocardial bridging of coronary artery	Segment of epicardial coronary artery “tunnels” into myocardium so that the coronary artery is covered by myocardium	Common, incidental finding, likely unrelated to SCD; unless myocardial ischemia is present distal to the tunneled segment
Valvular disease		
Congenital bicuspid aortic valve	Two aortic valve cusps, with non-separation of right-left cusps, right-noncoronary cusps, or left-non-coronary cusps, often with raphe, with or without calcification and fibrosis	Likely to be incidental in infants and children unless there is significant cardiac remodeling; potentially significant in adults if valve is severely calcified and stenotic
Mitral papillary muscle rupture	Disrupted mitral papillary muscle or tendinous cord; ischemic changes of mitral papillary muscle	Strong association with sudden cardiac death due to acute mitral regurgitation; cause of papillary muscle rupture may be ischemic heart disease
Myxomatous mitral valve	Rubbery thickening of mitral valve, billowing of mitral leaflets into left atrium; expanded spongiosa on histologic examination	Ruptured tendinous cord may result in acute mitral regurgitation and sudden death; myxomatous change alone unlikely to be associated with sudden cardiac death, unless severe and accompanied by atrial or ventricular dilatation/hypertrophy
Infective endocarditis	Vegetation on valve with possible perforation	Strong association with sudden cardiac death (possibly with history of indolent fever)
Mass Lesions		
Cystic tumor of atrioventricular node	Cystic lesion lined by epithelial cells within triangle of Koch (triangle between coronary sinus ostium, annulus of septal leaflet of tricuspid valve, and tendon of Tordaro)	Strong association with sudden arrhythmic death
Conduction system hamartoma (formerly, <i>histiocytoid cardiomyopathy</i>)	Gross findings may vary from no abnormality, to multifocal yellow-tan endocardial lesions, with or without dilatation or hypertrophy; Histologic findings are pathognomonic with subendocardial nests of histiocyte-like cells with foamy granular cytoplasm (Purkinje cells)	Strong association with sudden cardiac death in infants and young children
Other benign cardiac tumors (rhabdomyoma, fibroma, hamartoma of mature cardiac	Mass lesion, usually of ventricular myocardium, rhabdomyomas may be multifocal in tuberous sclerosis	Strong association with sudden cardiac death if large and likely to have been arrhythmogenic or interfered with cardiac function

myocytes, etc.)		
-----------------	--	--

Table 4. Cases in which autopsy samples for potential genetic testing should be retained

Autopsy and Investigation Findings	Genetic test to be considered
Apparently cardiac arrhythmic death, with no structural heart disease at autopsy (includes sudden unexplained infant, childhood and young adult deaths)	Consider testing for hereditary arrhythmia syndrome
Potentially hereditary cardiomyopathy found at autopsy (e.g. hypertrophic cardiomyopathy, arrhythmogenic cardiomyopathy, idiopathic dilated cardiomyopathy)	Consider testing for hereditary cardiomyopathy syndrome
Accidental drowning deaths in which no risk factors for accidental drowning were present (intoxication, poor swimming ability, unsafe conditions for swimming)	Consider testing for hereditary arrhythmia syndrome
Low-velocity motor vehicle crash deaths without significant blunt trauma or positional asphyxia	Consider testing for hereditary arrhythmia syndrome
Non-traumatic, non-status epilepticus, seizure-related deaths (SUDEP)	Consider testing for hereditary arrhythmia syndrome