

**SPECIAL ARTICLE**

## EANO—ESMO Clinical Practice Guidelines for diagnosis, treatment and follow-up of patients with brain metastasis from solid tumours<sup>☆</sup>

E. Le Rhun<sup>1,2</sup>, M. Guckenberger<sup>3</sup>, M. Smits<sup>4</sup>, R. Dummer<sup>5</sup>, T. Bachelot<sup>6</sup>, F. Sahm<sup>7</sup>, N. Galldiks<sup>8,9,10</sup>, E. de Azambuja<sup>11</sup>, A. S. Berghoff<sup>12</sup>, P. Metellus<sup>13,14</sup>, S. Peters<sup>15</sup>, Y.-K. Hong<sup>16</sup>, F. Winkler<sup>17</sup>, D. Schadendorf<sup>18,19</sup>, M. van den Bent<sup>20</sup>, J. Seoane<sup>21,22</sup>, R. Stahel<sup>23</sup>, G. Minniti<sup>24,25</sup>, P. Wesseling<sup>26,27</sup>, M. Weller<sup>2</sup> & M. Preusser<sup>12</sup>, on behalf of the EANO Executive Board and ESMO Guidelines Committee<sup>\*</sup>

Departments of <sup>1</sup>Neurosurgery and <sup>2</sup>Neurology, Clinical Neuroscience Center, University Hospital and University of Zurich, Zurich; <sup>3</sup>Department of Radiation Oncology, University Hospital Zurich and University of Zurich, Zurich, Switzerland; <sup>4</sup>Department of Radiology & Nuclear Medicine, Erasmus MC, University Medical Centre Rotterdam, Rotterdam, The Netherlands; <sup>5</sup>Department of Dermatology, University Hospital and University of Zurich, Zurich, Switzerland; <sup>6</sup>Département de Cancérologie Médicale, Centre Léon Bérard, Lyon, France; <sup>7</sup>Department of Neuropathology, University of Heidelberg and Clinical Cooperation Unit Neuropathology, German Consortium for Transnational Cancer Research (DKTK), German Cancer Research Center (DKFZ) and Hopp Children's Cancer Center, Heidelberg; <sup>8</sup>Department of Neurology, Faculty of Medicine and University Hospital Cologne, University of Cologne, Cologne; <sup>9</sup>Institute of Neuroscience and Medicine (INM-3), Research Center Juelich, Juelich; <sup>10</sup>Center of Integrated Oncology (CIO) Aachen, Bonn, Cologne and Duesseldorf, University of Cologne, Cologne, Germany; <sup>11</sup>Medical Oncology Department, Institut Jules Bordet and L'Université Libre de Bruxelles (U.L.B.), Brussels, Belgium; <sup>12</sup>Division of Oncology, Department of Medicine 1, Medical University of Vienna, Vienna, Austria; <sup>13</sup>Ramsay Santé, Hôpital Privé Clairval, Department of Neurosurgery, Marseille; <sup>14</sup>Aix-Marseille University, CNRS, INP, Neurophysiopathology Institute, Marseille, France; <sup>15</sup>Department of Oncology, University Hospital, Lausanne, Switzerland; <sup>16</sup>Department of Neurosurgery, Seoul St. Mary's Hospital, The Catholic University of Korea, Seoul, South Korea; <sup>17</sup>Neurology Clinic, Heidelberg University Medical Center, Clinical Cooperation Unit, Neuro-oncology, German Cancer Research Center, Heidelberg; <sup>18</sup>University Hospital Essen, Department of Dermatology, University of Duisburg-Essen, Essen; <sup>19</sup>German Cancer Consortium (DKTK), Partner Site Essen, Essen, Germany; <sup>20</sup>The Brain Tumor Center at Erasmus MC Cancer Institute, Rotterdam, The Netherlands; <sup>21</sup>Vall d'Hebron Institute of Oncology (VHIO), Vall d'Hebron University Hospital (HUVH), Universitat Autònoma de Barcelona. Institució Catalana de Recerca i Estudis Avançats (ICREA), Barcelona; <sup>22</sup>CIBERONC, Madrid, Spain; <sup>23</sup>Department for Medical Oncology and Hematology, University Hospital Zurich, Zurich, Switzerland; <sup>24</sup>Department of Medicine, Surgery and Neurosciences, University of Siena, Policlinico Le Scotte, Siena; <sup>25</sup>IRCCS Neuromed, Pozzilli, Italy; <sup>26</sup>Department of Pathology, Amsterdam University Medical Centers/VUmc and Brain Tumour Center, Amsterdam; <sup>27</sup>Laboratory for Childhood Cancer Pathology, Princess Máxima Center for Paediatric Oncology, Utrecht, The Netherlands; <sup>28</sup>Department of Neurology, Clinical Neuroscience Center, University Hospital and University of Zurich, Zurich, Switzerland



Available online 6 August 2021

**Key words:** central nervous system, cerebral, clinical practice, guideline, neurological, recommendations

### INTRODUCTION

The present joint European Association of Neuro-Oncology (EANO)—European Society for Medical Oncology (ESMO) recommendations for the diagnosis and treatment of parenchymal brain metastasis (BM) from solid cancers complement the first joint EANO—ESMO guideline on leptomeningeal metastasis from solid cancers.<sup>1</sup> These recommendations address BMs from solid tumours, but do not address BMs from primary brain tumours or BMs from lymphoma or leukaemia. The recommendations cover prevention, diagnosis, therapy and follow-up, but not

differential diagnosis, adverse effects of therapeutic measures or supportive or palliative care. Given the low level of evidence, the recommendations are often based on expert opinion and consensus rather than on evidence from informative clinical trials. Still, the EANO—ESMO multidisciplinary recommendations shall serve as a valuable source of information for physicians and other health care providers, as well as informed patients and relatives.

### INCIDENCE AND EPIDEMIOLOGY

Details on epidemiology and pathogenesis are covered in the [Supplementary Material](https://doi.org/10.1016/j.annonc.2021.07.016), available at <https://doi.org/10.1016/j.annonc.2021.07.016>.

### DIAGNOSIS, PATHOLOGY AND MOLECULAR BIOLOGY

#### Clinical presentation

The clinical history is commonly short with development of neurological symptoms and signs within weeks. BMs may cause headaches, epileptic seizures or motor deficits such as hemiparesis, hemisensory loss, personality changes, aphasia, visual disturbances or symptoms and signs of

<sup>\*</sup>Correspondence to: ESMO Guidelines Committee, ESMO Head Office, Via Geneva 4, 6960 Lugano, Switzerland

E-mail: [clinicalguidelines@esmo.org](mailto:clinicalguidelines@esmo.org) (ESMO Guidelines Committee).

<sup>\*</sup>EANO Office, c/o WMA GmbH, Alser Strasse 4, 1090 Vienna, Austria

E-mail: [office@eano.eu](mailto:office@eano.eu) (EANO Executive Board).

<sup>☆</sup>Note: This Guideline was developed by the European Association of Neuro-Oncology (EANO) and the European Society for Medical Oncology (ESMO). The guideline committees of the two societies nominated authors to write the guideline. This guideline was approved by the EANO Executive Board and the ESMO Guidelines Committee in August 2021.

0923-7534/© 2021 European Society for Medical Oncology. Published by Elsevier Ltd. All rights reserved.

raised intracranial pressure. The risk of epilepsy probably depends on proximity to the cortex and on the presence of tumoural haemorrhage. Focal symptoms and signs depend on BM location. Haemorrhage, typically with BMs from melanoma or chorionic carcinoma, or obstructive hydrocephalus, notably with cerebellar BMs, can cause rapid neurological deterioration. A detailed neurological examination using a standard evaluation form, e.g. as proposed by the Response Assessment in Neuro-Oncology (RANO) group,<sup>2</sup> should be carried out and documented when BMs are diagnosed and during follow-up.<sup>3</sup>

### Diagnostic procedures

**Neuroimaging at diagnosis.** New neurological symptoms and signs in a cancer patient should trigger a neurological work-up including neuroimaging to distinguish BMs from other aetiologies of neurological morbidity, notably side-effects of cancer therapy. Furthermore, subgroups of cancer patients have a high risk of BM, probably justifying screening at diagnosis of their cancer, including lung cancer in general, notably non-squamous lung cancers, with the possible exception of stage I non-small-cell lung cancer (NSCLC). Screening should also be considered in stage IV melanoma, notably because early BM diagnosis may impact clinical decision making and improve outcome. Screening at diagnosis is also potentially justified in metastatic human epidermal growth factor receptor 2 (HER2)-positive and triple-negative breast cancer [EANO: IV, n/a; ESMO: IV, B].<sup>4,5</sup> This approach will result in a higher rate of detection of asymptomatic brain metastases.

About 75% of BMs are located in the cerebral hemispheres, 21% in the cerebellum and up to 3% in the brain stem. Fewer than half of all BMs are single, i.e. there is only one brain lesion,<sup>6</sup> and very few are solitary, i.e. the only metastasis detected in the body. Cranial magnetic resonance imaging (MRI), without and with contrast agent administration carried out with at least 1.5-T field strength, is the gold standard for neuroradiological assessment of patients with suspected BMs.<sup>7</sup> The diagnostic work-up of patients with suspected BM should include at minimum cranial MRI with pre- and post-contrast T<sub>1</sub>-weighted, T<sub>2</sub>-weighted and/or T<sub>2</sub>-fluid-attenuated inversion recovery (FLAIR) and diffusion-weighted imaging (DWI) sequences [EANO III, C; ESMO IV, B]. Characteristic MRI findings include solid or ring enhancement, perifocal oedema and a predilection for the grey–white matter junction and vascular border zones. Magnetic resonance spectroscopy (MRS) as well as perfusion and DWI may offer supportive findings, such as tumour-specific metabolites, unrestricted diffusion of cystic content and low perfusion. However, there is no combination of imaging features that distinguishes BM from other pathologies with absolute certainty. Although differential diagnosis is beyond the scope of this guideline, a biopsy should be considered if lesions, notably of cystic nature, cannot be distinguished with certainty from primary brain tumours, abscesses or inflammatory lesions. The

sensitivity of MRI for the detection of BM depends on the technique employed, with influencing factors being field strength, contrast agent type and dose, delay between contrast agent administration and data acquisition and in- and through-plane resolution. Three-dimensional acquisition is preferred because of its thinner slices.<sup>8,9</sup> With double-dose contrast agent, imaging sensitivity is increased, but this comes at the cost of a decrease in specificity and should be reserved for those instances when it is essential to optimise sensitivity. There should be at least a several-minute delay between contrast agent administration and image acquisition, typically achieved by performing an additional sequence between contrast agent administration and the post-contrast T<sub>1</sub>-weighted acquisition.<sup>10,11</sup> Cranial computed tomography (CT) is markedly less sensitive than MRI for BM detection and should be limited to patients with contraindications for MRI.

Positron emission tomography using [<sup>18</sup>F]-2-fluoro-2-deoxy-D-glucose (FDG–PET) represents the most widely used tracer in extracranial oncological PET imaging and is of value in improving the accuracy of staging by detecting more extracranial metastases than CT, especially in BM patients with cancers of unknown primary (CUP).<sup>12</sup> However, the regionally high FDG uptake in the normal brain limits substantially the sensitivity of FDG–PET for BM detection.<sup>13</sup> PET using radiolabelled amino acids has an additional diagnostic value compared with anatomical MRI and is superior to FDG–PET for patients with brain tumours including BMs.<sup>13,14</sup>

**Pathology and liquid biopsies.** Details on pathology and liquid biopsies are covered in the [Supplementary Material](#), available at <https://doi.org/10.1016/j.annonc.2021.07.016>.

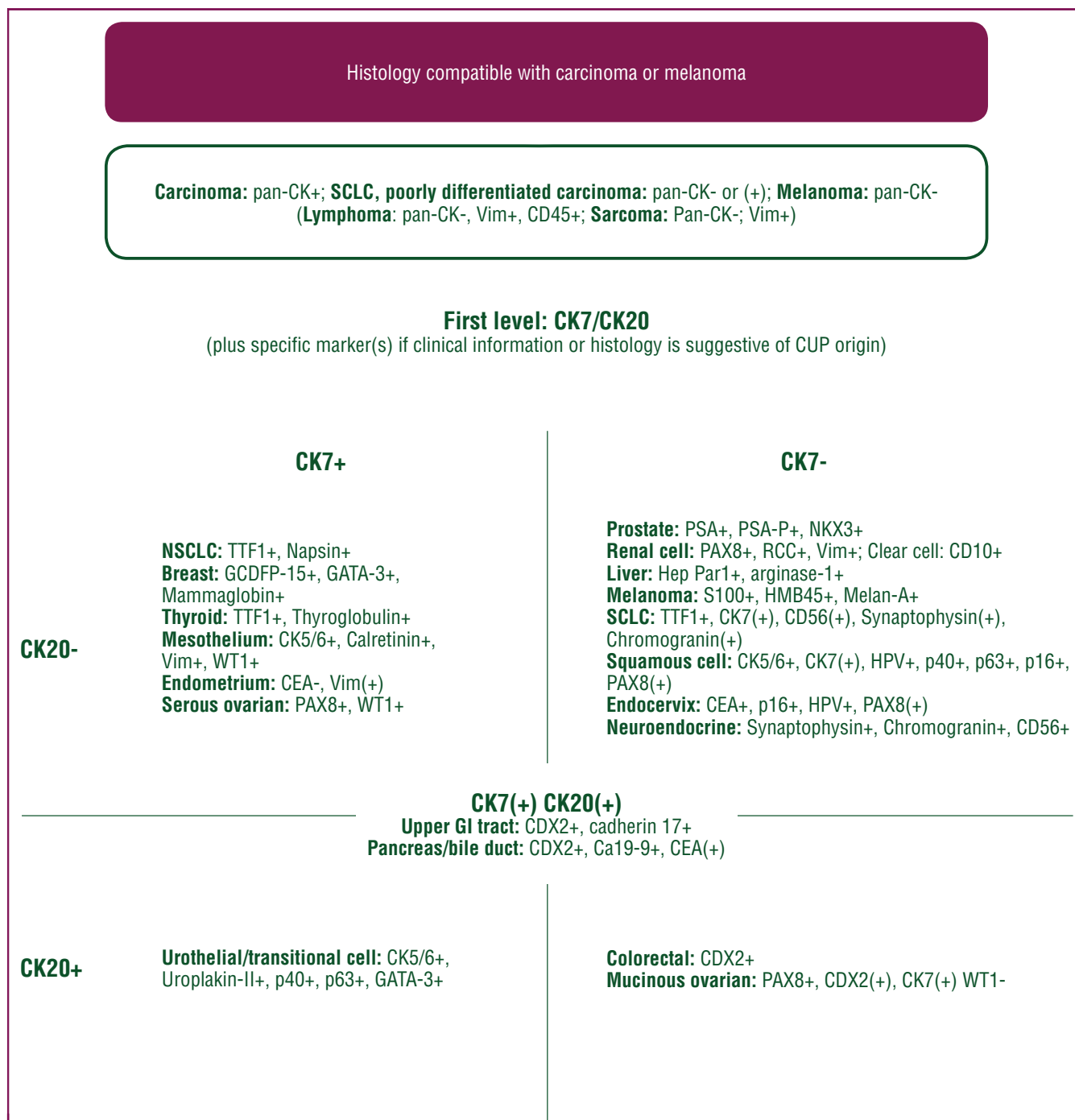
An efficient algorithm allows for identification of the source of BM in most patients ([Table 1](#) and [Figure 1](#)).

**Table 1. Predictive markers**

Entity	Molecular markers/targets
Breast	HER2, ER/PR, BRCA1/2 ('BRCAness'), PIK3CA, PD-L1
Non-small-cell lung	EGFR, ROS1, NTRK, ALK, RET, MET, KRAS, BRAF, PD-1/PD-L1
Squamous cell	FGFR1
Melanoma	BRAF, KIT, NF1, NRAS, PD-L1
Colorectal	KRAS, BRAF, NRAS, PD-L1, MSI
Upper gastrointestinal	HER2, MET
Urothelial/transitional Cell	PD-L1
Endometrium	MSI
Ovarian (serous)	ER/PR, MSI
Ovarian (mucinous)	MSI

Predictive value for treatment guidance of these markers may depend on the overall clinical setting (localisation and extent of manifestations, subsequent identification of primary) and is thus only provided for orientation.

ALK, anaplastic lymphoma kinase; EGFR, epidermal growth factor receptor; ER/PR, estrogen/progesterone receptor; FGFR1, fibroblast growth factor receptor 1; HER2, human epidermal growth factor receptor 2; MSI, microsatellite instability; NF1, neurofibromin 1; PD-1, programmed cell death protein 1; PD-L1, programmed death-ligand 1; PIK3CA, phosphatidylinositol-4,5-bisphosphate 3-kinase catalytic subunit alpha.



**Figure 1. Immunohistochemical markers for evaluation of metastatic carcinoma of unknown primary (CUP).** Typical expression profiles often greatly facilitate the identification of the tissue of origin. However, the combinations depicted here represent the most common marker profiles and various exceptions can occur (e.g. in less differentiated tumours, as is often the case for CUPs). Also, metastases of squamous cell and neuroendocrine carcinoma are particularly challenging in this respect because they often lack immunohistochemical markers indicating the tissue of origin. More recently developed diagnostic platforms such as DNA methylation, RNA or microRNA (miRNA) analysis hold great potential for the identification of the tissue of origin of CUPs but have not yet entered clinical routine. (+): tends to be positive. Ca19-9, cancer antigen 19-9; CD, cluster of differentiation; CDX, caudal type homeobox transcription factor; CEA, carcinoembryonic antigen; CK, cytokeratin; GATA-3, member 3 of transcription factor family binding to DNA sequence GATA; GCDFP, gross cystic disease fluid protein; GI, gastrointestinal; Hep Par 1, hepatocyte paraffin 1; HMB, human melanoma black; HPV, human papilloma virus; Melan-A, melanoma antigen recognised by T cells, MART1; NKX3, homeobox protein Nkx 3.1; NSCLC, non-small-cell lung carcinoma; p16/p40/p63, tumour protein 16/40/63; PAX, paired-box gene transcription factor; PSA, prostate-specific antigen; PSA-P, prostate-specific acidic phosphatase; RCC, renal cell carcinoma; SCLC, small-cell lung carcinoma; TTF, thyroid transcription factor; Vim, vimentin; WT1, Wilms tumour protein 1.

### Recommendations

- Screening for BM should be considered for patients with lung cancer with the possible exception of stage I NSCLC, and for stage IV melanoma, and potentially also for

patients with metastatic HER2-positive and triple-negative breast cancer [EANO: IV, n/a; ESMO: IV, B].

- The presence of BMs should be explored by neuroimaging in all patients with cancer who present with clinical

- symptoms or signs of raised intracranial pressure, seizures and new neurological deficits [EANO III, B; ESMO III, B].
- The diagnostic work-up of patients with suspected BM should include cranial MRI with pre- and post-contrast T1-weighted, T2-weighted and/or T2-FLAIR and diffusion-weighted sequences [EANO: III, C; ESMO: IV, B].
  - Histopathological and immunohistochemical work-up of BM should follow local institutional algorithms [EANO: IV, n/a; ESMO: V, B].
  - In patients undergoing neurosurgical resection, treatment-relevant predictive biomarkers detected in the primary tumour or extra-central nervous system (CNS) metastasis should be reconfirmed in the BM [EANO: IV, n/a; ESMO: V, B].
  - Cell-free tumour DNA in the blood or cerebrospinal fluid (CSF) analyses should not be routinely requested for the characterisation or monitoring of BM [EANO: IV, n/a; ESMO: IV, C].
  - CSF studies including cytology should be carried out to rule out leptomeningeal metastasis if suspected based on clinical or neuroimaging findings [EANO: III, C; ESMO: IV, B].

#### THERAPEUTIC STRATEGIES: GENERAL CONSIDERATIONS

For the majority of patients, the goal of treatment of BM is to prevent or delay neurological deterioration and to prolong survival with acceptable quality of life. A minority of patients, notably with small and few lesions, may experience long-term survival or even cure. Several tumour-specific approaches are commonly used in combination.

#### Surgery

**Diagnostic considerations.** Neurosurgical interventions with diagnostic intention are required in several clinical scenarios, including patients where neuroimaging leaves doubt that lesions represent BMs, where no primary tumour is known, where more than one tumour is known, where the primary tumour rarely generates BM or where changes in molecular profile compared with the primary tumour may impact clinical decision making [EANO: III, C; ESMO: IV, B]. The diagnostic value of biopsy to distinguish progression from therapy-induced changes after stereotactic radiotherapy (SRT) remains limited because active tumour- and therapy-induced changes like necrosis may coexist, but not adequately be represented in the biopsy material.

**Therapeutic considerations.** The therapeutic value of neurosurgical resection at least of single BMs in patients with controlled systemic disease remains undisputed. Extent of resection is associated with local control of BM<sup>15,16</sup> [EANO: I, A; ESMO: II, A]. *En bloc* resections may result in lower recurrence rates and lower risk of leptomeningeal dissemination than piecemeal resections.<sup>17</sup> The likelihood of gross total BM resection with low morbidity can be increased using preoperative functional

MRI, intraoperative neuronavigation, fluorescence-guided resection and cortical mapping.<sup>18-21</sup> A post-operative MRI should be carried out within 48 h after surgery to determine the extent of resection.

The randomised clinical trials that demonstrated improved survival when surgical resection was followed by whole-brain radiotherapy (WBRT), compared with WBRT alone in patients with single BMs, were conducted decades ago at a time when surgical and imaging techniques were different and when no active systemic treatments were available. These trials also commonly pooled patients with BMs from different primary tumours.<sup>22,23</sup> Extrapolating these data to modern neurosurgery has led to the assumption that similar improvements in outcome may be achieved with surgical interventions in patients with more than one BM if a gross total resection is feasible.

There are specific scenarios where surgery should be considered for its immediate therapeutic effect in patients with multiple BMs. This includes large BMs (>3 cm diameter) causing raised intracranial pressure or neurological impairment when located in eloquent brain regions. Posterior fossa location often constitutes a surgical indication because of the risk of obstructive hydrocephalus. Cystic or necrotic BMs are another indication since these may respond less well to SRT than solid BMs. Prior cyst aspiration followed by radiosurgery may also be considered.<sup>24,25</sup> Surgical resection, more than any other intervention, allows rapid steroid tapering and optimises the therapeutic efficacy of ensuing therapy, notably immune checkpoint inhibition.<sup>26</sup> Surgery is less often indicated for patients with recurrent BM, although the above-mentioned individual considerations may apply, notably if further promising systemic treatment options are available.

Laser interstitial thermal therapy is a novel intervention mostly for recurrent brain tumours as well as for radiation necrosis, with encouraging local control data,<sup>27</sup> but the definition of its role in the management of BM requires further study.<sup>28</sup>

All indications for surgical interventions in BM, except emergency situations, should be assessed for risk and benefit in a multidisciplinary tumour board since the majority of BM patients die of systemic disease and not of BM. Specifically, the role of surgery versus SRT needs to be weighted and it has to be determined which kind of molecular neuropathology work-up is required, to secure that an adequate amount and quality of tissue is obtained to maximise benefit for the patients.

#### Radiotherapy

**Stereotactic radiosurgery.** Whereas WBRT has been the historical mainstay of radiotherapy (RT) for treatment of BM, stereotactic radiosurgery (SRS) has today become the standard of care in many clinical situations. In general, SRS is defined as the delivery of high doses of radiation via stereotactic or image guidance with ~1 mm targeting accuracy to intracranial targets. It is commonly given as single fraction utilising doses between 15 and 24 Gy. Fractionated

SRS given in two to five fractions typically delivered with 27 Gy in three fractions or 30 Gy in five fractions<sup>29</sup> is preferred in patients with larger lesions (>3 cm diameter) or lesions in proximity of structures at risk, e.g. the brain stem or in pre-irradiated patients.

SRS added to WBRT improves overall survival (OS) in patients with 1-3 BMs.<sup>30</sup> SRS has been increasingly used in patients with >3 BMs. A prospective multicentre study (JLGK0901) of 1194 patients with 1-10 BMs who received SRS alone showed a similar survival of 10.8 months in patients with 2-4 versus 5-10 BMs.<sup>31</sup> Treatment-related toxicity was low, with neurocognitive function assessed by the mini-mental state examination being similar between groups when cumulative tumour volume was <15 ml.<sup>32</sup>

Because of high local recurrence rates after neurosurgical resection alone, two randomised trials evaluated SRS to the resection cavity after neurosurgical resection of BMs. Brown et al. randomised 194 patients to post-operative WBRT or SRS.<sup>33</sup> There was no difference in OS and the decline in cognitive function was more frequent after WBRT. Mahajan et al. randomised 132 patients to either post-operative SRS or observation.<sup>34</sup> Freedom from local recurrence was significantly improved by post-operative SRS. In case of larger resection cavities, a risk-adapted fractionation is encouraged where the total dose is distributed over three to five fractions.

**Whole-brain radiotherapy.** WBRT, typically 20-30 Gy in 5-10 fractions, has been used either as a consolidating treatment after local therapy or as the primary treatment modality primarily for patients with multiple BMs. WBRT after neurosurgical resection or SRS of limited BMs improved local and distant brain control, but not OS, and was associated with a detrimental effect on neurocognitive function.<sup>35-37</sup> In addition, no benefit for WBRT was demonstrated in a randomised phase III trial in melanoma patients already locally treated for one to three BMs.<sup>37</sup>

When used as initial treatment for patients with multiple BMs, WBRT is associated with a median survival of 3-6 months, with 10%-15% of BM patients alive at 1 year.<sup>38</sup> The QUARTZ trial, which randomised NSCLC patients not eligible for surgery or SRT to receive optimal supportive care or optimal supportive care plus WBRT (20 Gy in five fractions), showed similar median survival of ~9 weeks in both arms,<sup>39</sup> with no significant reduction in quality of life for patients receiving supportive care only. Yet, WBRT may still have a role for the management of patients with multiple large unresectable BMs in the context of a recent diagnosis of cancer, in younger patients and in patients in good general performance status (PS).

New WBRT-based approaches have also been evaluated in patients with multiple BMs. The simultaneous integrated boost technique allows an additional focal dose escalation in macroscopic BMs compared with WBRT alone. Radiation Therapy Oncology Group (RTOG) 0614 showed a trend towards neurocognitive protection by memantine when combined with WBRT.<sup>40</sup> The NRG CC001 trial compared WBRT plus memantine with hippocampal avoiding (HA)-

WBRT plus memantine and reported significantly preserved patient-reported quality of life and prevention of cognitive decline throughout the follow-up period.<sup>41</sup> The implications of these data for the use of memantine remain unclear because memantine alone was not active when combined with WBRT and whether it helped HA-WBRT to be active cannot be determined.

**Prophylactic cranial irradiation.** Prophylactic cranial irradiation (PCI) has been established as a standard of care in small-cell lung cancer (SCLC), both in limited<sup>42</sup> and extensive disease.<sup>43</sup> However, PCI is currently being challenged due to its toxicity in extensive-stage SCLC by the introduction of serial MRI-based follow-up<sup>44,45</sup> and immune checkpoint inhibition.<sup>46</sup> A randomised phase III trial showed no lower probability of cognitive decline in patients treated with PCI associated with hippocampal avoidance when compared to standard PCI. No difference in incidence rate of BM at 2 years or in survival was observed either.<sup>47</sup> Hippocampal sparing can thus not be considered standard of care in this setting.

### Pharmacotherapy

Most BMs exhibit uptake of contrast on MRI or CT and are thus characterised by the lack of a functional blood-brain barrier. Intravenously (i.v.) administered drugs are predicted to distribute in the same way as i.v. administered contrast agents for neuroimaging, suggesting that systemic pharmacotherapy could be as efficient for contrast-enhancing BMs as for other systemic tumour manifestations. However, to what extent uptake of a gadolinium-based contrast agent truly allows prediction of adequate penetration of larger molecules (like monoclonal antibodies or antibody-drug conjugates) remains uncertain. The choice of agent is primarily determined by histological and molecular tumour type and not by the metastasis location in the brain. If feasible, molecular genetic work-up of BMs rather than primary tumour should be considered for selecting targeted therapy and immunotherapy in a tumour-specific manner [EANO: IV, C; ESMO: IV, B]. Drugs with better blood-brain barrier penetration are predicted to provide superior tumour control, notably in tumour areas that are partially protected by the blood-brain barrier. Previous lines of treatment should also be considered in the decision making. In the situations of multiple systemic treatment options, CNS and extra-CNS disease activity as well as toxicity profile of the respective treatment options should be considered in the decision-making process for the optimal systemic treatment strategy [EANO: IV, A; ESMO: IV, B].

Preliminary evidence suggests that steroid use has a negative impact on outcome of immunotherapy in BM patients.<sup>48</sup>

**BM from breast cancer.** Systemic therapy plays an important role in the control of BM from breast cancer. Different drugs have been used for the treatment of BM including classical chemotherapy agents such as capecitabine,

cyclophosphamide, 5-fluorouracil, methotrexate, vincristine, cisplatin, etoposide, vinorelbine and gemcitabine, most of them with response rates >30%.

Patients with BM from HER2-positive metastatic breast cancer are particularly likely to benefit from targeted therapy. In patients without neurosurgical indication and with preserved neurological status (PS 0-2), previously treated with trastuzumab but capecitabine–lapatinib-naïve, the combination of lapatinib and capecitabine produced a brain response rate of 38% in patients with pre-irradiated BM and of 66% in patients with treatment-naïve BM.<sup>49,50</sup> The NALA study compared neratinib plus capecitabine to lapatinib plus capecitabine in second/third line. One hundred and thirty patients had asymptomatic and stable BM at study entry and ‘overall cumulative incidence’ of intervention for BM (mostly RT) was decreased from 29% to 23% in the neratinib arm ( $P = 0.04$ ).<sup>51</sup> The combination of neratinib and capecitabine showed a control rate approaching 50% (22 partial response, 16 stable disease) for patients with BM pre-treated with any combination of surgery and RT and with a stable steroid dose who had received mainly more than two lines of systemic treatment in a phase II study.<sup>52</sup> A secondary analysis of the second-line EMILIA study evaluating trastuzumab emtansine (T-DM1) in patients previously treated with trastuzumab and a taxane was carried out on patients retrospectively identified with asymptomatic CNS metastases ( $n = 95$ ). This analysis showed an improved OS in the T-DM1 group compared with the lapatinib and capecitabine group (median, 26.8 months,  $n = 45$  versus 12.9 months,  $n = 50$ ).<sup>53</sup> A retrospective analysis of T-DM1 in BM breast cancer patients, including 92% of patients pre-treated with local treatment, showed a response rate of up to 44%.<sup>54</sup> The combination of tucatinib, capecitabine and trastuzumab was tested in a third-line phase III trial with half of the patients presenting with BM (HER2CLIMB). In the sub-analysis among the 291 patients with BM, median OS was significantly prolonged in the tucatinib combination group compared with the trastuzumab and capecitabine combination group (18.1 versus 12.0 months).<sup>55</sup> Few studies have specifically assessed systemic therapy for BM from HER2-negative luminal or triple-negative breast cancer. Abemaciclib showed an intracranial clinical benefit rate defined as complete response plus partial response plus stable disease persisting for  $\geq 6$  months of 25% and a median progression-free survival (PFS) of 4.4 months in heavily pre-treated patients with BM from estrogen receptor-positive/HER2-negative breast cancer.<sup>56</sup>

Prevention of BM by systemic treatment is an emerging topic in the management of breast cancer. In the CLEOPATRA study, patients did not have BM at diagnosis but 13% relapsed in the brain at first recurrence. In this subpopulation, median time to develop BM was increased from 12 to 15 months with the addition of pertuzumab to trastuzumab and docetaxel.<sup>57</sup> The CEREBEL study did not show that the combination of lapatinib and capecitabine was more efficient than trastuzumab plus capecitabine for BM prevention in the first-line or second-line setting.<sup>58</sup>

**BM from lung cancer.** For patients with advanced NSCLC without actionable oncogenic driver alterations, monotherapy with anti-programmed cell death protein 1 (PD-1) or programmed death-ligand 1 (PD-L1) immune checkpoint inhibitors in case of PD-L1 positivity (>50%) or combination of immune checkpoint inhibition with platinum-based combination chemotherapy has become standard of care. Further combination immunotherapies, including cytotoxic T-lymphocyte-associated protein 4 (CTLA-4) inhibition, with or without chemotherapy, have recently reached clinical practice.<sup>59,60</sup> Only scarce data are available regarding the role of immune checkpoint inhibition specifically in the treatment of asymptomatic BM. Early data suggested that pembrolizumab is safe and effective for untreated NSCLC BMs with CNS response rates in the range of 30%.<sup>61</sup> The efficacy of nivolumab has been retrospectively confirmed in NSCLC patients with asymptomatic BMs.<sup>62</sup> Subgroup analyses from combination trials using anti-PD-1 and anti-CTLA-4, with or without chemotherapy, suggest a significant efficacy against BMs, with similar benefit irrespective of the presence of CNS lesions.<sup>63</sup> Most immunotherapy trials have only enrolled patients with controlled and treated, e.g. with RT, BMs, and the lack of prospective data limits the level of evidence for immunotherapy in the management of asymptomatic BM. A multicentre pooled analysis reported immunotherapy efficacy in a variety of settings. Among patients with ‘active’ BM ( $n = 73$ ), the intracranial response rate was 27.3%.<sup>64</sup>

NSCLC patients with oncogenic driver alterations such as epidermal growth factor receptor (*EGFR*) mutation and anaplastic lymphoma kinase (*ALK*), c-ros oncogene 1 (*ROS1*) or Ret proto-oncogene (*RET*) rearrangements are characterised by a higher cumulative incidence of BM than those without driver oncogenes. These patients achieve favourable median survival times of >3 years in *EGFR*-mutated NSCLC<sup>65</sup> and >5 years with *ALK* rearrangement.<sup>66</sup> Tyrosine kinase inhibitors (TKIs) have thus become a standard treatment component of the multimodality management because of increased response rates for extracranial as well as intracranial metastases compared with classical chemotherapy. CNS response rates are influenced by the potency of the TKIs as well as their blood–brain barrier penetration, including their specific P-glycoprotein interaction.<sup>67</sup> Specific TKIs have shown significant CNS activity, notably in the presence of *EGFR* mutations as well as *ALK*, *ROS1*, *RET*, neurotrophic tyrosine receptor kinase (*NTRK*), Neuregulin 1 (*NRG1*) rearrangements, as well as exon 14 skipping mutations of *MET*, also called tyrosine-protein kinase Met or hepatocyte growth factor receptor. Only limited data are available regarding targeted therapy for *KRAS* G12C and *BRAF* mutations.

The standard of care for patients with extensive SCLC disease is based on platinum and etoposide combination chemotherapy together with immune checkpoint inhibition,<sup>46</sup> [EANO: II, B; ESMO: II, B]. The added value of immune checkpoint inhibition remains to be formally demonstrated in SCLC patients with brain metastases, with or without symptoms or dedicated local treatment.

**BM from melanoma.** Systemic chemotherapy using classical agents such as temozolomide, dacarbazine or fotemustine has only limited efficacy in melanoma patients with BM.<sup>68</sup> Monotherapy using the BRAF inhibitors vemurafenib or dabrafenib in *BRAF*-mutated patients with melanoma BM achieved intracranial response rates between 15% and 40%;<sup>69-71</sup> and improved intracranial response rates up to 60% were observed with the combination of vemurafenib and dabrafenib in asymptomatic untreated BM, similar to the response rate in other organ sites with, however, overall short duration of response.<sup>72</sup> Anti-PD-1 monotherapy or ipilimumab plus nivolumab has been investigated in patients with BM: in patients with asymptomatic BM, current data favour the combination with an overall response rate of ~50%,<sup>73,74</sup> reasonable response duration and PFS of >50% at 18 months. However, the inclusion criteria in these trials were stringent resulting in asymptomatic or oligosymptomatic patient populations with low CNS tumour burden. Based on these data, ipilimumab–nivolumab combination therapy is the preferred first-line treatment also in *BRAF*-mutated asymptomatic patients with BMs [EANO: II, B; ESMO: II, B]. Importantly, efficacy of ipilimumab–nivolumab combination seems to be lower in patients with symptomatic BM requiring steroids with 21%<sup>74</sup> intracranial response rates.

## Recommendations

### Surgery

- Surgery should be considered when there is doubt on the neoplastic nature of a brain lesion, when no primary tumour is known, when more than one tumour is known, when the primary tumour rarely generates BM or when changes in molecular profile compared with the primary tumour may impact clinical decision making [EANO: III, C; ESMO: IV, B].
- Single BMs should be considered for surgical resection [EANO: I, A; ESMO: II, A].
- Multiple resectable BMs may be considered for surgical resection [EANO: IV, C; ESMO: V, C].
- Surgery may be considered for patients requiring steroids, who are candidates for immune checkpoint inhibition [EANO: III, n/a; ESMO: IV, B].
- Surgery should be considered when there are acute symptoms of raised intracranial pressure [EANO: III, C; ESMO: IV, B].
- A post-operative MRI should be carried out within 48 h after surgery to determine the extent of resection [EANO: IV, C; ESMO: V, C].

### Radiotherapy

- SRS is recommended for patients with a limited number (1-4) of BMs [EANO: I, A; ESMO: I, A].
- SRS may be considered for patients with a higher number of BMs (5-10) with a cumulative tumour volume <15 ml [EANO: II, B; ESMO: II, B].
- SRS to the resection cavity is recommended after complete or incomplete resection of BMs [EANO: I, A; ESMO: I, A].

- Post-operative WBRT after neurosurgical resection or after SRS should be discouraged [EANO: I, A; ESMO: I, E].
- WBRT should be considered for treatment of multiple BMs not amenable to SRS, depending on the presence of neurological symptoms, size, number and location of BMs and the choice and availability of CNS-active systemic therapy [EANO: III, B; ESMO: III, B].
- Supportive care with omission of WBRT should be considered in patients with multiple BMs not eligible for SRS and poor PS [EANO: I, B; ESMO: I, B].
- Despite scepticism, PCI is still recommended for patients with limited and extensive-stage SCLC with complete response to chemoradiotherapy [EANO: I, A; ESMO: I, A].

### Pharmacotherapy

- Systemic pharmacotherapy based on histological and molecular characteristics of the primary tumour and previous treatment should be considered for most patients with BMs [EANO: IV, n/a; ESMO: IV, B].
- If feasible, molecular genetic work-up of BMs rather than primary tumour should be considered for selecting targeted therapy and immunotherapy in a tumour-specific manner [EANO: IV, C; ESMO: IV, B].
- Systemic treatment of asymptomatic or oligosymptomatic BMs should be considered to delay WBRT in HER2-positive breast cancer patients with a preserved general status [EANO: III, C; ESMO: III, B].
- For HER2-negative breast cancer patients with progressive BM after local treatment, standard chemotherapy, such as capecitabine, eribulin or carboplatin and bevacizumab, may be considered [EANO: III, C; ESMO: III, B].
- Patients with NSCLC without actionable oncogenic driver alterations with asymptomatic or oligosymptomatic BM should be treated by upfront immune checkpoint inhibition alone (PD-L1 ≥50%) or systemic chemotherapy combined with immune checkpoint inhibition (PD-L1 <50%) [EANO: II, B; ESMO: III, B].
- Patients with NSCLC with actionable oncogenic driver alterations such as *EGFR* or *ALK* or *ROS1* rearrangement and asymptomatic or oligosymptomatic BM should be treated by upfront systemic targeted therapy [EANO: II, B; ESMO: III, B].
- Patients with SCLC should be treated by platinum-based chemotherapy without or with immune checkpoint inhibition [EANO: II, B; ESMO: II, B].
- The combination of ipilimumab and nivolumab should be the preferred first-line treatment option not only in *BRAF* wild-type, but also in *BRAF*-mutated asymptomatic patients [EANO: II, B; ESMO: II, B].
- Patients with multiple symptomatic *BRAF*-mutated BMs or patients requiring 4 mg dexamethasone or more eligible for further treatment should receive dabrafenib plus trametinib [EANO: IV, B; ESMO: IV, B].

## INTEGRATED THERAPEUTIC APPROACHES

The best combination of the different therapeutic approaches should be identified according to the general and

neurological status, comorbidities, neuroimaging findings, histology and molecular status of the primary tumours (if possible updated) and previous treatments (Figure 2). The multimodality treatment of BMs requires a careful individualised estimation of the different contributions from surgery, radiation oncology and medical oncology. Ideally, therapeutic decisions should be discussed at a dedicated BM board or at a disease-specific tumour board with participation of colleagues experienced in the management of CNS tumours [EANO: IV, n/a; ESMO: V, B].

To obtain local control, surgery and SRT can be competitive as well as complementary approaches. The role of WBRT is declining, considering the modest benefit–risk ratio and the development of SRS. The following factors favour neurosurgical resection: unknown primary tumour, neuroradiologically uncertain lesion, large cystic or necrotic lesion, need for high-dose steroids, mass effect and need for molecular profiling to guide clinical decision making. Factors favouring SRS alone over surgery commonly followed by SRS or systemic therapy include a surgically less accessible location, increased surgical risk and preference for a non-invasive outpatient treatment.

Systemic therapy should primarily follow the histology and molecular characteristics of the primary tumour and prior treatment.

In the specific case of BM from cancer of unknown primary tumour (BM-CUP), after extensive diagnostic work-up including notably PET, no data from controlled trials are available. Surgical resection should be followed by RT of the cavity, but not by any tumour-agnostic systemic treatment in the absence of further tumour manifestations unless an actionable driver mutation is detected.

When combining systemic pharmacotherapy and RT, the risk of adverse events should be considered for each new drug, e.g. BRAF inhibitors and WBRT cause severe dermatitis that is usually managed by avoiding concomitant treatment.<sup>75</sup>

For patients with asymptomatic or oligosymptomatic BM, no prospective trials have addressed the question of optimal combined modality treatment with systemic therapy, including TKI or immune checkpoint inhibition, and surgery or SRS. Such a trial would have to consider survival endpoints as well as quality of life including neurocognitive endpoints.

In breast cancer, no study has defined the best timing of systemic treatment and RT combinations and most of the trials focus on the role of systemic pharmacotherapy alone. In NSCLC patients without activating driver mutations and limited asymptomatic BM, systematic meta-analysis of mostly uncontrolled data suggests improved OS after early combination of immune checkpoint inhibitors and SRS compared with a sequential approach.<sup>76</sup> For NSCLC with activating *EGFR* mutations, several retrospective studies, including mainly studies on first-generation EGFR inhibitors characterised by a poor CNS tumour penetration, also suggest that the best survival may be achieved with combined upfront TKI and SRT compared with a sequential strategy.<sup>77–79</sup> Adequately designed controlled clinical trials are required to determine whether novel, potent brain-

penetrant TKIs, including the third-generation TKI osimertinib, can obviate the need for early SRS. Fewer data are available about optimal sequencing of TKI and local therapy in patients with *ALK* translocations where several potent CNS-penetrating compounds are available. However, there is widespread consensus that upfront WBRT should not be delivered in patients with *EGFR* mutation or *ALK* translocation. In case of BM from SCLC, the decision to add SRS or WBRT and the timing of such interventions depend on symptoms and disease burden. Replacement of WBRT by SRS appears to compromise time to progression in the CNS, but not OS.<sup>80</sup> Although melanoma is known as a radio-resistant tumour, durable local control may be achieved after SRS.<sup>81</sup> The optimal timing of SRT in the multimodal therapeutic approach to BM from melanoma remains to be determined, although data from uncontrolled cohort studies also support early combination.<sup>82</sup>

Data from randomised trials to confirm the superiority of initial combined modality treatment have not been published. To what extent patient selection introduced bias into the published cohort studies suggesting superiority of combined modality treatment remains controversial. For patients with symptomatic BM, systemic therapy is also considered, but commonly not as a single modality treatment.

Once progression of BMs has been diagnosed using appropriate imaging examinations or tissue analysis, further treatment options should ideally be discussed in a multidisciplinary board (Figure 2). On an individual case-by-case consideration, surgery, (repeat) SRS, change of systemic treatment and combinations thereof may be considered.

Randomised trials in the BM population are needed to confirm the optimal timing of the different interventions, e.g. surgery before immunotherapy, SRS at BM diagnosis concomitant with systemic pharmacotherapy or at progression. Considering the high unmet need, enrolment into trials should be considered whenever possible.

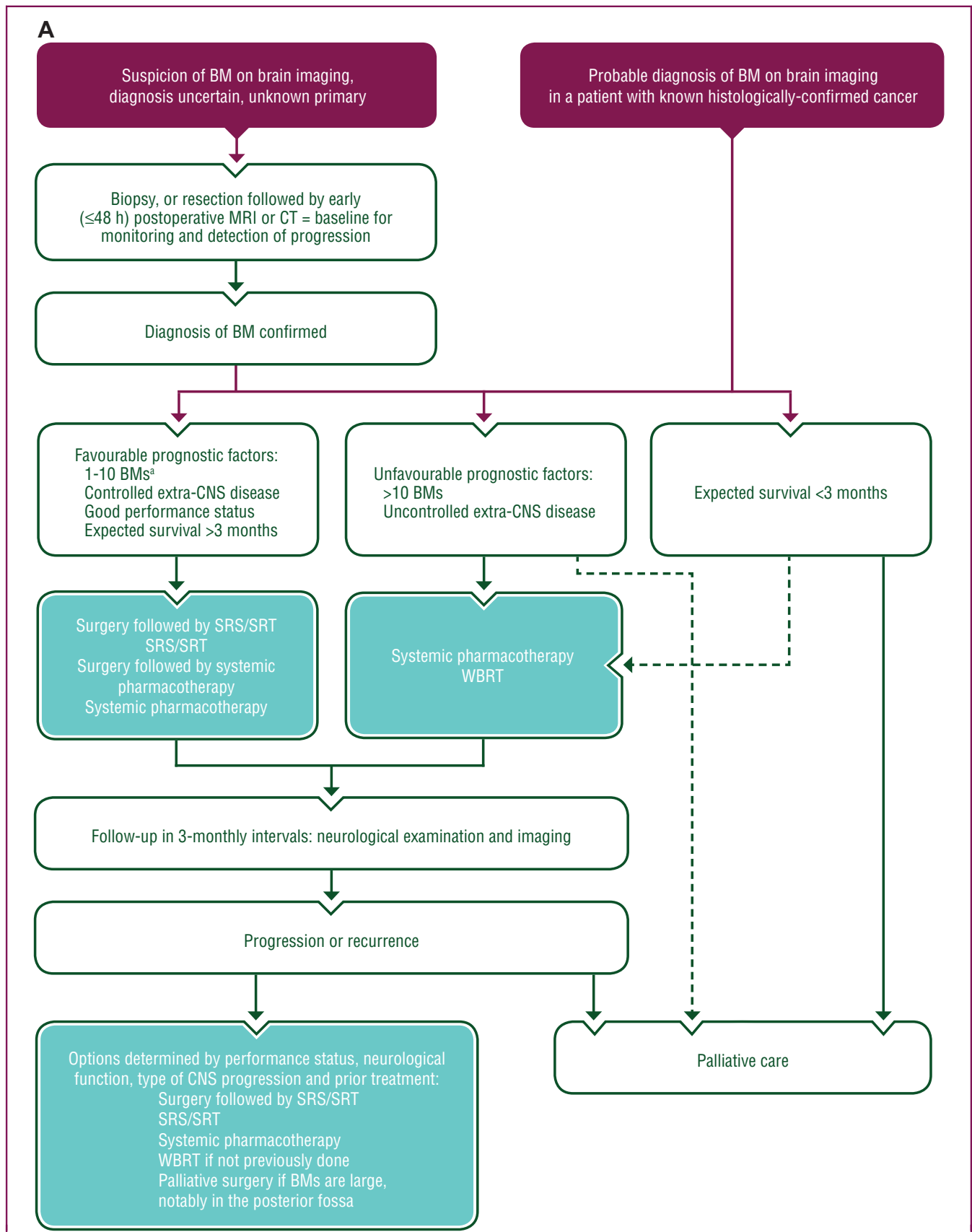
### Recommendations

- The multimodality treatment of BMs should be based on a careful individualised estimation of the different contributions from surgery, radiation oncology and medical oncology [EANO: IV, n/a; ESMO: V, B].
- Ideally, therapeutic decisions should be discussed at a dedicated BM board or at a disease-specific tumour board with participation of colleagues experienced in the management of CNS tumours [EANO: IV, n/a; ESMO: V, B].
- Randomised trials in patients with asymptomatic or oligosymptomatic BM should be conducted to identify the optimal combined modality treatment of systemic therapy, including TKI or immune checkpoint inhibition, with surgery or SRS [EANO: IV, n/a; ESMO: V, B].

### MONITORING AND FOLLOW-UP

Patients with a history of BM should be followed up by neurological assessment and neuroimaging in 3-monthly





**Figure 2. Proposed combination of the different therapeutic approaches for patients diagnosed with BM.**

(A) In general. (B) For SCLC patients. (C) For melanoma patients.

Purple: general categories or stratification; blue: systemic anticancer therapy; turquoise: combination of treatments or other systemic treatments; white: other aspects of management. Straight line: preferred option; dotted line, alternative option.

BM, brain metastasis; CNS, central nervous system; CT, computed tomography, GI, gastrointestinal; mucin, mucinous; MRI, magnetic resonance imaging; PCI, prophylactic cranial irradiation; SCLC, small-cell lung cancer; SRS, stereotactic radiosurgery; SRT, stereotactic radiotherapy; WBRT, whole-brain radiotherapy.

<sup>a</sup> Depending on the total volume of BM.

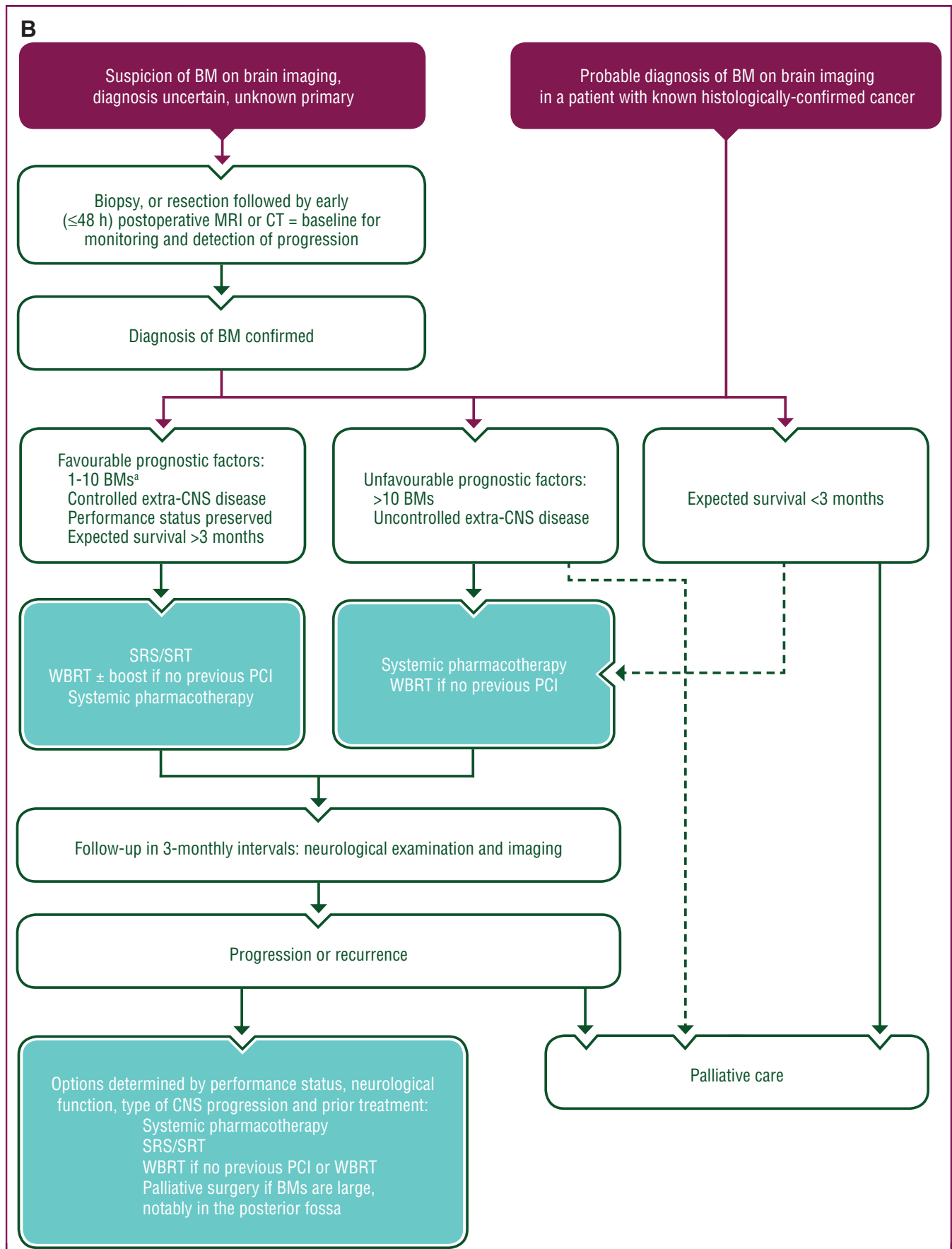


Figure 2. Continued.

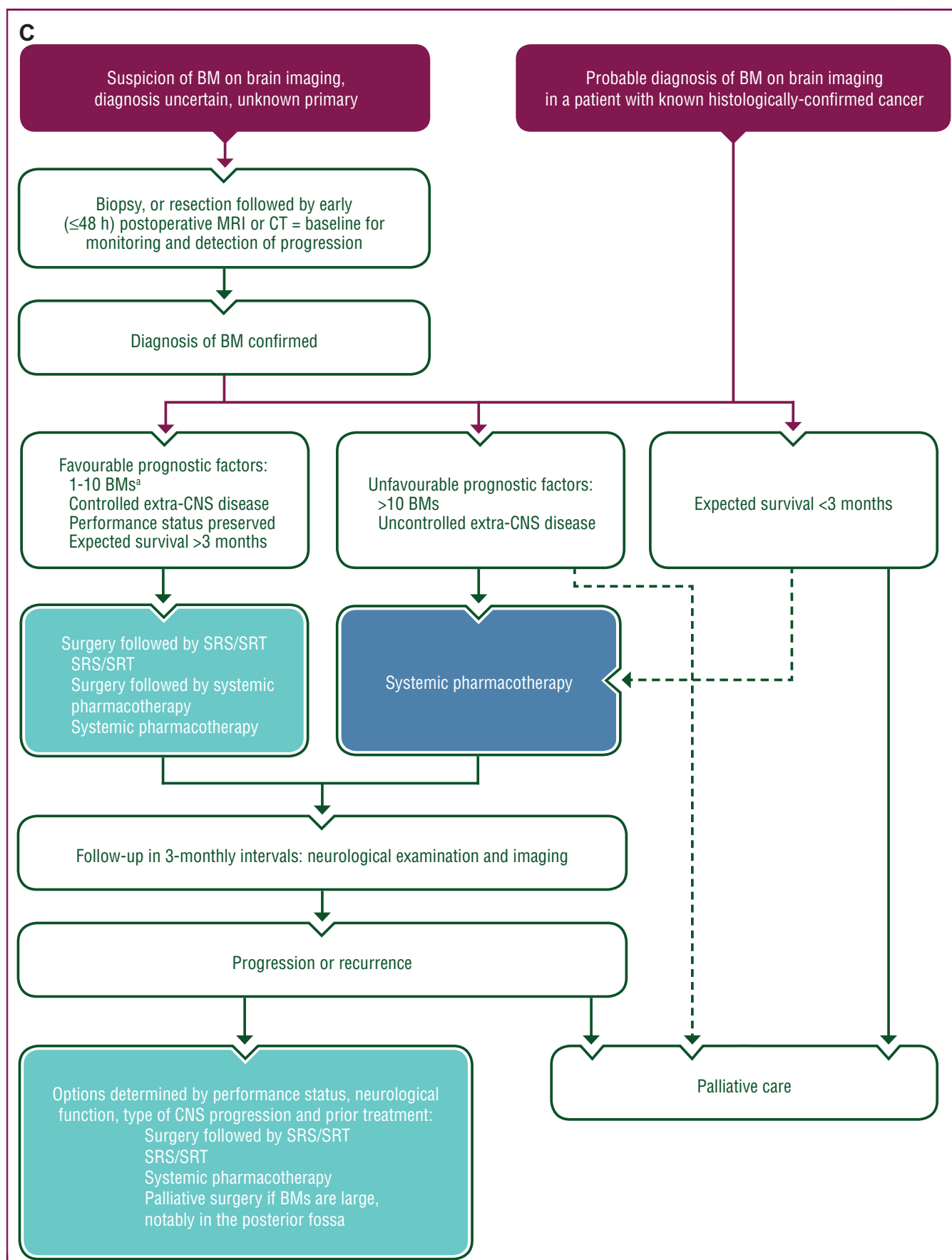


Figure 2. Continued.

intervals and whenever clinically indicated. The evaluation of response to treatment in clinical trials on BM is increasingly based on RANO criteria, which consider changes in target and non-target lesions on conventional contrast-enhanced MRI, neurological status and steroid use,<sup>83</sup> and such criteria are also increasingly used in clinical practice.

The neurological status should be regularly documented using a standardised procedure, e.g. the neurologic assessment in neuro-oncology scale.<sup>2</sup> Cognitive function should be assessed at baseline and in the course of disease and ability to consent should regularly be re-evaluated [EANO: IV, n/a; ESMO: V, B]. Brain MRI should be carried out every 2-3 months or at any instance of suspected neurological progression [EANO: IV, n/a; ESMO: V, B]. MRI is the standard method for response assessment and follow-up.<sup>83</sup> The MRI should be repeated on the same device or at least a device with an identical field strength. However, conventional MRI may not always reliably distinguish between treatment-related abnormalities, notably pseudo-progression, radionecrosis and tumour progression. Perfusion MRI and MRI spectroscopy are increasingly used in this setting, but evidence for their ability to aid in differential diagnosis remains low.<sup>84-86</sup>

Amino acid PET tracers such as [<sup>11</sup>C]-methyl-L-methionine, 3,4-dihydroxy-6-[<sup>18</sup>F]-fluoro-L-phenylalanine or O-(2-[<sup>18</sup>F]fluoroethyl)-L-tyrosine (FET) have been most frequently evaluated for the differentiation of BM relapse from radiation injury following RT. Across all these amino acid PET tracers, both the sensitivity and specificity for correct differentiation are in the range of 80%-90%.<sup>87</sup> Furthermore, amino acid PET using FET is also of value for the diagnosis of treatment-related changes following immunotherapy, using immune checkpoint inhibitors or targeted therapy, with or without RT [EANO III, C; ESMO IV, C].<sup>88</sup>

The immunotherapy RANO criteria<sup>89</sup> have been designed to assess delayed responses and prevent that progression is assumed too early in patients treated with immunotherapy, as long-term survival and tumour regression can occur following initial progression in these patients. The rate of pseudoprogression with immunotherapy alone appears to be low. Further studies are required to determine how to distinguish treatment-related changes from progression after SRT with or without systemic therapy.<sup>82</sup> For BM patients, whose primary tumour is still unknown after a first work-up at diagnosis, whole-body FDG-PET in the follow-up may be useful.

Liquid biopsies assessing circulating tumour cells or cell-free DNA in blood or CSF have not yet been integrated into the response assessment and follow-up of BM patients.<sup>90</sup>

### Recommendations

- A detailed neurological examination should be carried out every 2-3 months or earlier when radiological progression is suspected and/or neurological symptoms or signs develop [EANO: IV, n/a; ESMO: V, B].

- Neurocognitive function and ability to consent should be regularly assessed [EANO: IV, n/a; ESMO: IV, B].
- Brain MRI should be carried out every 2-3 months or at any instance of suspected neurological progression [EANO: IV, C; ESMO: IV, B].
- Advanced MRI techniques, such as MRS and perfusion imaging and amino acid PET, should be considered for distinguishing treatment-related changes from tumour progression [EANO: III, C; ESMO: IV, C].

### SUPPORTIVE CARE

This guideline does not aim to comprehensively describe palliative and supportive care for BM patients. Therefore, general considerations for brain tumour patients apply.<sup>91</sup> When required clinically for control of raised intracranial pressure, the lowest dose of steroids should be used for the shortest time possible [EANO: IV, n/a; ESMO: IV, B]. The risk of *Pneumocystis jirovecii* pneumonia is increased in patients treated with steroids for more than a few weeks, and prophylaxis with trimethoprim-sulfamethoxazole should be considered in such circumstances if additional immunosuppressive systemic therapy is administered. Bevacizumab is probably the best agent for the treatment of radionecrosis after SRT.<sup>92</sup> It exhibits superior activity compared with steroids and does probably not interfere with the efficacy of immunotherapy. Patients who experienced a seizure should receive secondary anticonvulsant prophylaxis, at least transiently. Primary prophylaxis is not recommended because it has not been shown to be effective in preventing a first-ever seizure [EANO: I, A; ESMO: I, A]. Seizures should be managed with anticonvulsant drugs that do not exhibit drug-drug interactions, e.g. levetiracetam, lamotrigine and lacosamide are preferred over phenytoin, carbamazepine or valproic acid. Primary thromboprophylaxis should be considered in patients hospitalised for an acute illness or who are confined to bed. Low-molecular-weight heparin (LMWH) or unfractionated heparin is recommended for primary prophylaxis as well as for the treatment of venous thromboembolism (VTE) [EANO: II, B; ESMO: II, C]. Risk factors for thromboembolic events in BM patients include specific primary tumours, steroid use, administration of chemotherapy, high body mass index and immobilisation. The risk of intracranial bleeding is probably not increased in BM patients in general treated with therapeutic doses of LMWH. Other risk factors of bleeding should be considered. Data on direct oral anticoagulants in BM patients are lacking.

### Recommendations

- Steroids should only be considered in symptomatic patients [EANO: IV, n/a; ESMO: IV, B].
- Primary anticonvulsant prophylaxis should not be given [EANO: I, A; ESMO: I, A].
- If indicated, LMWH should be considered as the first-line treatment for primary or secondary thromboprophylaxis and for the therapeutic treatment of VTE in BM patients [EANO: II, B; ESMO: II, C].

- Decisions on the competency to drive should take into account epilepsy but also cognitive and other neurological functions and need to adhere to national guidelines and law [EANO: IV, n/a; ESMO: V, n/a].

## OUTLOOK

Guidelines reflect knowledge and consensus at a given timepoint. Updates on these recommendations will be announced on the websites of EANO ([www.eano.org](http://www.eano.org)) and ESMO ([www.esmo.org](http://www.esmo.org)). Conclusions derived from secondary analyses on patients with BM defined as 'active' or 'inactive', which are poorly defined concepts, are not suitable to derive treatment algorithms. Dedicated trials for BM patients based on well-defined diagnostic and inclusion criteria, ideally enriched for molecular genetic signatures where feasible and with adequate criteria of evaluation, are required to improve the outcome of BM in a primary cancer-specific manner.

## METHODOLOGY

This Clinical Practice Guideline was developed in accordance with the ESMO standard operating procedures for Clinical Practice Guidelines development (<http://www.esmo.org/Guidelines/ESMO-Guidelines-Methodology>). The relevant literature has been selected by the expert authors. References were identified through searches of PubMed with the search terms 'CNS', 'brain', 'metastasis', 'trial', 'clinical', 'surgery', 'radiotherapy', 'chemotherapy', 'targeted therapy', 'immunotherapy', 'imaging', 'MRI' and 'PET' in various combinations from 1 January 2011 to 30 August 2020. Articles were also identified through searches of the authors' own files. Only papers in English were reviewed. The final reference list was generated by consensus of the authors and based on originality and relevance to the broad scope of this guideline. Levels of evidence and grades of recommendation were applied using the European Federation of Neurological Societies criteria as recommended by EANO ([Supplementary Table S1](#), available at <https://doi.org/10.1016/j.annonc.2021.07.016>)<sup>93</sup> as well as using an adapted version of the Infectious Disease Society of America-United States Public Health Service Grading System as recommended by ESMO ([Supplementary Table S2](#), available at <https://doi.org/10.1016/j.annonc.2021.07.016>).<sup>94</sup> Statements without grading were considered justified standard clinical practice by the experts.

## ACKNOWLEDGEMENTS

Manuscript editing support was provided by Sarah Escuin, Richard Lutz, Jennifer Lamarre and Catherine Evans (ESMO Guidelines staff).

## FUNDING

No external funding has been received for the preparation of these guidelines. Production costs have been covered by ESMO from central funds.

## DISCLOSURE

ELR has received honoraria for lectures or advisory board from AbbVie, AdastrA, Daiichi Sankyo, LEO Pharma, Seagen and Tocagen. MG has received honoraria for lectures or advisory board from AstraZeneca and has received research support from AstraZeneca and Varian. MS received honoraria for lectures from GE Healthcare and for trial imaging review from Parexel Ltd. RD has intermittent, project-focused consulting and/or advisory relationships with Novartis, Merck Sharp & Dohme, Bristol-Myers Squibb, Roche, Amgen, Takeda, Pierre Fabre, Sun Pharma, Sanofi, CatalYm, Second Genome, Regeneron and Alligator. TB has received personal fees and non-financial support from Roche; grants, personal fees and non-financial support from Novartis, AstraZeneca and Pfizer; and grant and personal fees from Seattle Genetics. ASB has research support from Daiichi Sankyo and Roche and honoraria for lectures, consultation or advisory board participation from Roche, Bristol-Meyers Squibb, Merck and Daiichi Sankyo as well as travel support from Roche, Amgen and AbbVie. EdA has received honoraria and/or advisory board from Roche/GNE, Novartis, Seattle Genetics, Zodiac, Libbs, Lilly and Pierre Fabre; travel grants from Roche/GNE and GSK/Novartis; and research grants to her institution from Roche/GNE, AstraZeneca, GSK/Novartis and Servier. SP has received education grants, provided consultation, attended advisory boards, provided lectures for and received honoraria from AbbVie, Amgen, AstraZeneca, Bayer, Biocartis, Bioinvent, Blueprint Medicines, Boehringer-Ingelheim, Bristol-Myers Squibb, Clovis, Daiichi Sankyo, Debiopharm, Eli Lilly, F. Hoffmann-La Roche, Foundation Medicine, Illumina, Janssen, Merck Sharp & Dohme, Merck Serono, Merrimack, Novartis, PharmaMar, Pfizer, Regeneron, Sanofi, Seattle Genetics, Takeda and Vaccibody. FS has received advisory board for AbbVie, travel support from Agilent and Illumina and speaker's bureau from Agilent and Medac. DS reported consulting or advisory role for Roche/Genentech, Novartis, Bristol-Myers Squibb, MSD, Merck Serono, Amgen, Immunocore, Incyte, InFlarX, 4SC, Pierre Fabre, Mologen, Nektar and Sanofi/Regeneron; honoraria from Roche/Genentech, Novartis, MSD, Bristol-Myers Squibb, Merck Serono, Amgen, Immunocore, Incyte, 4SC, Pierre Fabre, Array BioPharma, Pfizer, Philogen and Regeneron; travel, accommodation and expenses from Roche/Genentech, Novartis, Bristol-Myers Squibb, Merck Serono, Amgen and Merck; speakers' bureau for Novartis, Bristol-Myers Squibb, MSD, Pierre Fabre and Roche; research funding from Novartis and Bristol-Myers Squibb; and steering committee member for Novartis, MSD and Bristol-Myers Squibb. JS is a co-founder of Mosaic Biomedicals and board member of Northern Biologics; he received grant/research support from Mosaic Biomedicals, Northern Biologics, Roche/Glycart, Isarna and Ridgeline. RS has received honoraria for lectures or advisory board from boards from MSD, Roche, Merck Serono, Cell-dex Therapeutics, Novartis, Mundipharma and Puma Technologies. MvdB has received honoraria for consultation from AbbVie, Agios, Carthera, Celgene, Bayer, Nerviano,

Karyopharm and Boehringer. FW has received research grants from Roche, Genentech, Boehringer and Divide & Conquer Ltd. and honoraria from Divide & Conquer Ltd. MW has received research grants from AbbVie, Adastr, Dracen, Merck, Sharp & Dohme (MSD), Merck (EMD) and Novocure and honoraria for lectures or advisory board participation or consulting from AbbVie, Basilea, Bristol Meyer Squibb (BMS), Celgene, Medac, Merck, Sharp & Dohme (MSD), Merck (EMD), Novocure, Orbus, Roche and Tocagen. MP has received honoraria for lectures, consultation or advisory board participation from Bayer, Bristol-Myers Squibb, Novartis, Gerson Lehrman Group (GLG), CMC Contrast, GlaxoSmithKline, Mundipharma, Roche, BMJ Journals, MedMedia, AstraZeneca, AbbVie, Lilly, Medahead, Daiichi Sankyo, Sanofi, Merck Sharp & Dome and Tocagen and reported clinical trials and contracted research (paid to his institution) from Böhringer-Ingelheim, Bristol-Myers Squibb, Roche, Daiichi Sankyo, Merck Sharp & Dohme, Novocure, GlaxoSmithKline and AbbVie. The remaining authors have declared no conflicts of interest.

## REFERENCES

- Le Rhun E, Weller M, Brandsma D, et al. EANO-ESMO Clinical Practice Guidelines for diagnosis, treatment and follow-up of patients with leptomeningeal metastasis from solid tumours. *Ann Oncol*. 2017;28(suppl 4):iv84-iv99.
- Nayak L, DeAngelis LM, Brandes AA, et al. The Neurologic Assessment in Neuro-Oncology (NANO) scale: a tool to assess neurologic function for integration into the Response Assessment in Neuro-Oncology (RANO) criteria. *Neuro Oncol*. 2017;19(5):625-635.
- Soffietti R, Abacioglu U, Baumert B, et al. Diagnosis and treatment of brain metastases from solid tumors: guidelines from the European Association of Neuro-Oncology (EANO). *Neuro Oncol*. 2017;19(2):162-174.
- Cagney DN, Martin AM, Catalano PJ, et al. Incidence and prognosis of patients with brain metastases at diagnosis of systemic malignancy: a population-based study. *Neuro Oncol*. 2017;19(11):1511-1521.
- Singh R, Stoltzfus KC, Chen H, et al. Epidemiology of synchronous brain metastases. *Neurooncol Adv*. 2020;2(1):vdaa041.
- Wolpert F, Lareida A, Terziev R, et al. Risk factors for the development of epilepsy in patients with brain metastases. *Neuro Oncol*. 2020;22(5):718-728.
- Kaufmann TJ, Smits M, Boxerman J, et al. Consensus recommendations for a standardized brain tumor imaging protocol for clinical trials in brain metastases (BTIP-BM). *Neuro Oncol*. 2020;22:757-772.
- Suh CH, Jung SC, Kim KW, et al. The detectability of brain metastases using contrast-enhanced spin-echo or gradient-echo images: a systematic review and meta-analysis. *J Neurooncol*. 2016;129(2):363-371.
- Nagao E, Yoshiura T, Hiwatashi A, et al. 3D turbo spin-echo sequence with motion-sensitized driven-equilibrium preparation for detection of brain metastases on 3T MR imaging. *AJNR Am J Neuroradiol*. 2011;32(4):664-670.
- Yuh WT, Tali ET, Nguyen HD, et al. The effect of contrast dose, imaging time, and lesion size in the MR detection of intracerebral metastasis. *AJNR Am J Neuroradiol*. 1995;16(2):373-380.
- Jeon J-Y, Choi JW, Roh HG, et al. Effect of imaging time in the magnetic resonance detection of intracerebral metastases using single dose gadobutrol. *Korean J Radiol*. 2014;15(1):145-150.
- Wolpert F, Weller M, Berghoff AS, et al. Diagnostic value of 18F-fluorodesoxyglucose positron emission tomography for patients with brain metastasis from unknown primary site. *Eur J Cancer*. 2018;96:64-72.
- Galldiks N, Langen K-J, Albert NL, et al. PET imaging in patients with brain metastasis-report of the RANO/PET group. *Neuro Oncol*. 2019;21(5):585-595.
- Albert NL, Weller M, Suchorska B, et al. Response Assessment in Neuro-Oncology working group and European Association for Neuro-Oncology recommendations for the clinical use of PET imaging in gliomas. *Neuro Oncol*. 2016;18(9):1199-1208.
- Kamp MA, Rapp M, Slotty PJ, et al. Incidence of local in-brain progression after supramarginal resection of cerebral metastases. *Acta Neurochir (Wien)*. 2015;157(6):905-910;discussion 910-911.
- Yoo H, Kim YZ, Nam BH, et al. Reduced local recurrence of a single brain metastasis through microscopic total resection. *J Neurosurg*. 2009;110(4):730-736.
- Patel AJ, Suki D, Hatiboglu MA, et al. Impact of surgical methodology on the complication rate and functional outcome of patients with a single brain metastasis. *J Neurosurg*. 2015;122(5):1132-1143.
- Kamp MA, Munoz-Bendix C, Mijderwijk H-J, et al. Is 5-ALA fluorescence of cerebral metastases a prognostic factor for local recurrence and overall survival? *J Neurooncol*. 2019;141(3):547-553.
- Höhne J, Hohenberger C, Proescholdt M, et al. Fluorescein sodium-guided resection of cerebral metastases-an update. *Acta Neurochir (Wien)*. 2017;159(2):363-367.
- Chua TH, See AAQ, Ang BT, et al. Awake craniotomy for resection of brain metastases: a systematic review. *World Neurosurg*. 2018;120:e1128-e1135.
- Sanmillan JL, Fernández-Coello A, Fernández-Conejero I, et al. Functional approach using intraoperative brain mapping and neurophysiological monitoring for the surgical treatment of brain metastases in the central region. *J Neurosurg*. 2017;126(3):698-707.
- Patchell RA, Tibbs PA, Walsh JW, et al. A randomized trial of surgery in the treatment of single metastases to the brain. *N Engl J Med*. 1990;322(8):494-500.
- Vecht CJ, Haaxma-Reiche H, Noordijk EM, et al. Treatment of single brain metastasis: radiotherapy alone or combined with neurosurgery? *Ann Neurol*. 1993;33(6):583-590.
- Lee SR, Oh JY, Kim S-H. Gamma Knife radiosurgery for cystic brain metastases. *Br J Neurosurg*. 2016;30(1):43-48.
- Wang H, Liu X, Jiang X, et al. Cystic brain metastases had slower speed of tumor shrinkage but similar prognosis compared with solid tumors that underwent radiosurgery treatment. *Cancer Manag Res*. 2019;11:1753-1763.
- Alvarez-Breckenridge C, Giobbie-Hurder A, Gill CM, et al. Upfront surgical resection of melanoma brain metastases provides a bridge toward immunotherapy-mediated systemic control. *Oncologist*. 2019;24(5):671-679.
- Shah AH, Semonche A, Eichberg DG, et al. The role of laser interstitial thermal therapy in surgical neuro-oncology: series of 100 consecutive patients. *Neurosurgery*. 2020;87(2):266-275.
- Bastos DCA, Weinberg J, Kumar VA, et al. Laser interstitial thermal therapy in the treatment of brain metastases and radiation necrosis. *Cancer Lett*. 2020;489:9-18.
- Lehrer EJ, Peterson JL, Zaorsky NG, et al. Single versus multifraction stereotactic radiosurgery for large brain metastases: an international meta-analysis of 24 trials. *Int J Radiat Oncol Biol Phys*. 2019;103(3):618-630.
- Andrews DW, Scott CB, Sperduto PW, et al. Whole brain radiation therapy with or without stereotactic radiosurgery boost for patients with one to three brain metastases: phase III results of the RTOG 9508 randomised trial. *Lancet*. 2004;363(9422):1665-1672.
- Yamamoto M, Serizawa T, Higuchi Y, et al. A multi-institutional prospective observational study of stereotactic radiosurgery for patients with multiple brain metastases (JLKG0901 study update): irradiation-related complications and long-term maintenance of mini-mental state examination scores. *Int J Radiat Oncol Biol Phys*. 2017;99(1):31-40.
- Sahgal A, Aoyama H, Kocher M, et al. Phase 3 trials of stereotactic radiosurgery with or without whole-brain radiation therapy for 1 to 4 brain metastases: individual patient data meta-analysis. *Int J Radiat Oncol Biol Phys*. 2015;91(4):710-717.
- Brown PD, Ballman KV, Cerhan JH, et al. Postoperative stereotactic radiosurgery compared with whole brain radiotherapy for resected metastatic brain disease (NCCTG N107C/CEC-3): a multicentre, randomised, controlled, phase 3 trial. *Lancet Oncol*. 2017;18(8):1049-1060.

34. Mahajan A, Ahmed S, McAleer MF, et al. Post-operative stereotactic radiosurgery versus observation for completely resected brain metastases: a single-centre, randomised, controlled, phase 3 trial. *Lancet Oncol*. 2017;18(8):1040-1048.
35. Patchell RA, Tibbs PA, Regine WF, et al. Postoperative radiotherapy in the treatment of single metastases to the brain: a randomized trial. *J Am Med Assoc*. 1998;280(17):1485-1489.
36. Kocher M, Soffiotti R, Abacioglu U, et al. Adjuvant whole-brain radiotherapy versus observation after radiosurgery or surgical resection of one to three cerebral metastases: results of the EORTC 22952-26001 study. *J Clin Oncol*. 2011;29(2):134-141.
37. Hong AM, Fogarty GB, Dolven-Jacobsen K, et al. Adjuvant whole-brain radiation therapy compared with observation after local treatment of melanoma brain metastases: a multicenter, randomized phase III trial. *J Clin Oncol*. 2019;37(33):3132-3141.
38. Tsao M, Xu W, Sahgal A. A meta-analysis evaluating stereotactic radiosurgery, whole-brain radiotherapy, or both for patients presenting with a limited number of brain metastases. *Cancer*. 2012;118(9):2486-2493.
39. Mulvenna P, Nankivell M, Barton R, et al. Dexamethasone and supportive care with or without whole brain radiotherapy in treating patients with non-small cell lung cancer with brain metastases unsuitable for resection or stereotactic radiotherapy (QUARTZ): results from a phase 3, non-inferiority, randomised trial. *Lancet*. 2016;388(10055):2004-2014.
40. Brown PD, Pugh S, Laack NN, et al. Memantine for the prevention of cognitive dysfunction in patients receiving whole-brain radiotherapy: a randomized, double-blind, placebo-controlled trial. *Neuro Oncol*. 2013;15(10):1429-1437.
41. Brown PD, Gondi V, Pugh S, et al. Hippocampal avoidance during whole-brain radiotherapy plus memantine for patients with brain metastases: phase III trial NRG oncology CC001. *J Clin Oncol*. 2020;38(10):1019-1029.
42. Aupérin A, Arriagada R, Pignon JP, et al. Prophylactic cranial irradiation for patients with small-cell lung cancer in complete remission. Prophylactic Cranial Irradiation Overview Collaborative Group. *N Engl J Med*. 1999;341(7):476-484.
43. Slotman B, Faivre-Finn C, Kramer G, et al. Prophylactic cranial irradiation in extensive small-cell lung cancer. *N Engl J Med*. 2007;357(7):664-672.
44. Takahashi T, Yamanaka T, Seto T, et al. Prophylactic cranial irradiation versus observation in patients with extensive-disease small-cell lung cancer: a multicentre, randomised, open-label, phase 3 trial. *Lancet Oncol*. 2017;18(5):663-671.
45. De Ruyscher D, Dingemans A-MC, Praag J, et al. Prophylactic cranial irradiation versus observation in radically treated stage III non-small-cell lung cancer: a randomized phase III NVALT-11/DLCRG-02 study. *J Clin Oncol*. 2018;36(23):2366-2377.
46. Paz-Ares L, Dvorkin M, Chen Y, et al. Durvalumab plus platinum-etoposide versus platinum-etoposide in first-line treatment of extensive-stage small-cell lung cancer (CASPIAN): a randomised, controlled, open-label, phase 3 trial. *Lancet*. 2019;394(10212):1929-1939.
47. Belderbos JSA, De Ruyscher DKM, De Jaeger K, et al. Phase 3 randomized trial of prophylactic cranial irradiation with or without hippocampus avoidance in SCLC (NCT01780675). *J Thorac Oncol*. 2021;16(5):840-849.
48. Petrelli F, Signorelli D, Ghidini M, et al. Association of steroids use with survival in patients treated with immune checkpoint inhibitors: a systematic review and meta-analysis. *Cancers (Basel)*. 2020;12(3):546.
49. Lin NU, Diéras V, Paul D, et al. Multicenter phase II study of lapatinib in patients with brain metastases from HER2-positive breast cancer. *Clin Cancer Res*. 2009;15(4):1452-1459.
50. Bachelot T, Romieu G, Campone M, et al. Lapatinib plus capecitabine in patients with previously untreated brain metastases from HER2-positive metastatic breast cancer (LANDSCAPE): a single-group phase 2 study. *Lancet Oncol*. 2013;14(1):64-71.
51. Saura C, Oliveira M, Feng Y-H, et al. Neratinib plus capecitabine versus lapatinib plus capecitabine in HER2-positive metastatic breast cancer previously treated with  $\geq 2$  HER2-directed regimens: phase III NALA trial. *J Clin Oncol*. 2020;38(27):3138-3149.
52. Freedman RA, Gelman RS, Anders CK, et al. TBCRC 022: a phase II trial of neratinib and capecitabine for patients with human epidermal growth factor receptor 2-positive breast cancer and brain metastases. *J Clin Oncol*. 2019;37(13):1081-1089.
53. Krop IE, Lin NU, Blackwell K, et al. Trastuzumab emtansine (T-DM1) versus lapatinib plus capecitabine in patients with HER2-positive metastatic breast cancer and central nervous system metastases: a retrospective, exploratory analysis in EMILIA. *Ann Oncol*. 2015;26(1):113-119.
54. Jacot W, Pons E, Frenel J-S, et al. Efficacy and safety of trastuzumab emtansine (T-DM1) in patients with HER2-positive breast cancer with brain metastases. *Breast Cancer Res Treat*. 2016;157(2):307-318.
55. Lin NU, Borges V, Anders C, et al. Intracranial efficacy and survival with tucatinib plus trastuzumab and capecitabine for previously treated HER2-positive breast cancer with brain metastases in the HER2CLIMB trial. *J Clin Oncol*. 2020;38(23):2610-2619.
56. Tolaney SM, Sahebjam S, Le Rhun E, et al. A phase 2 study of abemaciclib in patients with brain metastases secondary to hormone receptor positive breast cancer. *Clin Cancer Res*. 2020;26(20):5310-5319.
57. Swain SM, Baselga J, Miles D, et al. Incidence of central nervous system metastases in patients with HER2-positive metastatic breast cancer treated with pertuzumab, trastuzumab, and docetaxel: results from the randomized phase III study CLEOPATRA. *Ann Oncol*. 2014;25(6):1116-1121.
58. Pivot X, Manikhas A, Żurawski B, et al. CEREBEL (EGF111438): a phase III, randomized, open-label study of lapatinib plus capecitabine versus trastuzumab plus capecitabine in patients with human epidermal growth factor receptor 2-positive metastatic breast cancer. *J Clin Oncol*. 2015;33(14):1564-1573.
59. Gandhi L, Rodríguez-Abreu D, Gadgeel S, et al. Pembrolizumab plus chemotherapy in metastatic non-small-cell lung cancer. *N Engl J Med*. 2018;378(22):2078-2092.
60. Gadgeel SM, Lukas RV, Goldschmidt J, et al. Atezolizumab in patients with advanced non-small cell lung cancer and history of asymptomatic, treated brain metastases: Exploratory analyses of the phase III OAK study. *Lung Cancer*. 2019;128:105-112.
61. Goldberg SB, Schalper KA, Gettinger SN, et al. Pembrolizumab for management of patients with NSCLC and brain metastases: long-term results and biomarker analysis from a non-randomised, open-label, phase 2 trial. *Lancet Oncol*. 2020;21(5):655-663.
62. Gauvain C, Vauléon E, Chouaid C, et al. Intracerebral efficacy and tolerance of nivolumab in non-small-cell lung cancer patients with brain metastases. *Lung Cancer*. 2018;116:62-66.
63. Paz-Ares L, Ciuleanu T-E, Cobo M, et al. First-line nivolumab plus ipilimumab combined with two cycles of chemotherapy in patients with non-small-cell lung cancer (CheckMate 9LA): an international, randomised, open-label, phase 3 trial. *Lancet Oncol*. 2021;22(2):198-211.
64. Hendriks LEL, Henon C, Auclin E, et al. Outcome of patients with non-small cell lung cancer and brain metastases treated with checkpoint inhibitors. *J Thorac Oncol*. 2019;14(7):1244-1254.
65. Ramalingam SS, Vansteenkiste J, Planchard D, et al. Overall survival with osimertinib in untreated, EGFR-mutated advanced NSCLC. *N Engl J Med*. 2020;382(1):41-50.
66. Mok T, Camidge DR, Gadgeel SM, et al. Updated overall survival and final progression-free survival data for patients with treatment-naive advanced ALK-positive non-small-cell lung cancer in the ALEX study. *Ann Oncol*. 2020;31(8):1056-1064.
67. Tan AC, Itchins M, Khasraw M. Brain metastases in lung cancers with emerging targetable fusion drivers. *Int J Mol Sci*. 2020;21(4):1416.
68. Gutzmer R, Vordermark D, Hassel JC, et al. Melanoma brain metastases—interdisciplinary management recommendations 2020. *Cancer Treat Rev*. 2020;89:102083.
69. Dummer R, Goldinger SM, Turttschi CP, et al. Vemurafenib in patients with BRAF(V600) mutation-positive melanoma with symptomatic brain metastases: final results of an open-label pilot study. *Eur J Cancer*. 2014;50(3):611-621.
70. McArthur GA, Maio M, Arance A, et al. Vemurafenib in metastatic melanoma patients with brain metastases: an open-label, single-arm, phase 2, multicentre study. *Ann Oncol*. 2017;28(3):634-641.

71. Long GV, Trefzer U, Davies MA, et al. Dabrafenib in patients with Val600Glu or Val600Lys BRAF-mutant melanoma metastatic to the brain (BREAK-MB): a multicentre, open-label, phase 2 trial. *Lancet Oncol*. 2012;13(11):1087-1095.
72. Davies MA, Saiag P, Robert C, et al. Dabrafenib plus trametinib in patients with BRAFV600-mutant melanoma brain metastases (COMBI-MB): a multicentre, multicohort, open-label, phase 2 trial. *Lancet Oncol*. 2017;18(7):863-873.
73. Tawbi HA, Forsyth PA, Algazi A, et al. Combined nivolumab and ipilimumab in melanoma metastatic to the brain. *N Engl J Med*. 2018;379(8):722-730.
74. Long GV, Atkinson V, Lo S, et al. Combination nivolumab and ipilimumab or nivolumab alone in melanoma brain metastases: a multicentre randomised phase 2 study. *Lancet Oncol*. 2018;19(5):672-681.
75. Anker CJ, Grossmann KF, Atkins MB, et al. Avoiding severe toxicity from combined BRAF inhibitor and radiation treatment: consensus guidelines from the Eastern Cooperative Oncology Group (ECOG). *Int J Radiat Oncol Biol Phys*. 2016;95(2):632-646.
76. Lehrer EJ, Peterson J, Brown PD, et al. Treatment of brain metastases with stereotactic radiosurgery and immune checkpoint inhibitors: an international meta-analysis of individual patient data. *Radiother Oncol*. 2019;130:104-112.
77. Magnuson WJ, Lester-Coll NH, Wu AJ, et al. Management of brain metastases in tyrosine kinase inhibitor-naïve epidermal growth factor receptor-mutant non-small-cell lung cancer: a retrospective multi-institutional analysis. *J Clin Oncol*. 2017;35(10):1070-1077.
78. Miyawaki E, Kenmotsu H, Mori K, et al. Optimal sequence of local and EGFR-TKI therapy for EGFR-mutant non-small cell lung cancer with brain metastases stratified by number of brain metastases. *Int J Radiat Oncol Biol Phys*. 2019;104(3):604-613.
79. Lee J-H, Chen H-Y, Hsu F-M, et al. Cranial irradiation for patients with epidermal growth factor receptor (EGFR) mutant lung cancer who have brain metastases in the era of a new generation of EGFR inhibitors. *Oncologist*. 2019;24(12):e1417-e1425.
80. Rusthoven CG, Yamamoto M, Bernhardt D, et al. Evaluation of first-line radiosurgery vs whole-brain radiotherapy for small cell lung cancer brain metastases: the FIRE-SCLC cohort study. *JAMA Oncol*. 2020;6(7):1028-1037.
81. Yaeh A, Nanda T, Jani A, et al. Control of brain metastases from radioresistant tumors treated by stereotactic radiosurgery. *J Neurooncol*. 2015;124(3):507-514.
82. Le Rhun E, Wolpert F, Fialek M, et al. Response assessment and outcome of combining immunotherapy and radiosurgery for brain metastasis from malignant melanoma. *ESMO Open*. 2020;5(4):e000763.
83. Lin NU, Lee EQ, Aoyama H, et al. Response assessment criteria for brain metastases: proposal from the RANO group. *Lancet Oncol*. 2015;16(6):e270-e278.
84. Knitter JR, Erly WK, Stea BD, et al. Interval change in diffusion and perfusion MRI parameters for the assessment of pseudoprogression in cerebral metastases treated with stereotactic radiation. *AJR Am J Roentgenol*. 2018;211(1):168-175.
85. Chuang M-T, Liu Y-S, Tsai Y-S, et al. Differentiating radiation-induced necrosis from recurrent brain tumor using MR perfusion and spectroscopy: a meta-analysis. *PLoS One*. 2016;11(1):e0141438.
86. Lai G, Mahadevan A, Hackney D, et al. Diagnostic accuracy of PET, SPECT, and arterial spin-labeling in differentiating tumor recurrence from necrosis in cerebral metastasis after stereotactic radiosurgery. *AJNR Am J Neuroradiol*. 2015;36(12):2250-2255.
87. Ceccon G, Lohmann P, Stoffels G, et al. Dynamic O-(2-18F-fluoroethyl)-L-tyrosine positron emission tomography differentiates brain metastasis recurrence from radiation injury after radiotherapy. *Neuro Oncol*. 2017;19(2):281-288.
88. Galldiks N, Abdulla DSY, Scheffler M, et al. Treatment monitoring of immunotherapy and targeted therapy using 18F-FET PET in patients with melanoma and lung cancer brain metastases: initial experiences. *J Nucl Med*. 2021;62(4):464-470.
89. Okada H, Weller M, Huang R, et al. Immunotherapy response assessment in neuro-oncology: a report of the RANO working group. *Lancet Oncol*. 2015;16(15):e534-e542.
90. Seoane J, De Mattos-Arruda L, Le Rhun E, et al. Cerebrospinal fluid cell-free tumour DNA as a liquid biopsy for primary brain tumours and central nervous system metastases. *Ann Oncol*. 2019;30(2):211-218.
91. Pace A, Dirven L, Koekkoek JAF, et al. European Association for Neuro-Oncology (EANO) guidelines for palliative care in adults with glioma. *Lancet Oncol*. 2017;18(6):e330-e340.
92. Levin VA, Bidaut L, Hou P, et al. Randomized double-blind placebo-controlled trial of bevacizumab therapy for radiation necrosis of the central nervous system. *Int J Radiat Oncol Biol Phys*. 2011;79(5):1487-1495.
93. Brainin M, Barnes M, Baron J-C, et al. Guidance for the preparation of neurological management guidelines by EFNS scientific task forces—revised recommendations 2004. *Eur J Neurol*. 2004;11(9):577-581.
94. Dykewicz CA. Centers for Disease Control and Prevention (U.S.), Infectious Diseases Society of America, American Society of Blood and Marrow Transplantation. Summary of the Guidelines for Preventing Opportunistic Infections among Hematopoietic Stem Cell Transplant Recipients. *Clin Infect Dis*. 2001;33(2):139-144 (Adapted from: Gross PA, Barrett TL, Dellinger EP, et al. Purpose of quality standards for infectious diseases. *Clin Infect Dis*. 1994;18:421).