



Review

Common Anatomical Variations of Neurovascular Canals and Foramina Relevant to Oral Surgeons: A Review

Laura Sferlazza ^{1,*}, Fabrizio Zaccheo ², Maria Elisabetta Campogrande ³, Giulia Petroni ¹ and Andrea Cicconetti ^{1,*}¹ Department of Oral and Maxillofacial Sciences, Sapienza University of Rome, 00161 Rome, Italy² Independent Researcher, 00199 Rome, Italy³ Department of Odontostomatologic Science, University of Rome Tor Vergata, 00133 Rome, Italy

* Correspondence: laura.sferlazza@uniroma1.it (L.S.); andrea.cicconetti@uniroma1.it (A.C.)

Abstract: (1) Background: The anatomical variations of neurovascular canals that are encountered in oral surgery are often overlooked by anatomy textbooks or provided with insufficient information. The aim of this study is to analyze the most common variations, describing their morphology, prevalence and clinical implications. (2) Methods: A review of published literature from the 20th century onwards was performed using the PubMed electronic database as well as anatomical textbooks. The variations being investigated were: retromolar canal (RMC) and foramen (RMF), accessory mental foramen (AMF), midline (MLF) and lateral (MLF) lingual foramina and canalis sinuosus (CS). (3) Results: Anatomical variants of neurovascular canals and foramina have a significant incidence and important clinical implications in the most common oral surgery procedures such as third molar extraction, bone harvesting and implantology. (4) Conclusions: Knowledge of these variables is highly important both for students to have a more accurate anatomical awareness and for professional surgeons to be able to provide better diagnoses and prevent complications during oral surgery techniques.



Citation: Sferlazza, L.; Zaccheo, F.; Campogrande, M.E.; Petroni, G.; Cicconetti, A. Common Anatomical Variations of Neurovascular Canals and Foramina Relevant to Oral Surgeons: A Review. *Anatomia* **2022**, *1*, 91–106. <https://doi.org/10.3390/anatomia1010010>

Academic Editors: Gianfranco Natale and Francesco Fornai

Received: 12 June 2022

Accepted: 1 August 2022

Published: 8 August 2022

Publisher's Note: MDPI stays neutral with regard to jurisdictional claims in published maps and institutional affiliations.



Copyright: © 2022 by the authors. Licensee MDPI, Basel, Switzerland. This article is an open access article distributed under the terms and conditions of the Creative Commons Attribution (CC BY) license (<https://creativecommons.org/licenses/by/4.0/>).

Keywords: mandible; anatomical variations; mandibular canal variations; retromolar canal; retromolar foramen; accessory mental foramen; mandibular lingual foramina; lingual foramina; canalis sinuosus; cone-beam computed tomography

1. Introduction

Anatomy represents the fundament of surgery and forms the basis for diagnosis, treatment and care. Anatomical knowledge is crucial for meeting diagnostic challenges but also for developing surgical procedures. Therefore, anatomy is a major requirement for all surgical specialities, including oral and maxillofacial surgery.

The concept of *normality* in anatomy is called relative: this is inferred from a series of repeated observations. Organisms vary within the same population but also the same species. Anatomical variations may contribute to unusual manifestations of clinical symptoms, influence the course of clinical examination or the interpretation of imaging and prove of primary importance during surgical procedures [1].

Insufficient anatomical awareness can lead to serious complications and poor postoperative results both aesthetically and functionally. Therefore, to perform safe and effective surgeries, it is essential to have a thorough understanding of clinical anatomy and potential anatomical differences that may be found between individuals.

Morphological changes caused by atrophy of alveolar processes following tooth loss may sometimes prevent the surgeon from locating anatomical landmarks.

This condition is complicated by anatomical variations, representing potential risk factors in oral and maxillofacial surgery. Variations in nerves and blood vessels can lead to serious complications such as uncontrollable haemorrhage with potentially fatal outcomes and permanent nerve trunk injuries which negatively impact patients' quality of life. To

avoid such complications, surgeons must be aware of anatomical changes and their clinical management.

We decided to analyse the most common anatomical variations of neurovascular canals and foramina relevant in the treatment planning and outcome of the most frequent dental surgery: third molar surgery, bone harvesting and implantology.

The anatomical variations we decided to investigate were: retromolar canal (RMC) and foramina (RMF), accessory mental foramen (AMF), midline (MLF) and lateral (MLF) lingual foramina and canalis sinuosus (CS).

The aim of this study was to assess the clinical anatomy and surgical significance of the main variations of neurovascular canals and foramina by reviewing the literature. These results may contribute to a more accurate awareness of variations in oral anatomy and may assist the oral surgeon in better diagnosis, preventing complications during oral surgical techniques.

2. Materials and Methods

The literature selected for this review was limited to work published in English from the 20th century onwards. Standard anatomical textbooks as well as keyword searches using the online PubMed and Google Scholar databases were used. Key terms used were: "Anatomical Variations", "Anatomical Variants", "Mandibular Canal Variations", "Retromolar Canal", "Retromolar Foramen", "Retromolar Foramina", "Mental Foramen", "Mental Foramina", "Mental Foramen Variation", "Accessory Mental Foramen", "Accessory Mental Foramina", "Mandibular Lingual Foramina", "Lingual Foramen", "Lingual Foramina", "Canalis Sinuosus", and "Cone-beam Computed Tomography". Further relevant papers were identified by examination of the reference lists of the useful articles found.

3. Results

The most common anatomical variants that this review selected were: Retromolar Canal and Foramen, Accessory Mental Foramina, Lingual Foramina, and Canalis Sinuosus.

3.1. Retromolar Canal and Foramen

The mandibular canal (MC) is now known as the main trunk from which multiple minor branches originate, running approximately parallel to it [2]. These accessory canals result from failure of primitive canal fusion during the prenatal period and are usually detected as incidental radiographic findings since they have no clinical landmarks [3]. However, a better understanding of the openings and location of mandibular accessory canals is important to ensure the safety of surgical procedures in the posterior part of the mandible.

3.1.1. Retromolar Canal

The retromolar canal (RMC) is a bifid variant of the MC that involves branches of the inferior alveolar nerve (IAN). These branches divide from the top of the canal and travel antero-superiorly within the bone to emerge from the retromolar foramen (RMF) into the retromolar fossa or retromolar triangle [4].

Classification of RMC

The retromolar canal was first classified by Ossenberg (1987) [5] and later by Von Arx et al. (2011) [6] into three main types. Later Patil et al. (2013) [7] introduced an additional subclassification in two subtypes.

The resulting classification is as follows: (Figure 1)

- **Type A1:** RMC with a vertical course that branches off from the MC and courses postero-superiorly to open into the retromolar fossa.
- **Type A2:** RMC with a vertical course that forms an additional horizontal anterior branch before opening posterosuperiorly into the retromolar fossa
- **Type B1:** RMC with a posteriorly curved course

- **Type B2:** RMC with posteriorly curved course forming an additional anterior horizontal branch before opening into the retromolar fossa
- **Type C:** RMC with a horizontal or transverse course with a posterior opening behind the temporal crest and an anterior opening in front of the temporal crest in the retromolar fossa.

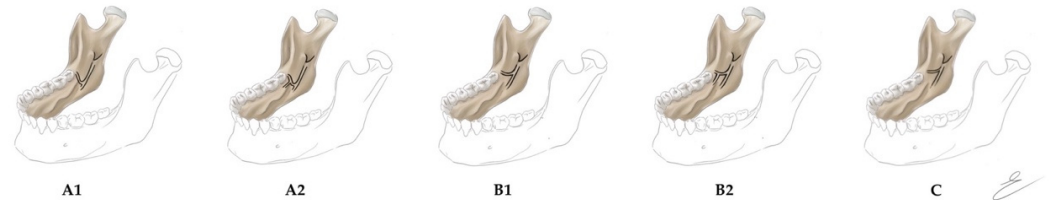


Figure 1. Retromolar Canal's Classification according to Patil et al. (2013). (A1) RMC with a vertical course; (A2) RMC with a vertical course forming an additional horizontal anterior branch; (B1) RMC with a posteriorly curved course; (B2) RMC with a posteriorly curved course forming an additional horizontal anterior branch; (C) RMC with a horizontal or transverse course with a posterior opening behind the temporal crest and an anterior opening in the retromolar fossa. Copyright © 2022 Maria Elisabetta Campogrande.

Zhang et al. [8] also described this classification system into three subtypes:

- Subtype 1, which runs directly over the surface of the bone;
- Subtype 2, which reaches the retromolar region with a single curve, giving the impression of a "V";
- Subtype 3, with three segments and two main curves before ending in the retromolar region, resembling a "U".

Another classification was proposed by Luangchana et al. (2018) [9], which distinguished five types of RMC by further modifying the classification of Patil et al. (2013) [7]:

- Type A: superior type;
- Type B: radicular retromolar type;
- Type C: dental type;
- Type D: plexus type;
- Type E: forward type. Further subclassified in: E1, where RMC branches off the MC and runs forward without fusing to the MC; E2, where RMC branches off the MC, runs forward for some distance and then fuses with the MC.

In spite of the numerous classification systems proposed to describe RMC in its various locations and configurations, most studies conducted over the years have focused on the most common type of RMC (type 1) proposed by Ossenberg (1987) [10,11].

Prevalence of RMC

According to the literature, RMC has an extremely variable prevalence ranging from 0% to 75.4%, depending on the method applied. Studies based on orthopantomography reported a low prevalence of RMC [5,12–15] while studies in which OPT and CBCT were associated found significantly higher results. These outcomes indicate the importance of three-dimensional investigations and their great advantage in detecting these anatomical structures [5,13,14,16]. The prevalence of RMC reported by studies carried out on CBCT ranges from 24.65% to 75.4% [7,14].

Other methods to evaluate RMCs have included anatomical dissection on cadavers [16], micro-CT studies, CBCT [11] and, more recently, endoscope studies [17].

Content of the RMC

Based on radiologic studies, cadaver studies, and biopsies, it has been reported that the retromolar canal contains a neurovascular bundle that is predominantly endowed by thin myelinated nerve fibres, venules and arterioles covered by collagen fibres, and adipose tissue in small amounts.

A recent study has mentioned that the diameter of nerve bundles varied between 40 to 60 microns, and the larger ones ranged from 80 to 180 microns. The largest arteriole had a diameter of a maximum of 600 microns [12].

Morphometric Measurement of RMC

The distance from the mandibular foramen to the origin of the RMC is 21.5 (11.2) mm [11]. The diameter of the RMC has been reported to range from a mean of 0.75 mm to 2.28 mm [8,18]. The narrowest RMC reported was 0.27 mm, while the widest was 3.29 mm in diameter [19]. The reported mean length of the RMC ranges from 6.9 mm to 16.2 mm [19,20]. The longest RMC ever reported was 33.2 [19]. The mean height of the canal has been reported to range from 6.66 (2.18) mm to 15.3 (4.6) mm from the MC [5,19].

3.1.2. Retromolar Foramen

RMF is the accessory foramen that allows RMC outflow and is often located on the medial [21,22] or lingual [23] surface of the retromolar trigone.

It has been suggested that the foramen on the medial aspect of the retromolar trigone may carry fibres of the mylohyoid nerve; this may be responsible in part for the dolorific sensibility of the third molar. The RMF often occurs as a single unilateral or bilateral foramen, although up to three foramina may be present at a single site [24].

Prevalence of RMF

The prevalence of the RMF as reported in studies of dry mandibles ranges from 3.2% to 92.7% [25]. Studies using orthopantomography reported a prevalence of only 5.3% [26], while CBCT studies reported a range between 7.33% and 12.4% [25,26]. This wide range has been attributed to ethnic differences, environmental and genetic factors, techniques of study, and differences in the number of samples studied [25].

Morphometric Measurement of RMF

RMF was first analysed in its size and location by Lofgren in 1957 [27].

The average diameter of the RMF ranged from 1.2 mm to 2.97 mm [28,29]. The smallest reported diameter was 0.1 mm [28]. Studies by Haas et al. (2016) [30] reported that RMF on the right side of the mandible was located more distally than on the contralateral side in the retromolar area. RMF is approximately 4.23 mm to 9.71 mm distant from the posterior edge of the third molar's socket [29,30]. However, it can be located as close as 1 mm from the tooth [29]. It lies 8.02 mm from the anterior aspect of the branch [4,31]. It is closer to the buccal cortex than to the lingual plate [4].

Clinical Significance

Currently, in clinical practice, a large number of procedures are performed in the retromolar area, and this is evidence of how RMC is a structure of considerable importance that deserves more attention in daily surgical practices.

The main complications that can be caused by accessory canals relate to failure to achieve complete local anaesthesia and intraoperative injury to neurovascular bundles if not detected before surgery [32].

The presence of an RMC is often associated with the so-called "escape pain phenomenon", which is the persistence of painful symptomatology in procedures such as third molar extraction despite proper local anaesthesia.

This escape pain is related to the presence of nerve fibres in the RMC responsible for innervation of the retromolar triangle mucosa, buccal mucosa and gingiva of the mandibular posterior region [33].

Local Anesthetic Failure

Accessory channels are often blamed for the failure to achieve a complete local anaesthetic block. Some studies, however, have suggested that this can be achieved provided the clinician has awareness of the anatomy of the region.

Suazo et al. (2008) [34] proposed a technique accounting for RMC, which allows the achievement of 72.5% anaesthesia with a latency of ten minutes. They argued that the technique allows for easy tracking of the puncture site, which can be observed during the entire deposition of the anaesthetic agent, without bleeding. Owing to the limited vascularization and strongly adherent periosteum of this area, this technique was proposed by the authors as the first-choice approach for anaesthesia in patients with blood dyscrasia because of its low risk of vascular injury.

Haemorrhage

The presence of a retromolar canal, given its neurovascular content, is one of the causes of excessive bleeding during surgical procedures in the retromolar trigone. There may be an initial haemorrhage from blood vessels that emerge from the retromolar canal which are torn when the flap is raised, or spontaneous haemorrhage may occur later during healing and lead to a hematoma.

These complications can be managed locally by crushing the bone in the area occupied by the canal or filling the opening with bone wax [35].

Neurosensory Disturbance

According to numerous case reports, such as that reported by Sigh in 1981 [36], the retromolar canal may contain an aberrant branch of the buccal nerve.

This anatomical variation is of considerable clinical significance since surgical procedures in the retromolar area could result in complications such as unilateral paresthesia or hypoesthesia subsequent to its damage.

Normally, the buccal nerve emerges from the mandibular nerve in the infratemporal fossa before heading low to the inner portion of the branch and crossing the external oblique line up to 3 mm from the deepest concavity of the anterior aspect of the branch. In the event that an aberrant long buccal nerve emerges from the retromolar foramen, it would be at a closer distance than expected from the surgical site. Thus, an injury to the RMC nerve bundle potentially results in neurosensory disturbances such as temporary or permanent sensory impairment or traumatic neurinoma formation, negatively impacting the patient's quality of life.

3.2. Accessory Mental Foramina

The mental foramen (MF) is the opening through which the mental nerve emerges from the mandible in its anterolateral aspect. It is usually located either between the roots of the first and second mandibular premolars or apical to the second premolar. The mental nerve represents one of the terminal branches of the mandibular nerve and divides into three branches supplying the lower lip, cheeks, chin, and the vestibular gingival of mandibular incisors [37]. Although the anatomy of the mandibular nerve is well established, some anatomical variations have been reported that must be taken into consideration to avoid clinical complications. One of these is the accessory mental nerve, which runs through small foramina in the area surrounding the MF, known as accessory mental foramina (AMF) [38].

The accessory mental nerve is a relevant anatomic structure in dental practice with special relevance to local anaesthesia and surgical procedures involving this region.

AMF are smaller than mental foramina and outflow from the mandibular canal. Naitoh et al. (2009) distinguished AMFs from nutrient foramina, which may also border the MF but are not connected to MC [39].

3.2.1. Prevalence and Morphometric Measurement of AMF

The AMF has been first reported by Toh et al.'s study in 1992 [38]. The study was on a cadaver case report of three samples only. Once CBCT became a common practice in the dental field, many researchers reported a higher prevalence of AMF [40–42].

Studies show a prevalence of AMF that range between 2% and 13% [43–45], with an average reported prevalence of 8.3%, according to the cumulative results [46].

AMF has been reported in multiple configurations for instant, separated, diffused or continuous in relation to MF (Figure 2). Muinelo-Lorenzo et al. (2014) observed that the presence of AMF influences the size of MF, finding that on the sides where AMF occurred, MF was significantly smaller [47]. Naitoh et al. (2009) also found MF size to be smaller on sides with AMF but did not find statistical significance [39]. The presence of the anterior loop of mandibular nerve (ALM) is an added complexity to the mental foraminal area.

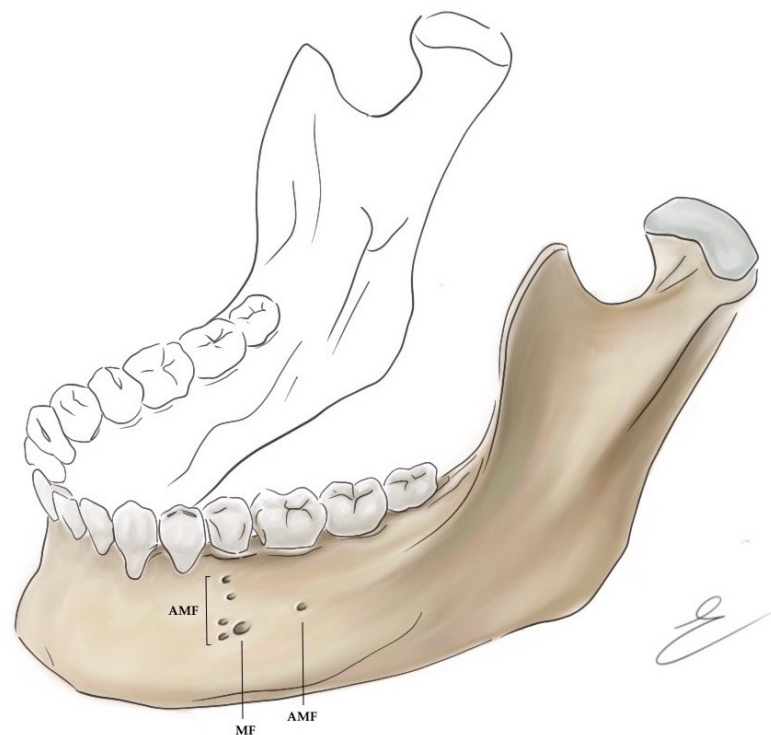


Figure 2. Schematic illustration of Mental Foramen (MF) and Accessory Mental Foramen (AMF) in its possible localization. Copyright © 2022 Maria Elisabetta Campogrande.

The average size of the reported measurement of the AMF is 1.55 mm from all the studies that calculated the AMF opening size. Iwanaga et al. (2017) detailed the bundle that exits from AMF, he and his colleagues in a dissection anatomical investigation showed nerve and blood vessels are passing through this foramen [42].

3.2.2. Clinical Significance

The position of the Mental Foramen (MF) and the Accessory Mental Foramen (AMF) is of utmost importance to modern dentistry and oral surgeons in general. The location and prevalence of any particular variation of the inferior alveolar nerve (IAN) and MN are vital for dental practitioners. Injuries to the mandibular nerve bundle can cause permanent lifelong disability and psychological damage. These include numbness of the lower lip and chin, tingling sensation of the same area and possibly dysesthesia. Many reported injuries in the dental field to the MN due to endodontic therapy [48], implant placement [49] and dental extraction [50].

Modern developments in radiology facilitate the detection of such landmarks by CBCT and panoramic imaging compared to periapical radiograph [46]. Panoramic imaging has a

great advantage of ease of use and availability in many dental practices. Using panoramic imaging is beneficial to localize the inferior alveolar nerve and the MF location in relation to dentitions. However, this modality has been reported to be inefficient to show the location of AMF due to AMF's relatively small size [47]. In addition, the panoramic image provides only a two-dimensional image that masks other important anatomical structures, such as the ALM [51].

On the other hand, the CBCT exams present several important features related to its feasibility in dentistry, such as low dose of radiations, high level of accuracy (an average of 95.5%), high resolution, and three-dimensional orientation [46]. Importantly, AMF is visible on CBCT and has been showing a relatively high incidence: Lam et al. (2019) reported a 6.4% presence of AMF in a 4000 CBCT study [52]. Interestingly, the AMF was known to the dental community since 1992 [38] through cadaver studies. However, the prevalence of AMF in radiology exams increased after the CBCT was introduced to dentistry. Other important anatomical structures in the mandible such as the anterior loop and the bifid mandibular canal [53] were also not delineated before the CBCT introduction to dentistry.

3.3. Mandibular Lingual Foramina

Lingual foramina are accessory foramina on the lingual surface of the mandible. They are typically located in the interforaminal area [54] but can also be commonly observed in the area of the second premolar [54–56]. Vascular and nerve anastomoses arising from branches of the submental artery, lingual artery, and mylohyoid nerve are found in these structures.

The lingual foramen is also known as medial lingual canal, lingual vascular canal, lateral lingual canal, and genial spinal foramen, which is itself subdivided into superior, when it is at or above the mental or genial spines, or inferior, when it is below the mental or genial spines. Other names by which it is described include supraspinous foramen (when it is located above the mental or genial spines); interspinous foramen (when it is located at the level of the mental or genial spines); infraspinous foramen (when it is located below the mental or genial spines); mental spinal foramen, lingual accessory foramen, mandibular accessory foramen, and mandibular lingual foramen [54,55].

The interforaminal zone, delimited by first premolars, is a mandibular area that is traditionally considered safe from a surgical point of view [57]. This area, on its vestibular side, is routinely used as a donor site for bone grafts of the mental block and implant placements [58]. However, these practices are often not supported by clinical protocols that take into account possible interference with lingual foramina. In fact, these structures are not described by current dental anatomy textbooks [59], and only radiographic anatomy textbooks have occasionally reported their presence [59,60].

3.3.1. Classification of Lingual Foramina

Lingual foramina are currently classified according to their location on the inner surface of the mandible into (Figure 3):

- Median or midline lingual foramina (MLF), located on the midline of the lingual aspect of the mandible, close to the genial tubercles;
- Paramedian lingual foramina, located up to the posterior margin of the canine;
- Posterior lingual foramina, located distal to the canine [61].

Many authors define all lingual foramina located beyond the midline as lateral lingual foramina (LLF). MLF is found very frequently regardless of the study method applied, while the finding of LLF in comparison is very minor.

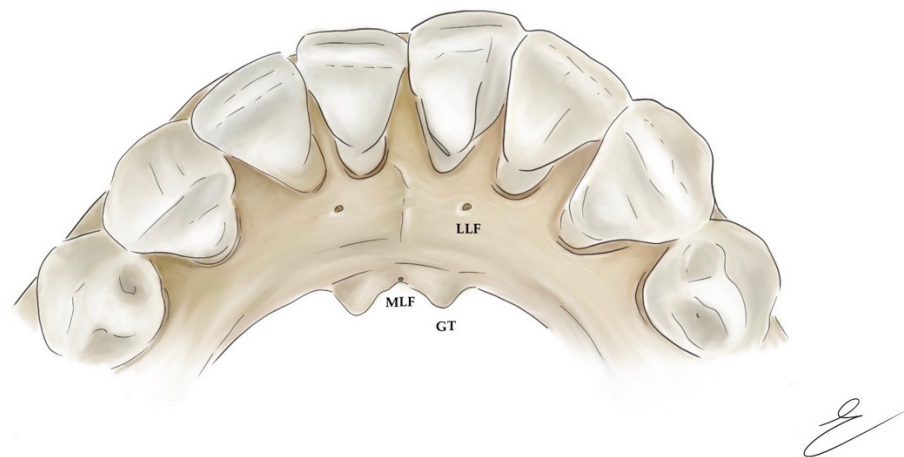


Figure 3. Schematic illustration of inner aspect of the jaw; LLF: Lateral Lingual Foramina; MLF: Midline Lingual Foramina; GT: Genial Tubercles. Copyright © 2022 Maria Elisabetta Campogrande.

Midline Lingual Foramina

MLF are the mandibular lingual foramina that are most often encountered and documented, with a prevalence ranging from 96% to 100% [62].

MLFs can often be divided into superior, middle, and inferior lingual foramina depending on their vertical position in relation to genial tubercles (or bilateral mental spines). As a result, these foramina are called supraspinous, interspinous, and infraspinous foramina [62]. Generally, one to three foramina are found, although some authors have described up to four midline lingual foramina [56]. Most studies describe two MLFs as the most common occurrence [62].

Studies have reported that if only one MLF is present, it is usually located above the mental spine. In mandibles with two foramina, the largest was located above the genial tubercles. Unlike, most mandibles with three MLF showed two of the three foramina located below the genial tubercles [59].

Lateral Lingual Foramina

LLF has been less commonly evaluated than MLF and has been observed in a lower number of cadavers and patient mandibles. The frequency of LLF generally reported in the literature ranges from 6 to 80% [61]. According to a study published by Katakami et al. (2009) [56], LLF is encountered with a relatively high frequency in the area corresponding to the first premolar (36%) but also in central incisor and canine areas (each 19.4%).

Von Arx et al. (2011) described frequencies of 22.6% and 20.3% for LLF in the first and second premolar areas, respectively [62]. The high occurrence of LLF under the first premolar was also confirmed in a cadaver study where 45.7% of the sides of dry cadaveric skulls had a notable lingual foramen in that region [63].

Concerning bilateral recurrence of LLF, in a CT study of 70 patients, bilateral lingual canals were observed in 29.7% of the cases [64]. Another CT study carried out on 200 patients found a 44% frequency of bilateral LLF [54]. However, no information on the symmetry of LLFs was provided in both studies.

3.3.2. Morphometric Measurement of Lingual Foramina

The average size of MLF reported in the literature ranges from 0.6 to 1.17 mm. The smallest size was 0.1 mm in diameter and the largest was 2.29 mm. Higher mean values were found for the superior MLF (0.75–1.12 mm) than for the inferior MLF (0.58–0.9 mm) [61]. CBCT studies found a greater height than the width in the MLF, while an inverted ratio in the LLF [62]. Regarding ratios from the MLF or LLF to adjacent anatomical structures, distances from the lower edge of the mandible have been observed by several studies.

The average distance to the lower edge of the mandible ranged from 12 to 18.4 mm for the superior MLF and from 2.2 to 7 mm for the inferior MLF [61]. Only two studies [65,66] evaluated the distance from the MLF to the alveolar crest because measurements and comparisons are hampered by periodontal diseases or atrophic bone. The average distances from the superior MLF to the alveolar crest were 14.2 mm [65] and 14.4 mm [66]. For LLF, the average distances from the lower edge of the mandible ranged from 5.3 to 11.5 mm. The reported distance of LLF of the incisor/canine area from the inferior edge of the mandible was 11.5 mm, while the distance of LLF of the premolar/molar area was 7.1 mm.

3.3.3. Canals of Lingual Foramina

MLF is always associated with a canal, often described in radiology textbooks as a radiopaque area surrounding the lingual foramen.

The medial lingual canal may be located superiorly, at the same level, or inferior to the genial tubercles. The MLC is almost always (99%) perpendicular to the mandibular lingual borders, from an axial view [62]. From the sagittal view, the superior MLC usually runs in an anteroinferior direction, whereas the inferior MLC runs in an anterosuperior direction [54,62]. In addition, the s-MLC can rarely run horizontally or upward (3% and 1%), while the i-MLC sometimes runs horizontally or downward (3% and 21%) [66]. As reported in some studies, the MLC may join the lingual and labial plaques [60].

It was reported that a lingual canal associated with LLF occurs in 95% of individuals. From the axial view, LLCs usually course anterior to the foramen (43%), even if 21% also course perpendicular to the lingual bone surface of the mandible [61,62].

Despite the fact that the most common type of lingual vascular canal is the single canal (77%), studies observed that 20% have bifurcations and 3% triple canals [67].

3.3.4. Content of Lingual Foramina and Canals

The LLF contains a branch of the submental artery, which may form an anastomosis with the lingual branch of the inferior alveolar artery or be independent and give branches supplying the incisive area and the lower lip.

In cases where anastomosis occurs, the inferior alveolar artery also supplies the incisive area [68,69].

LLC arising from the premolar region anastomoses with the incisor canal about 87% of the time and with the mandibular canal, 38% of the time [62]. Anastomoses with the mandibular canal can form in the anterior loop, in the area adjacent to the mental foramen, or posterior to the mental foramen [56]. In the incisor–canine region, all communication occurs with the incisor canal [62], thus connecting the CLL with the area concerning the mental nerve. For that reason, the occurrence of the lateral lingual foramen is a strong predictor of communication with the incisor canal [61].

The superior MLC contains branches of the lingual artery and vein. The superior MLC and anterior MLC are crossed by an anastomosing branch of the sublingual artery [59,60]. The inferior MLC includes submental or sublingual branches [60]. The MLCs do not connect in 92% of cases [62]. When they anastomose, the artery in the MLC may anastomose with the incisive artery in 8–40% of cases but less frequently than in MLC anastomoses with the incisive canal. That is because this canal is not typically present in the middle of the symphysis [56,62,67].

The superior MLC contains a branch of the lingual nerve, while the inferior MLC contains a branch of the mylohyoid nerve [60].

3.3.5. Clinical Significance

In light of the significant neurovascular content of both MLC and LLC and given the involvement of the interforaminal region in many surgical procedures, a thorough awareness of the location, size, and content of these structures is of utmost importance in daily clinical practice.

Dental Implantation

Implant rehabilitation represents one of the most common rehabilitative procedures that are performed in the interforaminal area in edentulous patients with bone atrophy. Implant placement allows recovery of function and aesthetics by taking advantage of an anatomical area that is considered surgically safe.

Nevertheless, after tooth loss, horizontal bone resorption occurs, drastically reducing the distance between the lingual foramen and the bone crest: this results in an increased risk of intra- and post-operative complications. Thus, the presence of at least one lingual foramen in almost all patients has prompted increased interest in identifying the exact position of MLF and LLF and the possible management of vessel injury therein.

Haemorrhage

Hemorrhages occurring in association with surgery can be late or early. The latter is most often caused by perforation of the lingual cortical. Intraoperative injury to the interforaminal lingual cortical may result in damage to the sublingual artery, submental artery as well as the inferior alveolar artery branch, which leads to an oral floor haematoma [70].

Since the interforaminal lingual cortical area is characterized by a rich blood supply, if the haemorrhage persists, it could cause an upward dislocation of the oral floor and tongue, leading to a potentially fatal upper airway obstruction [59,66].

In addition, in some individuals with mylohyoid muscle defects, haemorrhage from the sublingual space may extend to the submandibular space, causing airway obstruction as well [68]. Airway patency can be regained by intubation and tracheostomy. A better assessment of mandibular anatomy is therefore essential to avoid complications related to lingual cortical perforation [70].

Knowledge of the distance between the lingual canal and the alveolar ridge is particularly important in surgical procedures such as implant placement, as immediate implants placed deeper than the natural alveolus and implant platform preparation can damage the lingual canals [67]. Long dental implants should not be placed in canine regions and atrophic jaws. In all cases in which implant placement caused life-threatening haemorrhage, a drilling depth greater than 15 mm was observed to cause perforation of the lingual cortical [54,71]. Edema is the result of surgical bleeding and, if observed, should be immediately controlled. Additional prescription of antibiotics and steroids might be helpful when the bleeding resolves [72].

3.4. *Canalis Sinuosus*

The *Canalis Sinuosus* (CS) is a tortuous intraosseous canal that originates from the infraorbital nerve. It emerges posterior to the infraorbital foramen and runs in an anterolateral direction up to the anterior wall of the nasal cavity below the orbital margin, at this point, it turns sharply downwards along the pyriform opening describing an S-shaped course and then heading towards the low and emerge into the palatine mucosa through an accessory foramen (Figure 4). The term *Canalis Sinuosus* (CS) describes the double curvature of the latter, which runs for about 55 mm along the maxilla and is characterized by a thin overlying bone that makes it more susceptible to injury in case of trauma. For this reason, it is considered an important branch of the orbital nerve (ION). The anterosuperior alveolar nerve (ASAN) and corresponding veins and arteries run within it. The CS commonly presents anatomic variations anterior to the incisive canals in the anterior palate, called accessory channels (ACs). The neurovascular branches in the CS innervate incisor and canine region and adjacent soft tissues through the dental plexus [73].

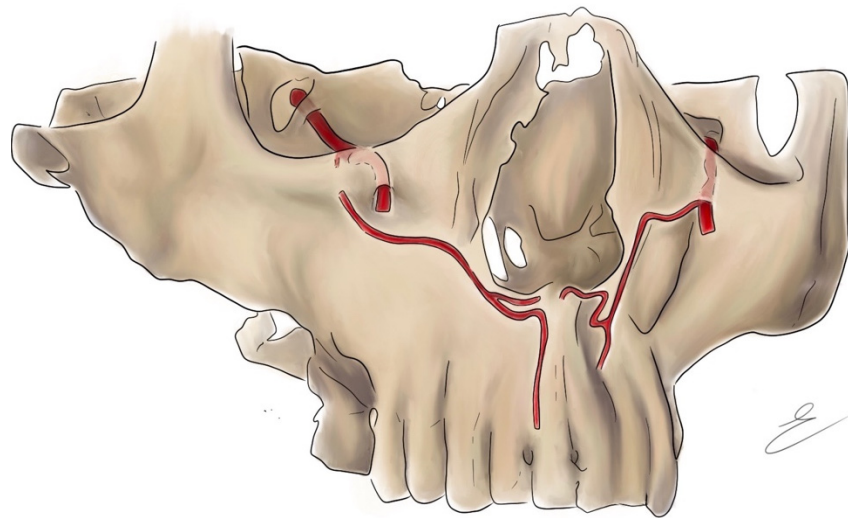


Figure 4. Schematic illustration of Canalis Sinuosus (CS) originating from the infraorbital canal. Copyright © 2022 Maria Elisabetta Campogrande.

3.4.1. Prevalence of CS

According to Wanzeler et al. (2015) and Gurler et al. (2017), the frequency of CS in the patients of these studies was 88% and 100% respectively [74,75].

In a study conducted by Oliveria-Santos et al. (2013), of a total of 178 patients, 28 presented ACs that were at least 1 mm in diameter, of which fourteen had a direct extension with the CS [73]. In Von Arx et al.'s (2015) study, ACs larger than 1.00 mm were found in 49 patients, and 56.7% of the ACs had a direct extension with the CS [76]. Machado et al. (2016), Ghandourah et al. (2017), and Orhan et al.'s (2018) studies provided similar results, reporting 52.1%, 67.6%, and 70.8% of ACs being interconnected with CSs, respectively [77–79]. The studies by Wanzeler et al. (2015) and Gurler et al. (2017) characterized the frequency of CS as 88% and 100%, respectively [74,75]. Oliveira-Santos et al. (2013) analyzed the frequency of the ACs, discovering that out of a total of 178 patients, 28 presented ACs that were at least 1 mm in diameter and that fourteen of their samples had a direct extension with the CS [73]. In the investigation of Von Arx et al. [76], ACs larger than 1.00 mm were found in 49 patients, and 38 (56.7%) of the ACs had a direct extension with the CS. Similar findings were observed in the studies by Machado et al. (2016), Ghandourah et al. (2017), and Orhan et al. (2018), who reported 52.1%, 67.6%, and 70.8% of the ACs, respectively, being interconnected with the CS [77–79].

3.4.2. Morphometric Measurement of CS

Most studies have focused on the terminal portion of the CS, showing that the final portions of the CS and the ACs variations are more frequent in the incisor and canine region near the palate [75,80].

Most of the studies found no significant statistical difference in frequency [74,75,80]; only one study showed the left side as more commonly affected [81].

The average diameter of the CS was found to be approximately 1 mm.

Regarding the diameter of ACs: Oliveira Santos et al. found a mean value of 1.4 mm [73]; Von Arx et al. of 1.3 mm [76]; Machado et al. of 1.0 mm [77].

3.4.3. Clinical Significance

There are many surgical procedures involving the anterior maxilla from all branches of dentistry: endodontics, periodontology, implantology, oral surgery and orthognathic [76].

Because of its anatomic course, the CS should be always considered in the treatment planning and outcome of dental surgery.

In implantology, invasion of the neurovascular bundle of the CS and Acs can compromise osseointegration and cause temporary or permanent paresthesia as well as blood loss and neurovascular disturbance in the region [82,83].

CS injuries may result in a clinical condition known as post-traumatic midface pain, characterized by paroxysmal neuropathic pain localized to the central and lateral incisors, canines, and maxilla. These symptoms are related to ASAN involvement. Injuries to ASAN can occur after midface fractures but can also be iatrogenic, following Lefort I-type osteotomies or dental surgery [84].

For all the reasons just listed, it is essential to know the trajectory and calibre of CS during the surgical programming phase. At present, some authors report essential the individuation of the CS in order to avoid the risk of haemorrhage and paraesthesia [83,85]. Jacobs et al. (2000) analysed the anatomical structures of the maxillary bones and any associated risks. The authors claim that there is great individual variability regarding the presence and the course of the CS and Acs. The identification of these anatomical structures in any surgical intervention in the maxillary region is essential. To avoid complications, it is very important surgical programming through radiographic examinations of the second level [86].

4. Discussion

Anatomically, the structures of significance in oral surgery contain neurovascular bundles and related foramina that, both in their classical anatomy and in their anatomical variations, are of crucial importance in the vascularization and innervation of dental structures and their surrounding tissues. Their knowledge allows professionals to select an appropriate approach to the patient's requirements.

This study shows that the reported prevalence of RMC is 24.6–75.4%, RMF is 7.33–12.4%, AMF is 2–13%, and MLF is 96–100%, while that of CS is 88–100%. Thus, these are anatomical variants that can be termed anything but rare and may be encountered with relative frequency in surgical practice.

The diagnosis of these variations has been changing as technology has evolved. In the first reported studies, the findings were presented on the basis of cadaveric mandibles and in the best of cases PANs [87], where it was often difficult to find them due to the ghost images that are generated in relation to the superposition of adjacent structures which is expected within a 2D image.

Currently, the range of tools available to diagnose anatomical variations of any neurovascular channel in the oro-maxillofacial territory has made the CBCT technique the first preference or the one with the best clinical acceptance. This is thanks to the high quality of 3D images that allow better investigation forms the presence of these variations within the mandibular and maxillary structure.

This review describes the clinical implications of encountering each of the listed variables. The main complications that can be found arise from the neurovascular content of these structures and are represented by marked bleeding, temporary or permanent sensitivity changes of the supplied areas, as well as local anaesthesia failure. Further, these accessory foramina may present an entry point and the related canals may act as a route of infection or, most rarely, tumour metastases [32,88].

The clinician's awareness of such eventualities should always be kept in mind during surgical procedures in order to be able to manage them properly.

5. Conclusions

The anatomical variations of the oromaxillofacial district occur with a relatively high incidence. Knowledge of them is of crucial importance both for professors, who provide morphological training, and for professional surgeons, who work daily in the oromaxillofacial territory. In addition, it is very important to have new lines of research that focus their efforts on describing and diagnosing these anatomical variations and being able to associate in which ethnic groups or genders it occurs in greater frequency.

In conclusion, all health professionals must continually challenge themselves in knowing the different anatomical variations that the human body presents and how these may affect clinical practice in order to perform a surgery that is as safe and minimally invasive as possible.

Author Contributions: Conceptualization, L.S. and F.Z.; methodology, F.Z.; software, L.S.; validation, A.C.; formal analysis, A.C.; investigation, L.S., F.Z. and G.P.; resources, A.C.; data curation, L.S., M.E.C. and G.P.; writing—original draft preparation, L.S. and F.Z.; writing—review and editing, L.S.; visualization, A.C.; supervision, A.C.; project administration, A.C. All authors have read and agreed to the published version of the manuscript.

Funding: This research received no external funding.

Institutional Review Board Statement: Not applicable.

Informed Consent Statement: Not applicable.

Conflicts of Interest: The authors declare no conflict of interest.

References

1. Żytkowski, A.; Tubbs, R.S.; Iwanaga, J.; Clarke, E.; Polguy, M.; Wysiadecki, G. Anatomical normality and variability: Historical perspective and methodological considerations. *Transl. Res. Anat.* **2021**, *23*, 100105. [[CrossRef](#)]
2. Kieser, J.; Kieser, D.; Hauman, T. The course and distribution of the inferior alveolar nerve in the edentulous mandible. *J. Craniofac. Surg.* **2005**, *16*, 6–9. [[CrossRef](#)] [[PubMed](#)]
3. White, S.C.; Pharoah, M.J. *Oral Radiology-E-Book: Principles and Interpretation*; Elsevier Health Sciences: St. Louis, MI, USA, 2014; ISBN 0-323-09634-4.
4. Motamedi, M.H.K.; Gharedaghi, J.; Mehralizadeh, S.; Navi, F.; Badkoobeh, A.; Valaei, N.; Azizi, T. Anthropomorphic assessment of the retromolar foramen and retromolar nerve: Anomaly or variation of normal anatomy? *Int. J. Oral Maxillofac. Surg.* **2016**, *45*, 241–244. [[CrossRef](#)]
5. Ossenberg, N.S. Retromolar foramen of the human mandible. *Am. J. Phys. Anthropol.* **1987**, *73*, 119–128. [[CrossRef](#)]
6. Von Arx, T.; Hänni, A.; Sendi, P.; Buser, D.; Bornstein, M.M. Radiographic study of the mandibular retromolar canal: An anatomic structure with clinical importance. *J. Endod.* **2011**, *37*, 1630–1635. [[CrossRef](#)]
7. Patil, S.; Matsuda, Y.; Nakajima, K.; Araki, K.; Okano, T. Retromolar canals as observed on cone-beam computed tomography: Their incidence, course, and characteristics. *Oral Surg. Oral Med. Oral Pathol. Oral Radiol.* **2013**, *115*, 692–699. [[CrossRef](#)]
8. Zhang, Y.-Q.; Zhao, Y.-N.; Liu, D.-G.; Meng, Y.; Ma, X.-C. Bifid variations of the mandibular canal: Cone beam computed tomography evaluation of 1000 Northern Chinese patients. *Oral Surg. Oral Med. Oral Pathol. Oral Radiol.* **2018**, *126*, e271–e278. [[CrossRef](#)]
9. Luangchana, P.; Pornprasertsuk-Damrongsri, S.; Kitisubkanchana, J.; Wongchuensoontorn, C. The retromolar canal and its variations: Classification using cone beam computed tomography. *Quintessence Int.* **2018**, *49*, 61–67.
10. Lizio, G.; Pelliccioni, G.A.; Ghigi, G.; Fanelli, A.; Marchetti, C. Radiographic assessment of the mandibular retromolar canal using cone-beam computed tomography. *Acta Odontol. Scand.* **2013**, *71*, 650–655. [[CrossRef](#)]
11. Park, M.-K.; Jung, W.; Bae, J.-H.; Kwak, H.-H. Anatomical and radiographic study of the mandibular retromolar canal. *J. Dent. Sci.* **2016**, *11*, 370–376. [[CrossRef](#)]
12. Capote, T.S.d.O.; de Almeida Gonçalves, M.; Campos, J.Á.D.B. Retromolar canal associated with age, side, sex, bifid mandibular canal, and accessory mental foramen in panoramic radiographs of Brazilians. *Anat. Res. Int.* **2015**, *2015*, 434083. [[CrossRef](#)] [[PubMed](#)]
13. Sisman, Y.; Ercan-Sekerci, A.; Payveren-Arkan, M.; Sahman, H. Diagnostic accuracy of cone-beam CT compared with panoramic images in predicting retromolar canal during extraction of impacted mandibular third molars. *Med. Oral Patol. Oral Cir. Bucal* **2015**, *20*, e74. [[CrossRef](#)] [[PubMed](#)]
14. Palma, L.F.; Buck, A.F.; Kfoury, F.d.Á.; Blachman, I.T.; Lombardi, L.A.; Cavalli, M.A. Evaluation of retromolar canals on cone beam computerized tomography scans and digital panoramic radiographs. *Oral Maxillofac. Surg.* **2017**, *21*, 307–312. [[CrossRef](#)] [[PubMed](#)]
15. Fuentes, R.; Arias, A.; Farfán, C.; Astete, N.; Garay, I.; Navarro, P.; Dias, F.J. Morphological variations of the mandibular canal in digital panoramic radiographs: A retrospective study in a Chilean population. *Folia Morphol.* **2019**, *78*, 163–170. [[CrossRef](#)] [[PubMed](#)]
16. Kikuta, S.; Iwanaga, J.; Nakamura, K.; Hino, K.; Nakamura, M.; Kusukawa, J. The retromolar canals and foramina: Radiographic observation and application to oral surgery. *Surg. Radiol. Anat.* **2018**, *40*, 647–652. [[CrossRef](#)] [[PubMed](#)]
17. Iwanaga, J.; Watanabe, K.; Saga, T.; Tubbs, R.S.; Tanaka, K.; Kikuta, S.; Tabira, Y.; Fisahn, C.; Kamura, Y.; Kusukawa, J. A novel method for observation of the mandibular foramen: Application to a better understanding of dental anatomy. *Anat. Rec.* **2017**, *300*, 1875–1880. [[CrossRef](#)] [[PubMed](#)]

18. Li, Y.; Yafei, C.; Jun, P.; Yuanyuan, L.; Shuqun, Q.; Jian, P. Cone beam computed tomography evaluation of bifid mandibular canals in the adult population in Sichuan Province. *Hua Xi Kou Qiang Yi Xue Za Zhi Huaxi Kouqiang Yixue Zazhi West China J. Stomatol.* **2017**, *35*, 82–88.
19. Kang, J.-H.; Lee, K.-S.; Oh, M.-G.; Choi, H.-Y.; Lee, S.-R.; Oh, S.-H.; Choi, Y.-J.; Kim, G.-T.; Choi, Y.-S.; Hwang, E.-H. The incidence and configuration of the bifid mandibular canal in Koreans by using cone-beam computed tomography. *Imaging Sci. Dent.* **2014**, *44*, 53–60. [[CrossRef](#)]
20. Alves, N.; Deana, N.F. Anatomical and radiographical study of the retromolar canal and retromolar foramen in macerated mandibles. *Int. J. Clin. Exp. Med.* **2015**, *8*, 4292.
21. Jeyaseelan, N.; Sharma, J.K. Morphological study of unnamed foramina in north Indian human mandibles and its possible role in neurovascular transmission. *Int. J. Oral Surg.* **1984**, *13*, 239–242. [[CrossRef](#)]
22. Potu, B.K.; Kumar, V.; Salem, A.-H.; Abu-Hijleh, M. Occurrence of the retromolar foramen in dry mandibles of South-eastern part of India: A morphological study with review of the literature. *Anat. Res. Int.* **2014**, *2014*, 296717. [[CrossRef](#)] [[PubMed](#)]
23. Kawai, T.; Asaumi, R.; Sato, I.; Kumazawa, Y.; Yosue, T. Observation of the retromolar foramen and canal of the mandible: A CBCT and macroscopic study. *Oral Radiol.* **2012**, *28*, 10–14. [[CrossRef](#)]
24. Rossi, A.C.; Freire, A.R.; Prado, G.B.; Prado, F.B.; Botacin, P.R.; Ferreira Caria, P.H. Incidence of retromolar foramen in human mandibles: Ethnic and clinical aspects. *Int. J. Morphol.* **2012**, *30*, 1074–1078. [[CrossRef](#)]
25. Ngeow, W.C.; Chai, W.L. The clinical significance of the retromolar canal and foramen in dentistry. *Clin. Anat.* **2021**, *34*, 512–521. [[CrossRef](#)] [[PubMed](#)]
26. Muínelo-Lorenzo, J.; Suárez-Quintanilla, J.A.; Fernández-Alonso, A.; Marsillas-Rascado, S.; Suárez-Cunqueiro, M.M. Descriptive study of the bifid mandibular canals and retromolar foramina: Cone beam CT vs. panoramic radiography. *Dentomaxillofac. Radiol.* **2014**, *43*, 20140090. [[CrossRef](#)] [[PubMed](#)]
27. Lofgren, A.B. Foramina retromolaria mandibulae. *Odont Tidskr* **1957**, *65*, 552–570.
28. Bilodi, A.K.S.; Singh, S.; Ebenezer, D.A.; Suman, P.; Kumar, K. A study on retromolar foramen and other accessory foramina in human mandibles of Tamil Nadu region. *Int. J. Health Sci. Res.* **2013**, *3*, 61–65.
29. Shantharam, V.; Manjunath, K.Y.; Aruna, N.; Shastri, D. Retromolar foramen in South Indian mandibles. *Anat. Karnataka* **2013**, *7*, 34–37.
30. Haas, L.F.; Dutra, K.; Porporatti, A.L.; Mezzomo, L.A.; De Luca Canto, G.; Flores-Mir, C.; Corrêa, M. Anatomical variations of mandibular canal detected by panoramic radiography and CT: A systematic review and meta-analysis. *Dentomaxillofac. Radiol.* **2016**, *45*, 20150310. [[CrossRef](#)]
31. Tiwari, S.; Ramakrishna, R.; Sangeeta, M. A study on the incidence of retromolar foramen in South Indian adult dried human mandibles and its clinical relevance. *Int. J. Res. Med. Sci.* **2015**, *3*, 1383–1387. [[CrossRef](#)]
32. Bilecenoglu, B.; Tuncer, N. Clinical and anatomical study of retromolar foramen and canal. *J. Oral Maxillofac. Surg.* **2006**, *64*, 1493–1497. [[CrossRef](#)] [[PubMed](#)]
33. Arakeri, G.; Sagoo, M.G.; Brennan, P.A. Neurovascular plexus theory for “escape pain phenomenon” in lower third molar surgery. *Plast Aesthet Res.* **2015**, *2*, 107–110. [[CrossRef](#)]
34. Suazo Galdames, I.C.; Cantín López, M.G.; Zavando Matamala, D.A. Inferior alveolar nerve block anesthesia via the retromolar triangle, an alternative for patients with blood dyscrasias. *Med. Oral Patol. Oral Cir. Bucal* **2008**, *13*, E43–E47. [[PubMed](#)]
35. Azaz, B.; Lustmann, J. Anatomical configurations in dry mandibles. *Br. J. Oral Surg.* **1973**, *11*, 1–9. [[CrossRef](#)]
36. Singh, S. Aberrant buccal nerve encountered at third molar surgery. *Oral Surg. Oral Med. Oral Pathol.* **1981**, *52*, 142. [[CrossRef](#)]
37. Greenstein, G.; Tarnow, D. The mental foramen and nerve: Clinical and anatomical factors related to dental implant placement: A literature review. *J. Periodontol.* **2006**, *77*, 1933–1943. [[CrossRef](#)] [[PubMed](#)]
38. Toh, H.; Kodama, J.; Yanagisako, M.; Ohmori, T. Anatomical study of the accessory mental foramen and the distribution of its nerve. *Okajimas Folia Anat. Jpn.* **1992**, *69*, 85–88. [[CrossRef](#)] [[PubMed](#)]
39. Naitoh, M.; Hiraiwa, Y.; Aimiya, H.; Gotoh, K.; Arijji, E. Accessory mental foramen assessment using cone-beam computed tomography. *Oral Surg. Oral Med. Oral Pathol. Oral Radiol. Endodontol.* **2009**, *107*, 289–294. [[CrossRef](#)]
40. Iwanaga, J.; Saga, T.; Tabira, Y.; Nakamura, M.; Kitashima, S.; Watanabe, K.; Kusukawa, J.; Yamaki, K.-I. The clinical anatomy of accessory mental nerves and foramina. *Clin. Anat.* **2015**, *28*, 848–856. [[CrossRef](#)]
41. Iwanaga, J.; Saga, T.; Tabira, Y.; Watanabe, K.; Yamaki, K. A novel method for visualization of the inferior alveolar nerve for clinical and educational purposes. *J. Oral Biosci.* **2016**, *58*, 66–68. [[CrossRef](#)]
42. Iwanaga, J.; Watanabe, K.; Saga, T.; Kikuta, S.; Tabira, Y.; Kitashima, S.; Fisahn, C.; Alonso, F.; Tubbs, R.S.; Kusukawa, J. Undetected small accessory mental foramina using cone-beam computed tomography. *Cureus* **2017**, *9*, e1210. [[CrossRef](#)] [[PubMed](#)]
43. Aytugar, E.; Özeren, C.; Lacin, N.; Veli, I.; Çene, E. Cone-beam computed tomographic evaluation of accessory mental foramen in a Turkish population. *Anat. Sci. Int.* **2019**, *94*, 257–265. [[CrossRef](#)]
44. Rawlinson, J.E.; Bass, L.; Campoy, L.; Lesser, C.; Prytherch, B. Evaluation of the equine mental foramen block: Cadaveric and in vivo injectate diffusion. *Vet. Anaesth. Analg.* **2018**, *45*, 839–848. [[CrossRef](#)]
45. Velasco-Torres, M.; Padial-Molina, M.; Avila-Ortiz, G.; García-Delgado, R.; Catena, A.; Galindo-Moreno, P. Inferior alveolar nerve trajectory, mental foramen location and incidence of mental nerve anterior loop. *Med. Oral Patol. Oral Cir. Bucal* **2017**, *22*, e630. [[CrossRef](#)] [[PubMed](#)]

46. Zainy, M.A.A.M. *Mental Foramen and Accessory Mental Foramen Variations: A Systematic Review*; Boston University: Boston, MA, USA, 2020.
47. Muínelo-Lorenzo, J.; Suárez-Quintanilla, J.-A.; Fernández-Alonso, A.; Varela-Mallou, J.; Suárez-Cunqueiro, M.-M. Anatomical characteristics and visibility of mental foramen and accessory mental foramen: Panoramic radiography vs. cone beam CT. *Med. Oral Patol. Oral Cir. Bucal* **2015**, *20*, e707. [[CrossRef](#)] [[PubMed](#)]
48. Scarano, A.; Di Carlo, F.; Quaranta, A.; Piattelli, A. Injury of the inferior alveolar nerve after overfilling of the root canal with endodontic cement: A case report. *Oral Surg. Oral Med. Oral Pathol. Oral Radiol. Endodontol.* **2007**, *104*, e56–e59. [[CrossRef](#)] [[PubMed](#)]
49. Wismeijer, D.; Van Waas, M.A.J.; Vermeeren, J.I.J.F.; Kalk, W. Patients' perception of sensory disturbances of the mental nerve before and after implant surgery: A prospective study of 110 patients. *Br. J. Oral Maxillofac. Surg.* **1997**, *35*, 254–259. [[CrossRef](#)]
50. Elahi, F.; Manolitsis, N.; Ranganath, Y.S.; Reddy, C.G. Mental nerve neuropathy following dental extraction. *Pain Physician* **2014**, *17*, E375. [[CrossRef](#)]
51. Raju, N.; Zhang, W.; Jadhav, A.; Ioannou, A.; Eswaran, S.; Weltman, R. Cone-beam computed tomography analysis of the prevalence, length, and passage of the anterior loop of the mandibular canal. *J. Oral Implantol.* **2019**, *45*, 463–468. [[CrossRef](#)]
52. Lam, M.; Koong, C.; Kruger, E.; Tennant, M. Prevalence of accessory mental foramina: A study of 4000 CBCT scans. *Clin. Anat.* **2019**, *32*, 1048–1052. [[CrossRef](#)]
53. Fuentes, R.; Farfán, C.; Astete, N.; Garay, I.; Dias, F.; Arias, A. Bilateral bifid mandibular canal: A case report using cone beam computed tomography. *Folia Morphol.* **2018**, *77*, 780–784. [[CrossRef](#)] [[PubMed](#)]
54. Tagaya, A.; Matsuda, Y.; Nakajima, K.; Seki, K.; Okano, T. Assessment of the blood supply to the lingual surface of the mandible for reduction of bleeding during implant surgery. *Clin. Oral Implants Res.* **2009**, *20*, 351–355. [[CrossRef](#)] [[PubMed](#)]
55. Ikuta, C.R.S.; da Silva Ramos, L.M.P.; Poleti, M.L.; Capelozza, A.L.A.; Rubira-Bullen, I.R.F. Anatomical study of the posterior mandible: Lateral lingual foramina in cone beam computed tomography. *Implant Dent.* **2016**, *25*, 247–251. [[CrossRef](#)]
56. Katakami, K.; Mishima, A.; Kuribayashi, A.; Shimoda, S.; Hamada, Y.; Kobayashi, K. Anatomical characteristics of the mandibular lingual foramina observed on limited cone-beam CT images. *Clin. Oral Implants Res.* **2009**, *20*, 386–390. [[CrossRef](#)]
57. Di Bari, R.; Coronelli, R.; Cicconetti, A. Intraosseous vascularization of anterior mandible: A radiographic analysis. *J. Craniofac. Surg.* **2014**, *25*, 872–879. [[CrossRef](#)] [[PubMed](#)]
58. Tolstunov, L. Implant zones of the jaws: Implant location and related success rate. *J. Oral Implantol.* **2007**, *33*, 211–220. [[CrossRef](#)]
59. Rosano, G.; Taschieri, S.; Gaudy, J.F.; Testori, T.; Del Fabbro, M. Anatomic assessment of the anterior mandible and relative hemorrhage risk in implant dentistry: A cadaveric study. *Clin. Oral Implants Res.* **2009**, *20*, 791–795. [[CrossRef](#)]
60. Liang, X.; Jacobs, R.; Lambrichts, I.; Vandewalle, G. Lingual foramina on the mandibular midline revisited: A macroanatomical study. *Clin. Anat. Off. J. Am. Assoc. Clin. Anat. Br. Assoc. Clin. Anat.* **2007**, *20*, 246–251. [[CrossRef](#)]
61. von Arx, T.; Lozanoff, S. Lingual foramina and canals. In *Clinical Oral Anatomy*; Springer: Berlin/Heidelberg, Germany, 2017; pp. 463–487.
62. Von Arx, T.; Matter, D.; Buser, D.; Bornstein, M.M. Evaluation of location and dimensions of lingual foramina using limited cone-beam computed tomography. *J. Oral Maxillofac. Surg.* **2011**, *69*, 2777–2785. [[CrossRef](#)]
63. Yoshida, S.; Kawai, T.; Okutsu, K.; Yosue, T.; Takamori, H.; Sunohara, M.; Sato, I. The appearance of foramen in the internal aspect of the mental region of mandible from Japanese cadavers and dry skulls under macroscopic observation and three-dimensional CT images. *Okajimas Folia Anat. Jpn.* **2005**, *82*, 83–88. [[CrossRef](#)]
64. Tepper, G.; Hofschneider, U.B.; Gahleitner, A.; Ulm, C. Computed tomographic diagnosis and localization of bone canals in the mandibular interforaminal region for prevention of bleeding complications during implant surgery. *Int. J. Oral Maxillofac. Implants* **2001**, *16*, 68–72. [[PubMed](#)]
65. Babiuc, I.; Tarlungeanu, I.; Pauna, M. Cone beam computed tomography observations of the lingual foramina and their bony canals in the median region of the mandible. *Rom. J. Morphol. Embryol.* **2011**, *52*, 827–829.
66. Sheikhi, M.; Mosavat, F.; Ahmadi, A. Assessing the anatomical variations of lingual foramen and its bony canals with CBCT taken from 102 patients in Isfahan. *Dent. Res. J.* **2012**, *9*, S45.
67. Oettlé, A.C.; Fourie, J.; Human-Baron, R.; van Zyl, A.W. The midline mandibular lingual canal: Importance in implant surgery. *Clin. Implant Dent. Relat. Res.* **2015**, *17*, 93–101. [[CrossRef](#)] [[PubMed](#)]
68. Nakajima, K.; Tagaya, A.; Otonari-Yamamoto, M.; Seki, K.; Araki, K.; Sano, T.; Okano, T.; Nakamura, M. Composition of the blood supply in the sublingual and submandibular spaces and its relationship to the lateral lingual foramen of the mandible. *Oral Surg. Oral Med. Oral Pathol. Oral Radiol.* **2014**, *117*, e32–e38. [[CrossRef](#)]
69. Kawai, T.; Sato, I.; Yosue, T.; Takamori, H.; Sunohara, M. Anastomosis between the inferior alveolar artery branches and submental artery in human mandible. *Surg. Radiol. Anat.* **2006**, *28*, 308–310. [[CrossRef](#)]
70. He, P.; Truong, M.K.; Adeeb, N.; Tubbs, R.S.; Iwanaga, J. Clinical anatomy and surgical significance of the lingual foramina and their canals. *Clin. Anat.* **2017**, *30*, 194–204. [[CrossRef](#)] [[PubMed](#)]
71. Scaravilli, M.S.; Mariniello, M.; Sammartino, G. Mandibular lingual vascular canals (MLVC): Evaluation on dental CTs of a case series. *Eur. J. Radiol.* **2010**, *76*, 173–176. [[CrossRef](#)]
72. Kim, D.H.; Kim, M.Y.; Kim, C.-H. Distribution of the lingual foramina in mandibular cortical bone in Koreans. *J. Korean Assoc. Oral Maxillofac. Surg.* **2013**, *39*, 263. [[CrossRef](#)]

73. de Oliveira-Santos, C.; Rubira-Bullen, I.R.; Monteiro, S.A.; León, J.E.; Jacobs, R. Neurovascular anatomical variations in the anterior palate observed on CBCT images. *Clin. Oral Implants Res.* **2013**, *24*, 1044–1048. [[CrossRef](#)]
74. Wanzeler, A.M.V.; Marinho, C.G.; Junior, S.M.A.; Manzi, F.R.; Tuji, F.M. Anatomical study of the canalis sinuosus in 100 cone beam computed tomography examinations. *Oral Maxillofac. Surg.* **2015**, *19*, 49–53. [[CrossRef](#)] [[PubMed](#)]
75. Gurler, G.; Delilbasi, C.; Ogut, E.E.; Aydin, K.; Sakul, U. Evaluation of the morphology of the canalis sinuosus using cone-beam computed tomography in patients with maxillary impacted canines. *Imaging Sci. Dent.* **2017**, *47*, 69–74. [[CrossRef](#)] [[PubMed](#)]
76. von Arx, T.; Lozanoff, S. Anterior superior alveolar nerve (ASAN). *Swiss Dent. J.* **2015**, *125*, 1202–1209. [[PubMed](#)]
77. Machado, V.d.C.; Chrcanovic, B.R.; Felipe, M.B.; Júnior, L.M.; De Carvalho, P.S.P. Assessment of accessory canals of the canalis sinuosus: A study of 1000 cone beam computed tomography examinations. *Int. J. Oral Maxillofac. Surg.* **2016**, *45*, 1586–1591. [[CrossRef](#)] [[PubMed](#)]
78. Ghandourah, A.O.; Rashad, A.; Heiland, M.; Hamzi, B.M.; Friedrich, R.E. Cone-beam tomographic analysis of canalis sinuosus accessory intraosseous canals in the maxilla. *GMS Ger. Med. Sci.* **2017**, *15*, Doc20.
79. Orhan, K.; Gorurgoz, C.; Akyol, M.; Ozarslanturk, S.; Avsever, H. An anatomical variant: Evaluation of accessory canals of the canalis sinuosus using cone beam computed tomography. *Folia Morphol.* **2018**, *77*, 551–557. [[CrossRef](#)]
80. Von Arx, T.; Lozanoff, S.; Sendi, P.; Bornstein, M.M. Assessment of bone channels other than the nasopalatine canal in the anterior maxilla using limited cone beam computed tomography. *Surg. Radiol. Anat.* **2013**, *35*, 783–790. [[CrossRef](#)]
81. Manhães Júnior, L.R.C.; Villaça-Carvalho, M.F.L.; Moraes, M.E.L.; Lopes, S.L.P.d.C.; Silva, M.B.F.; Junqueira, J.L.C. Location and classification of Canalis sinuosus for cone beam computed tomography: Avoiding misdiagnosis. *Braz. Oral Res.* **2016**, *30*, e49. [[CrossRef](#)]
82. McCrea, S.J. Aberrations causing neurovascular damage in the anterior maxilla during dental implant placement. *Case Rep. Dent.* **2017**, *2017*, 5969643. [[CrossRef](#)]
83. Torres, M.G.G.; de Faro Valverde, L.; Vidal, M.T.A.; Crusoé-Rebello, I.M. Branch of the canalis sinuosus: A rare anatomical variation—A case report. *Surg. Radiol. Anat.* **2015**, *37*, 879–881. [[CrossRef](#)]
84. Olenczak, J.B.; Hui-Chou, H.G.; Aguila III, D.J.; Shaeffer, C.A.; Dellon, A.L.; Manson, P.N. Posttraumatic midface pain: Clinical significance of the anterior superior alveolar nerve and canalis sinuosus. *Ann. Plast. Surg.* **2015**, *75*, 543–547. [[CrossRef](#)] [[PubMed](#)]
85. Arruda, J.A.; Silva, P.; Silva, L.; Álvares, P.; Silva, L.; Zavanelli, R.; Rodrigues, C.; Gerbi, M.; Sobral, A.P.; Silveira, M. Dental implant in the canalis sinuosus: A case report and review of the literature. *Case Rep. Dent.* **2017**, *2017*, 4810123. [[CrossRef](#)] [[PubMed](#)]
86. Jacobs, R.; Quirynen, M.; Bornstein, M.M. Neurovascular disturbances after implant surgery. *Periodontol. 2000* **2014**, *66*, 188–202. [[CrossRef](#)] [[PubMed](#)]
87. Valenzuela-Fuenzalida, J.J.; Cariseo, C.; Gold, M.; Díaz, D.; Orellana, M.; Iwanaga, J. Anatomical variations of the mandibular canal and their clinical implications in dental practice: A literature review. *Surg. Radiol. Anat.* **2021**, *43*, 1259–1272. [[CrossRef](#)]
88. Fanibunda, K.; Matthews, J.N.S. The relationship between accessory foramina and tumour spread on the medial mandibular surface. *J. Anat.* **2000**, *196*, 23–29. [[CrossRef](#)]