

Headache in Sturge–Weber syndrome: A systematic review

Cephalalgia

2024, Vol. 44(7) 1–17

© International Headache Society 2024


Article reuse guidelines:

sagepub.com/journals-permissions

DOI: 10.1177/03331024241265881

journals.sagepub.com/home/cep



Alessandro Ferretti¹ , Marta Muscianese², Claudia Fanfoni³, Giulia Bellone¹, Maurizio Mennini¹, Giovanni Di Nardo¹, Solmaz Abdolrahimzadeh⁴, Gabriella De Marco⁵, Alessandro Orsini⁶, Thomas Foadelli⁷, Iliara Frattale⁸, Massimiliano Valeriani^{8,9,10} , and Pasquale Parisi¹ 

Abstract

Background: Sturge–Weber syndrome (SWS) is a neurocutaneous disorder for which the neurological aspects, particularly headaches, remain poorly understood, despite significantly affecting morbidity. The present study aimed to elucidate the prevalence, characteristics and treatment strategies, as well as explore the pathogenesis of headaches, in SWS.

Methods: Using Preferred Reporting Items for Systematic reviews and Meta-Analyses (PRISMA) guidelines, we systematically reviewed observational studies, case reports and series from eight databases (Cochrane Library, EBSCO, Embase, Medline, PubMed, Science Direct, Scopus and Web of Science), published from 1978 to 2023, to investigate the prevalence, characteristics, medication response and pathogenic theories of headaches in SWS.

Results: The review analyzed 48 studies, uncovering headache prevalence between 37% and 71%. Migraine-like headache affected up to 52% of individuals. Prophylactic and acute treatments included non-steroidal anti-inflammatory drugs, triptans and antiepileptic drugs, despite the lack of established guidelines. Life-threatening headaches in SWS are uncommon, typically accompanied by other neurological symptoms. The pathogenesis of headaches in SWS is considered to involve venous congestion and neuronal hyperexcitability linked to leptomeningeal angiomas.

Conclusions: Headaches occur more frequently in individuals with SWS than in the general population. Despite symptoms meeting migraine criteria, these headaches should be considered secondary to vascular conditions. Implementing acute and prophylactic treatment is advised to reduce the impact on patients' lives.

Keywords

headache, migraine, secondary headache, Sturge–Weber syndrome, systematic review

Date received: 22 May 2024; accepted: 16 June 2024

¹Pediatrics Unit, Neuroscience, Mental Health and Sense Organs (NESMOS) Department, Faculty of Medicine and Psychology, Sapienza University of Rome, Rome, Italy

²Private Practice, Rome, Italy

³Pediatrics and Neonatology Unit, Maternal-Child Department, Santa Maria Goretti Hospital, Latina, Italy

⁴Ophthalmology Unit, Neurosciences, Mental Health, and Sense Organs (NESMOS) Department, Sapienza University of Rome, Rome, Italy

⁵Dermatology Unit, Neuroscience, Mental Health and Sense Organs (NESMOS) Department, Faculty of Medicine and Psychology, Sapienza University of Rome, Rome, Italy

⁶Pediatric Neurology, Pediatric University Department, Azienda Ospedaliera Universitaria Pisana, University of Pisa, Pisa, Italy

⁷Pediatric Clinic, Fondazione IRCCS Policlinico San Matteo, Pavia, Italy

⁸Systems Medicine Department, University of Rome Tor Vergata, Rome, Italy

⁹Developmental Neurology, Bambino Gesù Children Hospital, IRCCS, Rome, Italy

¹⁰Center for Sensory-Motor Interaction, Aalborg University, Aalborg, Denmark

Corresponding author:

Alessandro Ferretti, Pediatrics Unit, Neuroscience, Mental Health and Sense Organs (NESMOS) Department, Faculty of Medicine and Psychology, Sapienza University of Rome, Via di Grottarossa n. 1035/1039, 00189, Rome, Italy.

Email: alessandro.ferretti@uniroma1.it



Introduction

Sturge–Weber syndrome (SWS) is a sporadically occurring neurocutaneous disorder characterized by a port-wine stain (PWS) on the face, ocular anomalies and leptomeningeal angiomas (1,2). SWS occurs in approximately 1 in 20,000 to 50,000 live births (2,3). The syndrome results from a somatic activating mutation in GNAQ gene (4). The late origin of this somatic GNAQ mutation in vascular endothelial cells often leads to partial or incomplete manifestations of SWS. Consequently, SWS is categorized into three types: type I, featuring facial, choroidal and leptomeningeal angiomas with possible glaucoma; type II, characterized by facial angiomas without apparent endocranial involvement; and type III, presenting exclusive leptomeningeal angiomas (5). Individuals with SWS can exhibit varying degrees of neurological impairment, such as headache, epilepsy, hemiparesis, transient stroke-like neurologic deficits, stroke, visual field abnormalities, intellectual disability, behavioral challenges and psychiatric involvement. Significantly, the International Classification of Headache Disorders, 3rd edition (ICHD-3) (6) includes the diagnosis “Headache attributed to encephalotrigeminal or leptomeningeal angiomatosis (Sturge–Weber syndrome)” (ICHD-3 code: 6.3.5) among the secondary forms, indicating that encephalotrigeminal or leptomeningeal angiomatosis may contribute particularly to attacks with prolonged and/or motor auras (potentially linked to chronic oligemia). The diagnostic criteria specify that the headache may exhibit non-migraine or migraine characteristics. In the latter case, it could be either bilateral or localized to the site of the angioma, accompanied by aura contralateral to the angioma site. Despite this secondary form classified by the ICHD-3, characteristics and associations of headache with SWS are largely unknown.

In this systematic review, we sought to estimate the prevalence of headaches among individuals with SWS and assess the impact of this comorbidity on their quality of life. We examined the characteristics of primary and secondary headaches, including those with potential life-threatening outcomes, and evaluated both acute and prophylactic headache treatments. Additionally, we briefly explored the features of hemiplegic migraine, often closely related to the headache. Finally, we discuss the pathogenesis of headaches in this syndrome, aiming to elucidate the interrelationship between it and the examined features.

Methods

In our investigation, we systematically explored the individuals diagnosed with SWS and experiencing headaches, as described in the literature. Our primary focus was on scrutinizing observational studies (both prospective and retrospective cohort studies), case reports and case series

cataloged in major medical databases, including the Cochrane Library, EBSCO, Embase, Medline, PubMed, Science Direct, Scopus and Web of Science, covering the period from January 1978 to December 2023. Our search strategy encompassed specific terms: (1) “Sturge Weber” and “headache” and (2) “Sturge Weber” and “migraine.” Additionally, we meticulously reviewed the references cited in the identified articles to unearth any supplementary publications meeting our research criteria. For this systematic review, the Preferred Reporting Items for Systematic Reviews and Meta-Analyses (PRISMA) guidelines (7) were followed. To ensure methodological consistency in data extraction and analysis across the reviewed studies, we employed a standardized form to capture the following details: the primary author’s name, publication year, study design, number of individuals studied, prevalence of headache, impact on quality of life, demographic characteristics, features of the headache (including triggering factors, positive family history for headache/migraine, comorbidities with other conditions often associated with the syndrome such as glaucoma or epilepsy), type of SWS, diagnostic procedures, acute and prophylactic treatments, clinical outcomes, secondary causes of headache in the studied population, characteristics of hemiplegic migraine in the selected individuals, and pathogenic hypotheses. Exclusion criteria comprised other types of articles, such as reviews, commentaries and letters to the editor. The extracted data were then reported unchanged but grouped cohesively by the analyzed item, specifying any emerging differences. Non-English language articles were also excluded from consideration. Ethical approval was deemed unnecessary for the preparation of this article.

Results

The results of the literature search and screening

In total, 498 studies were initially identified through the electronic database search. After eliminating 278 duplicate studies, 220 studies remained for screening. During the screening process, 13 articles were inaccessible and 74 articles unrelated to SWS were excluded. Among these, six articles that did not meet the criteria of being case reports, case series or observational studies were also excluded. Furthermore, 62 articles did not describe individuals with headaches, and 17 articles lacked full-text availability. Finally, 48 articles met all the inclusion criteria and were included in the systematic review. Among these, 37 were case reports or case series (8–44), seven were retrospective observational studies based on medical records (45–51) and four studies were conducted using observational questionnaires (52–55). The flow diagram of the study selection process according to the PRISMA guidelines is shown in Figure 1. Epidemiology and characteristics of SWS and headache from the selected studies, including the type of

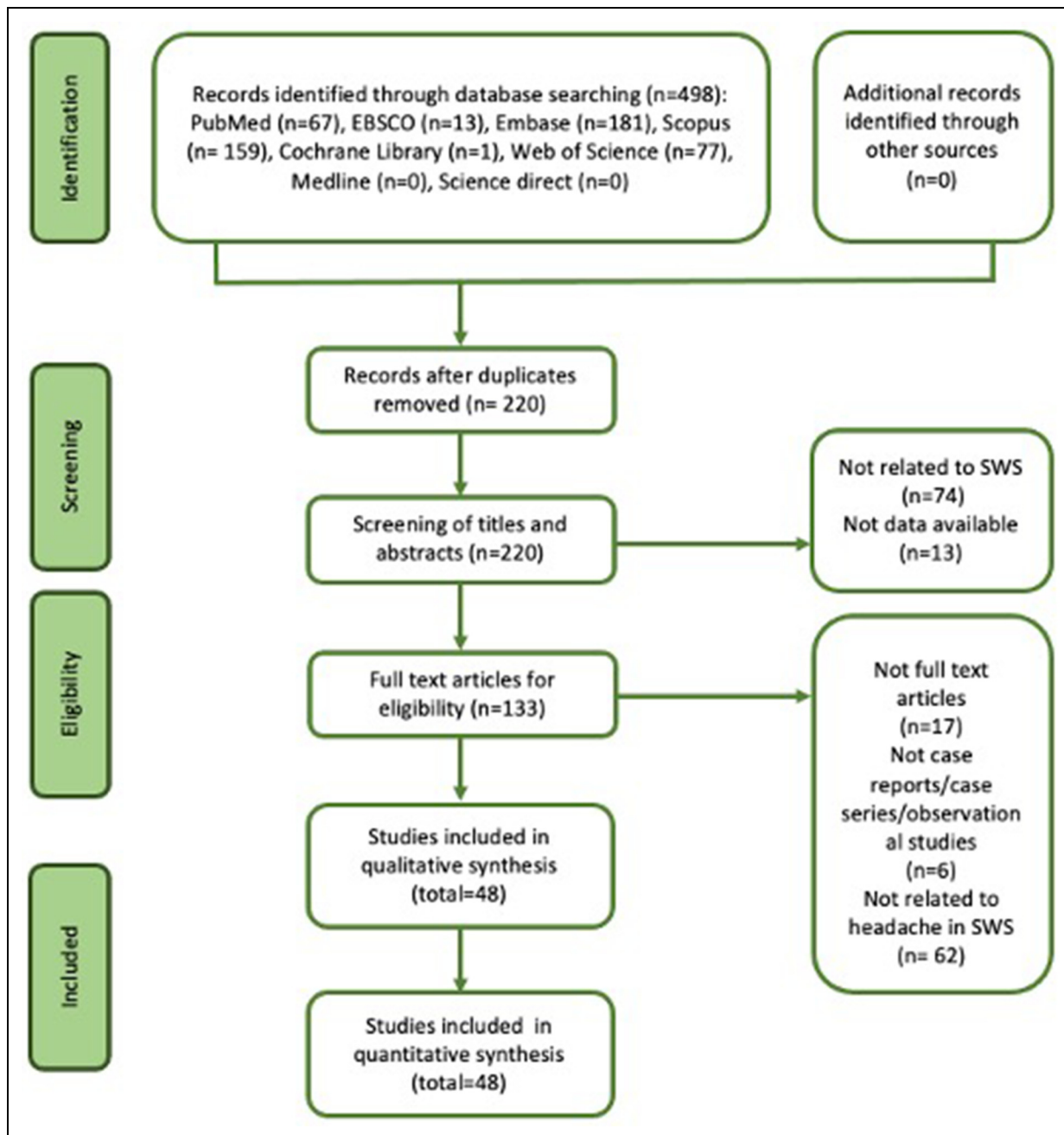


Figure 1. Flow diagram of study selection process. SWS = Sturge–Weber syndrome

SWS, age of headache onset, headache features, secondary causes suggested by the study, efficacy of acute and prophylactic treatments, and the possible presence of hemiplegic migraine associated with the headache, are reported in Table 1.

Headache prevalence and impact on quality of life

Prevalence estimates of headaches in SWS ranged from 37–57% in two exclusively pediatric populations observed

retrospectively (46,49). The percentage remains consistent across studies involving both pediatric and adult populations, with values ranging from 39.4% (56) to 44% (53), and up to 71% in a population-based study that utilized specifically structured questionnaires (55).

From an extensive observational study involving 556 patients, it was revealed that 16% experienced a delayed diagnosis of SWS, with 68% of these cases exhibiting clear pre-existing comorbidities, particularly headaches (52). Nevertheless, individuals with PWS or recurrent

Table 1. Epidemiology and characteristics of Sturge–Weber syndrome (SWS) and headache from the selected studies.

Reference	Country of study	Type of study	Population (adult, pediatric, both)	SWS type (I, II, III)	Age of headache onset	Headache features (migraine-like or tension-like, non-migraine non-tension-type)	Secondary causes of headache	Acute treatment of headache Drug (effectiveness)	Prophylactic treatment of headache Drug (effectiveness)	Hemiplegic migraine (Yes/No)
(8)	Italy	Case report	Pediatric	III	N/A	Migraine-like	Headache potentially linked to bilateral parieto-occipital calcifications	N/A	Valproate (+), Phenobarbital (+)	No
(9)	Romania	Case report	Adult	II	28 years	Migraine-like	Hemicrania and left hemiparesis developed 2 days after a caesarean section	N/A	N/A	Yes
(10)	UK	Case report	Pediatric	III	6 years	Migraine-like (migraine status)	–	N/A	N/A	No
(11)	USA	Case report	Adult	III	44 years	Non-migraine non-tension-type (orbital headache)	Headache as a stroke-like symptom	N/A	N/A	Yes
(12)	Iran	Case report	Adult	N/A	34 years	Migraine-like	Thunderclap headache accompanied by hemiparesis and hemianopia due to subarachnoid hemorrhage	N/A	N/A	Yes
(13)	N/A	Case report	Adult	I	46 years	Migraine-like (with aura)	Headache and photophobia before the onset of hemiplegic migraine in a pts with developmental venous anomaly	N/A	Topiramate (+)	Yes
(14)	UK	Case report	Adult	I	48 years	Migraine-like (with aura)	Headache as a stroke-like symptom occurred 2 days before the onset of seizures	N/A	N/A	Yes
(15)	Portugal	Case report	Adult	I	58 years	Migraine-like (with aura)	Ictal headache (as a symptom of an epileptic focal seizure)	N/A	N/A	No
(16)	South Korea	Case report	Pediatric	I	10 years	Non-migraine non-tension-type (occipital headache)	–	N/A	N/A	No
(17)	UK	Case report	Adult	I	30 years	Migraine-like	Headache and hemiplegic migraine related to a stroke-like episode	N/A	N/A	Yes

(continued)

Table 1. (continued)

Reference	Country of study	Type of study	Population (adult, pediatric, both)	SWS type (I, II, III)	Age of headache onset	Headache features (migraine-like or tension-like, non-migraine non-tension-type)	Secondary causes of headache	Acute treatment of headache Drug (effectiveness)	Prophylactic treatment of headache Drug (effectiveness)	Hemiplegic migraine (Yes/No)
(18)	USA	Case report	Pediatric	III	7 years	Migraine-like	–	N/A	N/A	Yes
(19)	USA	Case report	Adult	I	58 years	Migraine-like	Pre-seizures headache	N/A	N/A	Yes
(20)	Korea	Case report	Pediatric	I	9 years	Migraine-like	–	N/A	Amtripyline (+)	Yes
(21)	Netherlands	Case report	Adult	I	19 years	Migraine-like	“Vascular steal phenomenon” with relative decrease in brain perfusion by the shunt, due to the association between SWS and Moyamoya syndrome	Not specified analgesics (+)	N/A	No
(22)	France	Case report	Adult	I	24 years	Migraine-like	–	N/A	Lamotrigine (+)	Yes
(23)	China	Case report	Adult	I	46 years	Non-migraine non-tension-type	Headache due to left basal ganglia hemorrhage in a pt with SWS and Moyamoya syndrome	N/A	N/A	No
(24)	Japan	Case report	Pediatric	III	3 years	Migraine-like	–	Acetaminophen (–), Loxoprofen sodium hydrate (–), Naratriptan (+)	Lometizine hydrochloride (–), Propranolol (–), Valproate (–), Topiramate (–), Lamotrigine (+)	No
(25)	Turkey	Case report	Adult	I	19 years	Tension-like	–	N/A	N/A	No
(26)	Italy	Case report	Adult	I	39 years	Migraine-like (with prolonged aura)	Headache related to vascular malformation and associated structural lesions	Aspirin (–), Ibuprofen (–), Indomethacin (–)	N/A	No
(27)	Germany	Case report	Adult	I	14 years	Migraine-like	Headache associated with complex changes of both cerebral perfusion and glucose metabolism	Aspirin, Paracetamol, Metamizole, Piritramide (N/A effectiveness)	Valproate (–), Propofol (–), Topiramate (+)	Yes

(continued)

Table 1. (continued)

Reference	Country of study	Type of study	Population (adult, pediatric, both)	SWS type (I, II, III)	Age of headache onset	Headache features (migraine-like or tension-like, non-migraine non-tension-type)	Secondary causes of headache	Acute treatment of headache Drug (effectiveness)	Prophylactic treatment of headache Drug (effectiveness)	Hemiplegic migraine (Yes/No)
(28)	Taiwan	Case report	Adult	III	10 years	Migraine-like (with prolonged aura)	Headache and visual defect due to vasogenic leakage and hyperperfusion of the brain underlying the leptomeningeal angioma	Non-steroidal anti-inflammatory drugs (+), Dihydroergotamine (+)	Valproate (+), Flunarizine (+)	No
(29)	Turkey	Case report	Adult	I	12 years	Migraine-like	–	N/A	N/A	Yes
(30)	Italy	Case report	Pediatric	III	2 years	Migraine-like	Migraine-like headache resulting from vasomotor disturbances within and around the angioma	N/A	N/A	No
(31)	UK	Case report	Adult	III	75 years	Non-migraine	Post-ictal headache	N/A	Lamotrigine (+)	No
(32)	Japan	Case report	Pediatric	III	3 years	Migraine-like (with aura)	Migraine with aura and hemianopsia related to reduction in cerebral blood flow in the occipital region	Anti-inflammatory drugs (-), Ergotamine (-)	Valproate (-), Propranolol (-)	No
(33)	Japan	Case report	Adult	I	14 years	Migraine-like (with prolonged aura)	Headache related to vascular disorders (augmented gadolinium leakage from the occipital leptomeningeal angiomatosis during episode)	Analgesics (+)	N/A	No
(34)	China	Case report	Adult	I	2 years	Migraine-like	Headache triggered by a cold infection	N/A	N/A	Yes
(35)	Italy	Case report	Adult	I	Early infancy	Migraine-like (with aura)	Episodes of headache were spontaneous or triggered by seizures; cortical spreading depression triggers post-ictal headache	Non-steroidal anti-inflammatory drugs (-)	Propranolol (+)	No

(continued)

Table 1. (continued)

Reference	Country of study	Type of study	Population (adult, pediatric, both)	SWS type (I, II, III)	Age of headache onset	Headache features (migraine-like or tension-like, non-migraine non-tension-type)	Secondary causes of headache	Acute treatment of headache Drug (effectiveness)	Prophylactic treatment of headache Drug (effectiveness)	Hemiplegic migraine (Yes/No)
(36)	UK	Case report	Pediatric	III	6 years	Migraine-like (migraine status)	Pre-seizures headache	Paracetamol (-), Ibuprofen (-), Oramorph (-)	Flunarizine (+)	No
(37)	UK	Case report	Adult	I	24 years	Migraine-like	Throbbing headache due to chronic occlusion of the superior sagittal sinus, with extensive and tortuous collateral circulation	N/A	Valproate (+)	Yes
(38)	Canada	Case report	Adult	I	24 years	Migraine-like (with aura)	Ictal and post-ictal headaches	Acetaminophen (-)	Never received	Yes
(39)	Australia	Case report	Adult	III	18 years	Migraine-like	Ictal headache (episode of focal occipital status epilepticus)	Chlorpromazine (+)	N/A	No
(40)	Bangladesh	Case report	Adult	N/A	55 years	Migraine-like (with aura)	Ictal headache (symptomatic occipital epilepsy due to occipital calcifications)	N/A	N/A	No
(41)	Italy	Case report	Pediatric	I	17 m	Non-migraine non-tension-type	Episodes of hemiplegic migraine due to recurrent microthrombosis and microvascular stasis caused by angiomatosis	N/A	Flunarizine and aspirin (+)	Yes
(42)	UK	Case report	Adult	I	12 years	Not specified features	Left-sided weakness followed by left motor status epilepticus occurred after an head trauma	N/A	N/A	Yes
(43)	Italy	Case report	Adult	N/A	81 years	Migraine-like	Headache due to acute glaucoma attack	N/A	N/A	No
(44)	India	Case report	Pediatric	I	3 years	Migraine-like	Acute-onset headache after a mild head injury	No	Valproate (+)	Yes
(45)	USA	Retrospective observational study	Pediatric (136 pts)	N/A	79 to 155 m (mean 107 m)	7/136 (5%) pts with headache (not specified features)	Headache with neuroimaging showed sinusitis in 3/7 (43%) pts	N/A	N/A	No

(continued)

Table 1. (continued)

Reference study	Country of study	Type of study	Population (adult, pediatric, both)	SWS type (I, II, III)	Age of headache onset	Headache features (migraine-like or tension-like, non-migraine non-tension-type)	Secondary causes of headache	Acute treatment of headache Drug (effectiveness)	Prophylactic treatment of headache Drug (effectiveness)	Hemiplegic migraine (Yes/No)
(46)	UK	Retrospective observational study	Pediatric (84 pts)	N/A	5 m to 15 years (mean 7y)	31/84 (37%) pts with headache (not specified features)	Pre-seizure headaches (5 pts), post-ictal headaches (1 pt)	No	Flunarizine (3 pts) (+), Pizotifen (1 pt) (+), Valproate (1 pt) (+), Topiramate (1 pt) (+) N/A	Yes in 9/31 (29%) pts
(47)	Kosovo	Retrospective observational study	Pediatric (11 pts)	N/A	N/A	8/11 (73%) pts with headache (75% migraine-like and 25% tension-like)	-	N/A	N/A	Yes in 4/11 (36%) pts
(48)	UK	Retrospective observational study	Pediatric (20 pts)	15/20 (75%) pts type I, 5/20 (25%) pts type III	5 to 15 years (mean 7 years)	13/20 (65%) pts with "headache alone" (46% migraine-like), 7/20 (35%) pts with headache + transient hemiparetic episodes (29% migraine-like)	Headache after a minor head injury in 3/20 (15%) pts	N/A	Flunarizine (20/20 pts): decrease in headache frequency (15 pts); shorter headaches (14 pts); headaches were abolished (5pts). Topiramate (4 pts) (-)	Yes in 7/20 (35%) pts
(49)	UK	Retrospective observational study	Pediatric (140 pts)	120/140 (86%) pts type I or II, 20/140 (14%) pts type III	N/A	80/140 (57%) pts with headache (not specified features)	Stroke-like episodes in 56/140 (40%) pts: in 6/56 (11%) pts the antecedent was headache or vomiting	N/A	Topiramate (22 pts), Flunarizine (17 pts) (N/A effectiveness)	Yes in 81/140 (58%) pts
(50)	USA	Retrospective observational study	Both (36 pts)	N/A	N/A	Not specified features	Headache triggered by frequent illnesses or airway obstructions	N/A	N/A	No
(51)	USA	Retrospective observational study	Both (12 pts)	N/A	N/A	8/12 (67%) pts with headache (not specified features)	Headache occurred as a side effect of stimulant medications (methylphenidate/dextroamphetamine) in 3/12 (25%) pts	N/A	Valproate (3 pts), Topiramate (1 pt) (N/A effectiveness)	Yes in 8/12 (67%) pts

(continued)

Table 1. (continued)

Reference	Country of study	Type of study	Population (adult, pediatric, both)	SWS type (I, II, III)	Age of headache onset	Headache features (migraine-like or tension-like, non-migraine non-tension-type)	Secondary causes of headache	Acute treatment of headache Drug (effectiveness)	Prophylactic treatment of headache Drug (effectiveness)	Hemiplegic migraine (Yes/No)
(52)	USA	Observational study based on a questionnaire	Both (522 pts)	228 pts type I, 80 pts type II, 27 pts type III	N/A	131/522 (26%) pts with migraine-like	-	N/A	Valproate (7 pts), Topiramate (4 pts) (N/A effectiveness)	Yes in 123/522 (24%) pts
(53)	USA	Observational study based on a questionnaire	Both (71 pts)	N/A	85% pts had headache onset < 10 years	44% pts recurring headache, 28% pts migraine-like, 4% pts chronic tension, 1% pts with episodic tension	Post-ictal headache (41% pts), headache related to glaucoma (8% pts)	N/A	N/A	N/A
(54)	USA	Observational study based on a questionnaire	Both (68 pts)	N/A	0.5 to 45 years (mean 8 years)	52% pts with migraine-like	37/55 (67%) pts had precipitating triggers: sleep deprivation and fatigue (25), a change in routine (9), stress (7), minor head trauma (6), diet (6)	Acute medications in 54/55 (98%) pts. In 74% acute medications were helpful. Ibuprofene in 35/54 (65%) pts (efficacy in 19/35, 54%), Acetaminophen in 34/54 (63%) pts (efficacy in 8/34, 24%), Sumatriptan in 12/54 (22%) pts (efficacy in 7/12, 58%)	Prophylactic medication in 15/55 (27%) pts. In 12 (67%) pts prophylactic therapies were helpful, with no agent clearly superior: Gabapentin (3 pts), Valproate (3 pts), Amitriptyline (2 pts), diet (2 pts)	Yes in 41/55 (75%) pts
(55)	USA	Observational study based on a questionnaire	Both (104 pts)	N/A	N/A	74/104 (71%) pts with migraine-like	-	Triptans in 16/74 (22%) pts (efficacy in 71%)	Prophylactic medication in 26/74 (35%) pts (efficacy in 29%): Topiramate (9 pts), Valproate (9 pts), Propranolol (6 pts), Lamotrigine (4 pts), Gabapentin (4 pts), Amitriptyline (3 pts)	

The acute and prophylactic treatment columns indicate whether the drugs have provided a benefit (+) or have not provided a benefit (-) on the headache. Abbreviations: N/A = not available; pt = patient; pts = patients.

headaches are often not diagnosed with SWS until a more serious clinical event occurs, such as the onset of glaucoma, an episode of hemiplegic migraine or a seizure (9,18,52). Headaches significantly impact individuals with SWS (46,54). In total, 49% of individuals perceived their headaches as a more significant issue compared to 42% who deemed seizures more significant, even in instances of poorly controlled seizures. This trend persisted, with 50% of individuals reporting more severe headaches experiencing uncontrolled seizures (54).

Headache features

Headaches meeting the International Headache Society (IHS) criteria for migraine (unilateral pulsating pain, accompanied by nausea and/or vomiting, photophobia and phonophobia, aggravated by physical activity) were reported in 28% and 52% of individuals in two different questionnaire-based observational studies (53,54) and numerous case reports (8,14,19,23,24,38,47). The percentage of tension-type headache (TTH) reported was lower, at 4% in the chronic form and 1% in the episodic form (53). Consistent with these data, individual case reports with TTH are also scarce (25,47). From a retrospective study based on physician-recorded data on individuals with SWS, headaches had a mean age of onset at seven years (range 5 months to 15.5 years) (46) and eight years (range 0.5–45 years) (54). Precipitating triggers were identified in up to 67% of individuals and mostly included sleep deprivation and fatigue, followed by a change in routine, stress, minor head trauma and frequent illnesses or airway obstruction (42,44,45,48,54). The headache frequency varies from once or a few episodes per month to daily headaches (46,48,54). The median headache frequency was statistically significantly higher in subjects who reported stroke-like symptoms (54). The reported duration of headaches varied from 3–5 minutes to 8–10 days (46,48,54).

Individuals with SWS with a positive family history for headaches have an increased risk of experiencing headaches (56), and a positive family history of migraine was found in 25% (53) and 67% of probands (54). Furthermore, a family history of headaches was statistically significantly correlated with an earlier age at headache onset, at 7.5 versus 11 years (54). Comparing patients with and without PWS, no significant differences emerged in the occurrence of recurrent headaches and transient visual field deficits associated with headaches (49). No significant association was identified between headaches and a history of seizures, the administration of anti-epilepsy drugs, a history of transient hemiparesis, leptomeningeal angiomas lobar involvement, or whether the disease was unilateral or bilateral (46). No statistical correlation was found between headache characteristics (severity, frequency and duration) and radiological findings (number of lobes affected by pial angioma, bilateral involvement, presence of venous

anomalies, presence of calcification) (48). No evidence of associations between headache and glaucoma, unilateral versus bilateral brain involvement, birthmarks or age of seizure onset was identified (56). Another study indicated a link between headache and glaucoma in SWS patients (46), finding an 8% prevalence of glaucoma among those with headaches (53). Headaches were found to be associated with the administration of aspirin (ASA), whereas children with monoplegia and hemiplegia were less likely to experience headaches (46).

Acute and prophylactic treatment of headache

Based on numerous case reports, the common approaches in many countries involve improving sleep hygiene, hydration, ibuprofen, paracetamol and antiemetics (8–44). In a population surveyed with a standardized questionnaire, abortive medications were found to be helpful in 74% of cases. The most used medications included non-steroidal anti-inflammatory drugs, with ibuprofen and acetaminophen tried by 65% and 63% of patients, respectively. Sumatriptan was tried by 22% of cases, and ibuprofen showed statistically significant efficacy over acetaminophen. Notably, 54% of individuals found ibuprofen helpful compared to 24% for acetaminophen, with sumatriptan effective in 58% of users, reporting no adverse effects (54). In another study, triptans were used by 22% of individuals with migraines associated with SWS, with sumatriptan being the most frequently prescribed (55). Triptan users reported side effects such as nausea/vomiting, fatigue, worsening of headaches, pain or tightness, flushing and unusual sensations in a small number of cases, with two patients describing major side effects of worsening stroke-like events and weakness (55). Naratriptan improved acute headache control in an adult patient with SWS, reducing severity and duration when acetaminophen or loxoprofen sodium hydrate were ineffective (24). Prophylactic therapies such as gabapentin, sodium valproate and amitriptyline were utilized by 27% of individuals, according to a questionnaire study, with a reported benefit in 67% of cases. No single agent was identified as clearly superior (54). A subsequent study noted that 35% of patients diagnosed with both SWS and migraine reported the use of daily prophylactic medications, including topiramate, valproate, propranolol, lamotrigine, gabapentin and amitriptyline. Among these patients, 80% reported improved quality of life, with 29% considering the prophylactic drugs to be good or very good. In total, 63% of individuals using triptans had also used daily prophylaxis (55). The efficacy of flunarizine in a cohort of children with SWS showed a reduction in the severity, frequency and duration of headaches. However, treatment discontinuation occurred in two cases as a result of intolerable sedation and a non-anaphylactic allergic reaction. Reported side effects were sedation and weight gain, with no reports of behavioral or

extrapyramidal effects (48). Studies have indicated a potential association between topiramate use and an increased risk of glaucoma, which is prevalent among SWS patients. However, the mechanisms of glaucoma in SWS differ from those associated with topiramate use (57–59). A 2016 study examining glaucoma in SWS patients found that topiramate was effective and not associated with signs or symptoms concerning glaucoma (60).

Secondary causes of headache and neuroimaging in the emergency department

In a 34-year-old woman with no prior neurological complaints such as headaches or seizures, a thunderclap headache accompanied by right-sided hemiparesis and homonymous hemianopia was the presenting symptom of a subarachnoid hemorrhage (12). Another case involved an 81-year-old woman who suffered an acute loss of vision in her right eye, coupled with a right-sided headache, pain and nausea. These symptoms were associated with pupillary occlusion, leading to angle closure and acute glaucoma attack (43). A 29-year-old woman diagnosed with SWS and a history of episodic migraine headaches over the past five years was hospitalized as a result of a sudden onset of symptoms, including a throbbing headache accompanied by abrupt numbness, tingling, vomiting, photophobia and left-sided hemiparesis. Brain magnetic resonance imaging (MRI) revealed chronic occlusion of the superior sagittal sinus, with extensive and tortuous collateral circulation but no signs of recent thrombus formation or a vascular event (37). In one case, single-photon emission computed tomography (SPECT) imaging revealed a reduction in cerebral blood flow in the occipital region in a patient with persistent visual deficit (hemianopsia) during an episode of migraine with visual aura (32). Some studies have postulated that, in individuals with SWS, headaches can be triggered by frequent illnesses or airway obstructions (50), bilateral parieto-occipital calcifications (8) and stimulant medications (such as methylphenidate or dextroamphetamine) used in attention deficit hyperactivity disorder, although not contraindicating the use of such medications in this syndrome (51). In other conditions, headache itself can be a symptom of an epileptic crisis, especially when it involves paroxysmal and stereotyped episodes of colored lights with abstract shapes, motion and size variation, potentially delaying the diagnosis of focal epilepsy (15,39) or following an epileptic seizure (35). Postictal headaches occurred in 41% of seizures (53). In rare cases, it is reported that distinguishing between migraine and seizures can be difficult, especially when the symptoms manifest with atypical auras or symptoms that persist for several hours (38–40). This is exemplified by a case involving a 75-year-old woman who presented with a headache, along with postictal confusion, following a road traffic accident, likely occurring after her

first epileptic seizure. She had previously been in good health and was subsequently diagnosed with SWS type III (31). A retrospective study of patients with SWS presenting to the pediatric emergency department with acute neurological symptoms indicated that neuroimaging did not reveal acute hemorrhagic or ischemic strokes in these cases. The rate of neuroimaging was higher when children presented with headaches compared to those presenting with stroke-like episodes or seizures (100%, 89.7% and 34.4%, respectively) (45).

Hemiplegic migraine

Hemiplegic migraine is a recurring feature in SWS and is always accompanied by a headache. Hemiplegic migraine can be preceded by a headache with migraine-like characteristics (13) and may anticipate or trigger focal to bilateral tonic-clonic seizures (9) or a generalized tonic-clonic status epilepticus (17). Hemiplegic migraine can manifest in any type of SWS and be a presenting symptom in the form without leptomeningeal angioma, both in pediatric (18) and adult age (9). In SWS type III, it can be the initial manifestation of the syndrome, prompting brain MRI and subsequent diagnosis (11). However, an episode of hemiplegic migraine led to brain MRI and the diagnosis of SWS type I in a patient with facial PWS in a V1 distribution but without other manifest symptoms except for migraine with aura (14). In a 40-year-old woman who had been experiencing hemiplegic migraine episodes since the age of 24 years, with no history of seizures or mental retardation, initial investigations for mutations in the CACNA1A and ATP1A2 genes yielded normal results. The later-established diagnosis of SWS type I was confirmed through neuroimaging, revealing bilateral choroidal plexus calcifications, developmental venous anomaly with dilated transmedullary veins, left parieto-occipital leptomeningeal angioma and a bilateral port-wine stain extending from the forehead to the left chest and hand (22). Similar to headaches, hemiplegic migraine attacks can be triggered by factors such as head trauma (42,44). Many drugs have been used in the acute and prophylactic therapy of hemiplegic migraine, including antiepileptic drugs such as topiramate, valproate and lamotrigine, as well as flunarizine and ASA with variable efficacy (22,41). However, no studies have evaluated the retrospective or prospective observational response to such therapy in this condition. In some cases, hemiplegic migraine attacks associated with SWS can be severely drug-resistant, necessitating the transfer of the patient to the neurological intensive care unit (27).

Pathogenesis of headache

Studies on the pathophysiology of SWS have prominently highlighted the role of venous congestion, stasis, and

thrombosis in the progression of brain injury in this condition (5). The mechanism of migraine headache in SWS may be similar to that observed in epilepsy and vascular malformations. Leptomeningeal angiomatosis is characterized by abnormal pial vessels with increased permeability of the altered vessel walls (61). The heightened permeability of leptomeningeal angioma may predispose individuals to neuronal hyperexcitability, resulting in changes in cortical perfusion and oxygenation, aligning with theories on the pathophysiology of migraine (62). According to some studies, migraine-like symptoms may arise from vasomotor disturbances within and around the angioma (30). Although both epilepsy and migraine are more prevalent in SWS than in the general population, postictal headache has often been described as a feature of this syndrome (53). An individual with SWS may display not only a temporal relationship between seizures and headaches, but also continuity in the occurrence of the two phenomena (1). Therefore, it can be hypothesized that postictal headache in SWS may be triggered by epileptic hypersynchronization, facilitating the onset of cortical spreading depression (CSD) (35). CSD appears to be the pathogenetic link between migraine and epilepsy, potentially unlocking the understanding of the diverse spectrum of individuals with SWS. Furthermore, several studies indicate that contralateral cortices become highly hyperexcitable as a result of interhemispheric imbalance between excitatory and inhibitory circuits in the presence of diffuse cortical dysfunction (i.e. brain hypoxia) (63–65), which may underlie contralateral headache in the affected cerebral hemisphere of the syndrome. An alternative hypothesis proposed to explain migraine attacks with aura suggests that chronic focal oligemia and resulting tissue hypoxia might lead to severe and prolonged deficits without causing cerebral infarctions. It has been hypothesized in a 40-year-old woman with SWS that vasomotor disturbances within and around the angioma are responsible for oligemia, which could precipitate cortical spreading depression, leading to migraine with aura and hemiplegia (22). In this patient, CSD was indirectly demonstrated by slow waves on electroencephalogram, and oligemia by hypometabolism on [^{18}F]-fluorodeoxyglucose positron emission tomography/computed tomography. In individuals with migraine, cerebral blood flow, studies demonstrate a wave of oligemia that spreads forward from the occipital area; it precedes the aura and may persist into the headache phase (66). The rate of progression of this oligemia is comparable to the rate of CSD (67). Interictally, using perfusion-weighted imaging, cerebral blood flow (CBF), cerebral blood volume, and mean transit time were normal and symmetrical. Supporting this, during visual auras, CBF decreased by 15–53%, and cerebral blood volume decreased by 6–33% (68). Lastly, the activation of the trigeminovascular system is worth considering in detail because of the evident involvement of trigeminal nerves in this disease. The peripheral

trigeminovascular fibers induce migraine features and vasodilatation in the corresponding cortex. The mechanism of recurrent headaches with prolonged visual symptoms, often reported in individuals with SWS, remains speculative. Possible causes include recurrent small leaks from leptomeningeal angiomatosis, venous anomalies, occipital lobe seizure, reperfusion hyperemia and the activation of the trigeminovascular system. Various neurophysiologic studies have demonstrated that the visual cortex in patients with persistent visual aura maintains a steady state, and the threshold required for the onset of CSD is lower in epileptic syndromes, including SWS (69–71). Focal hyperemia associated with vasogenic leakage was observed in the brain region corresponding to the prolonged aura and possibly headache compared to asymptomatic periods (33). Enhanced MRI findings suggested the presence of augmented gadolinium leakage during the acute stage of symptoms from occipital leptomeningeal angiomatosis into the subarachnoid space. Therefore, it is likely that visual symptoms are attributed to neuronal dysfunction of the brain regions covered by occipital leptomeningeal angiomatosis (33). It is speculated that, once the trigeminovascular system is activated by an unknown trigger, as in migraine, an augmented reaction should develop, particularly around leptomeningeal angiomatosis, increasing vasogenic leakage of plasma and neuropeptides into the subarachnoid space (33). In an individual with a persistent aura associated with a migraine attack resulting in a permanent visual field defect at an 18-month follow-up without cerebral infarction, by adopting a multimodality imaging study (diffuse tensor imaging (DTI) color maps), it was suggested that the prolonged visual field defect was a result of blood flow disturbance and vasogenic leakage under the leptomeningeal angioma, combined with atrophy and damaged integrity of white matter in the right occipital lobe. In particular, the DTI disclosed severe loss and disorganization of the right inferior longitudinal fasciculus and optic radiation, which are important tracts of the visual pathway. As reported, the damaged subcortical white matter integrity might increase the susceptibility to prolonged visual defects in this case when concurring with blood flow disturbance and vasogenic leakage (28). In some cases, vascular alterations can cause permanent damage, as seen in another individual with SWS type III with a history of migraine-like headaches with visual aura, who, at the age of 14 years, experienced an episode with homonymous hemianopsia that did not resolve after the cessation of the headaches as in previous episodes. In this individual, reduced cerebral blood flow was subsequently observed in the right occipital area on SPECT imaging (32). However, the pathophysiological mechanism of prolonged aura remains to be elucidated, and associated cerebral blood flow changes should be further investigated.

Discussion

Headaches are more frequent and severe in patients with SWS compared to the general population, often significantly impacting their quality of life (46,54,55). Additionally, headache may serve as the initial symptom prompting investigations in an individual with an unexplored PWS (21), and it could also be the sole symptom leading to a diagnosis in an individual without other evident clinical signs and symptoms, as observed in SWS type III (10,11,36). The characteristics linked to these headaches are primarily derived from case reports and case series (8–44), with a paucity of observational studies (45–55), just as there are few prospective studies aimed at identifying characteristics and effectiveness of prophylactic therapies in headache in individuals not affected by syndromes (72). Nevertheless, literature suggests that headaches associated with SWS frequently meet the criteria for migraines (54), as well as for headache in other pathologies with cerebrovascular involvement such as Moyamoya disease (73,74). Headaches, mostly affecting older children and adults (46,49,53,55,56), often begin in childhood with episodes that range in frequency and severity from mild to debilitating. No significant association was identified between headaches/headache characteristics and history of seizures, the use of anti-epilepsy medications, a history of transient hemiparesis or radiological findings (46,48,49). Headaches were found to be associated with glaucoma and the use of ASA, although the same study hypothesized that the link between headaches and ASA use did not appear causative but was rather related to a more severe phenotypic presentation, leading to ASA administration (46). There are very few reports of headaches secondary to life-threatening causes in SWS. Moreover, none of the secondary headaches as a result of life-threatening causes presented as the exclusive symptom, always being accompanied by other neurological signs such as persistent visual disturbances, hemiparesis, or seizures (8,12,15,31,32,35,38–40,43,51,53), consistent with that already reported in the literature for other secondary causes of headache, such as cerebrovascular diseases and brain tumors (75,76). Despite this, emergency department visits for headaches have a higher rate of neuroimaging execution compared to visits for stroke-like episodes and seizures (45), serving as evidence of how headaches in SWS are consistently considered a warning sign for potentially life-threatening secondary causes. Regarding pathogenesis, the leptomeningeal angioma may predispose individuals to neuronal hyperexcitability, potentially accounting for the headache, migraine-like headaches, as well as a temporal relationship between headaches and seizure activity. Visual symptoms in SWS could be attributed to neuronal dysfunction in brain regions covered by occipital leptomeningeal angiomas (54). Given the increased prevalence of headaches and migraine-like headaches in individuals with

SWS, we consider that, although the clinical features fulfill the IHS criteria for the symptomatology of migraine, it would be appropriate to classify these headaches as secondary headaches associated with vascular disorders until the pathophysiological mechanism of headache and migraine, without or with aura, in SWS is elucidated. However, it is important to note that the high percentage of subjects with a family history of headaches suggests that genetic propensity may play a role in the symptoms of these patients (54). Additionally, the five-fold increase in headache frequency in patients with stroke-like episodes suggests that progression of central nervous system morbidity associated with SWS might lead to headache disability (54). Alternatively, frequent headaches could increase the risk of stroke-like episodes, suggesting that prophylactic headache therapy should be considered earlier for this group of patients. Children with SWS often resort to acute therapy rather than preventative therapy for headaches (54). Although there are no guidelines for acute or preventative management, improving sleep, hydration, and the use of ibuprofen, paracetamol and antiemetics are commonly reported in most cases (77), as in headaches in individuals not affected by syndromes (78). Indeed, individuals with SWS are at increased risk of stroke because of pre-existing perfusion and metabolic defects that subject them to prolonged phases of oligemia, a characteristic of migraine-induced stroke (79,80). Vomiting, fever and dehydration can create a hyperviscous state, increasing the risk of headache and thrombosis. As for acute therapy, triptans are safe and often effective in SWS (55). Although no issues with triptans were reported in this survey, theoretical concerns about using a vasoconstrictive agent (which may unlikely affect the leptomeningeal blood vessels of SWS) exist. In SWS, therapeutic treatment often focuses on preventing epileptic seizures, and it has been reported that this has a positive impact on headaches (8). Nonetheless, antiepileptic drugs such as valproate, lamotrigine, topiramate or gabapentin, along with flunarizine and amitriptyline, are frequently used for headache prophylaxis even in the absence of epilepsy (20,24,54,55). Daily preventative medications were also efficacious in reducing the impact of the headache on quality of life (55). ASA has been shown to be useful in preventing headaches in sporadic cases (54), but a controlled study of ASA for the prevention of stroke-like events, and possibly headaches and seizures, is needed to assess its safety, indications and efficacy. One of the hallmarks of SWS in the central nervous system is abnormalities in the medullary and subependymal veins, as well as deep venous structures associated with impaired venous outflow (5). Venous congestion, stasis and thrombosis predispose SWS patients to ischemia-related progressive brain injury. Thus, low-dose ASA (3–5 mg/kg/day) has been considered for managing seizures and stroke-like episodes (81,82). At present, there are no placebo-controlled randomized trials

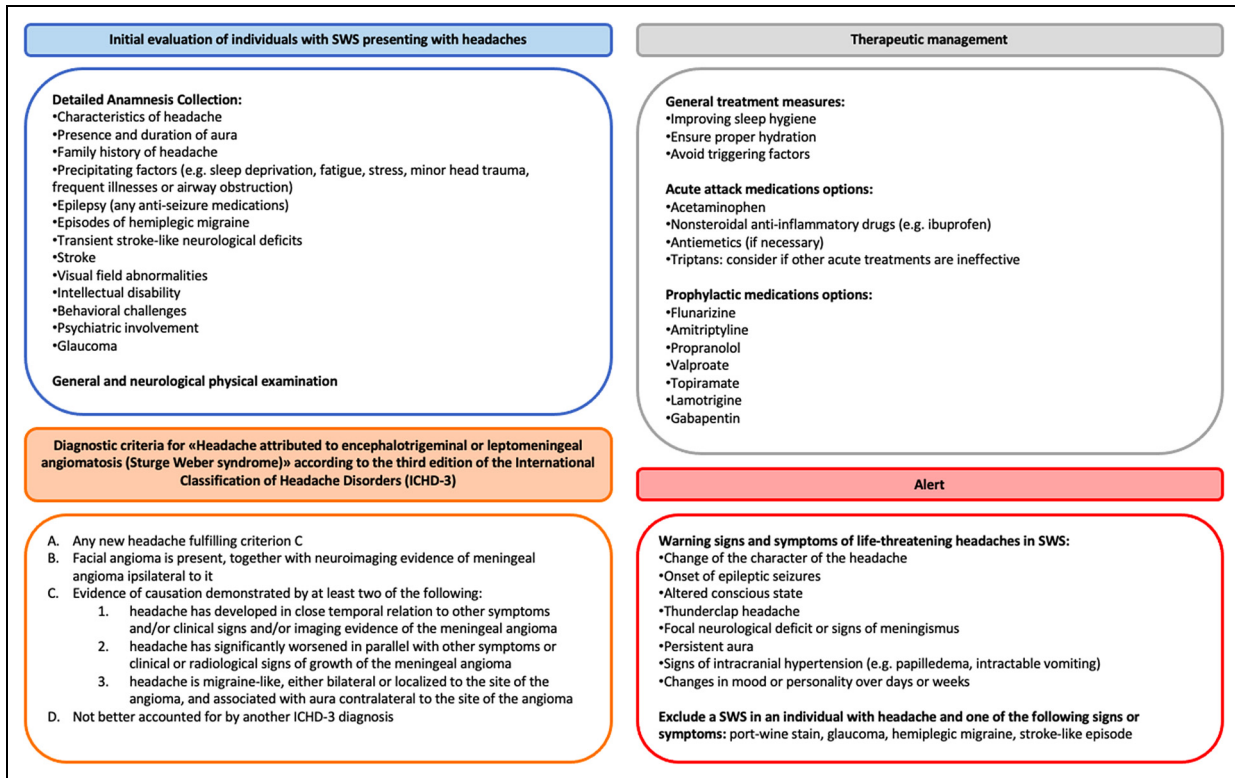


Figure 2. Recommendations for the comprehensive evaluation and management of headaches in individuals with Sturge–Weber syndrome.

to determine the real efficacy of ASA as prophylactic treatment in seizures, strokes or headaches, although retrospective studies and reports of small series show a reduced incidence of stroke-like episodes and seizures in patients treated with ASA (82).

To enhance the comprehensiveness and clinical applicability of this systematic review, we have shared recommendations for the comprehensive evaluation and management of headaches in SWS in Figure 2. This includes evidence-based practical guidelines for the initial evaluation of individuals with SWS presenting with headaches, diagnostic criteria for “Headache attributed to encephalotrigeminal or leptomeningeal angiomatosis (Sturge–Weber syndrome)” according to ICHD-3, acute and prophylactic management strategies, and an alert on the signs and symptoms of life-threatening headaches in SWS. Specific conditions to reduce the diagnostic delay of SWS in individuals with headaches are also highlighted.

The systematic review presents several limitations. The study designs selected showed substantial heterogeneity, which may impact the consistency of findings; the diagnostic criteria for headache varied considerably across the studies, leading to potential inconsistencies in patient classification and outcomes; the diagnostic and therapeutic management approaches also differed widely, reflecting diverse clinical practices and potentially influencing the

results; and many of the larger studies included were retrospective in nature, introducing potential biases related to data collection and patient recall. These limitations underscore the need for standardized methodologies and criteria in future research to improve the reliability and comparability of findings, particularly in exploring the pathophysiology and therapeutic implications of headache in SWS. To this end, it would be necessary to conduct observational and prospective studies to define the salient characteristics of headache in SWS, assess the pathophysiology in large case series, and compare acute and prophylactic treatments against placebo in specifically designed clinical trials.

Conclusions

Headaches are more frequent in individuals with SWS compared to the general population and often represent the investigated symptom that leads to diagnosis. Based on these findings, we recommend that patients with a PWS on the face should undergo further investigation to exclude intracranial vascular malformations, especially if headaches and migraine-like headaches are present. Although the clinical signs align with the IHS criteria for migraine presentations, it is advisable to classify these headaches as secondary, originating from vascular issues, until their underlying mechanisms are fully understood. This recommendation is in line

with the classification of secondary headache “Headache attributed to encephalotrigeminal or leptomeningeal angiomatosis (Sturge–Weber syndrome)” as outlined by the ICHD-3 (6). Headaches secondary to life-threatening causes in SWS are very rare and especially not reported

unless associated with other neurological signs and symptoms. In addition to improving sleep hygiene, hydration, and using ibuprofen, paracetamol and antiemetics for acute attacks, access to prophylactic therapies should be expanded to reduce the impact of headache on quality of life.

Key Findings

- Up to 71% of people with SWS experience headaches that significantly affect daily life.
- Over 50% of headaches exhibit migraine features, starting in childhood; no significant links to seizures, radiological findings or glaucoma were found.
- No established guidelines for managing headaches exist; common treatments include sleep improvement, hydration and acute treatments; prophylactic therapies are used, showing varied efficacy.

Data availability statement

All data generated or analyzed during this study are available from the corresponding author upon reasonable request.




Declaration of conflicting interests

The authors declared no potential conflicts of interest with respect to the research, authorship and/or publication of this article.

Funding

The authors received no financial support for the research, authorship and/or publication of this article.

ORCID iDs

Alessandro Ferretti  <https://orcid.org/0000-0002-3854-9299>
 Massimiliano Valeriani  <https://orcid.org/0000-0001-6602-103X>
 Pasquale Parisi  <https://orcid.org/0000-0001-9042-8120>

References

1. Comi AM. Presentation, diagnosis, pathophysiology, and treatment of the neurological features of Sturge-Weber syndrome. *Neurologist* 2011; 17: 179–184.
2. Comi AM. Update on Sturge-Weber syndrome: diagnosis, treatment, quantitative measures, and controversies. *Lymphat Res Biol* 2007; 5: 257–564.
3. Thomas-Sohl KA, Vaslow DF and Maria BL. Sturge-Weber syndrome: a review. *Pediatr Neurol* 2004; 30: 303–310.
4. Shirley MD, Tang H, Gallione CJ, et al. Sturge-Weber syndrome and port-wine stains caused by somatic mutation in GNAQ. *N Engl J Med* 2013; 368: 1971–1979.
5. Sudarsanam A and Ardern-Holmes SL. Sturge-Weber syndrome: from the past to the present. *Eur J Paediatr Neurol* 2014; 18: 257–266.
6. Headache Classification Committee of the International Headache Society (IHS). The International Classification of Headache Disorders, 3rd edition. *Cephalalgia* 2018; 38: 1–211.
7. Panic N, Leoncini E, de Belvis G, et al. Evaluation of the endorsement of the preferred reporting items for systematic reviews and meta-analysis (PRISMA) statement on the quality of published systematic review and meta-analyses. *PLoS One* 2013; 8: e83138.
8. Battistella PA, Mattesi P, Casara GL, et al. Bilateral cerebral occipital calcifications and migraine-like headache. *Cephalalgia* 1987; 7: 125–129.
9. Purcaru L, Tudor I, Terecoasa E, et al. Sturge-Weber syndrome and hemiplegic migraine-case report. *Romanian J Neurol* 2020; 19: S57.
10. Ahmed MI, Jordan P, Arora M, et al. Sturge weber syndrome type 3 masquerading as ‘migraine status’ at presentation. *Arch Dis Childhood* 2017; 102: A157.
11. Lowe J, Bhan C and Rai V. Sturge-weber syndrome type 3 in a 44 year old woman: a case report & review of literature. *Neurology* 2017; 88: 1.
12. Habibi A, Sarraf P, Tafakhori A, et al. Subarachnoid hemorrhage and cerebralvenous sinus thrombosis in Sturge Weber patient. *Internat J Stroke* 2016; 11: 193.
13. Bughio S and Lvovsky D. Prolonged hemiplegic migraine associated with Sturge-Weber syndrome. *Am J Res Critical Care Med* 2015; 191 A4643.
14. Cosgrove J and Hassan A. Staring you in the face! Sturge-Weber syndrome is a spectrum disorder and late presentation is possible. *J Neurol Neurosurg Psych* 2013; 84: e2.18–e2.e2.
15. Salgado P, Cardoso M, Pedro Pereira J, et al. Late-onset and easy to treat epilepsy with leptomeningeal angiomatosis – where the disease spectrum ends? *J Clinical Neurosci* 2019; 61: 247–248.
16. In-Seok B, Hyeong-Joong Y and Young JL. Multifocal arteriovenous malformations and facial nevus without leptomeningeal angioma: a variant form of Sturge–Weber syndrome? A case report and review of the literatures. *Childs Nerv Syst* 2013; 29: 311–315.
17. Kobylecki C, Jones M, Williams T, et al. Reversible increases in cortical diffusion-weighted MR signal in a patient with Sturge-Weber syndrome and subacute hemiplegia. *J Neurol* 2011; 258: 2095–2096.
18. Martin TC, Harle H, Dawson R, et al. Index of suspicion: case 2: vomiting, headache, and seizures in a 7-year-old boy. Presentation and discussion. *Pediatrics in Review* 2011; 32: 209–214.
19. Traub R, Riley C and Horvath S. Teaching NeuroImages: Sturge-weber syndrome presenting in a 58-year-old woman with seizures. *Neurology* 2010; 75: e52.

20. Rho YI. Recurrent migraine and transient stroke-like episode in child with Sturge-Weber syndrome: a case report. *J Headache Pain* 2010; 11: S20.
21. Mozumder AS, Gaub MB, Simon RC, et al. Moyamoya syndrome in the setting of Sturge Weber: a case report. *Neurology* 2022; 98: 18.
22. Planche V, Chassin O, Leduc L, et al. Sturge-Weber syndrome with late onset hemiplegic migraine-like attacks and progressive unilateral cerebral atrophy. *Cephalalgia* 2014; 34: 73–77.
23. Hao Z and Lai X. Sturge-Weber syndrome coexisting with moyamoya disease in the fifth decade: a case report and literature review. *Neurologist* 2019; 24: 13–16.
24. Nomura S, Shimakawa S, Fukui M, et al. Lamotrigine for intractable migraine-like headaches in Sturge-Weber syndrome. *Brain Dev* 2014; 36: 399–401.
25. Balkuv E, Isik N, Canturk IA, et al. Sturge-weber syndrome: a case report with persistent headache. *Pan Afr Med J* 2014; 26: 87.
26. Lisotto C, Mainardi F, Maggioni F, et al. Headache in Sturge-Weber syndrome: a case report and review of the literature. *Cephalalgia* 2004; 24: 1001–1004.
27. Freilinger T, Peters N, Rémi J, et al. A case of Sturge-Weber syndrome with symptomatic hemiplegic migraine: clinical and multimodality imaging data during a prolonged attack. *J Neurol Sci* 2009; 287: 271–274.
28. Huang HY, Lin KH, Chen JC, et al. Type III Sturge-Weber syndrome with migraine-like attacks associated with prolonged visual aura. *Headache* 2013; 53: 845–849.
29. Dora B and Balkan S. Sporadic hemiplegic migraine and Sturge-Weber syndrome. *Headache* 2001; 41: 209–210.
30. Taddeucci G, Bonuccelli A and Polacco P. Migraine-like attacks in child with Sturge-Weber syndrome without facial nevus. *Pediatr Neurol* 2005; 32: 131–133.
31. Gough J, Downes S and Hughes T. Sturge-Weber syndrome presenting in late adulthood. *BMJ Case Rep* 2021; 14: e239179.
32. Shimakawa S, Miyamoto R, Tanabe T, et al. Prolonged left homonymous hemianopsia associated with migraine-like attacks in a child with Sturge-Weber syndrome. *Brain Dev* 2010; 32: 681–684.
33. Iizuka T, Sakai F, Yamakawa K, et al. Vasogenic leakage and the mechanism of migraine with prolonged aura in Sturge-Weber syndrome. *Cephalalgia* 2004; 24: 767–770.
34. Luo Y, Yang Y and Chen X. A case report of a pregnant woman with Sturge-Weber syndrome. *J Int Med Res* 2020; 48: 300060520913708.
35. Giannantoni NM, Della Marca G and Vollono C. An apparently classical case report of Sturge-Weber syndrome. *Clin EEG Neurosci* 2015; 46: 353–356.
36. Jordan PR, Iqbal M and Prasad M. Sturge-Weber syndrome type 3 manifesting as ‘Status migrainosus’. *BMJ Case Rep* 2016; 2016: bcr2016216842.
37. Jung A, Raman A and Rowland Hill C. Acute hemiparesis in Sturge-Weber syndrome. *Pract Neurol* 2009; 9: 169–171.
38. Jacobs J, Levan P, Olivier A, et al. Late-onset epilepsy in a surgically-treated Sturge-Weber patient. *Epileptic Disord* 2008; 10: 312–318.
39. Sethi M, Kowalczyk MA, Dalic LJ, et al. Abnormal neurovascular coupling during status epilepticus migrainosus in Sturge-Weber syndrome. *Neurology* 2017; 88: 209–211.
40. Mahmud R, Presentation SH and Etiology O. And differentiation of visual semiology of adult occipital epilepsy from visual aura of migraine headache: a prospective study in a tertiary care center in Bangladesh. *Cureus* 2022; 14: e24186.
41. D’Arrigo S, Tessarollo V, Maselli E, et al. Flunarizine and aspirin for transient hemiparesis in sturge-weber syndrome. *Neuropediatrics* 2019; 50: 406–407.
42. Zolkipli Z, Aylett S, Rankin PM, et al. Transient exacerbation of hemiplegia following minor head trauma in sturge-weber syndrome. *Dev Med Child Neurol* 2007; 49: 697–699.
43. Lambiase A, Mantelli F, Mannino G, et al. An unusual case of acute glaucoma in Sturge-Weber syndrome. *Eur J Ophthalmol* 2015; 25: e103–e105.
44. Ahmed S and Paul SP. Hemiplegia following mild head injury in a child with Sturge-Weber syndrome - A diagnostic dilemma. *J Coll Physicians Surg Pak* 2016; 26: 704–706.
45. Jülich K, Neuberger I, Sahin M, et al. Yield of emergent neuroimaging in patients with Sturge-Weber syndrome presenting with acute neurologic symptoms. *J Child Neurol* 2019; 34: 17–21.
46. Arkush L, Prabhakar P, Scott RC, et al. Headache in children with Sturge-Weber syndrome - prevalence, associations and impact. *Eur J Paediatr Neurol* 2020; 27: 43–48.
47. Zeka N, Zeka B, Gerguri A, et al. Sturge-Weber syndrome and variability of clinical presentation. *Med J Malaysia* 2023; 78: 145–148.
48. Gallop F, Fosi T, Prabhakar P, et al. Flunarizine for headache prophylaxis in children with Sturge-Weber syndrome. *Pediatr Neurol* 2019; 93: 27–33.
49. Powell S, Fosi T, Sloneem J, et al. Neurological presentations and cognitive outcome in Sturge-Weber syndrome. *Eur J Paediatr Neurol* 2021; 34: 21–32.
50. Irving ND, Lim JH, Cohen B, et al. Sturge-Weber syndrome: ear, nose, and throat issues and neurologic status. *Pediatr Neurol* 2010; 43: 241–244.
51. Lance EI, Lanier KE, Zabel TA, et al. Stimulant use in patients with Sturge-Weber syndrome: safety and efficacy. *Pediatr Neurol* 2014; 51: 675–680.
52. Cho S, Maharathi B, Ball KL, et al. Sturge-Weber syndrome patient registry: delayed diagnosis and poor seizure control. *J Pediatr* 2019; 215: 158–163. e6.
53. Klapper J. Headache in Sturge-Weber syndrome. *Headache* 1994; 34: 521–522.
54. Kossoff EH, Hatfield LA, Ball KL, et al. Comorbidity of epilepsy and headache in patients with Sturge-Weber syndrome. *J Child Neurol* 2005; 20: 678–682.
55. Kossoff EH, Balasta M, Hatfield LM, et al. Self-reported treatment patterns in patients with Sturge-Weber syndrome and migraines. *J Child Neurol* 2007; 22: 720–726.
56. Day AM, McCulloch CE, Hammill AM, et al. Physical and family history variables associated with neurological and cognitive development in sturge-weber syndrome. *Pediatr Neurol* 2019; 96: 30–36.
57. Awad AH, Mullaney PB, Al-Mesfer S, et al. Glaucoma in Sturge-Weber syndrome. *J AAPOS* 1999; 3: 40–45.
58. Etminan M, Maberley D and Mikelberg FS. Use of topiramate and risk of glaucoma: a case-control study. *Am J Ophthalmol* 2012; 153: 827–830.
59. Symes RJ, Etminan M and Mikelberg FS. Risk of angle-closure glaucoma with bupropion and topiramate. *JAMA Ophthalmol* 2015; 133: 1187–1189.

60. Kaplan EH, Kossoff EH, Bachur CD, et al. Anticonvulsant efficacy in sturge-weber syndrome. *Pediatr Neurol* 2016; 58: 31–36.
61. Guseo A. Ultrastructure of calcification in Sturge-Weber disease. *Virchows Arch A Pathol Anat Histol* 1975; 366: 353–356.
62. Lauritzen M. Pathophysiology of the migraine aura. The spreading depression theory. *Brain* 1994; 117: 199–210.
63. Suh JG, An SJ, Park JB, et al. Transcortical alterations in Na(+)-K+ ATPase and microtubule-associated proteins immunoreactivity in the rat cortical atrophy model induced by hypoxic ischemia. *Neural Plast* 2002; 9: 135–146.
64. Paul JS, Fwu-Shan S and Luft AR. Early adaptations in somatosensory cortex after focal ischemic injury to motor cortex. *Exp Brain Res* 2006; 168: 178–185.
65. Innocenti GM. Dynamic interactions between the cerebral hemispheres. *Exp Brain Res* 2009; 192: 417–423.
66. Olesen J, Larsen B and Lauritzen M. Focal hyperemia followed by spreading oligemia and impaired activation of rCBF in classic migraine. *Ann Neurol* 1981; 9: 344–352.
67. Simkins RT, Tepley N, Barkley GL, et al. Spontaneous neuromagnetic fields in migraine: possible link to spreading cortical depression. *Neurology* 1989; 39: 325.
68. Cutrer FM and O'Donnell A. Recent advances in functional neuroimaging. *Curr Opin Neurol* 1999; 12: 255–259.
69. Belcastro V, Striano P, Kasteleijn-Nolst Trenité DG, et al. Migralepsy, hemicrania epileptica, post-ictal headache and "ictal epileptic headache": a proposal for terminology and classification revision. *J Headache Pain* 2011; 12: 289–294.
70. Brigo F, Storti M, Tezzon F, et al. Primary visual cortex excitability in migraine: a systematic review with meta-analysis. *Neurol Sci* 2013; 34: 819–830.
71. Chen WT, Lin YY and Wang SJ. Headache frontiers: using magnetoencephalography to investigate pathophysiology of chronic migraine. *Curr Pain Headache Rep* 2013; 17: 309.
72. Papetti L, Spalice A, Nicita F, et al. Migraine treatment in developmental age: guidelines update. *J Headache Pain* 2010; 11: 267–276.
73. Chiang CC, Shahid AH, Harriott AM, et al. Evaluation and treatment of headache associated with moyamoya disease - a narrative review. *Cephalalgia* 2022; 42: 542–552.
74. Kraemer M, Lee SI, Ayzenberg I, et al. Headache in Caucasian patients with Moyamoya angiopathy - a systematic cohort study. *Cephalalgia* 2017; 37: 496–500.
75. Rothrock JF and Diener HC. Headache secondary to cerebrovascular disease. *Cephalalgia* 2021; 41: 479–492.
76. Palmieri A, Valentinis L and Zanchin G. Update on headache and brain tumors. *Cephalalgia* 2021; 41: 431–437.
77. Comi AM. Sturge-Weber syndrome and epilepsy: an argument for aggressive seizure management in these patients. *Expert Rev Neurother* 2007; 7: 951–956.
78. Raucci U, Boni A, Evangelisti M, et al. Lifestyle modifications to help prevent headache at a developmental age. *Front Neurol* 2021; 11: doi.org/10.3389/fneur.2020.618375.
79. Welch KM. Relationship of stroke and migraine. *Neurology* 1994; 44: S33–S36.
80. Hamberger A and van Gelder NM. Metabolic manipulation of neural tissue to counter the hypersynchronous excitation of migraine and epilepsy. *Neurochem Res* 1993; 18: 503–509.
81. Lance EI, Sreenivasan AK, Zabel TA, et al. Aspirin use in Sturge-Weber syndrome: side effects and clinical outcomes. *J Child Neurol* 2013; 28: 213–218.
82. Triana Junco PE, Sánchez-Carpintero I and López-Gutiérrez JC. Preventive treatment with oral sirolimus and aspirin in a newborn with severe Sturge-Weber syndrome. *Pediatr Dermatol* 2019; 36: 524–527.