




Familial adenomatosis polyposis-related desmoid tumours treated with low-dose chemotherapy: results from an international, multi-institutional, retrospective analysis

Andrea Napolitano ¹, Salvatore Provenzano,² Chiara Colombo,³ Marco Vitellaro,³ Antonella Brunello,⁴ Giuseppe Badalamenti,⁵ Margherita Nannini,⁶ Toni Ibrahim,⁷ Peter Hohenberger,⁸ Silvia Gasperoni,⁹ Spyridon Gennatas,¹⁰ Robin L Jones,¹⁰ Nadia Hindi,¹¹ Javier Martin-Broto,¹¹ Mariella Spalato Ceruso,¹ Marianna Silletta,¹ Angelo Paolo Dei Tos,¹² Alessandro Gronchi,³ Silvia Stacchiotti,² Daniele Santini,¹ Giuseppe Tonini,¹ Elena Palassini,² Bruno Vincenzi¹

To cite: Napolitano A, Provenzano S, Colombo C, *et al.* Familial adenomatosis polyposis-related desmoid tumours treated with low-dose chemotherapy: results from an international, multi-institutional, retrospective analysis. *ESMO Open* 2020;5:e000604. doi:10.1136/esmooopen-2019-000604

EP and BV contributed equally.

Received 2 October 2019
Revised 5 November 2019
Accepted 6 November 2019

© Author (s) (or their employer(s)) 2020. Re-use permitted under CC BY-NC. No commercial re-use. Published by BMJ on behalf of the European Society for Medical Oncology.

For numbered affiliations see end of article.

Correspondence to
Professor Bruno Vincenzi;
b.vincenzi@unicampus.it

ABSTRACT

Introduction Desmoid tumour (DT) is a locally aggressive fibroblastic proliferative disease representing the most common extraintestinal manifestation of familial adenomatosis polyposis (FAP). As data on the activity of chemotherapy in these patients are limited, we examined the outcomes of patients treated with low-dose methotrexate (MTX)+vinca alkaloids (vinorelbine or vinblastine).

Patients and methods We retrospectively reviewed clinical and outcome data from all patients with confirmed FAP-associated DTs treated with weekly MTX+vinca alkaloids in seven European sarcoma reference centres between January 2000 and December 2018. Radiological responses were assessed using RECIST V.1.0 and V.1.1. The Kaplan-Meier method associated to the log-rank test was used to estimate and compare survival curves.

Results We identified 37 patients (median age 29 years, range 7–44). According to RECIST, 20/37 (54.1%) patients achieved partial response (PR), 15/37 (40.5%) patients had stable disease and 2/37 (5.4%) had progressive disease as best response. Overall, the median progression-free survival (PFS) was 6.5 years (range, 0.3–12.1 years). In the subset of patients achieving PR as best response, the median PFS was not reached. In a subset of 11 patients with progressive disease offered MTX+vinca alkaloids rechallenge (after chemotherapy withdrawal following prolonged disease control), the disease control rate was 100%, resulting in a median PFS after rechallenge of 5.8 years.

Conclusions This is the largest series on the activity of low-dose chemotherapy in patients with FAP-related DT. In this population, MTX+vinca alkaloids is an active combination, as already reported in patients with sporadic DT.

INTRODUCTION

Desmoid tumour (DT), also known as desmoid-type fibromatosis, is a monoclonal, non-metastasising, locally aggressive, sometimes multifocal, fibroblastic proliferative

Key questions

What is already known about this subject?

▶ Desmoid tumors associated to the hereditary cancer predisposition syndrome familial adenomatosis polyposis (FAP)-related represents 10%–15% of all cases. Low-dose chemotherapy with methotrexate and vinca alkaloids is an effective and safe regimen in sporadic desmoid tumors, but no data specifically collected on FAP-associated desmoid tumors are currently available.

What does this study add?

▶ We retrospectively reviewed clinical and outcome data from patients with confirmed FAP-associated desmoid tumors treated with methotrexate and vinca alkaloids, showing for the first time that this regimen is active also in this rare population.

How might this impact on clinical practice?

▶ Our study supports the use of medical therapy with methotrexate and vinca alkaloids in FAP-associated desmoid tumor patients. This is particularly relevant, as in these patients surgery might be more challenging, and medical therapy therefore more relevant.

disease arising from connective tissues.¹ The incidence of DT is low, in the range of 2–4 new cases per million per year.² About 85%–90% of the DT cases are sporadic and harbour mutations in the gene *CTNGB1* encoding β-catenin; the remaining 10%–15% of the DT cases are associated with familial adenomatous polyposis (FAP) and harbour germline *APC* mutations. Patients with FAP have a lifelong risk of 10%–15% to develop DT, the so-called Gardner syndrome. Depending on their *APC* gene mutation, the risk is 800-fold



Table 1 Patient characteristics	
Age (median, range)	29 (7–44) years
Gender (female)	22/37 (59.5%)
Primary tumour site	
Intra-abdominal only	25/37 (67.6%)
Intra-abdominal+trunk/abdominal wall	7/37 (18.9%)
Trunk/abdominal wall only	3/37 (8.1%)
Other	2/37 (5.4%)
Extremity	1/37 (2.7%)
Intrathoracic	1/37 (2.7%)
Multifocal disease	32/37 (86.5%)
Previous surgery	23/37 (62.2%)
Prior medical therapy	
Only hormonal therapy	7/37 (18.9%)
Only NSAIDs	10/37 (18.9%)
Both hormonal therapy and NSAIDs	3/37 (8.1%)
Reasons for treatment initiation	
Progressive disease	18/37 (48.6%)
Symptomatic disease	10/37 (27.0%)
Disease in a critical site	9/37 (24.3%)
Reasons for treatment discontinuation	
Treatment completion	25/37 (67.6%)
One year of treatment	7/37 (18.9%)
Progressive disease	2/37 (5.4%)
Prolonged G2 neurotoxicity	1/37 (2.7%)
Patient's choice	1/37 (2.7%)
Unknown	1/37 (2.7%)
Chemotherapy regimen subtype	
MTX+vinorelbine	32/37 (86.5%)
MTX+vinblastine	5/37 (13.5%)

MTX, methotrexate; NSAID, non-steroidal anti-inflammatory drug.

to 1000-fold higher than in the general population.^{3–5} Data from a recent meta-analysis of European FAP families suggested that a positive family history for DT, prior abdominal surgery and specific *APC* mutation site are significant risk factors for development of DT.⁶ Interestingly, FAP-associated DTs appear to be more often diagnosed years after an open rather than laparoscopic surgery.⁷ Sporadic DTs can arise in any body district and they are commonly found in the abdominal wall, limbs and girdles; FAP-associated DTs are on the contrary significantly more often intra-abdominal in location.^{6,8} Importantly, in patients with FAP, DTs represent the first cause of mortality in those patients who received total or subtotal colectomy to reduce the risk of colorectal cancer,⁹ while the risk of DT-related death is very low in sporadic cases.

Recently, the management of DT has radically changed, shifting towards more conservative management.² Given the unpredictable behaviour of this disease, with a tendency to spontaneous regression reported in up to

20% of cases,¹⁰ an upfront active surveillance strategy is generally offered to patients. When an active treatment is required, a systemic therapy is generally preferred.² Several systemic therapies have demonstrated activity in this disease, including anti-oestrogen, non-steroidal anti-inflammatory drugs (NSAIDs), low-dose chemotherapy, conventional chemotherapy and tyrosine kinase inhibitors (imatinib, sorafenib, pazopanib).²

In the last three decades, several case series and two phase II clinical trials have evaluated low-dose chemotherapy with methotrexate (MTX) and vinca alkaloids in patients with DT, reporting radiological objective responses in the range of 30%–75% of cases and prolonged clinical benefit.^{11–17} However, because of the rarity of FAP-associated DTs, the aforementioned data were developed irrespective of DT subtype, with the vast majority of cases being sporadic DTs. Data on low-dose chemotherapy in FAP-related DT are therefore very limited. Here, we report on the results of a multi-institutional, retrospective study of patients with FAP-associated DT treated with low-dose MTX and vinca alkaloids.

MATERIALS AND METHODS

We retrospectively reviewed all cases of patients with FAP-associated DT treated with low-dose MTX plus vinorelbine or low-dose MTX plus vinblastine between January 2000 and December 2018 in seven European sarcoma reference centres (four in Italy, one in Germany, one in England, one in Spain). Diagnosis of FAP was locally confirmed by analysis of germline DNA for the presence of pathogenic *APC* mutations.

Patient medical records were examined retrospectively to collect clinical data. The following data were collected: age at diagnosis, primary site of disease, evidence of multifocality, prior treatment (including surgery, hormone and medical therapy with NSAIDs), main reason for treatment initiation (progressive disease before chemotherapy; symptomatic disease, ie, pain or obstructive bowel symptoms; disease in a critical anatomical site, defined as any site in the judgement of the treating physician where disease progression would have carried high risk of symptoms or complications; other reasons), type of chemotherapy, G3/G4 toxicities according to the current version of Common Terminology Criteria for Adverse Events (CTCAE), radiological response, reason for treatment discontinuation and time to progression.

Chemotherapy was initially administered according to the following schedules: weekly MTX 30 mg/m² plus vinorelbine 20 mg/m²; or weekly MTX 30 mg/m² plus vinblastine 6 mg/m², and reduced in presence of excessive toxicities. Each weekly administration was considered a chemotherapy cycle.

Radiological response was evaluated by MRI or CT, every 3 to 4 months, and evaluated according to Response Evaluation Criteria in Solid Tumors (RECIST, V.1.0 before January 2009 and V.1.1 from January 2009). Disease control rate (DCR) was defined as the percentage

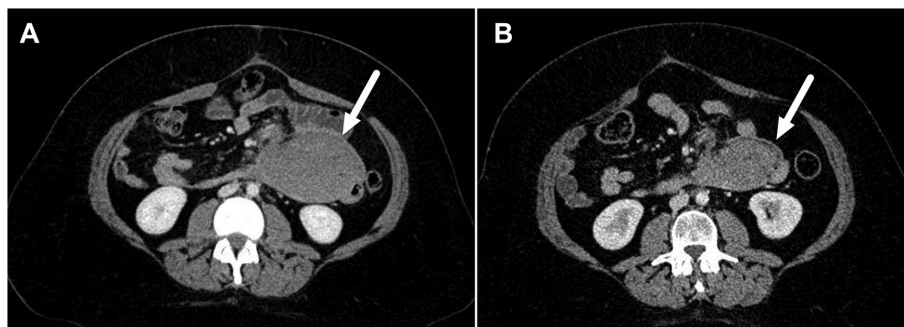


Figure 1 Patient with FAP-associated desmoid tumour treated with MTX+vinorelbine with partial response (PR). (A) CT scan before treatment; (B) CT scan at best response (PR) after 6 months of treatment.

of patients who achieved complete response (CR), partial response (PR) and stable disease (SD) as best response. To calculate progression-free survival (PFS), the event time was computed from the date of treatment start to the date of disease progression or death by any cause; event-free patients were censored at the date of last patient contact. Survival was estimated by Kaplan-Meier method, and groups were compared through the log-rank test. GraphPad Prism V.7.0 (GraphPad Software, La Jolla, USA) and SPSS V.17.0 were used for statistical analyses.

RESULTS

Patient characteristics

Patient characteristics are summarised in [table 1](#).

The analysis included 37 patients, with 22 women (59.5%). Median age of diagnosis was 29 years (range, 7–44 years). Primary tumour sites were intra-abdominal only (25/37; 67.6%), intra-abdominal+trunk/abdominal wall (7/37; 18.9%), trunk/abdominal wall only (3/37; 8.1%) and other sites (2/37; 5.4%). The disease was multifocal in 32/37 (86.5%) of the cases.

Twenty-three out of 37 (62.2%) patients had undergone previous surgery for DT. Prior medical therapy had been administered in 20/37 (54.1%) of patients. Hormonal agents had been administered in 10/37 (27.0%) of patients. Among hormonal agents, tamoxifen was used in six cases, raloxifene in three cases, toremifene in two cases, with one patient receiving two prior lines of hormonal therapy (tamoxifen followed by raloxifene). NSAIDs had been administered in 13/37 (35.1%) of patients. Among NSAIDs, celecoxib was used in five cases, sulindac in four cases, meloxicam in two cases, aspirin in one case, with one patient receiving a non-specified NSAID. A small subgroup of patients, 3/37 (8.1%), received both hormonal therapy and NSAIDs.

The main reasons for chemotherapy initiation were progressive disease in 18/37 (48.6%) of cases, symptomatic disease in 10/37 (27.0%) of cases or disease in a critical anatomical site in the remaining 9/37 (24.3%) patients; no patients had other main reasons for chemotherapy initiation.

The low-dose chemotherapy regimens used were MTX+vinorelbine in 32/37 (86.5%) of cases and MTX+vinblastine in the remaining 5/37 (13.5%) patients. The median number of cycles of chemotherapy was 40 (range, 16–65). The median duration of chemotherapy treatment was 16.5 months (range, 4.0–36.0).

The main reasons for chemotherapy discontinuation were treatment completion defined as the administration of 40 to 50 chemotherapy cycles^{16 18} in 25/37 (67.6%) of cases, treatment lasting approximately one calendar year with <40 total chemotherapy cycles for 7/37 (18.9%) of cases, patient's choice in one case, prolonged G2 neurotoxicity in one case and for unknown reasons in one patient.

On subsequent disease progression, MTX and vinca alkaloid rechallenge was offered to 11 patients following prolonged disease control after initial chemotherapy.

Efficacy

Median follow-up was 5.4 years (range, 1.2–18.3 years). All patients were evaluable for response. According to RECIST, there were no CR; 20/37 (54.1%, 95% CI 36.9% to 70.5%) of the patients achieved a PR, 15/37 (40.5%, 95% CI 24.8% to 57.9%) patients had SD and 2/37 (5.4%, 95% CI 0.7% to 18.2%) had progressive disease (PD) as best response. The DCR was 94.6%. A representative MRI showing a partial response is shown in [figure 1](#). No CTCAE G3/G4 toxicities nor toxic deaths were recorded.

Overall, the median PFS was 6.5 years (range, 0.3–12.1 years) ([figure 2A](#)). Univariate survival analysis of all the variables is shown in [table 2](#).

Of the 10 symptomatic patients, 9 patients (90.0%) reported some symptomatic relief.

Although none of the variables was significantly associated with survival, in the subset of patients achieving PR as best response, the median PFS was not reached, compared with 3.8 years in patients who achieved SD or PD as best response ([figure 2B](#)) ($p=0.0639$). Similarly, age at diagnosis younger than 29 years (median value) was associated with a non-significant trend towards longer median PFS ($p=0.0850$). Multivariate analysis was not performed due to the low number of cases.

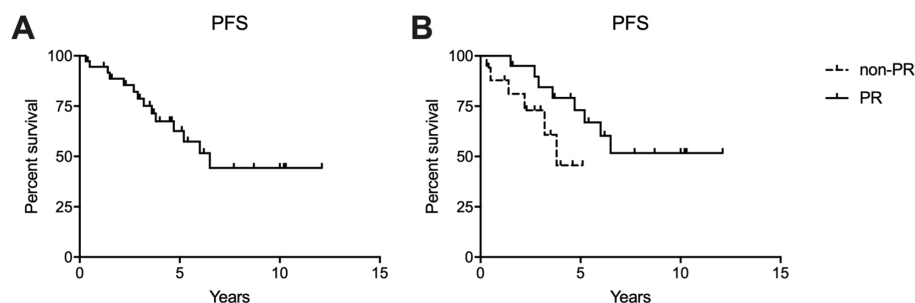


Figure 2 Kaplan-Meier curves for progression-free survival (PFS). (A) Overall population. (B) Depending on best response (partial response (PR) vs non-PR).

In 11 patients with evidence of disease progression after stopping MTX+vinca alkaloids who were rechallenged to the same regimen, DCR after rechallenge was 100%, with a median PFS after rechallenge of 5.8 years (range, 2.0–5.9 years) (figure 3).

DISCUSSION

FAP-associated DTs represent a challenging disease. Compared with sporadic tumours, FAP-associated DTs generally arise from a more critical anatomical site, at higher risk of complications, being more often intra-abdominal. In our series, about 70% of the cases had intra-abdominal disease and more than 80% of patients had multifocal disease.

Our analysis included 37 patients with chemo-naïve, FAP-associated DT treated with MTX and vinca alkaloids. Although retrospective, this is to the best of our knowledge the largest series of patients with FAP-associated DT treated with chemotherapy. In 2006, the only prospective trial specifically addressing the role of the combination of doxorubicin and dacarbazine in FAP-associated DTs recruited only seven patients.¹⁹

In this series, we reported a response rate of 54.1% and stable disease in 40.5% of cases. Importantly, our response rate was calculated on dimensional rather than morphological criteria, and this might underestimate the true response rate.²⁰

The median PFS was 6.5 years. These results are superimposable with those observed in previous reports that have investigated this regimen essentially in sporadic DTs. In particular, in a recent large retrospective analysis with more than 70 sporadic DTs, the partial response rate was approximately 50%, with a median PFS of 6.3 years (11.3 years in the subgroup of responding patients and 4.1 years in patients with SD/PD as best response).¹⁶ In the same study, MTX and vinca alkaloid rechallenge in patients with disease progression after chemotherapy withdrawal following prolonged stabilisation was extremely effective in halting disease progression.¹⁶ The same results were observed in our 11 patients offered rechallenge, with a DCR on rechallenge of 100% and a second median PFS of 5.8 years. Overall, our results suggest that low-dose chemotherapy with MTX and vinca alkaloids in DT is equally active and effective regardless of the genetic driver.

Adverse events associated to the chemotherapeutic regimens were within expectations and overlapping with previous reports,¹⁶ and resulted in only one case of early treatment discontinuation for a prolonged G2 neurological toxicity.

Recently, novel medical therapies such as tyrosine kinase inhibitors or gamma-secretase inhibitors have

Table 2 Survival analysis

Variable	P value
Best RECIST response (PR vs non-PR)	0.0639
Age (<median vs ≥median)	0.0850
Multifocal disease (yes vs no)	0.1272
Gender (male vs female)	0.2216
Previous hormonal therapy (yes vs no)	0.2503
Reasons for treatment discontinuation (completion vs all other reasons)	0.7266
Previous surgery (yes vs no)	0.7872
Primary tumour site (intra-abdominal only vs all the other sites)	0.8859
Previous NSAIDs (yes vs no)	0.9263
Reasons for treatment initiation (progressive disease vs symptomatic disease vs disease in a critical site)	0.9320

NSAID, non-steroidal anti-inflammatory drug; PR, partial response.

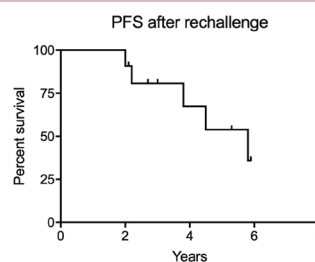


Figure 3 Kaplan-Meier curves for progression-free survival (PFS) after rechallenge.

shown promising activity in DTs.^{21–24} Also, in clinical trials, the number of patients with FAP-associated DT included has been very low, consistent with epidemiological expectations. For example, the promising gamma-secretase inhibitor nirogacestat was evaluated in a phase II trial in 17 patients with DT, of which only 3 (17.6%) had FAP-associated DTs.²³ Similarly, in the recent phase II evaluating pazopanib or low-dose MTX+vinblastine activity in progressive DTs, out of 72 patients recruited, only 8 (11.1%) had confirmed *APC* mutations; the PFS rate at 6 months in the overall group was only 45%.²¹ An effort to better understand the role of these therapies in FAP-related DTs should be advocated.

In conclusion, in this series, low-dose chemotherapy with MTX and vinca alkaloids resulted in more than 50% of patients experiencing a PR, with almost 95% of them showing disease control. The median PFS was 6.5 years; longer in patients achieving PR as a best response. Also, MTX and vinca alkaloids rechallenge was effective in controlling disease progression after chemotherapy withdrawal following prolonged disease control. Given our results, the treatment algorithm of FAP-associated DTs remains consistent with the general approach recently proposed in a collaborative position paper for sporadic DTs.² Nevertheless, abdominal surgery with anticipated low morbidity might be more challenging for intra-abdominal FAP-associated DTs and medical therapy therefore more relevant.

Finally, these data may serve as a benchmark for future trials in FAP-related DTs. Moreover, this study confirms the value of international, collaborative, retrospective studies among reference centres to answer relevant clinical questions in very rare neoplasms.

Summary

Low-dose chemotherapy with methotrexate and vinca alkaloids is an active and tolerated regimen in sporadic DTs. No data are present in the literature on its activity in FAP-associated DTs, which represent about 10%–15% of all cases. This is the first study showing that the combination of methotrexate and vinca alkaloids is active and tolerated also in FAP-associated DTs. This study expands our evidences on the clinical efficacy of low-dose chemotherapy in DTs to FAP-associated forms, thus impacting the clinical management of this very rare disease.

Author affiliations

¹Medical Oncology, Universita Campus Bio-Medico di Roma, Roma, Lazio, Italy

²Department of Cancer Medicine, Fondazione IRCCS Istituto Nazionale dei Tumori, Milano, Lombardia, Italy

³Department of Surgery, Fondazione IRCCS Istituto Nazionale dei Tumori, Milano, Lombardia, Italy

⁴Medical Oncology, IOV IRCCS, Padova, Veneto, Italy

⁵Medical Oncology, Paolo Giaccone Policlinic, Palermo, Sicilia, Italy

⁶University of Bologna Hospital of Bologna Sant'Orsola-Malpighi Polyclinic, Bologna, Emilia-Romagna, Italy

⁷Surgical Oncology and Thoracic Surgery, Osteoncology and Rare Tumors Center, Istituto Scientifico Romagnolo per lo Studio e la Cura dei Tumori Srl, Meldola, Emilia-Romagna, Italy

⁸Medical Oncology, Faculty of Medicine, Ruprecht Karls University Heidelberg, Mannheim, Baden-Württemberg, Germany

⁹Sarcoma Unit, University Hospital Careggi, Firenze, Toscana, Italy

¹⁰Medical Oncology, Royal Marsden NHS Foundation Trust, London, UK

¹¹Anatomic Pathology, Institute of Biomedicine of Seville (IBiS), Sevilla, Spain

¹²Treviso General Hospital, Treviso, Italy

Contributors Study design: EP, BV. Manuscript writing: AN, EP, BV. Data collection: AN, SP, CC, MV, AB, GB, MN, TI, PH, SGa, SGe, RLJ, NH, JM-B, MSC, MS. Data analysis: AN, EP, BV. Manuscript revision and approval: all authors.

Funding The authors have not declared a specific grant for this research from any funding agency in the public, commercial or not-for-profit sectors.

Competing interests None declared.

Patient consent for publication Obtained.

Ethics approval This study received approval from local ethics committees.

Provenance and peer review Not commissioned; externally peer reviewed.

Data availability statement All data relevant to the study are included in the article or uploaded as online supplementary information.

Open access This is an open access article distributed in accordance with the Creative Commons Attribution Non Commercial (CC BY-NC 4.0) license, which permits others to distribute, remix, adapt, build upon this work non-commercially, and license their derivative works on different terms, provided the original work is properly cited, any changes made are indicated, and the use is non-commercial. See: <http://creativecommons.org/licenses/by-nc/4.0/>.

ORCID iD

Andrea Napolitano <http://orcid.org/0000-0002-7509-1555>

REFERENCES

- Fletcher CDM, Bridge JA, Hogendoorn P, *et al*. *WHO classification of tumours of soft tissue and bone*. 4th edn, 2013.
- Kasper B, Baumgarten C, Garcia J, *et al*. An update on the management of sporadic desmoid-type fibromatosis: a European Consensus Initiative between Sarcoma Patients EuroNet (SPAEN) and European Organization for Research and Treatment of Cancer (EORTC)/Soft Tissue and Bone Sarcoma Group (STBSG). *Ann Oncol* 2017;28:2399–408.
- Friedl W, Caspari R, Sengteller M, *et al*. Can APC mutation analysis contribute to therapeutic decisions in familial adenomatous polyposis? Experience from 680 FAP families. *Gut* 2001;48:515–21.
- DE Marchis ML, Tonelli F, Quaresmini D, *et al*. Desmoid tumors in familial adenomatous polyposis. *Anticancer Res* 2017;37:3357–66.
- Slowik V, Attard T, Dai H, *et al*. Desmoid tumors complicating familial adenomatous polyposis: a meta-analysis mutation spectrum of affected individuals. *BMC Gastroenterol* 2015;15:84.
- Nieuwenhuis MH, Lefevre JH, Bülow S, *et al*. Family history, surgery, and APC mutation are risk factors for desmoid tumors in familial adenomatous polyposis: an international cohort study. *Dis Colon Rectum* 2011;54:1229–34.
- Vitellaro M, Sala P, Signoroni S, *et al*. Risk of desmoid tumours after open and laparoscopic colectomy in patients with familial adenomatous polyposis. *Br J Surg* 2014;101:558–65.
- Campos FG, Martinez CAR, Novaes M, *et al*. Desmoid tumors: clinical features and outcome of an unpredictable and challenging manifestation of familial adenomatous polyposis. *Fam Cancer* 2015;14:211–9.
- Parc Y, Piquard A, Dozois RR, *et al*. Long-term outcome of familial adenomatous polyposis patients after restorative colectomy. *Ann Surg* 2004;239:378–82.
- Bonvalot S, Ternès N, Fiore M, *et al*. Spontaneous regression of primary abdominal wall desmoid tumors: more common than previously thought. *Ann Surg Oncol* 2013;20:4096–102.
- Weiss AJ, Lackman RD. Low-dose chemotherapy of desmoid tumors. *Cancer* 1989;64:1192–4.
- Azzarelli A, Gronchi A, Bertulli R, *et al*. Low-dose chemotherapy with methotrexate and vinblastine for patients with advanced aggressive fibromatosis. *Cancer* 2001;92:1259–64.
- Al-Otaibi ML, Turcotte RE, Hings I, *et al*. Low-dose chemotherapy for extra-abdominal desmoid tumor. *Saudi Med J* 2008;29:1730–4.
- Nishida Y, Tsukushi S, Urakawa H, *et al*. Low-dose chemotherapy with methotrexate and vinblastine for patients with desmoid



- tumors: relationship to CTNNB1 mutation status. *Int J Clin Oncol* 2015;20:1211–7.
- 15 Park K-H, Choi YJ, Kim K-W, *et al.* Combination chemotherapy with methotrexate and vinblastine for surgically unresectable, aggressive fibromatosis. *Jpn J Clin Oncol* 2016;46:845–9.
- 16 Palassini E, Frezza AM, Mariani L, *et al.* Long-term efficacy of methotrexate plus vinblastine/vinorelbine in a large series of patients affected by desmoid-type fibromatosis. *Cancer J* 2017;23:86–91.
- 17 Skapek SX, Ferguson WS, Granowetter L, *et al.* Vinblastine and methotrexate for desmoid fibromatosis in children: results of a Pediatric Oncology Group Phase II Trial. *J Clin Oncol* 2007;25:501–6.
- 18 Weiss AJ, Horowitz S, Lackman RD, *et al.* Therapy of desmoid tumors and fibromatosis using vinorelbine. *Am J Clin Oncol* 1999;22:193–5.
- 19 Gega M, Yanagi H, Yoshikawa R, *et al.* Successful chemotherapeutic modality of doxorubicin plus dacarbazine for the treatment of desmoid tumors in association with familial adenomatous polyposis. *J Clin Oncol* 2006;24:102–5.
- 20 Sheth PJ, Del Moral S, Wilky BA, *et al.* Desmoid fibromatosis: MRI features of response to systemic therapy. *Skeletal Radiol* 2016;45:1365–73.
- 21 Toulmonde M, Pulido M, Ray-Coquard I, *et al.* Pazopanib or methotrexate–vinblastine combination chemotherapy in adult patients with progressive desmoid tumours (DESMOPAZ): a non-comparative, randomised, open-label, multicentre, phase 2 study. *Lancet Oncol* 2019;20:1263–72.
- 22 Gounder MM, Mahoney MR, Van Tine BA, *et al.* Sorafenib for advanced and refractory desmoid tumors. *N Engl J Med* 2018;379:2417–28.
- 23 Kummar S, O'Sullivan Coyne G, Do KT, *et al.* Clinical activity of the γ -secretase inhibitor PF-03084014 in adults with desmoid tumors (aggressive fibromatosis). *J Clin Oncol* 2017;35:1561–9.
- 24 Kasper B, Gruenwald V, Reichardt P, *et al.* Imatinib induces sustained progression arrest in RECIST progressive desmoid tumours: final results of a phase II study of the German Interdisciplinary Sarcoma Group (GISG). *Eur J Cancer* 2017;76:60–7.