

Access this article online
Quick Response Code:

Website: www.jorthodsci.org
DOI: 10.4103/jos.jos_174_23

# Lower molar distalization using clear aligners: Is it effective? A systematic review

Horodyski Martina, De Stefano Adriana A., Bottone Ernesto, Impellizzeri Alessandra, Vernucci Roberto A. and Galluccio Gabriella

## Abstract

Distalization is one of the most useful movements in orthodontic treatments. The aim of this systematic review is to analyze the effectiveness of lower molar distalization using clear aligner therapy (CAT). An electronic search was made from January 2012 to October 2022 using PubMed, Scopus, and LILACS databases without language limitations. This systematic review followed the Preferred Reporting Items for Systematic reviews and Meta-Analyses checklist. The search strategy resulted in 151 studies. A screening was performed to remove duplicates, and all the studies that did not respond to our questions for the title or abstract. Three studies underwent full text analysis. From the evaluation of the studies included in this review, it is possible to state that lower molar distalization is a clinical solution, but it is not a full bodily movement. CAT can provide more specifically a distal tipping movement. This is confirmed analyzing the discrepancy between expected movement and obtained movement. CAT can be considered a valid therapeutic option in patients with dental class III malocclusion, but it is obtained as a tipping movement instead of a body movement. Over-correction should be considered during the planning of the therapy.

## Keywords:

Clear aligner appliances, digital technology, invisalign, molar distalization, orthodontic tooth movement, orthodontics, systematic review

## Introduction

Distalization is an important movement to gain space in arches in patients with III skeletal class or with crowding, specifically in non-surgical cases and non-extractive cases.<sup>[1,2]</sup>

The ideal treatment for mandibular prognathism in non-growing patients involves surgical correction of the skeletal malposition. However, in patients with mild-to-moderate skeletal discrepancies who refuse to undergo orthognathic surgery, camouflage treatment may be used to achieve functional occlusion with a normal incisor overbite and overjet.<sup>[3]</sup>

This is an open access journal, and articles are distributed under the terms of the Creative Commons Attribution-NonCommercial-ShareAlike 4.0 License, which allows others to remix, tweak, and build upon the work non-commercially, as long as appropriate credit is given and the new creations are licensed under the identical terms.

For reprints contact: WKHLRPMedknow\_reprints@wolterskluwer.com

Lower molar distalization is a difficult movement to obtain because the mandibular bone is thicker and the lower molar morphology is more complex than the upper molar morphology.<sup>[4]</sup>

Nowadays, various techniques have been introduced in orthodontics with the aim of accelerating and stimulating tooth movement, especially in cases where there is low predictability of movement or to reduce the side effect and to decrease the time of orthodontic treatment.<sup>[5-10]</sup>

Clear aligners are widely used in orthodontics because of their esthetics, comfort, and efficiency in treatments that require molar distalization.<sup>[11-13]</sup> It is possible to program tooth movements during clear

**How to cite this article:** Martina H, Stefano Adriana AD, Ernesto B, Alessandra I, Roberto AV, Galluccio Gabriella G. Lower molar distalization using clear aligners: Is it effective? A systematic review. *J Orthodont Sci* 2024;13:11.

Department of Oral and Maxillofacial Sciences, Sapienza University of Rome, Roma RM, Italy

### Address for correspondence:

Dr. De Stefano Adriana A.,  
Via Caserta 6 –  
00161- Roma, Roma RM,  
Italy.  
E-mail: adriana.destefano@uniroma1.it

Submitted: 28-Sep-2023  
Revised: 09-Jan-2024  
Accepted: 24-Jan-2024  
Published: 16-Feb-2024

aligner therapy (CAT) using specific software in the design stage. Molar distalization has a high expression rate with CAT, but often, there is a discrepancy between the expected movements and effective movements.<sup>[14-17]</sup> In scientific literature, there are a lot of studies about efficiency of CAT, but there are a few studies that analyzed distalization of lower molars.<sup>[17-19]</sup>

The aim of this study is to evaluate the scientific evidence related to the efficacy of lower molar distalization using only CAT without a miniscrew through a systematic review of the literature. The present systematic review was performed to answer the following clinical research question: Is CAT without a miniscrew effective in lower molar distalization or there are mostly uprighting movements?

## Methods

### Protocol and eligibility criteria

In October 2022, a systematic search in the medical literature (Scopus, PubMed, and Lilacs databases) was performed to identify all peer-reviewed articles potentially relevant to the review's question. In this systematic review, the search and selection strategy were developed by following standards and guidelines reported in the PRISMA (Preferred Reporting Items for Systematic Reviews and Meta-Analyses) statement.<sup>[20]</sup>

### Search strategy

The search strategy was "(Molar distalization) AND ((Clear Aligner) OR (Invisalign))". Keywords employed were the same in each database. Our research covered the period from January 2008 until October 2022. No language restrictions were applied. Only studies on humans were included, with male and female participants older than 18 years old.

Randomized controlled trials (RCTs) and cohort, case-control, longitudinal, and epidemiological studies were all considered, while case reports, case series, reviews, books or book chapters, abstracts, and editorials were excluded. Studies that analyzed lower molar distalization with CAT and miniscrews were excluded.

### Selection process

Two independent reviewers checked the initial collection of articles. A first screen was performed by examining titles and abstracts; subsequently, full texts were assessed for eligibility criteria.

### Data items

The data items collected were author, year of publication, sample size, mean age, aligner system, and effectiveness of lower molar distalization.

## Methodological quality assessment

A grading system described by the Swedish Council on Technology Assessment in Health Care (SBU) was used to rate the methodological quality of the articles and to assess the level of evidence of this review [Table 1].

Evaluation of methodological quality gives an indication of the strength of evidence provided by the study because flaws in the design or in the conduction of a study can result in biases.

### Data analysis

To perform this systematic review, there were analyzed studies that calculated how many millimeters of lower second molar distalization can be achieved by using CAT to define a quantitative evaluation of the movement and to establish the effectiveness of aligners in lower molar distalization.

## Results

### Study selection

The search strategy resulted in 151 studies. A first screening was performed to remove duplicates, so 27 articles were removed. Then, all studies that did not respond to the study question for the title or abstract were excluded: only three studies underwent full text analysis [Figure 1].

### Study characteristics and quality of the individual studies

Three studies were included: a preliminary study, a retrospective study, and an RCT. All the data considered and the quality of evidence of the individual studies are reported in Table 2.

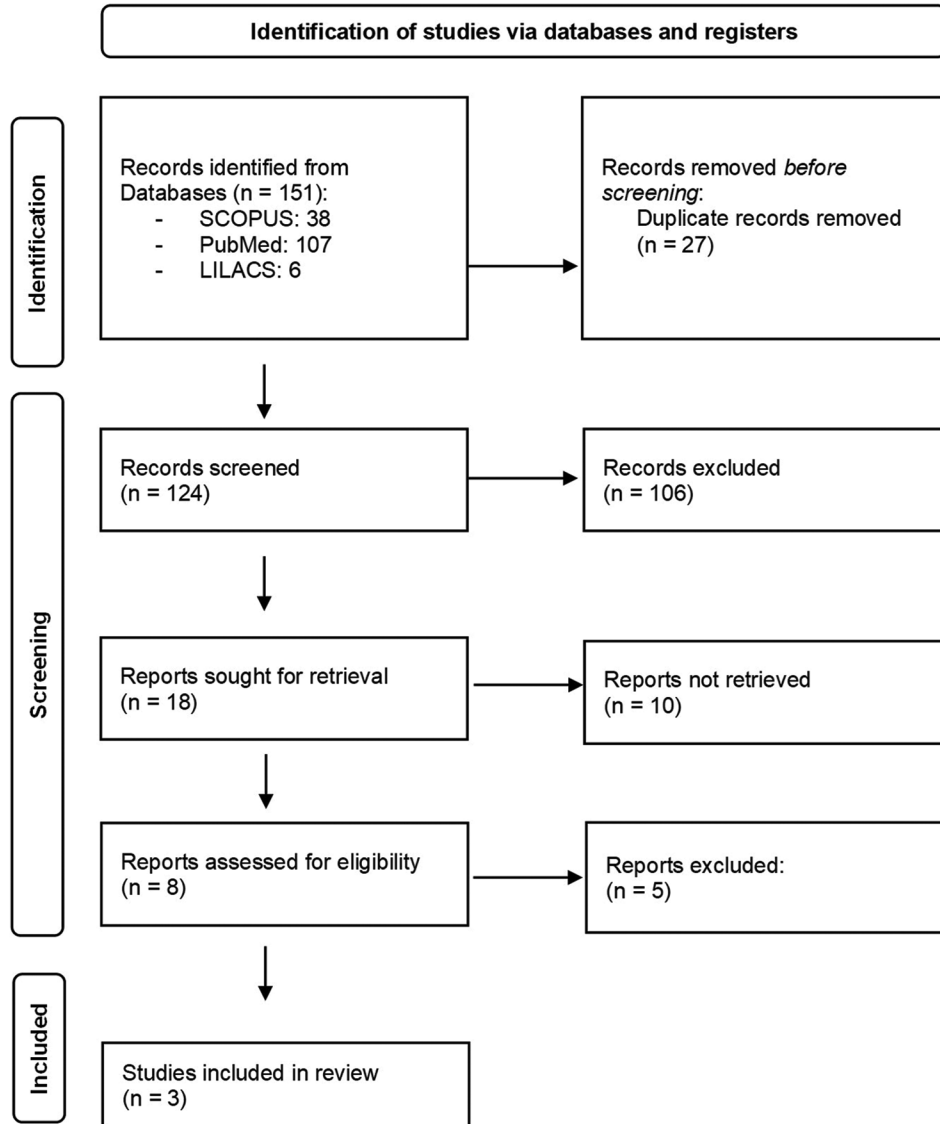
According to the SBU tools, the methodological quality of the studies was evaluated. In this way, it is possible to have a specific indication of the strength of evidence provided by the studies because flaws in

**Table 1: SBU grading system to assess the level of evidence of a systematic review**

Grade	Criteria
A (High value of evidence)	Randomized clinical study or retrospective study with a well-defined control group. Defined diagnosis and endpoints. Diagnostic reliability tests and reproducibility described. Blinded outcome assessment.
B (Moderate value of evidence)	Cohort study or retrospective case series with a defined control or reference group. Defined diagnosis and endpoints. Diagnostic reliability tests and reproducibility described.
C (Low value of evidence)	Large attrition. Unclear diagnosis and endpoints. Poorly defined patient material.

**Table 2: Study characteristics and quality of the individual studies**

Author	Type of study	Sample size	Mean age	Aligners applied	Quality of evidence (SBU grading system)
Rota <i>et al.</i> <sup>[23]</sup> 2022	Preliminary study	16 (8M; 8F)	25,6	Invisalign	B
Han <i>et al.</i> <sup>[21]</sup> 2021	Retrospective study	32 (9M; 23F)	24,83	Invisalign	B
Wu <i>et al.</i> <sup>[22]</sup> 2021	RCT	20 (8M; 12F)	Unknown	Invisalign	B

**Figure 1:** Flowchart from the PRISMA method — article selection process

the design or in the conduction of a study can result in biases.

The grade of evidence of the analyzed studies influenced the level of evidence of our review. There are four levels of evidence of a review, as reported in Table 3. The studies that were analyzed had a grade B of evidence, so the level of this review is supposed to be 3.

### Results of single studies

The sample size ranged from 16 to 32 subjects: 37% were male and 63% were female. All subjects were 18 or older.

Two of the three studies were made in China and the other one in Italy. The results of each study analyzed are included in Table 4.

The retrospective study by Han *et al.*<sup>[21]</sup> calculated distalization of the crown and root of first and second lower molars through cone beam computed tomography (CBCT) and Dolphin software. The movement directions of L6 and L7 crowns were both distal. The movement amount was smaller than expected. The difference was statistically significant for crowns and roots for both lower molars.

To measure actual displacement, the authors<sup>[21]</sup> used the expression rate: the percentage ratio between actual and expected displacements.

(Expression rate = actual movement/expected movement × 100%).

The expression rate of the L6 crown was 67.19% ± 20.13%, and that of the L7 crown was 58.47% ± 21.07%. The expression rate of L6 roots was 37.87% ± 33.72%, and that of L7 roots was 57.03% ± 48.48%.

Wu *et al.*<sup>[22]</sup> analyzed first and second lower molar distalization considering roots and different points on the crowns using CBCT and Dolphin software. As in the previous study, these authors calculated the distalization expression rate. For the first molar, the efficiency was 71% for the crown and 47% for the root; the second molar distalization efficiency was 74% for the crown and 49% for the root.

Second and first molars were accompanied by depression, distal tilt, and buccal tilt with 1.06 mm, 2.10°, 2.27° and 0.91 mm, 1.62°, 1.91°, respectively, with significant differences between T0 and T1 ( $P < 0.05$ ).

Rota *et al.*<sup>[23]</sup> analyzed RX cephalograms taken before the treatment (T0) and after the end of the treatment (T1) of 16 patients. All of them had a Class III malocclusion,

and the protocol comprised intermaxillary Class III elastics to counteract the proclination of lower incisors during the entire distalization phase. Through the cephalograms, the following parameters were used to measure changes in the lower molar position. Through these parameters, the mean distalization of the first lower molar was 1.16 mm and the mean distalization of the second lower molar was 2.47 mm. For both molars, there was a significant tipping movement ( $P < 0.05$ ). The global position of lower molars, measured considering the distance from the Co-Go line and occlusal and root references, did not show any significant changes.

## Discussion and Conclusion

The present systematic review was conducted to evaluate the scientific evidence related to the efficacy of lower molar distalization using CAT without a miniscrew.

The scientific evidence of this review is moderated, and it is obviously influenced by the limitations of the analyzed studies. All of them had a poor sample size; one of them was a retrospective study with its intrinsic biases and problems. The number of analyzed studies also was poor because scientific literature focused specifically on upper molar distalization.

Two studies analyzed lower molar distalization by using CBCT and Dolphin software to calculate movements; the other one did it through RX cephalograms. The difference between the methods used to calculate the distalization limited the possibility to do a quantitative evaluation of the results.

As reported in the analyzed studies,<sup>[21-23]</sup> it is possible to state that lower molar distalization is a clinical solution, but it is not a full bodily movement. Specifically, the

**Table 3: Definitions of evidence level**

Level	Evidence	Definition
1	Strong	At least two studies assessed with level "A"
2	Moderate	One study with level "A" and at least two studies with level "B"
3	Limited	At least two studies with level "B"
4	Inconclusive	Fewer than two studies with level "B"

**Table 4: Comparative table of the results of the selected studies**

Study	Results
Rota <i>et al.</i> <sup>[23]</sup> 2022	Lower second molar mean distalization: 2.47 mm; significant tipping ( $P=0.027$ ) Lower first molar mean distalization: 1.16 mm; significant tipping ( $P=0.003$ )
Han <i>et al.</i> <sup>[21]</sup> 2021	Lower first molar distalization: Average efficiency of the crown=67.19% (2.03±1.00 mm) Average efficiency of the root=37.87% (1.53±1.80 mm) Statistically significant difference between the achieved movement amount and the expected amount ( $P<0.05$ ) Lower second molar distalization: Average efficiency of the crown=58.47% (2.16±1.00 mm) Average efficiency of the root=57.03% (0.78±2.16 mm) Statistically significant difference between the achieved movement amount and the expected amount ( $P>0.05$ )
Wu <i>et al.</i> <sup>[22]</sup> 2021	Lower first molar distalization: Effective rate of crown distalization: 71% (0.96±0.65 mm) Effective rate of root distalization: 47% (0.83±0.62) Lower second molar distalization: Effective rate of crown distalization: 74% (1.29±1.25 mm) Effective rate of root distalization: 49% (1.11±1.14 mm) Significant difference between T0 and T1 ( $P<0.05$ )

second lower molar crown can be moved distally for a maximum of 2.47 mm and a minimum of 1.19 mm; the second lower molar root distalization range was between 0.78 mm and 0.83 mm. For the first molar, the maximum crown distalization was between 2.03 mm and 1.16 mm; root distalization was between 1.58 mm and 0.83 mm.

CAT can provide more specifically a distal tipping movement. This is confirmed analyzing the discrepancy between expected movement and obtained movement. There is a difference between distalization of the first lower molar and the second one too because the space behind the second molar is more represented when third molars were removed before treatment.

CAT can be considered a valid therapeutic option in patients with dental class III malocclusion where it is necessary to perform uprighting or to correct minor class III dental discrepancies to achieve Class I molar relationship, but it can obtain mainly a tipping movement. Over-correction and miniscrews should be considered during the planning of the therapy.

Considering all the results of this systematic review, it is recommended that future researchers should include more RCTs with a rigorous methodology and a proper sample size to increase the evidence of the future studies and to develop defined protocols in daily clinical practice.

CAT is effective in lower molar distalization, but there is a difference between movements of the first and second molars and its efficiency seems to be lower than distalization in the upper arch.

### List of abbreviations

CAT: Clear aligner therapy

RCT: Randomized controlled trial

SBU: Swedish Council on Technology Assessment in Health Care

CBCT: Cone beam computed tomography.

### Financial support and sponsorship

Nil.

### Conflicts of interest

There are no conflicts of interest.

## References

1. Reyes BC, Baccetti T, McNamara JA Jr. An estimate of craniofacial growth in Class III malocclusion. *Angle Orthod* 2006;76:577-84.
2. Baccetti T, Franchi L, McNamara JA Jr. Growth in the untreated Class III subjects. *Semin Orthod* 2007;13:130-42.
3. Choi YT, Kim YJ, Yang KS, Lee DY. Bone availability for mandibular molar distalization in adults with mandibular prognathism. *Angle Orthod* 2018;88:52-7.
4. Iglesias-Linares A, Morford LA, Hartsfield JK Jr. Bone density and dental external apical root resorption. *Curr Osteoporos Rep* 2016;14:292-309.
5. Impellizzeri A, Horodyski M, Palaia G, Romeo U, Galluccio G. CO2 and diode lasers vs. conventional surgery in the disinclusion of palatally impacted canines: A randomized controlled trial. *Photonics* 2023;10:244.
6. Impellizzeri A, Horodyski M, Serritella E, Polimeni A, Galluccio G. Uncovering and autonomous eruption of palatally impacted canines: A case report. *Dent J* 2021;9:66.
7. Impellizzeri A, Horodyski M, Fusco R, Palaia G, Polimeni A, Romeo U, et al. Photobiomodulation therapy on orthodontic movement: Analysis of preliminary studies with a new protocol. *Int J Environ Res Public Health* 2020;17:3547. doi: 10.3390/ijerph17103547.
8. Impellizzeri A, Horodyski M, De Stefano A, Guercio-Monaco E, Palaia G, Serritella E, et al. Disinclusion of palatally impacted canines with surgical and photobiomodulating action of a diode laser: Case series. *Appl Sci* 2021;11:4869.
9. Raghis TR, Alsulaiman TMA, Mahmoud G, Youssef M. Efficiency of maxillary total arch distalization using temporary anchorage devices (TADs) for treatment of Class II-malocclusions: A systematic review and meta-analysis. *Int Orth* 2022;20:100666. doi: 10.1016/j.ortho.2022.100666.
10. Leo M, Cerroni L, Pasquantonio G, Condò SG, Condò R. Temporary anchorage devices (TADs) in orthodontics: Review of the factors that influence the clinical success rate of the mini-implants. *Clin Ter* 2016;167:e70-7.
11. Galluccio G, De Stefano AA, Horodyski M, Impellizzeri A, Guarnieri R, Barbato E, et al. Efficacy and accuracy of maxillary arch expansion with clear aligner treatment. *Int J Environ Res Public Health* 2023;20:4634. doi: 10.3390/ijerph20054634.
12. Putrino A, Barbato E, Galluccio G. Clear aligners: Between evolution and efficiency-a scoping review. *Int J Environ Res Public Health* 2021;18:2870. doi: 10.3390/ijerph18062870.
13. Robertson L, Kaur H, Fagundes NC, Romanyk D, Major P, Flores Mir C. Effectiveness of clear aligner therapy for orthodontic treatment: A systematic review. *Orthod Craniofac Res* 2020;23:133-42.
14. Rossini G, Parrini S, Castroflorio T, Deregisbus A, Debernardi CL. Efficacy of clear aligners in controlling orthodontic tooth movement: A systematic review. *Angle Orthod* 2015;85:881-9.
15. Papadimitriou A, Mousoulea S, Gkantidis N, Kloukos D. Clinical effectiveness of Invisalign® orthodontic treatment: A systematic review. *Prog Orthod* 2018;19:37.
16. Galan-Lopez L, Barcia-Gonzalez J, Plasencia E. A systematic review of the accuracy and efficiency of dental movements with Invisalign®. *Korean J Orthod* 2019;49:140-9.
17. Galluccio G. Is the use of clear aligners a real critical change in oral health prevention and treatment? *Clin Ter* 2021;172:113-5.
18. D'Antò V, Valletta R, Ferretti R, Bucci R, Kirlis R, Rongo R. Predictability of maxillary molar distalization and derotation with clear aligners: A prospective study. *Int J Environ Res Public Health* 2023;20:2941.
19. Ravera S, Castroflorio T, Garino F, Daher S, Cugliari G, Deregisbus A. Maxillary molar distalization with aligners in adult patients: A multicenter retrospective study. *Prog Orthod* 2016;17:12.
20. Zorzela L, Loke YK, Ioannidis JP, Golder S, Santaguida P, Altman DG, et al. PRISMA harms checklist: Improving harms reporting in systematic reviews. *BMJ* 2016;353:i2229. doi: 10.1136/bmj.i2229.
21. Han J, Ning N, Du H, Zhou M, Cai C, Hong Y, et al. Efficacy of clear aligners on mandibular molar distalization: A retrospective study. *Digit Med* 2021;7:1.
22. Wu D, Zhao Y, Ma M, Zhang Q, Lei H, Wang Y, et al. Efficacy of mandibular molar distalization by clear aligner treatment. *Zhong Nan Da Xue Xue Bao Yi Xue Ban* 2021;46:1114-21.
23. Rota E, Parrini S, Malekian K, Cugliari G, Mampieri G, Deregisbus A, et al. Lower molar distalization using clear aligners: Bodily movement or uprighting? A preliminary study. *Appl Sci* 2022;12:7123.