

# Measuring Cortical Connectivity in Alzheimer's Disease as a Brain Neural Network Pathology: Toward Clinical Applications



INS is approved by the American Psychological Association to sponsor Continuing Education for psychologists. INS maintains responsibility for this program and its content.

Stefan Teipel,<sup>1,2</sup> Michel J. Grothe,<sup>2</sup> Juan Zhou,<sup>3</sup> Jorge Sepulcre,<sup>4</sup> Martin Dyrba,<sup>2</sup> Christian Sorg,<sup>5</sup> AND Claudio Babiloni<sup>6</sup>

<sup>1</sup>Department of Psychosomatic Medicine, University of Rostock, Rostock, Germany

<sup>2</sup>DZNE, German Center for Neurodegenerative Diseases, Rostock, Germany

<sup>3</sup>Center for Cognitive Neuroscience, Neuroscience and Behavioral Disorders Program, Duke-NUS Graduate Medical School, Singapore

<sup>4</sup>Division of Nuclear Medicine and Molecular Imaging, Massachusetts General Hospital, Harvard Medical School, Boston, Massachusetts

<sup>5</sup>Department of Psychiatry and Neuroradiology, TUM-NIC Neuroimaging Center, Technische Universität München, Munich, Germany

<sup>6</sup>Department of Physiology and Pharmacology "V. Erspamer", University of Rome "La Sapienza", Rome, Italy; IRCCS San Raffaele Pisana of Rome, Italy

(RECEIVED April 2, 2015; FINAL REVISION July 31, 2015; ACCEPTED September 20, 2015)

## Abstract

**Objectives:** The objective was to review the literature on diffusion tensor imaging as well as resting-state functional magnetic resonance imaging and electroencephalography (EEG) to unveil neuroanatomical and neurophysiological substrates of Alzheimer's disease (AD) as a brain neural network pathology affecting structural and functional cortical connectivity underlying human cognition. **Methods:** We reviewed papers registered in PubMed and other scientific repositories on the use of these techniques in amnesic mild cognitive impairment (MCI) and clinically mild AD dementia patients compared to cognitively intact elderly individuals (Controls). **Results:** Hundreds of peer-reviewed (cross-sectional and longitudinal) papers have shown in patients with MCI and mild AD compared to Controls (1) impairment of callosal (splenium), thalamic, and anterior–posterior white matter bundles; (2) reduced correlation of resting state blood oxygen level-dependent activity across several intrinsic brain circuits including default mode and attention-related networks; and (3) abnormal power and functional coupling of resting state cortical EEG rhythms. Clinical applications of these measures are still limited. **Conclusions:** Structural and functional (in vivo) cortical connectivity measures represent a reliable marker of cerebral reserve capacity and should be used to predict and monitor the evolution of AD and its relative impact on cognitive domains in pre-clinical, prodromal, and dementia stages of AD. (*JINS*, 2016, 22, 138–163)

**Keywords:** Dementia diagnosis, Prognosis, PET, MRI, EEG, Treatment trials

## INTRODUCTION

Alzheimer's disease (AD) is the most frequent neurodegenerative disorder causing cognitive impairment, disabilities, and finally dementia in aged people. This disease is related to an extra-cellular brain accumulation of beta-amyloid (A $\beta$ ) and intracellular tangles of hyperphosphorylated tau peptides that affect cortical neuronal networks related to cognitive functions (Pievani, de Haan, Wu, Seeley, & Frisoni, 2011). Soluble A $\beta$  elicits a toxic signaling cascade by receptors leading to synaptic impairments, intraneuronal A $\beta$ 42 aggregates, and correlated cognitive deficits (Dziewczapolski, Glogowski, Masliah, & Heinemann, 2009). This compromised signaling

possibly leads to or aggravates aggregation of hyperphosphorylated tau protein and formation of neurofibrillary tangles (NFTs). Preclinical data suggest a non-linear relationship of A $\beta$  peptide levels with synaptic plasticity (Parihar & Brewer, 2010). A $\beta$  at lower levels may play a physiological role in synaptic plasticity (Puzzo et al., 2008), whereas higher levels of A $\beta$  may impair synaptic activity (Shankar et al., 2007) or may even be induced by synaptic activity (Cirrito et al., 2008) in metabolic active cortical regions (Buckner et al., 2009). The bidirectional interaction between local amyloid accumulation and metabolic activity may be an important determinant for the cognitive effects of AD pathological changes and represent a potential determinant for brain reserve capacity, that is, the ability of the brain to maintain function despite an increasing load of neurodegenerative lesions.

Structural, molecular, and functional neuroimaging studies have replicated the findings of a systematic spread of AD

Correspondence and reprint requests to: Stefan Teipel, DZNE, German Center for Neurodegenerative Diseases, Gehlsheimer Str. 20, 18147 Rostock. E-mail: stefan.teipel@med.uni-rostock.de

pathology markers. First, patterns of brain atrophy, as revealed by structural magnetic resonance imaging (MRI), most closely resemble the distribution of neurofibrillary tangles across different clinical stages of disease (Chetelat et al., 2002; Whitwell et al., 2007). Second, positron emission tomography (PET) of amyloid in the brain suggests a sequence of amyloid accumulation similar to stages derived from autopsy studies (Thal, Attems, & Ewers, 2014). Third,  $^{18}\text{F}$ FDG-PET detection of cortical glucose consumption uncovers a sequence of metabolic changes that overlaps between both, pattern of brain atrophy/tangle accumulation and amyloid deposition (Choo et al., 2007). An emergent regional pattern from these multimodal-imaging studies suggests a characteristic network of key brain regions that are involved in a specific temporal sequence across the clinical stages of AD.

Compared to the mentioned neuroimaging techniques, human brain neural networks have been more directly probed by diffusion tensor imaging (DTI) and resting-state functional MRI (rs-fMRI). These techniques have identified consistent structurally and functionally connected brain networks in the human brain (Fox et al., 2005; van den Heuvel, Mandl, Kahn, & Hulshoff Pol, 2009). The destruction of key hubs of these networks may mediate the effect of molecular pathology on cognitive performance in AD (Koch et al., 2014); along the same line, brain reserve may act through modulation of such networks to preserve cognitive function in the presence of molecular pathology (Bozzali et al., 2014). One step further, it has even been implicated that the functional connectivity within a network and the strengths of positive functional associations between intrinsic networks determines the regional spread of different types of neurodegenerative changes, such as neurofibrillary tangles, amyloid accumulation, Lewy bodies, and TDP43 deposition, which in turn lead to distinct clinical disease entities, such as AD (tau and amyloid), Lewy body dementia (alpha-synuclein), or frontotemporal dementia (tau and TDP43) (Zhou, Gennatas, Kramer, Miller, & Seeley, 2012).

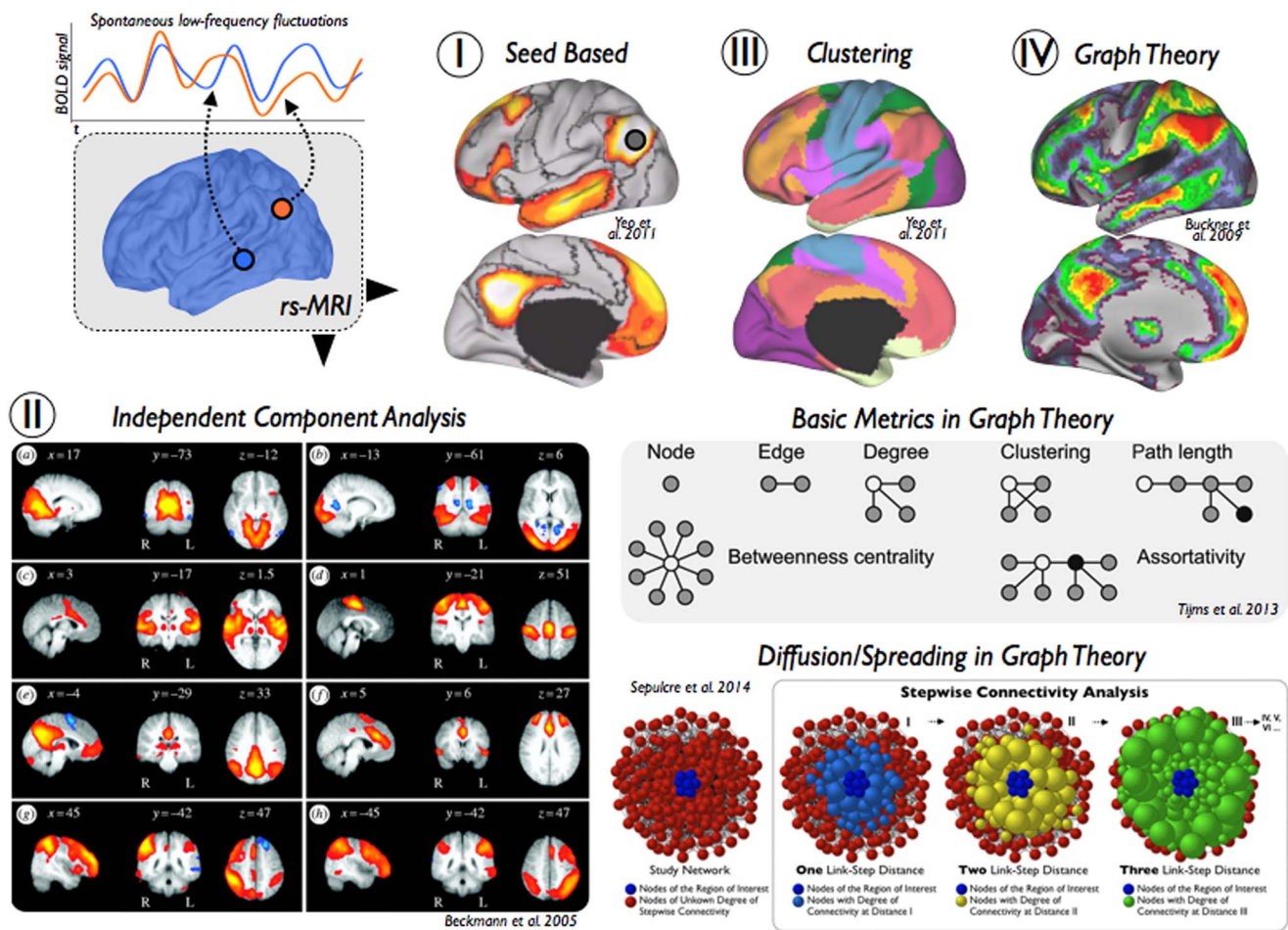
On this basis, an understanding of the functional and structural organization of brain networks may further our understanding of neurodegenerative disease pathogenesis and brain reserve. In a back-translation approach, imaging can provide evidence to support the hypothesis of network specificity of AD. These findings inform basic science studies on potential molecular mechanisms that account for the network specificity of pathological features of AD. Complementary, hypotheses on molecular mechanisms, such as oxidative stress of highly connected network hubs (Buckner et al., 2009) or prion-like spread of pathogenic protein conformations along strong anatomical connections (Braak & Del Tredici, 2011), can be tested in the human *in vivo* framework using multimodal imaging. Associations between metabolic characteristics of a cortical hub region and molecular and atrophic changes, both in large cross-sectional samples across clinically and biomarker-based disease stages and in longitudinal cohorts spanning the time of conversion from cognitively healthy to early dementia stages, can help to test the pathogenetic validity of specific molecular

mechanisms in humans. In a complementary perspective, brain functional and structural connectivity represents the potential substrate of brain reserve capacity in the presence of significant AD pathology and comorbid pathologies such as cerebrovascular disease. Understanding mechanisms of brain reserve provides both potential targets for preventive interventions and *in vivo* surrogate endpoints to test the mechanistic mode of action of a specific intervention. From a clinical point of view, the study of network connectivity may provide a diagnostic marker of early disease as well as a prognostic marker at an individual level where the integrity of key functional networks will influence the likelihood of cognitive decline at a given level of molecular pathology (Teipel et al., 2013).

In the following sections, we will introduce established as well as emerging methods to determine functional and structural cortical connectivity in the living human brain, covering acquisition and analysis of such data, and describe the main contributions of these methods to our current understanding of pathogenesis, diagnosis, and disease monitoring in AD. A specific emphasis is put on multimodal approaches. In this framework, limitations and perspectives will be outlined that are related to the validity of a method (in respect to assumed underlying neurobiological substrates) as well as its implementation into a clinical setting in the middle to the far future.

## Methodology of Connectivity Analysis

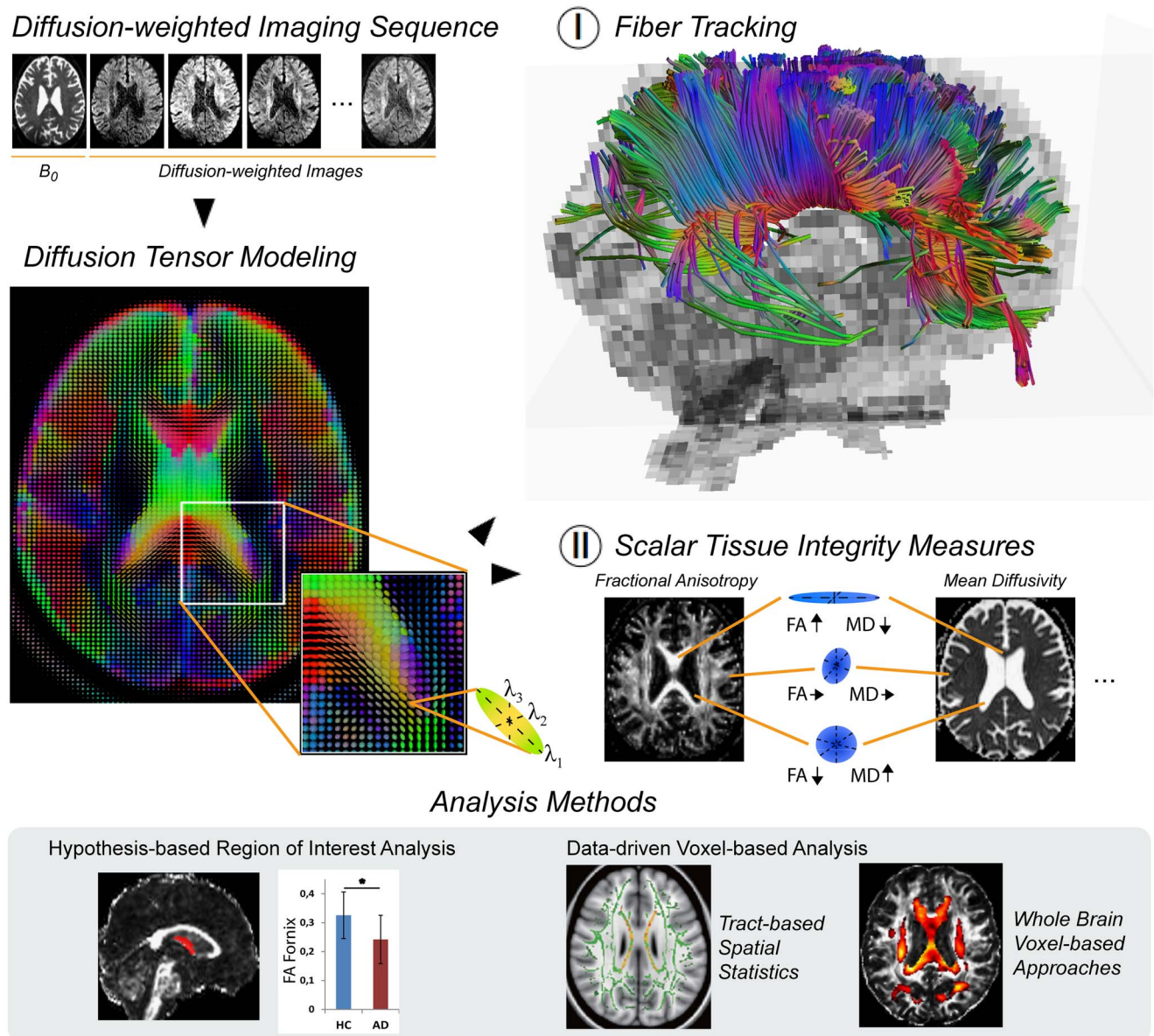
Functional MRI provides a unique window to study AD's impact on coherent slowly fluctuating brain activity, that is, intrinsic brain networks (Fox & Raichle, 2007). At rest, macroscopic brain activity fluctuates slowly at frequencies below 0.1 Hz; such fluctuations are detectable by rs-fMRI. Slowly fluctuating activity is coherent or synchronized across brain regions (i.e., functional connectivity), constituting a couple of intrinsic brain networks such as the default mode or dorsal attention network (Fox et al., 2005). Intrinsic brain networks represent a highly conserved and robust form of organized macroscopic brain activity, that is, comparable networks are observed in distinct species such as mice, monkeys, and humans (Vincent et al., 2007), in distinct stages of ontogeny such as after preterm birth, babies, children, adults, and elder persons (Doria et al., 2010), and at distinct stages of awareness from sleep to different domains of goal-directed behavior (Smith et al., 2009). The rs-fMRI signal is of special relevance for many analytical methods assessing functional connectivity. It provides spontaneous low-frequency fluctuations of blood oxygen level-dependent (BOLD) signals (Figure 1) and makes possible investigations of the network architecture of brain systems (Biswal, Yetkin, Haughton, & Hyde, 1995; Biswal et al., 2010; Fox & Raichle, 2007; Lu et al., 2011). Compared to conventional fMRI studies, rs-fMRI is a task-free and data-driven neuroimaging technique that can be easily acquired in cognitively impaired populations. There are four main methods in which rs-fMRI has been frequently applied. Seed-based analysis uses correlations of rs-fMRI spontaneous low-frequency fluctuations between a seed region and the rest of the brain (Figure 1-I)



**Fig. 1.** Overview of functional connectivity analysis methods for resting-state functional MRI. Several neuroimaging techniques use low-frequency spontaneous fluctuations in brain activity to analyze functional connections in the human brain. (I) Seed-based correlation analysis is a widely used approach to characterize functional connectivity patterns of seed regions or voxels of interest. (II) Independent component analysis is a signal processing method that is able to separate independent sources from mixed signals of the rs-fMRI data. (III) Clustering techniques, such as k-means or hierarchical clustering, are useful approaches to generate spatial partitions based on functional connectivity profiles. (IV) Graph theory refers to a wide field of research that focuses on the analysis of graphs, defined by pairwise associations of nodes, and network structures. In neuroimaging, graph theoretical metrics have been used to describe multiple network properties of the human brain. Several examples of basic measures and a diffusion/spreading method are displayed in the figure.

(Biswal et al., 1995). It describes relatively simple patterns of functional connectivity of single brain areas. More advanced approaches take advantage of multiple simultaneous brain interactions to pull apart coherent brain networks. For instance, independent component analysis (ICA) and clustering methods have been extremely useful to isolate modules of the brain and to create subdivisions and parcellation schemes of the cerebral cortex (Figure 1-II and 1-III) (Beckmann, DeLuca, Devlin, & Smith, 2005; Yeo et al., 2011). Third, graph theory has facilitated the comprehension and visualization of complex brain interactions by transforming connectivity data to nodes (vertices) and links (edges) (Figure 1-IV) (Bullmore & Sporns, 2009; Rubinov & Sporns, 2010). Several graph theoretical metrics quantify “network hubs” of the brain, that is central regions that act as integration stations for connecting otherwise segregated brain networks (Figure 1-IV, Basic Metrics in Graph Theory)

(Buckner et al., 2009; Crossley et al., 2013; Sporns, Honey, & Kotter, 2007; van den Heuvel & Sporns, 2011; Zuo et al., 2012), while other metrics—such as clustering coefficient, path length, small-worldness, or rich-club organization—emphasize modularity or efficient communications. Finally, diffusion graph theory algorithms have been proposed to study putative pathways for the spread of pathology through interconnected brain systems (Figure 1-IV, Diffusion/Spreading Metrics in Graph Theory) (Raj, Kuceyeski, & Weiner, 2012; Sepulcre, Sabuncu, Becker, Sperling, & Johnson, 2013; Sepulcre, Sabuncu, Yeo, Liu, & Johnson, 2012). More advanced analysis methods additionally incorporate the phase lag information of the time signal, such as Granger causality analysis (Goebel, Roebroeck, Kim, & Formisano, 2003; Granger, 1969) or dynamic causal modeling (Friston, Harrison, & Penny, 2003), to derive a causal relationship between brain regions. Those techniques have



**Fig. 2.** Overview of structural connectivity analysis methods for diffusion tensor imaging. Diffusion-weighted imaging assesses the diffusion of water molecules that is restricted by the tissue structure. In diffusion tensor imaging the diffusion process is modeled as a tensor, which is estimated from the non-diffusion image ( $B_0$ ) and the diffusion-weighted scans. The tensor model can be represented as an ellipsoid with three principal axes ( $\lambda_1$ ,  $\lambda_2$ ,  $\lambda_3$ ), the length of which reflects the diffusion tendency along each direction. (I) Fiber tracking algorithms use the shape and the direction of the ellipsoid to trace the most likely fiber pathways. (II) Scalar tissue integrity measures, such as the fractional anisotropy (FA) or mean diffusivity (MD), characterize the shape of the ellipsoid. In large tracts with mainly parallel orientation of the fibers, for example, in the corpus callosum, the ellipsoid is cigar-shaped such that FA reaches its largest values while MD is relatively low. In the liquor, the water is not restricted in any direction leading to a ball-shaped ellipsoid, indicated by high MD and low FA. Both measures have intermediate values in gray matter regions as well as crossing fiber areas where the ellipsoid may be more oblate-shaped. Statistical analysis approaches can be categorized in hypothesis-based region of interest analysis and data-driven voxel-based analysis methods.

been applied less frequently in the context of AD (Agosta et al., 2010; Dauwels, Vialatte, Musha, & Cichocki, 2010; Liu et al., 2012; Miao, Wu, Li, Chen, & Yao, 2011), as they are prone to provide different results caused by random variance in the data (Daunizeau, David, & Stephan, 2011). Further in-depth discussion on methodology of fMRI data analysis can be found in two recent reviews by

Krajcovicova, Marecek, Mikl, & Rektorova (2014) and Dennis & Thompson (2014).

The term *structural connectivity* refers to the interconnection between neurons or brain regions by nerve fibers. The integrity of fiber tracts can be assessed *in vivo* using diffusion-weighted imaging techniques (Le Bihan, Turner, Douek, & Patronas, 1992). These allow the mapping of the

diffusion process of water molecules and rely on the principle that the diffusion of water is restricted by the tissue structure. In the context of AD, diffusion tensor imaging (DTI) is being used most frequently. The minimum scan protocol comprises one non-diffusion image, often referred to as  $B_0$  image, and six diffusion-weighted images for opposing gradient directions (Basser, Mattiello, & LeBihan, 1994). From these data, a tensor model is estimated that can be represented as an ellipsoid with three principal axes, the length of which reflects the diffusion tendency along each direction ( $\lambda_1$ ,  $\lambda_2$ ,  $\lambda_3$ ; Figure 2, Diffusion Tensor Modeling). Scalar tissue integrity measures characterizing the shape of the ellipsoid include the fractional anisotropy (FA), mode of anisotropy (MO), as well as axial (aD), radial (rD), and mean diffusivity (MD), providing complementary information about the configuration of the ellipsoid axes (Le Bihan et al., 2001) (Figure 2-II). In extension to characterizing single voxels, one can perform fiber tracking to infer the white matter pathways within the brain, with the two most popular approaches being streamline and probabilistic tractography (Mori, Crain, Chacko, & Van Zijl, 1999; Mori & Zhang, 2006) (Figure 2-I). Both methods do not only use the shape but also the principal direction of the ellipsoid to trace the most likely fiber pathways. Patient's characteristics, group differences, or statistical associations between fiber tract integrity measures and, for instance, measures of cognitive functioning can be assessed using hypothesis-based region of interest analysis (Figure 2, Analysis Methods). Complementary data-driven voxel-based analysis allows the evaluation of group differences or statistical associations on the level of each single voxel (Figure 2, Analysis Methods).

## CONTRIBUTION OF CORTICAL DISCONNECTION TO AD PHENOTYPE AND DEVELOPMENT

### Functional Connectivity Changes in the Course of AD

Neuroimaging approaches including rs-fMRI have produced a tide of direct support for the network-based neurodegeneration hypothesis in living humans (Buckner et al., 2005; Greicius, Srivastava, Reiss, & Menon, 2004; Raj, Kuceyeski, & Weiner, 2012; Seeley, Crawford, Zhou, Miller, & Greicius, 2009; Zhou, Gennatas, Kramer, Miller, & Seeley, 2012). AD, the most common neurodegenerative disorder, begins with dysfunction in episodic memory before progressing to involve posterior cortical cognitive functions such as word retrieval, visuospatial function, arithmetic, and praxis. In parallel to the symptoms, AD is associated with atrophy and hypometabolism predominantly in posterior hippocampal, cingulate, temporal, and parietal regions, which collectively resemble the default mode network (DMN) as mapped in healthy subjects with task-free fMRI (Greicius, Krasnow, Reiss, & Menon, 2003). The DMN is

typically found deactivated during cognitive tasks requiring externally focused attention and activated during internally focused mental tasks, such as episodic memory retrieval, mental state attribution, and visual imagery (Buckner, Andrews-Hanna, & Schacter, 2008; Mason et al., 2007; Raichle et al., 2001; Shulman et al., 1997).

In addition to the regional atrophy and neuronal hypometabolism affecting DMN nodes, disruptions in functional connectivity of the DMN in AD dementia have been widely replicated (Agosta et al., 2012; Binnewijzend et al., 2012; Greicius, Srivastava, Reiss, & Menon, 2004), and have been linked to core memory and visuospatial deficits (Greicius et al., 2004; Supekar, Menon, Rubin, Musen, & Greicius, 2008; Zhang et al., 2010). Intriguingly, connectivity disruption and impaired task-related down regulation of the DMN may already emerge during the presymptomatic phase of AD as modeled cross-sectionally on the basis of imaging evidence of cortical amyloid pathology (Hedden et al., 2009; Sperling et al., 2009) or an apolipoprotein E4 (APOE4) positive genotype, which is a major genetic risk factor for late onset AD (Damoiseaux et al., 2012; Machulda et al., 2011; Persson et al., 2008). Particularly the functional isolation of the posterior cingulate from its main interaction sites in the medial temporal lobe and the medial prefrontal cortex appears to emerge early in the disease process and was found to be related to worsening episodic memory function in MCI subjects (Bai et al., 2011). Of interest, the posterior cingulate cortex showed reduced connectivity in MCI patients even in the absence of gray matter atrophy, which was only detectable at the stage of fully developed AD (Gili et al., 2011). AD pathology, however, also presents with non-memory symptoms such as impairments in executive function, language, and visuospatial abilities, particularly at the clinically manifest dementia stage of the disease. While there is also evidence of impaired executive function network connectivity (including the dorsal lateral prefrontal cortex and superior parietal lobe) in AD and MCI (Brier et al., 2012; Liang, Wang, Yang, Jia, & Li, 2011; Sorg et al., 2007), the relation of these changes to the emergence of respective clinical symptoms still requires further investigation.

In the task-free setting, DMN activity correlates inversely with activity in multiple brain regions in health, including the salience network (SN) (Fox et al., 2005; Greicius & Menon, 2004; Seeley et al., 2007). Many forms of emotional salience require a focusing of attention toward homeostatic demands and behavioral responses ("here and now"), creating a need to de-prioritize attention to internal ("there and then") ruminations about one's personal past or future, functions attributed to the DMN (Seeley et al., 2007). Such opposing network functions might engender between-network competition for brain resources (Deco & Corbetta, 2011), shifts between "binary brain configurations" (Jones et al., 2012), or direct reciprocal suppression of one network in favor of the other, orchestrated by nodes within the two networks or by a nodal "switch" positioned elsewhere to reconfigure network dynamics in response to shifting conditions (Menon & Uddin, 2010). Questionnaire- and laboratory-based studies

suggest that patients with AD show retained or enhanced interpersonal warmth and empathy, mutual gaze, and emotional morality (Mendez & Shapira, 2009; Rankin et al., 2006; Sollberger et al., 2009; Sturm et al., 2011). Emotional contagion (sharing emotional states with others) appears to increase linearly across the healthy through MCI to AD dementia spectrum (Sturm et al., 2013). In line with these findings, AD patients were shown to exhibit increased SN connectivity compared to controls, which was associated with decreased DMN connectivity (Zhou et al., 2010). SN enhancement has been widely replicated in the growing AD task-free fMRI literature. Evidence to date suggests that SN hub connectivity escalates in genetic at risk groups (APOE4 carriers) and prodromal stages of AD (Bai et al., 2009; Brier et al., 2012; Machulda et al., 2011), correlates with emotion intensification symptoms (Balthazar et al., 2013), is accompanied by SN hyperperfusion (Hsieh, Kao, Huang, & Chou, 2010), and may wane in later disease stages (Brier et al., 2012).

### *Multimodal imaging of functional connectivity and amyloid load*

In addition to the connectivity changes within and across particular networks, emerging graph theoretical approaches also detected changes in general network topology in AD, characterized by a lower clustering coefficient or an increased characteristic path length, which renders the whole-brain network metrics closer to the theoretical values of random networks and largely supports the hypothesis of disrupted global information integration in AD (Sanz-Arigita et al., 2010; Wang et al., 2007). Impaired parallel information transmission efficiency and reduced intra- and inter-modular connectivity of the posterior DMN and executive control network were also detected in healthy APOE4 carriers compared to non-carriers (Wang et al., 2015). Future work is needed to develop network imaging methods equipped to handle both intra- and inter-network connectivity and topology profiles, corresponding to the broad range of clinico-anatomical presentations associated with the disease.

Aberrant functional connectivity of intrinsic networks is intimately linked with AD's amyloid pathology (Drzezga et al., 2011; Sheline, Raichle, et al., 2010; Sperling et al., 2009). Using PiB-PET (i.e., Pittsburgh Compound B PET) to detect *in vivo* amyloid- $\beta$  plaques in combination with rs-fMRI in asymptomatic and mildly impaired elderly with amyloid positivity, Drzezga and colleagues found that the higher the amyloid plaque load the more the global centrality in the parietal cortex is reduced (centrality measures for each voxel its degree of functional connectivity with all other voxels of the brain) (Drzezga et al., 2011). More specifically, for several networks, such as default mode and different attention networks, the spatial distributions of plaques and network functional connectivity were highly correspondent in individuals with prodromal AD, suggesting that plaque spread is linked with a networks' connectivity (Myers et al., 2014). Furthermore, in network centers of high connectivity

and high plaque load, this relationship changes, that is, the more plaques the more connectivity is impaired, demonstrating the detrimental effect of amyloid pathology on intrinsic functional connectivity when certain levels of pathology are overstepped. These studies demonstrate the relevance of intrinsic brain networks for pathophysiology and pathogenesis of AD particularly in early stages of the disease. Of interest, while APOE4 genotype has been consistently associated with increased amyloid load (Morris et al., 2010), detrimental effects of this genotype on functional brain connectivity have also been observed independently of amyloid pathology (Sheline, Morris, et al., 2010). Although genetic effects on functional connectivity disruptions are best studied for the APOE4 genotype, there are now also initial reports of connectivity-altering effects of other risk genes for AD, such as polymorphisms in tau- or KIBRA-related genes (Bai et al., 2014; Wang et al., 2013).

### **Structural Disconnection in the Course of AD**

Several cross-sectional DTI studies revealed white matter integrity changes in AD dementia patients compared to healthy controls in wide spread commissural, association, and limbic fiber tracts, whereas extracortical projecting fiber tracts were found to be relatively preserved until advanced stages of the disease (Bozzali et al., 2002, 2001; Fellgiebel et al., 2005; Friese et al., 2010; Huang, Friedland, & Auchus, 2007; Medina et al., 2006; Naggara et al., 2006; Stahl et al., 2007; Xie et al., 2006; Zhang et al., 2007). In MCI subjects, disruptions of white matter integrity were mainly reported for limbic fiber tracts with direct connections to medial temporal lobe structures, including the posterior and parahippocampal cingulum, the perforant path, the fornix, and the uncinate fasciculus (Fellgiebel et al., 2005; Kalus et al., 2006; Sexton et al., 2010; Zhang et al., 2007).

In an attempt to better characterize the earliest white matter changes and their regional progression in the course of AD pathogenesis, recent DTI studies have more and more focused on asymptomatic at-risk populations, such as healthy subjects carrying AD-susceptibility genes, most notably the APOE4 allele (Bendlin et al., 2010; Kljajevic et al., 2014; Westlye, Reinvang, Rootwelt, & Espeseth, 2012; Xiong et al., 2011), but also other risk-associated candidate genes (Braskie et al., 2012, 2011; Forde et al., 2014; Liang, Li, et al., 2015; Lyall et al., 2014; Voineskos et al., 2011), or completely dominant familial AD mutations (Ringman et al., 2007; Ryan et al., 2013). Other recent studies examined white matter changes in asymptomatic individuals showing biomarker evidence of amyloid or tau pathology (Bendlin et al., 2012; Chao et al., 2013; Gold et al., 2014; Kantarci et al., 2014; Molinuevo et al., 2014; Racine et al., 2014; Stenset et al., 2011). These cross-sectional studies of at-risk populations are now increasingly being complemented by longitudinal follow-up studies that allow relating the detected imaging abnormalities to future clinical outcomes (Douaud et al., 2013; Fletcher et al., 2013; Mielke et al., 2012; Teipel, Meindl, et al., 2010; Zhuang et al., 2012). Together the

findings converge on a pattern of microstructural white matter changes in AD that begin and are most severe in limbic tracts, including the fornix, uncinate fasciculus, and posterior and parahippocampal fibers of the cingulum, and sequentially extend to include more lateral temporoparietal association fibers, commissural fibers of the splenium, and finally long-ranging association tracts involving the frontal white matter. Importantly, first microstructural alterations of the limbic tracts were already detectable in presymptomatic subjects, years before they developed cognitive deficits and at a time the macrostructural gray matter volume was still widely preserved (Fletcher et al., 2013; Ringman et al., 2007; Zhuang et al., 2012).

In accordance with models of the representation of cognitive function across neuronal networks in the human brain, the clinical consequences of microstructural white matter changes were found to depend on the specific white matter tracts affected. Thus, disruptions of limbic fiber tracts, most notably the fornix and the parahippocampal white matter, show associations with impaired episodic memory function (Fellgiebel et al., 2008; Huang & Auchus, 2007; Sexton et al., 2010), whereas executive function deficits appear to be more closely associated with fiber disruptions in long-ranging association tracts connected to the frontal lobe (Chen et al., 2009; Grambaite et al., 2011; Huang & Auchus, 2007). Of interest, memory performance in healthy elderly subjects was found to depend primarily on fornix integrity, whereas memory performance in MCI subjects showed greater dependence on parahippocampal white matter integrity (Metzler-Baddeley et al., 2012). This cognitive realignment from the more severely damaged fornix to the parahippocampal white matter in MCI was found to be beneficial for residual memory function in this condition and depended on a relatively spared structure of the basal forebrain cholinergic system, thought to be implicated in plastic brain responses (Ray et al., 2015).

While most studies focused on decreases in FA or increases in MD as scalar diffusion markers of microstructural white matter damage, simultaneous assessment of the full range of tensor-derived diffusion indices, including FA and MD, but also axial (aD) and radial (rD) diffusivities, and the MO, may provide more detailed information about the specifics of white matter degeneration in AD. Thus, in experimental studies on animal models increases in rD have been specifically associated with myelin degeneration, whereas changes in aD were more reflective of direct axonal damage (Song et al., 2003). In AD, the type of microstructural changes as reflected by the distinct diffusivity indices was found to differ between limbic, commissural, and association fiber tracts, indicating differing processes of tissue disruption among fiber populations (Huang et al., 2012). In general, increases in absolute diffusivities (i.e., MD, aD, and rD) were found to be more sensitive markers of AD-related white matter changes than decreases in FA, particularly in early and prodromal stages of the disease (Acosta-Cabronero, Williams, Pengas, & Nestor, 2010; Bosch et al., 2012). The rather counterintuitive observation of relatively increased FA

values along cortico-fugal and cortico-petal fiber tracts in AD and MCI (Douaud et al., 2011) may likely be explained by the loss of intracortically projecting crossing fiber tracts, and hence a more linear shape of the resulting diffusion tensor, as has been illustrated by a parallel increase of FA and MO in motor related tracts (Douaud et al., 2011; Teipel, Grothe, et al., 2014).

In addition to the regional analysis of scalar diffusion indices, complementary information on structural network organization can be obtained from the graph theoretical analysis of individual whole-brain connectivity networks derived from tractography-based reconstructions. In AD dementia, structural connectivity networks exhibit altered topological network metrics, such as increased shortest path lengths, decreased local and global efficiency, and decreased number of rich-club hub nodes (Daianu et al., 2013, 2015; Lo et al., 2010; Shao et al., 2012). These topological network changes were also shown to account for core memory and executive function deficits (Reijmer et al., 2013), and were already detectable in cognitively normal individuals with high amyloid burden (Fischer, Wolf, Scheurich, & Fellgiebel, 2015) and asymptomatic APOE4 carriers (Brown et al., 2011). However, current DTI-based fiber tracking algorithms are limited in their ability to resolve crossing and touching fiber bundles, which are highly prevalent fiber configurations in the human white matter (Jeurissen, Leemans, Tournier, Jones, & Sijbers, 2013). Recently developed model free reconstruction techniques based on high angular resolution diffusion data or diffusion spectrum imaging allow a more accurate reconstruction of crossing fiber tracts (Dell'Acqua & Catani, 2012; Wedeen et al., 2008), and may be used in the future to study age- and AD-related structural connectivity changes in greater detail (Reijmer et al., 2012; Teipel, Lerche, et al., 2014).

### Multimodal Imaging of Structural and Functional Connectivity Changes

Multimodal brain connectome approaches using both rs-fMRI and DTI could provide exciting new insights on structure-function relationships and how these are affected by disease. In health, the presence of a direct fiber connection is almost always correlated with functional connectivity in the corresponding brain regions (Damoiseaux & Greicius, 2009). However, the presence of functional connectivity between distinct brain regions is not necessarily suggesting the presence of a direct fiber connection, and the dependence on direct structural connections between network nodes varies among the different large-scale functional networks (Horn, Ostwald, Reisert, & Blankenburg, 2014). Table 1 lists key studies on combined fMRI and DTI in AD. Within the DMN it has been found that functional connectivity strength is largely predefined by the structural integrity of fiber tracts connecting the key nodes of this network, that is, the dorsal cingulum bundle connecting medial frontal and parietal nodes, and the ventral/parahippocampal cingulum connecting the posterior cingulate with the medial temporal lobe

(Greicius, Supekar, Menon, & Dougherty, 2009; Teipel, Bodke, et al., 2010; van den Heuvel, Mandl, Luigjes, & Hulshoff Pol, 2008). Accordingly, the functional disconnection of the DMN in MCI and AD is paralleled by a declining integrity of these underlying fiber tracts (Hahn et al., 2013; Soldner et al., 2012; Weiler et al., 2014). Similarly, working memory related network breakdown occurred along structurally defined networks when evaluated using task fMRI and DTI in healthy aging and MCI individuals (Teipel et al., 2015). Further evidence for a close relation between white matter degeneration and cortical dysfunction in aging and AD comes also from studies showing distinct associations between decreasing fiber integrity and declining regional hypometabolism in connected cortical areas (Bozoki, Korolev, Davis, Hoisington, & Berger, 2012; Cross et al., 2013; Glodzik et al., 2014; Kuczynski et al., 2010; Villain et al., 2010). Of interest, a recent multimodal MRI study found that integrity of the fornix was positively correlated with hippocampal-thalamic functional connectivity strength in normally aging subjects, but not in subjects with MCI, indicating that pathologic aging processes may alter the relationship between functional and structural connectivity characteristics within specific brain systems (Kehoe et al., 2015).

Finally, combined assessment of structural and functional abnormalities in asymptomatic young adult and middle-aged APOE4 carriers indicated that abnormalities in functional network communication may precede the breakdown of structural white matter connections in the pathogenesis of AD (Matura et al., 2014; Patel et al., 2013). However, other studies in asymptomatic APOE4 carriers have found parallel decreases in functional and structural connectivity (Heise et al., 2014) or even more pronounced structural network changes (Chen et al., 2014). Longitudinal studies using multimodal imaging assessments are needed to provide more detail on the specific sequence of structural and functional connectivity alterations in the course from presymptomatic to clinically manifest AD.

### **Multimodal Imaging of Regional Distribution and Progression Patterns of Pathologic Alterations on the Basis of the Brain's Connectivity Architecture: MRI, fMRI, and PET**

Besides its utility in studying functional and structural connectivity alterations in the course of normal and pathological aging, connectivity information from rs-fMRI and DTI may also be used to study the underlying mechanism of the distinct regional distribution and progression patterns of pathologic alterations in AD and other neurodegenerative dementias. Thus, different neurodegenerative dementia forms, such as AD, frontotemporal dementia, or semantic dementia, are not only characterized by distinct clinical presentations, but also by different patterns of regional brain atrophy, which show only partial overlap or no overlap at all between dementia syndromes in the early clinical stages. Using functional connectivity information from healthy

individuals, it could be demonstrated that the specific atrophy patterns observed in distinct neurodegenerative diseases resemble specific functional connectivity networks in the human brain, which largely correspond to the respective clinical presentation (Seeley et al., 2009; Zhou et al., 2012). Intriguingly, one recent study assessed functional connectivity patterns of the most atrophic regions in three distinct clinical variants of AD, namely early-onset AD, logopenic aphasia, and posterior cortical atrophy. In accordance with the syndrome-specific clinical presentations, they found that the functional connectivity pattern of the most atrophic region in early-onset AD resembled anterior salience and right executive-control networks, in logopenic aphasia it resembled the language network, and the functional connectivity pattern of the most atrophic region in posterior cortical atrophy corresponded to the higher visual network. These findings suggest that, although degeneration in AD dementia generally targets the DMN, deviations from the typical regional atrophy pattern in the form of syndrome-specific neurodegenerative variants are driven by the involvement of specific networks outside the DMN (Lehmann et al., 2013).

Information about the functional and structural connectivity architecture of the healthy human brain has also been used to construct predictive models of the regional distribution of pathologic changes in AD and other neurodegenerative dementias. Table 1 lists key studies on fMRI and DTI together with molecular imaging modalities. A region's total amount of functional connections with other regions in the healthy brain (i.e., its "functional hub" character) was shown to be predictive of the regional amount of amyloid accumulation in AD as measured with amyloid-sensitive PET imaging (Buckner et al., 2009; Myers et al., 2014). Moreover, an "epidemic spreading model" that considered axonal propagation of amyloid proteins along the healthy structural connectome in combination with regional clearance mechanisms was able to explain approximately 50% of the variance in real amyloid deposition patterns as observed by amyloid-sensitive PET (Iturria-Medina, Sotero, Toussaint, & Evans, 2014). Thus, this model strongly supports the hypothesis that regional amyloid deposition likelihood is explained to a large extent by the effective (i.e., connectional) anatomical distance from specific outbreak regions estimated to lie in the anterior and posterior cingulate cortex. Similar approaches have also been used to successfully predict regional atrophy severity and progression of atrophy based on structural (Crossley et al., 2014; Raj et al., 2012, 2015) and functional (Zhou et al., 2012) connectomic brain features, such as a region's total connectivity in the healthy brain or the connectional (rather than Euclidean) distance of this region to the site where atrophy first manifests.

These data provide first evidence in humans for hypotheses on molecular disease mechanisms derived from preclinical studies, including increased vulnerability of highly connected network hubs due to increased amyloid accumulation and oxidative stress (Cirrito et al., 2005; Spires-Jones & Hyman, 2014), or prion-like spread of pathogenic protein



**Table 1.** Multimodal imaging studies relevant for AD

Studies	Modalities	Main findings	Comments
<b>DTI+ (fMRI/MRI)</b>			
(Dyrba, Grothe, et al., 2015)	DTI, rsfMRI, anatomical MRI	Group separation in AD dementia ( $n = 28$ ) vs. controls ( $n = 25$ ) structural MRI > DTI > rsfMRI using multiple kernel SVM.	Number of subjects was low, relative novelty was multimodal machine learning approach. Strict cross-validation.
(Kehoe et al., 2015)	DTI, rsfMRI	Association of functional connectivity between hippocampus and thalamus seeds and linear diffusion coefficient of fornix tract was significantly positive in 22 healthy controls, but was not significantly different from zero in 19 MCI individuals.	Several diffusion parameters were assessed, but only effects of one of these was reported as significant.
(Balachandar et al., 2015)	DTI, rsfMRI	15 AD patients showed decreased functional connectivity within the DMN, and significantly increased functional connectivity in the executive network compared with 15 healthy controls, but no alterations in diffusion markers in any region.	No direct comparison between functional and structural connectivity changes. Lack of FA changes in AD patients is not consistent with the majority of previous findings.
(Liang, Chen, et al., 2015)	DTI, rsfMRI	In 24 MCI individuals, decreased FA of ventral cingulum was associated with decreased functional connectivity between ventral and dorsal anterior cingulum.	Hypothesis driven approach for assessment of anterior cingulum connectivity, which is functionally connected with the salience network.
(Dyrba, Chen, et al., 2015)	DTI, anatomical MRI	DTI was superior to anatomical MRI to predict amyloid positivity in MCI ( $n = 70$ MCI, 25 controls) using SVM.	Medium number of subjects in a multicentre DTI dataset. Strict cross-validation.
(Ray et al., 2015)	DTI, anatomical MRI	Memory performance depended primarily on fornix integrity in healthy elderly subjects ( $n = 20$ ) and on parahippocampal white matter integrity in MCI ( $n = 25$ ). This beneficial realignment in MCI depended on cholinergic basal forebrain integrity.	Potential method to probe plastic brain responses in neurodegenerative diseases and their relation to cholinergic system integrity. Only indirect volumetric marker of cholinergic system integrity was used.
(Jacobs et al., 2015)	DTI, task fMRI	18 MCI individuals showed decreased deactivation in areas with decreased diffusion, and increased activation in areas with increased diffusion during object recognition compared to 18 healthy controls.	Functional activation pattern was used to search for white matter regional FA changes. No assessment of shape of diffusion tensor in areas with FA increases in MCI.
(Teipel et al., 2015)	DTI, task fMRI	12 MCI individuals showed decreased antero-posterior functional and structural connectivity during working memory performance compared with 12 controls using three way joint independent component analysis.	Assessing FA and mode of anisotropy as measures of fiber directionality and shape of the diffusion tensor. Data driven approach without cross-validation, limiting the generalizability of the findings.
(Vidal-Pineiro et al., 2014)	DTI, rsfMRI, anatomical MRI, perfusion MRI (ASL)	Functional disconnection between anterior and posterior DMN nodes in healthy aging ( $n = 116$ elders) correlated with atrophy in DMN areas and the cingulum bundle, but not with cerebral blood flow.	Comprehensive multimodal approach to study brain wide correlates of antero-posterior DMN disconnection as a sensitive measure of brain aging. Associations were not controlled for age as a possible indirect driver of the correlations.
(Salami, Pudas, & Nyberg, 2014)	DTI, rsfMRI, task fMRI	Age-related increases in intra-hippocampal functional connectivity were associated with declining memory function, as well as structural and functional cortical disconnection of the hippocampal system.	Very large sample of healthy subjects spanning the whole adult age range ( $n = 339$ ; 25–80 y). Evidence for a malign nature of age-related hippocampal hyperconnectivity, probably related to a disinhibition effect.

**Table 1:** (Continued)

Studies	Modalities	Main findings	Comments
(Hahn et al., 2013)	DTI, rsfMRI	23 AD dementia patients, 28 MCI individuals and 26 healthy controls tractography originated from seed points from 8 intrinsic connectivity networks with nodes derived from the rsfMRI data. Edge distributions for the whole graph and for selected networks (i.e., default mode and attention network) revealed progressively impaired structural connectivity in patients.	Pattern of structural connectivity was driven by functional connectivity pattern, but no direct comparison between both measures.
(Wee et al., 2012)	DTI, rsfMRI	Group separation of 10 MCI individuals from 17 controls based on combined DTI and rsfMRI using multiple kernel SVM.	Strict cross-validation, the very low number of subjects limits the generalizability of the findings.
(Teipel, Meindl, et al., 2011)	DTI, anatomical MRI	In separate analyses on 21 AD patients, 16 MCI individuals and 20 controls, only in the AD group atrophy of cholinergic basal forebrain nuclei was associated with reduced FA in intracortical projecting fiber tracts.	Potential approach to explore cholinergic fiber tracts in the human brain in vivo.
(Teipel, Bokde, et al., 2010)	DTI, rsfMRI	Positive association between functional and structural connectivity of the default mode network in 20 healthy older controls using joint independent component analysis.	Data driven approach without cross-validation, limiting the generalizability of the findings.
(Greicius et al., 2009)	DTI, rsfMRI	Rs-fMRI derived DMN nodes served as seeds for fiber tractography and led to stable fiber tract estimates between these nodes in 23 healthy young controls.	Widely descriptive approach providing no statistical inference on associations between resting state functional connectivity and fiber tract integrity between DMN nodes.
(van den Heuvel et al., 2008)	DTI, rsfMRI	Positive association between functional and structural connectivity of the cingulum tract in 45 healthy young controls, using partial correlation coefficients between nodal time series and mean tract-based FA.	Hypothesis driven approach; nodes of connectivity maps were determined from the group data, limiting the generalizability of the findings.
<b>DTI + (Amyloid-PET/FDG-PET)</b>			
(Kuczynski et al., 2010)	DTI, FDG-PET	In 16 individuals ranging from cognitively healthy to mild dementia regional FA reductions were associated with voxel-wise reductions of cortical metabolism without regional preference.	Effects were controlled for MMSE score, reducing the confounding effect of overall cognitive decline on associations. Number of subjects too low to assess the specificity of these effects.
(Yakushev et al., 2011)	DTI, FDG-PET	21 AD dementia patients exhibited significant associations between hippocampus mean diffusivity and metabolism in hippocampus, parahippocampus and posterior cingulate gyrus.	Data support the idea that disconnection from downstream areas contributes to posterior cingulate hypometabolism in AD.
(Bozoki et al., 2012)	DTI, FDG-PET	Posterior cingulate metabolism was associated with cingulate bundle FA in combined group of 23 MCI individuals and 21 AD patients.	Effect only significant within combined AD-MCI group, raising the question of overall disease severity as confound.
(Cross et al., 2013)	DTI, FDG-PET	Olfactory tract FA was significantly correlated with FDG-PET signal in olfactory processing structures and beyond when combining the data of 12 MCI individuals and 23 healthy controls.	Effect only significant within combined MCI-control group, raising the question of global cognitive status as confound.

**Table 1:** (Continued)

Studies	Modalities	Main findings	Comments
(Chetelat et al., 2013)	DTI, rsfMRI, FDG-PET	Metabolism decline in healthy older ( $n = 57$ ) compared to young adults ( $n = 40$ ) predominated in the left inferior frontal junction and was associated with disruption of fronto-temporo-occipital fibers, but not with functional connectivity.	Insights into the association between age-related metabolism and connectivity changes. Association with connectivity only assessed for a priori seed region of highest metabolic decline.
(Glodzik et al., 2014)	DTI, Amyloid-PET, FDG-PET, T2-MRI	In 72 healthy elderly, white matter hyperintensities on T2-MRI were related to decreased amyloid load and glucose metabolism in gray matter regions that are structurally connected with the white matter lesion.	Human structural connectome informs the “change in connectivity” score: defined for each GM region as the percentage of fiber tracts connecting to that region that pass through the white matter lesion.
(Kantarci et al., 2014)	DTI, Amyloid-PET, FDG-PET	Fiber tract integrity was assessed in 570 cognitively normal subjects and 131 MCI individuals stratified by amyloid load and neurodegeneration status. FA of the fornix body decreased with neurodegeneration and was significantly associated with cognitive performance.	Loss of white matter integrity was more associated with gray matter neurodegeneration modulated by amyloid load. Amyloid biomarker positivity with absence of gray matter neurodegeneration or cognitive impairment showed no effect on whole brain FA.
(Racine et al., 2014)	DTI, Amyloid-PET	FA was associated with whole brain amyloid load in long association fibers and intracortical projecting fibers in 139 cognitively healthy subjects.	No group differences were found for axial and radial diffusivity. MD was associated with amyloid load in a right fronto-lateral cluster only.
(Iturria-Medina et al., 2014)	DTI, Amyloid-PET	A model for amyloid- $\beta$ spreading was developed using the information of structural connections derived from DTI. Main contributors for amyloid deposition were the parameters amyloid clearance deficiency and early amyloid onset age, both strongly associated with the disease severity and APOE e4 genotype.	The model identified the posterior and anterior cingulate cortices as starting location for amyloid deposition. Local amyloid deposition patterns of 733 subjects (AD dementia, MCI and controls) could be reproduced explaining approximately 50% of variance in regional amyloid load. Regions less connected were less likely to aggregate amyloid.
(Fischer et al., 2015)	DTI, Amyloid-PET	Graph-theoretical measures of structural connectivity revealed significant group differences between 31 amyloid-negative cognitively healthy subjects vs. 12 amyloid-positive cognitively healthy subjects.	No differences were found in hippocampal volume, whole-brain metabolism, or white matter FA and MD.
(Kim et al., 2015)	DTI, Amyloid-PET, T2-MRI	In 232 elderly patients with cognitive impairment, effects of small vessel disease on cortical atrophy and cognitive dysfunction were mediated by white matter network disruptions. Amyloid affected cortical atrophy and cognitive impairment without being mediated by white matter network integrity.	Amyloid and small vessel disease can give rise to brain atrophy and cognitive impairments in regionally and domain-specific patterns. Effect of small vessel disease, but not of amyloid, is mediated by white matter disruption.
(Raj et al., 2015)	DTI, FDG-PET, anatomical MRI	Progression patterns of atrophic and hypometabolic changes on longitudinal MRI/PET scans can be accurately predicted by considering inter-regional diffusion of pathology along the human white matter network.	Multimodal longitudinal imaging data of large sample ( $n = 418$ ), including CN, MCI and AD. White matter network based on advanced tractography (HARDI) in young adults ( $n = 73$ ). “Network diffusion model” is promising prognostic biomarker.
<b>fMRI + (Amyloid-PET/FDG-PET)</b>			
(Hedden et al., 2009)	rsfMRI, Amyloid-PET	Amyloid accumulation was correlated with DMN functional connectivity in clinically normal participants, controlled for age and structural atrophy.	Data suggest DMN network breakdown in the preclinical phase of AD. A priori DMN regions included posterior cingulate, lateral parietal and medial prefrontal cortices.

**Table 1:** (Continued)

Studies	Modalities	Main findings	Comments
(Sperling et al., 2009)	Task fMRI, Amyloid-PET	High levels of amyloid deposition were associated with aberrant DMN activity (reduced deactivation during successful memory encoding) in asymptomatic and minimally impaired older individuals.	High amyloid burden might be responsible for dysfunction of DMN supporting memory function. Controlled for age and performance but not atrophy.
(Sheline, Raichle, et al., 2010)	rsfMRI, Amyloid-PET	The PIB + cognitively normal group (and AD) had reduced functional connectivity of the precuneus to (para) hippocampus, anterior/dorsal cingulate, gyrus rectus, and superior precuneus compared to PIB- group.	No correlation between amyloid deposition in the precuneus and the precuneus-regional functional connectivity in the PIB + group.
(Mormino et al., 2011)	rsfMRI, Amyloid-PET	With increasing levels of global PIB uptake in healthy controls, functional connectivity decreases were identified in regions implicated in episodic memory processing while connectivity increases were detected in dorsal and anterior medial prefrontal and lateral temporal cortices.	Data suggest heightened vulnerability of episodic memory-related brain regions in AD whereas the observed increases in functional connectivity may reflect a compensatory response.
(Drzezga et al., 2011)	rsfMRI, Amyloid-PET, FDG-PET	PIB + MCI and asymptomatic participants had disruption of whole-brain connectivity in cortical hubs (posterior cingulate cortex/precuneus), overlapping with regional hypometabolism. Amyloid burden showed a negative correlation with whole-brain connectivity and metabolism.	Data suggest the possible high susceptibility of cortical hubs in terms of hypometabolism and disruption of connectivity in early AD and the possible link between synaptic dysfunction and functional disconnection. Results were controlled for structural atrophy.
(Oh & Jagust, 2013)	rsfMRI, task fMRI, Amyloid-PET	Amyloid-positive elders showed increased regional brain activation and decreased task-related connectivity during memory-related fMRI compared to amyloid-negative individuals. In the latter, increased task-related connectivity related to better memory performance.	Findings highlight the importance of network connectivity for compensating for reduced regional activity during successful memory encoding in aging, while in those with A $\beta$ this network compensation fails and is accompanied by inefficient regional hyperactivation.
(Lehmann et al., 2013)	rsfMRI, Amyloid-PET, FDG-PET	Hypometabolism patterns differed across AD variants, reflecting involvement of specific functional networks, whereas amyloid patterns were diffuse and similar across variants.	First study to compare in vivo glucose metabolism and amyloid deposition patterns across three clinical variants of AD, as well as their relation to functional brain networks.
(Arenaza-Urquijo et al., 2013)	rsfMRI, anatomical MRI, FDG-PET	In 36 healthy elders, higher levels of education were related to increased gray matter volume, glucose metabolism, and functional connectivity of the anterior cingulate cortex. Increased connectivity also correlated with better cognitive performance.	Structural, metabolic, and connectivity characteristics of the anterior cingulate cortex may underlie education-related reserve in healthy elders. Connectivity analysis was limited to anterior cingulate seed, based on volumetric and metabolic findings.
(Adriaanse et al., 2014)	rsfMRI, Amyloid-PET	No association between mean DMN functional connectivity and mean DMN amyloid binding was found across all subjects or within each group (AD, MCI, healthy elderly). Voxel-wise regression revealed that reduced functional connectivity in posterior cingulate cortex was associated with higher average DMN PIB binding across all subjects or PIB- subjects.	Data confirmed the DMN functional connectivity difference between PIB + and PIB- subjects. The lack of association between mean DMN functional connectivity and amyloid binding might be influenced by small sample size and averaging effect. The PIB- association points to the need of longitudinal studies.

**Table 1:** (Continued)

Studies	Modalities	Main findings	Comments
(Koch et al., 2014)	rsfMRI, task fMRI, Amyloid-PET	Reduced rsfMRI functional connectivity in the default mode and an attention network was associated with both regional amyloid plaque load and aberrant functional connectivity during attention task. It was further linked to impaired attention, suggesting reduced rsfMRI connectivity to link amyloid pathology and impaired cognition.	Changes in functional connectivity are regionally consistent across task and rest states, and linked with regional amyloid pathology.
(La Joie et al., 2014)	rsfMRI, FDG-PET, anatomical MRI	Atrophy in AD ( $n = 18$ ) and semantic dementia ( $n = 13$ ), overlaps in the hippocampus, but cortical hypometabolism in AD reflects more closely the functional connectivity pattern of posterior compared to anterior hippocampus seeds, and vice versa for SD.	Disease associated cognitive profiles seem to reflect the disruption of targeted networks more than atrophy in specific brain regions. Direct correlations between memory scores and disease-specific network disruptions within the patient groups were not assessed.
(Myers et al., 2014)	rsfMRI, Amyloid-PET	Patterns of resting-state functional connectivity are associated with patterns of amyloid plaque deposition in individual subjects.	Plaque deposition and functional connectivity of intrinsic networks interact.
(Klupp et al., 2015)	rsfMRI, Amyloid-PET, FDG-PET	Increasing hypometabolism in a region not affected by amyloid plaques is associated with increase of plaque load in a functionally connected area, suggesting an amyloid-facilitated spread of hypometabolism along functional networks.	Longitudinal study reinforcing the idea of distant functional responses to regional pathology mediated by brain connectivity. Presence of hypometabolic cortical regions not affected by plaque load in AD is at odds with some previous multitracer PET studies.
(Tahmasian et al., 2015)	rsfMRI, FDG-PET	The more functional connectivity between precuneus and hippocampus is impaired in AD patients, the higher hippocampus metabolism, suggesting disinhibition-like effects of hippocampus dysconnectivity.	Integrating cortical dysconnectivity and hippocampus local activity.
(Perrotin et al., 2015)	rsfMRI, FDG-PET	Anosognosia in AD patients ( $n = 23$ ) correlated with hypometabolism in orbitofrontal and posterior cingulate cortices, but also with reduced functional connectivity between these regions and the medial temporal lobe.	In addition to local functional deficits within self-related cortical midline regions, lack of awareness of memory deficits in AD may result from connectivity disruptions between self-related and memory-related brain networks.
<b>EEG + (MRI/DTI/PET)</b>			
(Teipel et al., 2009)	EEG, DTI	Reduced fiber tracts (MD) in anterior corpus callosum, frontal lobe white matter, thalamus, pons, and cerebellum were specifically associated with decrease of resting state frontal EEG (alpha) spectral coherence across 16 MCI individuals.	Peterson's clinical criteria for MCI diagnosis. Future studies should test if this effect is specific for MCI due to prodromal AD as revealed by amyloid biomarkers.
(Babiloni, Pievani, et al., 2009)	EEG, anatomical MRI	Higher load of white matter lesions along suspected cholinergic fiber tracts as determined from T2-weighted MRI scans was associated with reduced power of occipital, parietal, temporal, and limbic alpha 1 and theta frequency sources in 57 MCI individuals and 28 age-matched controls.	Interesting approach toward estimating impairment of cholinergic system integrity. Limited, however, by the limited evidence on localization of cholinergic fiber tracts in the cerebral white matter and the unclear specificity of the suspected locations for cholinergic fibers.
(Moretti, Paternico, Binetti, Zanetti, & Frisoni, 2012)	EEG, anatomical MRI	Association of a higher ratio of high to low alpha band power, and of higher ratio of theta to gamma band power in EEG with larger volumes of basal ganglia and thalamus in 74 MCI individuals.	Largely exploratory study that generated a hypothesis on the involvement of ventral striatum and pulvinar in different subtypes of MCI to be tested in subsequent studies. Very liberal level of significance.

**Table 1:** (Continued)

Studies	Modalities	Main findings	Comments
(Gonzalez-Escamilla, Atienza, Garcia-Solis, & Cantero, 2014)	EEG, anatomical MRI, FDG-PET	Association between the inter-hemispheric coupling of fronto-occipital regions in the alpha band of resting state EEG and gray matter volume of a thalamic region and between glucose consumption of right parietal lobe and alpha coupling of a right parietal region in 26 healthy older controls, but not in 29 MCI individuals.	Hypothesis driven study, connecting structural and metabolic integrity of potential EEG source regions with resting state EEG connectivity. Due to multiple testing these data need independent confirmation.
(Babiloni et al., 2015)	EEG, anatomical MRI	Atrophy in occipital gray matter was correlated to lower resting state EEG (alpha) occipital source activity across 45 healthy elderly, 100 MCI subjects and 90 patients with mild to moderate AD dementia.	Effect was significant within the combined AD-MCI-control group. Future studies should test if this effect is specific for AD neurodegenerative process or is merely related to global cognitive status
(Vecchio et al., 2015)	EEG, DTI	Reduced fiber tract integrity (FA) in posterior corpus callosum was significantly associated with resting state EEG source activity path length (decrease in alpha, increase in delta) across 9 healthy controls, 10 MCI individuals and 21 patients with mild to moderate AD dementia.	Effect was significant within the combined AD-MCI-control group, raising the question of global cognitive status as confound.
(Mander et al., 2015)	EEG, Amyloid-PET	In 26 healthy older controls, prefrontal cortical amyloid levels were associated with Non REM slow wave activities (0.6 – 1 Hz range) in EEG; this association mediated the association between amyloid levels and memory consolidation.	Hypothesis driven study, linking amyloid pathology with impaired hippocampus related memory consolidation <i>via</i> non-REM sleep disruption.

conformations (such as misfolded tau and amyloid proteins) along synaptic connections (Ahmed et al., 2014; Braak & Del Tredici, 2011; Nath et al., 2012).

### Multimodal Imaging of Brain Connectivity Measurements: Resting State EEG Rhythms, MRI, FDG-PET, and rs-fMRI Activity

It is well-known that low spatial resolution (centimeters) of the electroencephalography (EEG) techniques prevents a reliable and precise spatial estimation of the cortical sources and of the functional coupling of the EEG rhythms. On the other hand, rs-fMRI has an insufficient temporal resolution (seconds) for the study of the brain rhythms but a very high spatial resolution (millimeters). For this reason, the combination of the EEG and fMRI techniques has been performed in the past years to exploit the information contents of both methodologies. In this line, several multimodal studies have investigated the correlation between EEG rhythms in the resting state and low-frequency (approximately 0.1 Hz) fluctuations of the blood oxygenation signal (BOLD) in healthy subjects, showing that these fluctuations are temporally correlated across large-scale

distributed networks. In the resting-state eyes-closed condition, some studies have reported a positive correlation between the alpha power and the BOLD signal time series in the DMN (Mantini, Perrucci, Del Gratta, Romani, & Corbetta, 2007). Other evidence pointed to negative or mixed correlations (Goncalves et al., 2006; Laufs et al., 2003). In contrast, the alpha power was negatively correlated with activity in the Dorsal Attention Network (DAN) during the resting state condition (Laufs et al., 2003; Mantini et al., 2007; Sadaghiani et al., 2010). This is a set of control regions recruited during goal-driven behavior and perceptual selection (Corbetta & Shulman, 2002). The same negative correlation is observed between the alpha power and the ventral fronto-parietal cortical network (VAN; Corbetta & Shulman, 2002). Finally, the resting state alpha power also correlated to BOLD activity in a cingulo-insular-thalamic subnetwork of the VAN, the so-called Salience network (Goncalves et al., 2006; Sadaghiani et al., 2010).

Correlation between the resting state EEG power and the brain BOLD activity was not limited to alpha rhythms. It has been shown that the power of several EEG bands (i.e., delta, theta, alpha, beta, and gamma) correlated to fMRI time courses within the resting state networks identified by the use of independent component analysis (Mantini et al., 2007).

Analogously to the alpha power, the beta power was positively correlated to the BOLD activity in the DMN and self-referential networks, and was negatively correlated with the BOLD activity observed in the DAN (Mantini et al., 2007).

The correlation between the resting state alpha power and the BOLD signal in the DMN and attentional networks unveils the functional role of brain EEG oscillatory activity for the functional connectivity and neurotransmission within long-range cortical networks, as a possible basis of the regulation of spontaneous cortical arousal in wakefulness (Fox et al., 2005). Keeping in mind these data, we think that the study of correlation between the resting state alpha power and the BOLD signal in the DMN, DAN, and VAN represent a new avenue for a better understanding of the clinical neurophysiology of AD patients and for the definition and validation of instrumental markers for diagnostic, prognostic, and therapy monitoring purposes.

Another important avenue is the study of the relationship between resting state EEG rhythms and structural MRI markers of AD neurodegeneration co-registered in the same anatomical space. For this purpose, a promising approach is the estimation of the cortical sources of the resting state EEG rhythms by low-resolution brain electromagnetic tomography (LORETA) (<http://www.uzh.ch/keyinst/loreta.htm>). With this goal in mind, LORETA has been repeatedly used to study cortical sources of the resting state EEG rhythms in MCI and AD subjects (Figure 3). In these studies, occipital sources of the resting state alpha rhythms were the most promising EEG marker of prodromal AD in MCI subjects. Specifically, the magnitude of occipital sources of alpha rhythms was related to MRI markers including white matter lesions and atrophy of the hippocampal and global cortical gray matter in MCI and AD subjects (Babiloni et al., 2013, 2015; Babiloni, Ferri, et al., 2009; Babiloni et al., 2006; Babiloni, Frisoni, et al., 2009; Babiloni, Pievani, et al., 2009). Further evidence for a close relation between white matter degeneration and cortical dysfunction in aging and AD comes also from studies showing distinct associations between decreasing fiber integrity and declining trans-hemispheric coherence in resting-state EEG rhythms (Teipel et al., 2009). Key studies on EEG combined with other imaging modalities are listed in Table 1.

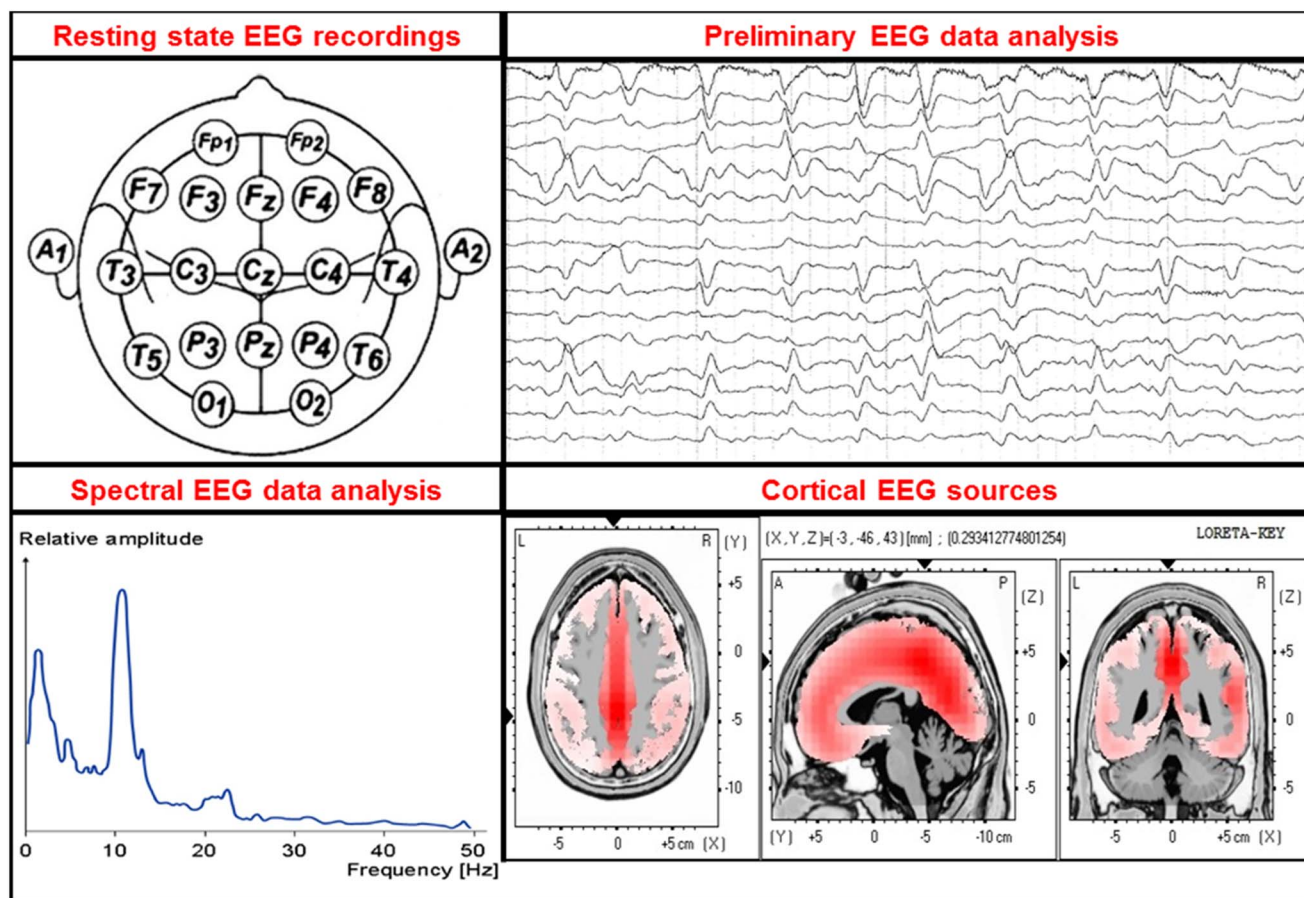
### **Contribution of Multimodal Imaging of Connectivity to Diagnostic Accuracy in AD: fMRI and DTI**

First studies used the critical role of intrinsic functional connectivity in AD's pathophysiology to apply rs-fMRI and functional connectivity in a diagnostic context. In general, due to low signal-to-noise ratio and its non-quantitative nature, fMRI signal (i.e., the BOLD signal) is highly problematic for individual reliable diagnostics (Fox & Greicius, 2010). Quantitative BOLD imaging and new data acquisition techniques producing massively more data in

comparable time to increase the power of data analysis (e.g., multi-band fMRI) might be helpful for future approaches (Smith et al., 2013). Furthermore, detection of individual intrinsic functional connectivity might be confounded by systematic center and scanner effects. For example Biswal and colleagues demonstrated significant center effects on ongoing BOLD activity and coherence in a huge sample of more than 1400 subjects collected across 35 centers (Biswal et al., 2010). The authors identified several factors which underlie such center effects and which have to be carefully controlled for across subject and center comparisons in a diagnostic context, including scanner type, sequence specifications, instructions to participants, and degree of participant's wakefulness. Finally, since intrinsic functional connectivity reflects individual wakefulness and ongoing cognitive activity such as mind wandering (Mason et al., 2007), intra-individual reliability and consistency of rs-fMRI-based diagnostic markers is a challenge (Damoiseaux et al., 2006; Patriat et al., 2013). Nevertheless, some studies demonstrated acceptable diagnostic potential of resting-state functional connectivity maps. For example, independently from each other Dyrba and colleagues and Wee and colleagues demonstrated that pattern classification of individual functional connectivity matrices of whole brain connectivity separates patients with AD or MCI from healthy controls with accuracy and specificity rates of approximately 70% (Dyrba, Grothe, Kirste, & Teipel, 2015; Wee et al., 2012). However, both studies also found that combining functional and structural connectivity (based on DTI data) substantially increases these rates above 90%, suggesting that multimodal connectivity measures might help in future diagnostic approaches.

The diagnostic use of DTI has been assessed in few studies so far. In monocenter studies, the separation of AD patients from healthy controls as well as MCI converters from healthy controls reached 80% to 90% accuracy using FA or MD maps in multivariate analysis based on principal component analysis (Friese et al., 2010), or support vector machine classification (Grana et al., 2011; O'Dwyer et al., 2012; Shao et al., 2012).

Regional diffusion measures of white matter integrity, most notably of the fornix, posterior cingulum, and parahippocampal white matter, have also shown promising accuracies between 77% and 95% for the prediction of conversion from MCI to AD dementia over clinical follow-up times of 2 to 3 years (Douaud et al., 2013; Mielke et al., 2012; Scola et al., 2010; Selnes et al., 2013). Preliminary findings further suggest that MD may be of higher predictive value compared to FA (Douaud et al., 2013), and that diffusion metrics may be generally better predictors of conversion than volumetric measurements on structural MRI (Fellgiebel et al., 2006; Scola et al., 2010), particularly for the prediction of future cognitive impairments in cognitively normal elderly (Fletcher et al., 2013; Zhuang et al., 2012). However, these first monocentric studies are generally limited by relatively small sample sizes, and diagnostic and prognostic findings within the highly controlled experimental conditions of these



**Fig. 3.** Overview of EEG spectral analysis. Several EEG techniques use brain electrical activity recorded during spontaneous fluctuations of vigilance in the resting state eyes closed condition to analyze functional synchronization and functional coupling of cortical neural activity in normal elderly subjects and patients with Alzheimer's disease (AD). On the whole, four main methodological stages can be recognized: (I) EEG recordings, typically from 19 scalp electrodes placed according to 10–20 system. This is the typical electrode montage used in clinical context. A low spatial sampling of EEG signals is allowed when the spatial frequency of EEG activity is relatively low as in the condition of resting state eyes-closed condition. (II) Preliminary EEG data analysis is a procedure aimed at selecting artifact-free EEG segments to be used for further analysis. In some cases, artifacts in the EEG segments can be corrected by mathematical procedures (e.g., correction of blinking artifacts). (III) Spectral EEG analysis is a procedure to compute EEG power spectra at scalp electrodes. This procedure aims at evaluating the general quality of EEG segments selected for the final analysis. In the case of healthy elderly subjects the EEG power spectra of posterior electrodes is dominated by a main peak of power density around 8–10 Hz. Power density at frequency lower than 4–6 Hz is typically higher in amplitude in the frontal than in the posterior electrodes. (IV) Cortical sources of resting state eyes closed EEG rhythms (free from artifacts) are typically estimated and compared among groups of healthy elderly subjects and patients with mild cognitive impairment and AD. For this purpose, a promising approach is the estimation of EEG cortical sources by low-resolution brain electromagnetic tomography (LORETA) (<http://www.uzh.ch/keyinst/loreta.htm>). These four basic stages are displayed in the figure.

studies, such as uniform DTI acquisition protocols and selected patient populations, will probably not translate seamlessly into the broader clinical context.

Only recently, multicenter acquisition and analysis of DTI data have begun to be explored in the framework of the European DTI Study on Dementia (EDSD) (Teipel, Reuter, et al., 2011). Using a physical and clinical phantom study, the EDSD showed an at least 50% increase of between scanner variability compared to anatomical MRI acquisitions (Teipel, Reuter, et al., 2011). Diagnostic accuracy for the comparison of AD *versus* controls yielded only 70% accuracy using univariate voxel-based meta-analysis (Teipel et al., 2012) or

posterior cingulate tractography (Fischer et al., 2012), but was increased to more than 80% accuracy using support vector machine analysis (Dyrba et al., 2013). The more relevant discrimination of prodromal MCI individuals from healthy controls and biomarker negative MCI individuals was more accurate using FA and MD measures from DTI in a machine learning framework than using gray matter and white matter volume, but yielded only approximately 70% accuracy (Dyrba, Barkhof, et al., 2015). The clinically most relevant question of predicting short to mid-term conversion within a group of MCI subjects recruited from multiple centers is presently being explored in the EDSD framework.



## SUMMARY

„Κάλχας Θεστορίδης οἰωνοπόλων ὄχ' ἄριστος, ὃς ἦδη τά τ' ἔόντα τά τ' ἐσσόμενα πρό τ' ἔόντα,”

“Calchas son of Thestor, far the best of bird-diviners, who knew the things that were, and that were to be, and that had been before,” Iliad, first book, lines 69/70

In the Iliad, the seer Calchas is the one who knows what is (the present), what will be (the future), and what was before him (the past). The previous sections have shown that what was characteristic for the most well-known seer of old days characterizes the potential utility of neuroimaging markers today. Measures of structural and functional connectivity help to resolve the three major challenges that are important for diagnosing and managing disease today as they were important for the Mycenaean Greeks when they sieged the city of Troy:

1. Looking into the past: structural and functional connectivity changes can explain how an endophenotype of molecular pathological changes, such as cortical amyloid and tau accumulation, has built up in an individual brain. The hub characteristics of a brain region and the degree of their functional connectivity and structural integration explain why certain brain networks are more vulnerable than others to brain diseases such as AD.
2. Understanding the presence: the presence of a certain disease stage, such as predementia or dementia AD, can diagnostically be detected using measures of structural and functional connectivity with reasonable accuracy in highly selected patient samples. In addition, recent evidence from multicenter data suggests that structural imaging methods may be robust diagnostic markers in the context of less controlled clinical samples as well.
3. Predicting the future: the most important task in clinical prognosis is to predict what will come next. This task has two aspects. First, for *clinical prediction*, measures of structural and functional connectivity need further exploration in large scale multicenter studies. Preliminary evidence from such studies suggests that measures of structural connectivity may be less accurate than classical measures of regional brain atrophy in predicting individual progression from MCI to AD dementia (Brüggen et al., in revision). Similar data from fMRI are still widely lacking. Resolving this question will provide guidance if these measures will usefully be used in the selection of individuals into clinical trials on prevention strategies geared toward a specific molecular pathogenic mechanism of disease or will become relevant for individual prognosis of disease progression in MCI individuals in tertiary and primary care settings.

Second, for *predicting the spread of molecular or functional lesions* of disease throughout the brain, the hub characteristics of a region could be used to predict the likelihood of a region to accumulate amyloid or tau pathology in the further course of the disease. Thus, the spread of a

molecular event, such as amyloid accumulation, can be predicted with moderate accuracy on a group level, but is still unresolved for an individual brain based on its network connectivity features. If this observation, however, is found to be robust in larger and more heterogeneous samples this would help to bridge the gap between molecular brain changes and clinical phenotype on the syndromal or even on the symptomatological level.

Several issues remain to be addressed: What will be the role of functional and structural brain connectivity in the light of international diagnostic guidelines? Summarizing, the current model of typical (i.e., most frequent) presentation of AD assumes that brain amyloidosis biomarkers (i.e., abnormal tracer retention on amyloid PET imaging and low A $\beta$ 42 concentration in the CSF) turn abnormal earliest, and are diagnostic biomarkers of AD when associated to episodic memory deficits as revealed by neuropsychological tests (Jack et al., 2010). During the evolution of the disease, this picture would be followed by cortical and hippocampal hypometabolism (FDG-PET), and finally by massive neuronal loss (i.e., brain atrophy on structural MRI). In this line, an International Working Group [IWG, (Dubois et al., 2014)] differentiated clinical phenotypes of AD and mixed AD, and proposed to distinguish clinical use of diagnostic (CSF and ligand PET of A $\beta$ 42 and tau brain accumulation) from disease tracking (MRI, FDG-PET) biomarkers. The *systematic collection and analysis of multicenter multimodal imaging data* including biomarkers of functional and structural cortical connectivity are an indispensable requirement for the future assessment of the diagnostic, prognostic, monitoring, and therapy response accuracy of these markers, both for clinical trials as well as health care applications, such as a radiological expert system. This also involves the analysis of the robustness or vulnerability of the markers to degrading image quality or varying numbers of available imaging modalities. Systematic studies need to explore the minimum image quality and data dimensions that still yield diagnostically useful information for an individual subject.

In addition, in a turn of the perspective, the functional and structural connectivity properties of an individual brain may help to predict what will be the likelihood for an individual at a given level of molecular brain lesions to remain cognitive stable over 2 to 3 years. The positive predictive value of a significant cortical amyloid accumulation in cognitively intact persons is approximately 25% for subsequent development of cognitive symptoms over 3 years (Villemagne et al., 2011); this points to mechanisms of cerebral reserve as an important factor for the individual resistance to brain lesions. As the associations between education and brain structural and functional connectivity suggest, the degree of structural and functional connectivity may be an important proxy of brain reserve. The assessment of these markers in combination with the detection of molecular lesions will help to stratify predementia and preclinical individuals into high risk *versus* low risk cohorts for the development of cognitive symptoms, an important requirement for future primary prevention clinical studies.

In summary, future work in clinical dementia research needs to close the growing gap between advances in imaging technology on the one hand, and stagnation in the development of efficient treatments. Particularly, the novel view on mechanisms of brain resilience in healthy and pathological aging may help to open new avenues for treatment evaluations beyond classical monocausal interventions against a single suspected key molecular event. The development of multimodal individualized treatments, including medication management, cholinergic treatment, as well as stage specific cognitive training and rehabilitation will contribute to mitigate the course of manifest and prodementia stages of AD. Individual primary prevention will also gain from the strengthening of individual reserve capacity where the intensity, frequency, and type of intervention may be selected based on the network properties of an individual brain as a proxy for the risk to yield or resist a given level of molecular lesions.

## ACKNOWLEDGMENTS

The present review was developed and granted in the framework of the following projects: “SinDem” (German Ministry of Research, BMBF, 16SV7091), “AgeGain” (German Ministry of Research, BMBF), “GRIDCORE” (Italian Ministry of Health, RF-2010-2319113) and “CONNAGE” (Italian Ministry of University and Technological Research, PRIN2010-2011, prot. 2010SH7H3F). There are no conflicts of interest related to this manuscript.

## REFERENCES

- Acosta-Cabronero, J., Williams, G.B., Pengas, G., & Nestor, P.J. (2010). Absolute diffusivities define the landscape of white matter degeneration in Alzheimer's disease. *Brain*, 133(Pt 2), 529–539.
- Adriaanse, S.M., Sanz-Arigita, E.J., Binnewijzend, M.A., Ossenkoppele, R., Tolboom, N., van Assema, D.M., ... van Berckel, B.N. (2014). Amyloid and its association with default network integrity in Alzheimer's disease. *Human Brain Mapping*, 35(3), 779–791.
- Agosta, F., Pievani, M., Geroldi, C., Copetti, M., Frisoni, G.B., & Filippi, M. (2012). Resting state fMRI in Alzheimer's disease: Beyond the default mode network. *Neurobiology of Aging*, 33(8), 1564–1578.
- Agosta, F., Rocca, M.A., Pagani, E., Absinta, M., Magnani, G., Marcone, A., ... Filippi, M. (2010). Sensorimotor network rewiring in mild cognitive impairment and Alzheimer's disease. *Human Brain Mapping*, 31(4), 515–525.
- Ahmed, Z., Cooper, J., Murray, T.K., Garn, K., McNaughton, E., Clarke, H., ... O'Neill, M.J. (2014). A novel in vivo model of tau propagation with rapid and progressive neurofibrillary tangle pathology: The pattern of spread is determined by connectivity, not proximity. *Acta Neuropathologica*, 127(5), 667–683.
- Arenaza-Urquijo, E.M., Landeau, B., La Joie, R., Mevel, K., Mezenge, F., Perrotin, A., ... Chetelat, G. (2013). Relationships between years of education and gray matter volume, metabolism and functional connectivity in healthy elders. *Neuroimage*, 83C, 450–457.
- Babiloni, C., Carducci, F., Lizio, R., Vecchio, F., Baglieri, A., Bernardini, S., ... Frisoni, G.B. (2013). Resting state cortical electroencephalographic rhythms are related to gray matter volume in subjects with mild cognitive impairment and Alzheimer's disease. *Human Brain Mapping*, 34(6), 1427–1446.
- Babiloni, C., Del Percio, C., Boccardi, M., Lizio, R., Lopez, S., Carducci, F., ... Frisoni, G.B. (2015). Occipital sources of resting-state alpha rhythms are related to local gray matter density in subjects with amnesic mild cognitive impairment and Alzheimer's disease. *Neurobiology of Aging*, 36(2), 556–570.
- Babiloni, C., Ferri, R., Binetti, G., Vecchio, F., Frisoni, G.B., Lanuzza, B., ... Rossini, P.M. (2009). Directionality of EEG synchronization in Alzheimer's disease subjects. *Neurobiology of Aging*, 30(1), 93–102.
- Babiloni, C., Frisoni, G., Steriade, M., Bresciani, L., Binetti, G., Del Percio, C., ... Rossini, P.M. (2006). Frontal white matter volume and delta EEG sources negatively correlate in awake subjects with mild cognitive impairment and Alzheimer's disease. *Clinical Neurophysiology*, 117(5), 1113–1129.
- Babiloni, C., Frisoni, G.B., Pievani, M., Vecchio, F., Lizio, R., Buttiglione, M., ... Rossini, P.M. (2009). Hippocampal volume and cortical sources of EEG alpha rhythms in mild cognitive impairment and Alzheimer disease. *Neuroimage*, 44(1), 123–135.
- Babiloni, C., Pievani, M., Vecchio, F., Geroldi, C., Eusebi, F., Fracassi, C., ... Frisoni, G.B. (2009). White-matter lesions along the cholinergic tracts are related to cortical sources of EEG rhythms in amnesic mild cognitive impairment. *Human Brain Mapping*, 30(5), 1431–1443.
- Bai, F., Liao, W., Yue, C., Pu, M., Shi, Y., Yu, H., ... Zhang, Z. (2014). Genetics pathway-based imaging approaches in Chinese Han population with Alzheimer's disease risk. *Brain Structure & Function*. [Epub ahead of print].
- Bai, F., Watson, D.R., Shi, Y., Wang, Y., Yue, C., Yuhuan, Teng, ... Zhang, Z. (2011). Specifically progressive deficits of brain functional marker in amnesic type mild cognitive impairment. *PLoS One*, 6(9), e24271.
- Bai, F., Watson, D.R., Yu, H., Shi, Y., Yuan, Y., & Zhang, Z. (2009). Abnormal resting-state functional connectivity of posterior cingulate cortex in amnesic type mild cognitive impairment. *Brain Research*, 1302, 167–174.
- Balachandar, R., John, J.P., Saini, J., Kumar, K.J., Joshi, H., Sadanand, S., ... Bharath, S. (2015). A study of structural and functional connectivity in early Alzheimer's disease using rest fMRI and diffusion tensor imaging. *International Journal of Geriatric Psychiatry*, 30(5), 497–504.
- Balthazar, M.L., Pereira, F.R., Lopes, T.M., da Silva, E.L., Coan, A.C., Campos, B.M., ... Cendes, F. (2013). Neuropsychiatric symptoms in Alzheimer's disease are related to functional connectivity alterations in the salience network. *Human Brain Mapping*.
- Basser, P.J., Mattiello, J., & LeBihan, D. (1994). MR diffusion tensor spectroscopy and imaging. *Biophysical Journal*, 66(1), 259–267.
- Beckmann, C.F., DeLuca, M., Devlin, J.T., & Smith, S.M. (2005). Investigations into resting-state connectivity using independent component analysis. *Philosophical Transactions of the Royal Society of London. Series B, Biological Sciences*, 360(1457), 1001–1013.
- Bendlin, B.B., Carlsson, C.M., Johnson, S.C., Zetterberg, H., Blennow, K., Willette, A.A., ... Sager, M.A. (2012). CSF T-Tau/Abeta42 predicts white matter microstructure in healthy adults at risk for Alzheimer's disease. *PLoS One*, 7(6), e37720.
- Bendlin, B.B., Ries, M.L., Canu, E., Sodhi, A., Lazar, M., Alexander, A.L., ... Johnson, S.C. (2010). White matter is

- altered with parental family history of Alzheimer's disease. *Alzheimers & Dementia*, 6(5), 394–403.
- Binnewijzend, M.A., Schoonheim, M.M., Sanz-Arigita, E., Wink, A.M., van der Flier, W.M., Tolboom, N., ... Barkhof, F. (2012). Resting-state fMRI changes in Alzheimer's disease and mild cognitive impairment. *Neurobiology of Aging*, 33(9), 2018–2028.
- Biswal, B., Yetkin, F.Z., Haughton, V.M., & Hyde, J.S. (1995). Functional connectivity in the motor cortex of resting human brain using echo-planar MRI. *Magnetic Resonance in Medicine*, 34(4), 537–541.
- Biswal, B.B., Mennes, M., Zuo, X.N., Gohel, S., Kelly, C., Smith, S.M., ... Milham, M.P. (2010). Toward discovery science of human brain function. *Proceedings of the National Academy of Sciences of the United States of America*, 107(10), 4734–4739.
- Bosch, B., Arenaza-Urquijo, E.M., Rami, L., Sala-Llonch, R., Junque, C., Sole-Padullés, C., ... Bartres-Faz, D. (2012). Multiple DTI index analysis in normal aging, amnesic MCI and AD. Relationship with neuropsychological performance. *Neurobiology of Aging*, 33(1), 61–74.
- Bozoki, A.C., Korolev, I.O., Davis, N.C., Hoisington, L.A., & Berger, K.L. (2012). Disruption of limbic white matter pathways in mild cognitive impairment and Alzheimer's disease: A DTI/FDG-PET study. *Human Brain Mapping*, 33(8), 1792–1802.
- Bozzali, M., Dowling, C., Serra, L., Spano, B., Torso, M., Marra, C., ... Cercignani, M. (2014). The impact of cognitive reserve on brain functional connectivity in Alzheimer's Disease. *Journal of Alzheimers Disease*, 44, 243–250.
- Bozzali, M., Falini, A., Franceschi, M., Cercignani, M., Zuffi, M., Scotti, G., ... Filippi, M. (2002). White matter damage in Alzheimer's disease assessed in vivo using diffusion tensor magnetic resonance imaging. *Journal of Neurology, Neurosurgery, and Psychiatry*, 72(6), 742–746.
- Bozzali, M., Franceschi, M., Falini, A., Pontesilli, S., Cercignani, M., Magnani, G., ... Filippi, M. (2001). Quantification of tissue damage in AD using diffusion tensor and magnetization transfer MRI. *Neurology*, 57(6), 1135–1137.
- Braak, H., & Del Tredici, K. (2011). Alzheimer's pathogenesis: Is there neuron-to-neuron propagation? *Acta Neuropathologica*, 121(5), 589–595.
- Braskie, M.N., Jahanshad, N., Stein, J.L., Barysheva, M., Johnson, K., McMahon, K.L., ... Thompson, P.M. (2012). Relationship of a variant in the NTRK1 gene to white matter microstructure in young adults. *The Journal of Neuroscience*, 32(17), 5964–5972.
- Braskie, M.N., Jahanshad, N., Stein, J.L., Barysheva, M., McMahon, K.L., de Zubicaray, G.I., ... Thompson, P.M. (2011). Common Alzheimer's disease risk variant within the CLU gene affects white matter microstructure in young adults. *The Journal of Neuroscience*, 31(18), 6764–6770.
- Brier, M.R., Thomas, J.B., Snyder, A.Z., Benzinger, T.L., Zhang, D., Raichle, M.E., ... Ances, B.M. (2012). Loss of intranetwork and internetwork resting state functional connections with Alzheimer's disease progression. *The Journal of Neuroscience*, 32(26), 8890–8899.
- Brown, J.A., Terashima, K.H., Burggren, A.C., Ercoli, L.M., Miller, K.J., Small, G.W., ... Bookheimer, S.Y. (2011). Brain network local interconnectivity loss in aging APOE-4 allele carriers. *Proceedings of the National Academy of Sciences of the United States of America*, 108(51), 20760–20765.
- Buckner, R.L., Andrews-Hanna, J.R., & Schacter, D.L. (2008). The brain's default network: Anatomy, function, and relevance to disease. *Annals of the New York Academy of Sciences*, 1124, 1–38.
- Buckner, R.L., Sepulcre, J., Talukdar, T., Krienen, F.M., Liu, H., Hedden, T., ... Johnson, K.A. (2009). Cortical hubs revealed by intrinsic functional connectivity: Mapping, assessment of stability, and relation to Alzheimer's disease. *The Journal of Neuroscience*, 29(6), 1860–1873.
- Buckner, R.L., Snyder, A.Z., Shannon, B.J., LaRossa, G., Sachs, R., Fotenos, A.F., ... Mintun, M.A. (2005). Molecular, structural, and functional characterization of Alzheimer's disease: Evidence for a relationship between default activity, amyloid, and memory. *The Journal of Neuroscience*, 25(34), 7709–7717.
- Bullmore, E., & Sporns, O. (2009). Complex brain networks: Graph theoretical analysis of structural and functional systems. *Nature Reviews Neuroscience*, 10(3), 186–198.
- Chao, L.L., Decarli, C., Kriger, S., Truran, D., Zhang, Y., Laxamana, J., ... Weiner, M.W. (2013). Associations between white matter hyperintensities and beta amyloid on integrity of projection, association, and limbic fiber tracts measured with diffusion tensor MRI. *PLoS One*, 8(6), e65175.
- Chen, T.F., Chen, Y.F., Cheng, T.W., Hua, M.S., Liu, H.M., & Chiu, M.J. (2009). Executive dysfunction and periventricular diffusion tensor changes in amnesic mild cognitive impairment and early Alzheimer's disease. *Human Brain Mapping*, 30(11), 3826–3836.
- Chen, Y., Chen, K., Zhang, J., Li, X., Shu, N., Wang, J., ... Reiman, E.M. (2014). Disrupted functional and structural networks in cognitively normal elderly subjects with the APOE varepsilon4 Allele. *Neuropsychopharmacology*, 40, 1181–1191.
- Chetelat, G., Desgranges, B., De La Sayette, V., Viader, F., Eustache, F., & Baron, J.C. (2002). Mapping gray matter loss with voxel-based morphometry in mild cognitive impairment. *Neuroreport*, 13(15), 1939–1943.
- Chetelat, G., Landeau, B., Salmon, E., Yakushev, I., Bahri, M.A., Mezenge, F., ... Fellgiebel, A. (2013). Relationships between brain metabolism decrease in normal aging and changes in structural and functional connectivity. *Neuroimage*, 76, 167–177.
- Choo, I.H., Lee, D.Y., Youn, J.C., Jhoo, J.H., Kim, K.W., Lee, D.S., ... Woo, J.I. (2007). Topographic patterns of brain functional impairment progression according to clinical severity staging in 116 Alzheimer disease patients: FDG-PET study. *Alzheimer Disease and Associated Disorders*, 21(2), 77–84.
- Cirrito, J.R., Kang, J.E., Lee, J., Stewart, F.R., Verges, D.K., Silverio, L.M., ... Holtzman, D.M. (2008). Endocytosis is required for synaptic activity-dependent release of amyloid-beta in vivo. *Neuron*, 58(1), 42–51.
- Cirrito, J.R., Yamada, K.A., Finn, M.B., Sloviter, R.S., Bales, K.R., May, P.C., ... Holtzman, D.M. (2005). Synaptic activity regulates interstitial fluid amyloid-beta levels in vivo. *Neuron*, 48(6), 913–922.
- Corbetta, M., & Shulman, G.L. (2002). Control of goal-directed and stimulus-driven attention in the brain. *Nature Reviews Neuroscience*, 3(3), 201–215.
- Cross, D.J., Anzai, Y., Petrie, E.C., Martin, N., Richards, T.L., Maravilla, K.R., ... Minoshima, S. (2013). Loss of olfactory tract integrity affects cortical metabolism in the brain and olfactory regions in aging and mild cognitive impairment. *Journal of Nuclear Medicine*, 54(8), 1278–1284.
- Crossley, N.A., Mechelli, A., Scott, J., Carletti, F., Fox, P.T., McGuire, P., ... Bullmore, E.T. (2014). The hubs of the human connectome are generally implicated in the anatomy of brain disorders. *Brain*, 137(Pt 8), 2382–2395.
- Crossley, N.A., Mechelli, A., Vertes, P.E., Winton-Brown, T.T., Patel, A.X., Ginestet, C.E., ... Bullmore, E.T. (2013). Cognitive

- relevance of the community structure of the human brain functional coactivation network. *Proceedings of the National Academy of Sciences of the United States of America*, 110(28), 11583–11588.
- Daianu, M., Dennis, E.L., Jahanshad, N., Nir, T.M., Toga, A.W., Jack, C.R., ... Thompson, P.M. (2013). Alzheimer's disease disrupts rich club organization in brain connectivity networks. *IEEE International Symposium on Biomedical Imaging, 2013*, 266–269.
- Daianu, M., Jahanshad, N., Nir, T.M., Jack, C.R., Weiner, M.W., Bernstein, M.A., ... Thompson, P.M. (2015). Rich club analysis in the Alzheimer's disease connectome reveals a relatively undisturbed structural core network. *Human Brain Mapping*, 36(8), 3087–3103.
- Damoiseaux, J.S., & Greicius, M.D. (2009). Greater than the sum of its parts: A review of studies combining structural connectivity and resting-state functional connectivity. *Brain Structure & Function*, 213(6), 525–533.
- Damoiseaux, J.S., Rombouts, S.A., Barkhof, F., Scheltens, P., Stam, C.J., Smith, S.M., ... Beckmann, C.F. (2006). Consistent resting-state networks across healthy subjects. *Proceedings of the National Academy of Sciences of the United States of America*, 103(37), 13848–13853.
- Damoiseaux, J.S., Seeley, W.W., Zhou, J., Shirer, W.R., Coppola, G., Karydas, A., ... Greicius, M.D. (2012). Gender modulates the APOE {varepsilon}4 effect in healthy older adults: Convergent evidence from functional brain connectivity and spinal fluid Tau levels. *The Journal of Neuroscience*, 32(24), 8254–8262.
- Daunizeau, J., David, O., & Stephan, K.E. (2011). Dynamic causal modelling: A critical review of the biophysical and statistical foundations. *Neuroimage*, 58(2), 312–322.
- Dauwels, J., Vialatte, F., Musha, T., & Cichocki, A. (2010). A comparative study of synchrony measures for the early diagnosis of Alzheimer's disease based on EEG. *Neuroimage*, 49(1), 668–693.
- Deco, G., & Corbetta, M. (2011). The dynamical balance of the brain at rest. *The Neuroscientist*, 17(1), 107–123.
- Dell'Acqua, F., & Catani, M. (2012). Structural human brain networks: Hot topics in diffusion tractography. *Current Opinion in Neurology*, 25(4), 375–383.
- Dennis, E.L., & Thompson, P.M. (2014). Functional brain connectivity using fMRI in aging and Alzheimer's disease. *Neuropsychology Review*, 24(1), 49–62.
- Doria, V., Beckmann, C.F., Arichi, T., Merchant, N., Groppo, M., Turkheimer, F.E., ... Edwards, A.D. (2010). Emergence of resting state networks in the preterm human brain. *Proceedings of the National Academy of Sciences of the United States of America*, 107(46), 20015–20020.
- Douaud, G., Jbabdi, S., Behrens, T.E., Menke, R.A., Gass, A., Monsch, A.U., ... Smith, S. (2011). DTI measures in crossing-fibre areas: Increased diffusion anisotropy reveals early white matter alteration in MCI and mild Alzheimer's disease. *Neuroimage*, 55(3), 880–890.
- Douaud, G., Menke, R.A., Gass, A., Monsch, A.U., Rao, A., Whitcher, B., ... Smith, S. (2013). Brain microstructure reveals early abnormalities more than two years prior to clinical progression from mild cognitive impairment to Alzheimer's disease. *The Journal of Neuroscience*, 33(5), 2147–2155.
- Drzezga, A., Becker, J.A., Van Dijk, K.R., Sreenivasan, A., Talukdar, T., Sullivan, C., ... Sperling, R.A. (2011). Neuronal dysfunction and disconnection of cortical hubs in non-demented subjects with elevated amyloid burden. *Brain*, 134(Pt 6), 1635–1646.
- Dubois, B., Feldman, H.H., Jacova, C., Hampel, H., Molinuevo, J.L., Blennow, K., ... Cummings, J.L. (2014). Advancing research diagnostic criteria for Alzheimer's disease: The IWG-2 criteria. *The Lancet. Neurology*, 13(6), 614–629.
- Dyrba, M., Barkhof, F., Fellgiebel, A., Filippi, M., Hausner, L., Hauenstein, K., ... Teipel, S.J. (2015). Predicting prodromal Alzheimer's disease in subjects with mild cognitive impairment using machine learning classification of multimodal multicenter diffusion-tensor and magnetic resonance imaging data. *J Neuroimaging*, 25, 738–747.
- Dyrba, M., Ewers, M., Wegrzyn, M., Kilimann, I., Plant, C., Oswald, A., ... Teipel, S.J. (2013). Robust automated detection of microstructural white matter degeneration in Alzheimer's disease using machine learning classification of multicenter DTI data. *PLoS One*, 8(5), e64925.
- Dyrba, M., Grothe, M., Kirste, T., & Teipel, S.J. (2015). Multimodal analysis of functional and structural disconnection in Alzheimer's disease using multiple kernel SVM. *Human Brain Mapping*, 36(6), 2118–2131.
- Dziewczapolski, G., Glogowski, C.M., Masliah, E., & Heinemann, S.F. (2009). Deletion of the alpha 7 nicotinic acetylcholine receptor gene improves cognitive deficits and synaptic pathology in a mouse model of Alzheimer's disease. *The Journal of Neuroscience*, 29(27), 8805–8815.
- Fellgiebel, A., Dellani, P.R., Greverus, D., Scheurich, A., Stoeter, P., & Muller, M.J. (2006). Predicting conversion to dementia in mild cognitive impairment by volumetric and diffusivity measurements of the hippocampus. *Psychiatry Research*, 146(3), 283–287.
- Fellgiebel, A., Muller, M.J., Wille, P., Dellani, P.R., Scheurich, A., Schmidt, L.G., ... Stoeter, P. (2005). Color-coded diffusion-tensor-imaging of posterior cingulate fiber tracts in mild cognitive impairment. *Neurobiology of Aging*, 26(8), 1193–1198.
- Fellgiebel, A., Schermuly, I., Gerhard, A., Keller, I., Albrecht, J., Weibrich, C., ... Stoeter, P. (2008). Functional relevant loss of long association fibre tracts integrity in early Alzheimer's disease. *Neuropsychologia*, 46(6), 1698–1706.
- Fischer, F.U., Scheurich, A., Wegrzyn, M., Schermuly, I., Bokde, A.L., Kloppel, S., ... Fellgiebel, A. (2012). Automated tractography of the cingulate bundle in Alzheimer's disease: A multicenter DTI study. *Journal of Magnetic Resonance Imaging*, 36, 84–91.
- Fischer, F.U., Wolf, D., Scheurich, A., & Fellgiebel, A. (2015). Altered whole-brain white matter networks in preclinical Alzheimer's disease. *Neuroimage: Clinical*, 8, 660–666.
- Fletcher, E., Raman, M., Huebner, P., Liu, A., Mungas, D., Carmichael, O., ... DeCarli, C. (2013). Loss of fornix white matter volume as a predictor of cognitive impairment in cognitively normal elderly individuals. *JAMA Neurology*, 70(11), 1389–1395.
- Forde, N.J., Ronan, L., Suckling, J., Scanlon, C., Neary, S., Holleran, L., ... Cannon, D.M. (2014). Structural neuroimaging correlates of allelic variation of the BDNF val66met polymorphism. *Neuroimage*, 90, 280–289.
- Fox, M.D., & Greicius, M. (2010). Clinical applications of resting state functional connectivity. *Frontiers in Systems Neuroscience*, 4, 19.
- Fox, M.D., & Raichle, M.E. (2007). Spontaneous fluctuations in brain activity observed with functional magnetic resonance imaging. *Nature Reviews. Neuroscience*, 8(9), 700–711.
- Fox, M.D., Snyder, A.Z., Vincent, J.L., Corbetta, M., Van Essen, D.C., & Raichle, M.E. (2005). The human brain is intrinsically organized into dynamic, anticorrelated functional networks. *Proceedings of*

- the National Academy of Sciences of the United States of America, 102(27), 9673–9678.
- Friese, U., Meindl, T., Herpertz, S.C., Reiser, M.F., Hampel, H., & Teipel, S.J. (2010). Diagnostic utility of novel MRI-based biomarkers for Alzheimer's disease: Diffusion tensor imaging and deformation-based morphometry. *Journal of Alzheimer's Disease*, 20(2), 477–490.
- Friston, K.J., Harrison, L., & Penny, W. (2003). Dynamic causal modelling. *Neuroimage*, 19(4), 1273–1302.
- Gili, T., Cercignani, M., Serra, L., Perri, R., Giove, F., Maraviglia, B., ... Bozzali, M. (2011). Regional brain atrophy and functional disconnection across Alzheimer's disease evolution. *Journal of Neurology, Neurosurgery, and Psychiatry*, 82(1), 58–66.
- Glodzik, L., Kuceyeski, A., Rusinek, H., Tsui, W., Mosconi, L., Li, Y., ... de Leon, M.J. (2014). Reduced glucose uptake and Abeta in brain regions with hyperintensities in connected white matter. *Neuroimage*, 100, 684–691.
- Goebel, R., Roebroeck, A., Kim, D.-S., & Formisano, E. (2003). Investigating directed cortical interactions in time-resolved fMRI data using vector autoregressive modeling and Granger causality mapping. *Magnetic Resonance Imaging*, 21(10), 1251–1261.
- Gold, B.T., Zhu, Z., Brown, C.A., Andersen, A.H., LaDu, M.J., Tai, L., ... Smith, C.D. (2014). White matter integrity is associated with cerebrospinal fluid markers of Alzheimer's disease in normal adults. *Neurobiology of Aging*, 35(10), 2263–2271.
- Goncalves, S.I., de Munck, J.C., Pouwels, P.J., Schoonhoven, R., Kuijter, J.P., Maurits, N.M., ... Lopes da Silva, F.H. (2006). Correlating the alpha rhythm to BOLD using simultaneous EEG/fMRI: Inter-subject variability. *Neuroimage*, 30(1), 203–213.
- Gonzalez-Escamilla, G., Aizenstein, M., Garcia-Solis, D., & Cantero, J.L. (2014). Cerebral and blood correlates of reduced functional connectivity in mild cognitive impairment. *Brain Structure & Function*. [Epub ahead of print].
- Grambaite, R., Selnes, P., Reinvang, I., Aarsland, D., Hessen, E., Gjerstad, L., ... Fladby, T. (2011). Executive dysfunction in mild cognitive impairment is associated with changes in frontal and cingulate white matter tracts. *Journal of Alzheimer's Disease*, 27(2), 453–462.
- Grana, M., Termenon, M., Savio, A., Gonzalez-Pinto, A., Echeveste, J., Perez, J.M., ... Besga, A. (2011). Computer aided diagnosis system for Alzheimer disease using brain diffusion tensor imaging features selected by Pearson's correlation. *Neurosci Letters*, 502(3), 225–229.
- Granger, C.W.J. (1969). Investigating causal relations by econometric models and cross-spectral methods. *Econometrica*, 37(3), 424.
- Greicius, M.D., Krasnow, B., Reiss, A.L., & Menon, V. (2003). Functional connectivity in the resting brain: A network analysis of the default mode hypothesis. *Proceedings of the National Academy of Sciences of the United States of America*, 100(1), 253–258.
- Greicius, M.D., & Menon, V. (2004). Default-mode activity during a passive sensory task: Uncoupled from deactivation but impacting activation. *Journal of Cognitive Neuroscience*, 16(9), 1484–1492.
- Greicius, M.D., Srivastava, G., Reiss, A.L., & Menon, V. (2004). Default-mode network activity distinguishes Alzheimer's disease from healthy aging: Evidence from functional MRI. *Proceedings of the National Academy of Sciences of the United States of America*, 101(13), 4637–4642.
- Greicius, M.D., Supekar, K., Menon, V., & Dougherty, R.F. (2009). Resting-state functional connectivity reflects structural connectivity in the default mode network. *Cerebral Cortex*, 19(1), 72–78.
- Hahn, K., Myers, N., Prigarin, S., Rodenacker, K., Kurz, A., Forstl, H., ... Sorg, C. (2013). Selectively and progressively disrupted structural connectivity of functional brain networks in Alzheimer's disease - revealed by a novel framework to analyze edge distributions of networks detecting disruptions with strong statistical evidence. *Neuroimage*, 81, 96–109.
- Hedden, T., Van Dijk, K.R., Becker, J.A., Mehta, A., Sperling, R.A., Johnson, K.A., ... Buckner, R.L. (2009). Disruption of functional connectivity in clinically normal older adults harboring amyloid burden. *The Journal of Neuroscience*, 29(40), 12686–12694.
- Heise, V., Filippini, N., Trachtenberg, A.J., Suri, S., Ebmeier, K.P., & Mackay, C.E. (2014). Apolipoprotein E genotype, gender and age modulate connectivity of the hippocampus in healthy adults. *Neuroimage*, 98, 23–30.
- Horn, A., Ostwald, D., Reisert, M., & Blankenburg, F. (2014). The structural-functional connectome and the default mode network of the human brain. *Neuroimage*, 102(Pt 1), 142–151.
- Hsieh, H.J., Kao, P.F., Huang, H.L., & Chou, Y.H. (2010). Cardiac stab injury: A fixed perfusion defect on Tc-99m sestamibi SPECT. *Clinical Nuclear Medicine*, 35(2), 121–122.
- Huang, H., Fan, X., Weiner, M., Martin-Cook, K., Xiao, G., Davis, J., ... Diaz-Arrastia, R. (2012). Distinctive disruption patterns of white matter tracts in Alzheimer's disease with full diffusion tensor characterization. *Neurobiology of Aging*, 33(9), 2029–2045.
- Huang, J., & Auchs, A.P. (2007). Diffusion tensor imaging of normal appearing white matter and its correlation with cognitive functioning in mild cognitive impairment and Alzheimer's disease. *Annals of the New York Academy of Sciences*, 1097, 259–264.
- Huang, J., Friedland, R.P., & Auchs, A.P. (2007). Diffusion tensor imaging of normal-appearing white matter in mild cognitive impairment and early Alzheimer disease: Preliminary evidence of axonal degeneration in the temporal lobe. *AJNR American Journal of Neuroradiology*, 28(10), 1943–1948.
- Iturria-Medina, Y., Sotero, R.C., Toussaint, P.J., & Evans, A.C. (2014). Epidemic spreading model to characterize misfolded proteins propagation in aging and associated neurodegenerative disorders. *PLoS Computational Biology*, 10(11), e1003956.
- Jack, C.R. Jr., Knopman, D.S., Jagust, W.J., Shaw, L.M., Aisen, P.S., Weiner, M.W., ... Trojanowski, J.Q. (2010). Hypothetical model of dynamic biomarkers of the Alzheimer's pathological cascade. *The Lancet. Neurology*, 9(1), 119–128.
- Jacobs, H.I., Gronenschild, E.H., Evers, E.A., Ramakers, I.H., Hofman, P.A., Backes, W.H., ... Van Boxtel, M.P. (2015). Visuospatial processing in early Alzheimer's disease: A multi-modal neuroimaging study. *Cortex*, 64, 394–406.
- Jeurissen, B., Leemans, A., Tournier, J.D., Jones, D.K., & Sijbers, J. (2013). Investigating the prevalence of complex fiber configurations in white matter tissue with diffusion magnetic resonance imaging. *Human Brain Mapping*, 34(11), 2747–2766.
- Jones, D.T., Vemuri, P., Murphy, M.C., Gunter, J.L., Senjem, M.L., Machulda, M.M., ... Jack, C.R. Jr. (2012). Non-stationarity in the "resting brain's" modular architecture. *PLoS One*, 7(6), e39731.
- Kalus, P., Slotboom, J., Gallinat, J., Mahlberg, R., Cattapan-Ludewig, K., Wiest, R., ... Kiefer, C. (2006). Examining the gateway to the limbic system with diffusion tensor imaging: The perforant pathway in dementia. *Neuroimage*, 30(3), 713–720.
- Kantarci, K., Schwarz, C.G., Reid, R.I., Przybelski, S.A., Lesnick, T.G., Zuk, S.M., ... Jack, C.R. Jr. (2014). White matter integrity determined with diffusion tensor imaging in older adults without

- dementia: Influence of amyloid load and neurodegeneration. *JAMA Neurology*, 71(12), 1547–1554.
- Kehoe, E.G., Farrell, D., Metzler-Baddeley, C., Lawlor, B.A., Kenny, R.A., Lyons, D., ... Bokke, A.L. (2015). Fornix white matter is correlated with resting-state functional connectivity of the thalamus and hippocampus in healthy aging but not in mild cognitive impairment - A preliminary study. *Frontiers in Aging Neuroscience*, 7, 10.
- Kim, H.J., Im, K., Kwon, H., Lee, J.M., Kim, C., Kim, Y.J., ... Seo, S.W. (2015). Clinical effect of white matter network disruption related to amyloid and small vessel disease. *Neurology*, 85(1), 63–70.
- Kljajevic, V., Meyer, P., Holzmann, C., Dyrba, M., Kasper, E., Bokke, A.L., ... Teipel, S. (2014). The epsilon4 genotype of apolipoprotein E and white matter integrity in Alzheimer's disease. *Alzheimers & Dementia*, 10(3), 401–404.
- Klupp, E., Grimmer, T., Tahmasian, M., Sorg, C., Yakushev, I., Yousefi, B.H., ... Forster, S. (2015). Prefrontal hypometabolism in Alzheimer disease is related to longitudinal amyloid accumulation in remote brain regions. *Journal of Nuclear Medicine*, 56(3), 399–404.
- Koch, K., Myers, N.E., Gottler, J., Pasquini, L., Grimmer, T., Forster, S., ... Sorg, C. (2014). Disrupted intrinsic networks link amyloid-beta pathology and impaired cognition in prodromal Alzheimer's disease. *Cerebral Cortex*. [Epub ahead of print].
- Krajcovicova, L., Marecek, R., Mikl, M., & Rektorova, I. (2014). Disruption of resting functional connectivity in Alzheimer's patients and at-risk subjects. *Current Neurology and Neuroscience Reports*, 14(10), 491.
- Kuczynski, B., Targan, E., Madison, C., Weiner, M., Zhang, Y., Reed, B., ... Jagust, W. (2010). White matter integrity and cortical metabolic associations in aging and dementia. *Alzheimers & Dementia*, 6(1), 54–62.
- La Joie, R., Landeau, B., Perrotin, A., Bejanin, A., Egret, S., Pelerin, A., ... Chetelat, G. (2014). Intrinsic connectivity identifies the hippocampus as a main crossroad between Alzheimer's and semantic dementia-targeted networks. *Neuron*, 81(6), 1417–1428.
- Laufs, H., Krakow, K., Sterzer, P., Eger, E., Beyerle, A., Salek-Haddadi, A., ... Kleinschmidt, A. (2003). Electroencephalographic signatures of attentional and cognitive default modes in spontaneous brain activity fluctuations at rest. *Proceedings of the National Academy of Sciences of the United States of America*, 100(19), 11053–11058.
- Le Bihan, D., Mangin, J.F., Poupon, C., Clark, C.A., Pappata, S., Molko, N., ... Chabriat, H. (2001). Diffusion tensor imaging: Concepts and applications. *Journal of Magnetic Resonance Imaging*, 13(4), 534–546.
- Le Bihan, D., Turner, R., Douek, P., & Patronas, N. (1992). Diffusion MR imaging: Clinical applications. *AJR American Journal of Roentgenology*, 159(3), 591–599.
- Lehmann, M., Madison, C.M., Ghosh, P.M., Seeley, W.W., Mormino, E., Greicius, M.D., ... Rabinovici, G.D. (2013). Intrinsic connectivity networks in healthy subjects explain clinical variability in Alzheimer's disease. *Proceedings of the National Academy of Sciences of the United States of America*, 110(28), 11606–11611.
- Liang, P., Wang, Z., Yang, Y., Jia, X., & Li, K. (2011). Functional disconnection and compensation in mild cognitive impairment: Evidence from DLPFC connectivity using resting-state fMRI. *PLoS One*, 6(7), e22153.
- Liang, Y., Chen, Y., Li, H., Zhao, T., Sun, X., Shu, N., ... Zhang, Z. (2015). Disrupted functional connectivity related to differential degeneration of the cingulum bundle in mild cognitive impairment patients. *Current Alzheimer Research*, 12(3), 255–265.
- Liang, Y., Li, H., Lv, C., Shu, N., Chen, K., Li, X., ... Zhang, Z. (2015). Sex moderates the effects of the Sor11 gene rs2070045 polymorphism on cognitive impairment and disruption of the cingulum integrity in healthy elderly. *Neuropsychopharmacology*, 40(6), 1519–1527.
- Liu, Z., Zhang, Y., Yan, H., Bai, L., Dai, R., Wei, W., ... Tian, J. (2012). Altered topological patterns of brain networks in mild cognitive impairment and Alzheimer's disease: A resting-state fMRI study. *Psychiatry Research: Neuroimaging*, 202(2), 118–125.
- Lo, C.Y., Wang, P.N., Chou, K.H., Wang, J., He, Y., & Lin, C.P. (2010). Diffusion tensor tractography reveals abnormal topological organization in structural cortical networks in Alzheimer's disease. *The Journal of Neuroscience*, 30(50), 16876–16885.
- Lu, J., Liu, H., Zhang, M., Wang, D., Cao, Y., Ma, Q., ... Li, K. (2011). Focal pontine lesions provide evidence that intrinsic functional connectivity reflects polysynaptic anatomical pathways. *The Journal of Neuroscience*, 31(42), 15065–15071.
- Lyall, D.M., Harris, S.E., Bastin, M.E., Munoz Maniega, S., Murray, C., Lutz, M.W., ... Deary, I.J. (2014). Alzheimer's disease susceptibility genes APOE and TOMM40, and brain white matter integrity in the Lothian Birth Cohort 1936. *Neurobiology of Aging*, 35(6), 1513 e1525–e1533.
- Machulda, M.M., Jones, D.T., Vemuri, P., McDade, E., Avula, R., Przybelski, S., ... Jack, C.R. Jr. (2011). Effect of APOE epsilon4 status on intrinsic network connectivity in cognitively normal elderly subjects. *Archives of Neurology*, 68(9), 1131–1136.
- Mander, B.A., Marks, S.M., Vogel, J.W., Rao, V., Lu, B., Saletin, J.M., ... Walker, M.P. (2015). beta-amyloid disrupts human NREM slow waves and related hippocampus-dependent memory consolidation. *Nature Neuroscience*, 18(7), 1051–1057.
- Mantini, D., Perrucci, M.G., Del Gratta, C., Romani, G.L., & Corbetta, M. (2007). Electrophysiological signatures of resting state networks in the human brain. *Proceedings of the National Academy of Sciences of the United States of America*, 104(32), 13170–13175.
- Mason, M.F., Norton, M.I., Van Horn, J.D., Wegner, D.M., Grafton, S.T., & Macrae, C.N. (2007). Wandering minds: The default network and stimulus-independent thought. *Science*, 315(5810), 393–395.
- Matura, S., Prvulovic, D., Jurcoane, A., Hartmann, D., Miller, J., Scheibe, M., ... Pantel, J. (2014). Differential effects of the ApoE4 genotype on brain structure and function. *Neuroimage*, 89, 81–91.
- Medina, D., DeToledo-Morrell, L., Urresta, F., Gabrieli, J.D., Moseley, M., Fleischman, D., ... Stebbins, G.T. (2006). White matter changes in mild cognitive impairment and AD: A diffusion tensor imaging study. *Neurobiology of Aging*, 27(5), 663–672.
- Mendez, M.F., & Shapira, J.S. (2009). Altered emotional morality in frontotemporal dementia. *Cognitive Neuropsychiatry*, 14(3), 165–179.
- Menon, V., & Uddin, L.Q. (2010). Saliency, switching, attention and control: A network model of insula function. *Brain Structure & Function*, 214(5-6), 655–667.
- Metzler-Baddeley, C., Hunt, S., Jones, D.K., Leemans, A., Aggleton, J.P., & O'Sullivan, M.J. (2012). Temporal association tracts and the breakdown of episodic memory in mild cognitive impairment. *Neurology*, 79(23), 2233–2240.
- Miao, X., Wu, X., Li, R., Chen, K., & Yao, L. (2011). Altered connectivity pattern of hubs in default-mode network with

- Alzheimer's disease: An Granger causality modeling approach. *PLoS One*, 6(10), e25546.
- Mielke, M.M., Okonkwo, O.C., Oishi, K., Mori, S., Tighe, S., Miller, M.I., ... Lyketsos, C.G. (2012). Fornix integrity and hippocampal volume predict memory decline and progression to Alzheimer's disease. *Alzheimers & Dementia*, 8(2), 105–113.
- Molinuevo, J.L., Ripolles, P., Simo, M., Llado, A., Olives, J., Balasa, M., ... Rami, L. (2014). White matter changes in preclinical Alzheimer's disease: A magnetic resonance imaging-diffusion tensor imaging study on cognitively normal older people with positive amyloid beta protein 42 levels. *Neurobiology of Aging*, 35(12), 2671–2680.
- Moretti, D.V., Paternico, D., Binetti, G., Zanetti, O., & Frisoni, G.B. (2012). EEG markers are associated to gray matter changes in thalamus and basal ganglia in subjects with mild cognitive impairment. *Neuroimage*, 60(1), 489–496.
- Mori, S., Crain, B.J., Chacko, V.P., & Van Zijl, P.C.M. (1999). Three-dimensional tracking of axonal projections in the brain by magnetic resonance imaging. *Annals of Neurology*, 45(2), 265–269.
- Mori, S., & Zhang, J. (2006). Principles of diffusion tensor imaging and its applications to basic neuroscience research. *Neuron*, 51(5), 527–539.
- Mormino, E.C., Smiljic, A., Hayenga, A.O., Onami, S.H., Greicius, M.D., Rabinovici, G.D., ... Jagust, W.J. (2011). Relationships between beta-amyloid and functional connectivity in different components of the default mode network in aging. *Cerebral Cortex*, 21(10), 2399–2407.
- Morris, J.C., Roe, C.M., Xiong, C., Fagan, A.M., Goate, A.M., Holtzman, D.M., ... Mintun, M.A. (2010). APOE predicts amyloid-beta but not tau Alzheimer pathology in cognitively normal aging. *Annals of Neurology*, 67(1), 122–131.
- Myers, N., Pasquini, L., Gottler, J., Grimmer, T., Koch, K., Ortner, M., ... Sorg, C. (2014). Within-patient correspondence of amyloid-beta and intrinsic network connectivity in Alzheimer's disease. *Brain*, 137(Pt 7), 2052–2064.
- Naggara, O., Oppenheim, C., Rieu, D., Raoux, N., Rodrigo, S., Dalla Barba, G., ... Meder, J.F. (2006). Diffusion tensor imaging in early Alzheimer's disease. *Psychiatry Research*, 146(3), 243–249.
- Nath, S., Agholme, L., Kurudenkandy, F.R., Granseth, B., Marcusson, J., & Hallbeck, M. (2012). Spreading of neurodegenerative pathology via neuron-to-neuron transmission of beta-amyloid. *The Journal of Neuroscience*, 32(26), 8767–8777.
- O'Dwyer, L., Lamberton, F., Bokde, A.L., Ewers, M., Faluy, Y.O., Tanner, C., ... Hampel, H. (2012). Using support vector machines with multiple indices of diffusion for automated classification of mild cognitive impairment. *PLoS One*, 7(2), e32441.
- Oh, H., & Jagust, W.J. (2013). Frontotemporal network connectivity during memory encoding is increased with aging and disrupted by beta-amyloid. *The Journal of Neuroscience*, 33(47), 18425–18437.
- Parihar, M.S., & Brewer, G.J. (2010). Amyloid-beta as a modulator of synaptic plasticity. *Journal of Alzheimer's Disease*, 22(3), 741–763.
- Patel, K.T., Stevens, M.C., Pearlson, G.D., Winkler, A.M., Hawkins, K.A., Skudlarski, P., ... Bauer, L.O. (2013). Default mode network activity and white matter integrity in healthy middle-aged ApoE4 carriers. *Brain Imaging and Behavior*, 7(1), 60–67.
- Patriat, R., Molloy, E.K., Meier, T.B., Kirk, G.R., Nair, V.A., Meyerand, M.E., ... Birn, R.M. (2013). The effect of resting condition on resting-state fMRI reliability and consistency: A comparison between resting with eyes open, closed, and fixated. *Neuroimage*, 78, 463–473.
- Perrotin, A., Desgranges, B., Landeau, B., Mezenge, F., La Joie, R., Egret, S., ... Chetelat, G. (2015). Anosognosia in Alzheimer disease: Disconnection between memory and self-related brain networks. *Annals of Neurology*, 78, 477–486.
- Persson, J., Lind, J., Larsson, A., Ingvar, M., Slegers, K., Van Broeckhoven, C., ... Nyberg, L. (2008). Altered deactivation in individuals with genetic risk for Alzheimer's disease. *Neuropsychologia*, 46(6), 1679–1687.
- Pievani, M., de Haan, W., Wu, T., Seeley, W.W., & Frisoni, G.B. (2011). Functional network disruption in the degenerative dementias. *The Lancet. Neurology*, 10(9), 829–843.
- Puzzo, D., Privitera, L., Leznik, E., Fa, M., Staniszewski, A., Palmeri, A., ... Arancio, O. (2008). Picomolar amyloid-beta positively modulates synaptic plasticity and memory in hippocampus. *The Journal of Neuroscience*, 28(53), 14537–14545.
- Racine, A.M., Adluru, N., Alexander, A.L., Christian, B.T., Okonkwo, O.C., Oh, J., ... Johnson, S.C. (2014). Associations between white matter microstructure and amyloid burden in preclinical Alzheimer's disease: A multimodal imaging investigation. *Neuroimage. Clinical*, 4, 604–614.
- Raichle, M.E., MacLeod, A.M., Snyder, A.Z., Powers, W.J., Gusnard, D.A., & Shulman, G.L. (2001). A default mode of brain function. *Proceedings of the National Academy of Sciences of the United States of America*, 98(2), 676–682.
- Raj, A., Kuceyeski, A., & Weiner, M. (2012). A network diffusion model of disease progression in dementia. *Neuron*, 73(6), 1204–1215.
- Raj, A., LoCastro, E., Kuceyeski, A., Tosun, D., Relkin, N., & Weiner, M. (2015). Network diffusion model of progression predicts longitudinal patterns of atrophy and metabolism in Alzheimer's Disease. *Cell Reports*. [Epub ahead of print].
- Rankin, K.P., Gorno-Tempini, M.L., Allison, S.C., Stanley, C.M., Glenn, S., Weiner, M.W., ... Miller, B.L. (2006). Structural anatomy of empathy in neurodegenerative disease. *Brain*, 129, 2945–2956.
- Ray, N.J., Metzler-Baddeley, C., Khondoker, M.R., Grothe, M.J., Teipel, S., Wright, P., ... O'Sullivan, M.J. (2015). Cholinergic Basal forebrain structure influences the reconfiguration of white matter connections to support residual memory in mild cognitive impairment. *The Journal of Neuroscience*, 35(2), 739–747.
- Reijmer, Y.D., Leemans, A., Caeyenberghs, K., Heringa, S.M., Koek, H.L., & Biessels, G.J. (2013). Disruption of cerebral networks and cognitive impairment in Alzheimer disease. *Neurology*, 80(15), 1370–1377.
- Reijmer, Y.D., Leemans, A., Heringa, S.M., Wielaard, I., Jeurissen, B., Koek, H.L., ... Biessels, G.J. (2012). Improved sensitivity to cerebral white matter abnormalities in Alzheimer's disease with spherical deconvolution based tractography. *PLoS One*, 7(8), e44074.
- Ringman, J.M., O'Neill, J., Geschwind, D., Medina, L., Apostolova, L.G., Rodriguez, Y., ... Bartzokis, G. (2007). Diffusion tensor imaging in preclinical and presymptomatic carriers of familial Alzheimer's disease mutations. *Brain*, 130(Pt 7), 1767–1776.
- Rubinov, M., & Sporns, O. (2010). Complex network measures of brain connectivity: Uses and interpretations. *Neuroimage*, 52(3), 1059–1069.
- Ryan, N.S., Keihaninejad, S., Shakespeare, T.J., Lehmann, M., Crutch, S.J., Malone, I.B., ... Fox, N.C. (2013). Magnetic resonance

- imaging evidence for presymptomatic change in thalamus and caudate in familial Alzheimer's disease. *Brain*, 136(Pt 5), 1399–1414.
- Sadaghiani, S., Scheeringa, R., Lehongre, K., Morillon, B., Giraud, A.L., & Kleinschmidt, A. (2010). Intrinsic connectivity networks, alpha oscillations, and tonic alertness: A simultaneous electroencephalography/functional magnetic resonance imaging study. *The Journal of Neuroscience*, 30(30), 10243–10250.
- Salami, A., Pudas, S., & Nyberg, L. (2014). Elevated hippocampal resting-state connectivity underlies deficient neurocognitive function in aging. *Proceedings of the National Academy of Sciences of the United States of America*, 111(49), 17654–17659.
- Sanz-Arigita, E.J., Schoonheim, M.M., Damoiseaux, J.S., Rombouts, S.A., Maris, E., Barkhof, F., ... Stam, C.J. (2010). Loss of 'small-world' networks in Alzheimer's disease: Graph analysis of fMRI resting-state functional connectivity. *PLoS One*, 5(11), e13788.
- Scola, E., Bozzali, M., Agosta, F., Magnani, G., Franceschi, M., Sormani, M.P., ... Falini, A. (2010). A diffusion tensor MRI study of patients with MCI and AD with a 2-year clinical follow-up. *Journal of Neurology, Neurosurgery and Psychiatry*, 81(7), 798–805.
- Seeley, W.W., Allman, J.M., Carlin, D.A., Crawford, R.K., Macedo, M.N., Greicius, M.D., ... Miller, B.L. (2007). Divergent social functioning in behavioral variant frontotemporal dementia and Alzheimer disease: Reciprocal networks and neuronal evolution. *Alzheimer Disease and Associated Disorders*, 21(4), S50–S57.
- Seeley, W.W., Crawford, R.K., Zhou, J., Miller, B.L., & Greicius, M.D. (2009). Neurodegenerative diseases target large-scale human brain networks. *Neuron*, 62(1), 42–52.
- Selnes, P., Aarsland, D., Bjørnerud, A., Gjerstad, L., Wallin, A., Hessen, E., ... Fladby, T. (2013). Diffusion tensor imaging surpasses cerebrospinal fluid as predictor of cognitive decline and medial temporal lobe atrophy in subjective cognitive impairment and mild cognitive impairment. *Journal of Alzheimer's Disease*, 33(3), 723–736.
- Sepulcre, J., Sabuncu, M.R., Becker, A., Sperling, R., & Johnson, K.A. (2013). In vivo characterization of the early states of the amyloid-beta network. *Brain*, 136(Pt 7), 2239–2252.
- Sepulcre, J., Sabuncu, M.R., Yeo, T.B., Liu, H., & Johnson, K.A. (2012). Stepwise connectivity of the modal cortex reveals the multimodal organization of the human brain. *The Journal of Neuroscience*, 32(31), 10649–10661.
- Sexton, C.E., Mackay, C.E., Lonie, J.A., Bastin, M.E., Terriere, E., O'Carroll, R.E., ... Ebmeier, K.P. (2010). MRI correlates of episodic memory in Alzheimer's disease, mild cognitive impairment, and healthy aging. *Psychiatry Research*, 184(1), 57–62.
- Shankar, G.M., Bloodgood, B.L., Townsend, M., Walsh, D.M., Selkoe, D.J., & Sabatini, B.L. (2007). Natural oligomers of the Alzheimer amyloid-beta protein induce reversible synapse loss by modulating an NMDA-type glutamate receptor-dependent signaling pathway. *The Journal of Neuroscience*, 27(11), 2866–2875.
- Shao, J., Myers, N., Yang, Q., Feng, J., Plant, C., Bohm, C., ... Sorg, C. (2012). Prediction of Alzheimer's disease using individual structural connectivity networks. *Neurobiology of Aging*, 33(12), 2756–2765.
- Sheline, Y.I., Morris, J.C., Snyder, A.Z., Price, J.L., Yan, Z., D'Angelo, G., ... Mintun, M.A. (2010). APOE4 allele disrupts resting state fMRI connectivity in the absence of amyloid plaques or decreased CSF Abeta42. *The Journal of Neuroscience*, 30(50), 17035–17040.
- Sheline, Y.I., Raichle, M.E., Snyder, A.Z., Morris, J.C., Head, D., Wang, S., ... Mintun, M.A. (2010). Amyloid plaques disrupt resting state default mode network connectivity in cognitively normal elderly. *Biological Psychiatry*, 67(6), 584–587.
- Shulman, G.L., Corbetta, M., Fiez, J.A., Buckner, R.L., Miezin, F.M., Raichle, M.E., ... Petersen, S.E. (1997). Searching for activations that generalize over tasks. *Human Brain Mapping*, 5(4), 317–322.
- Smith, S.M., Beckmann, C.F., Andersson, J., Auerbach, E.J., Bijsterbosch, J., Douaud, G., ... Glasser, M.F. (2013). Resting-state fMRI in the Human Connectome Project. *Neuroimage*, 80, 144–168.
- Smith, S.M., Fox, P.T., Miller, K.L., Glahn, D.C., Fox, P.M., Mackay, C.E., ... Beckmann, C.F. (2009). Correspondence of the brain's functional architecture during activation and rest. *Proceedings of the National Academy of Sciences of the United States of America*, 106(31), 13040–13045.
- Soldner, J., Meindl, T., Koch, W., Bokde, A.L., Reiser, M.F., Moller, H.J., ... Teipel, S.J. (2012). [Structural and functional neuronal connectivity in Alzheimer's disease: A combined DTI and fMRI study]. *Der Nervenarzt*, 83(7), 878–887.
- Sollberger, M., Stanley, C.M., Wilson, S.M., Gyurak, A., Beckman, V., Growdon, M., ... Rankin, K.P. (2009). Neural basis of interpersonal traits in neurodegenerative diseases. *Neuropsychologia*, 47(13), 2812–2827.
- Song, S.K., Sun, S.W., Ju, W.K., Lin, S.J., Cross, A.H., & Neufeld, A.H. (2003). Diffusion tensor imaging detects and differentiates axon and myelin degeneration in mouse optic nerve after retinal ischemia. *Neuroimage*, 20(3), 1714–1722.
- Sorg, C., Riedel, V., Muhlau, M., Calhoun, V.D., Eichele, T., Laer, L., ... Wohlschlagel, A.M. (2007). Selective changes of resting-state networks in individuals at risk for Alzheimer's disease. *Proceedings of the National Academy of Sciences of the United States of America*, 104(47), 18760–18765.
- Sperling, R.A., Laviolette, P.S., O'Keefe, K., O'Brien, J., Rentz, D.M., Pihlajamaki, M., ... Johnson, K.A. (2009). Amyloid deposition is associated with impaired default network function in older persons without dementia. *Neuron*, 63(2), 178–188.
- Spires-Jones, T.L., & Hyman, B.T. (2014). The intersection of amyloid beta and tau at synapses in Alzheimer's disease. *Neuron*, 82(4), 756–771.
- Sporns, O., Honey, C.J., & Kotter, R. (2007). Identification and classification of hubs in brain networks. *PLoS One*, 2(10), e1049.
- Stahl, R., Dietrich, O., Teipel, S.J., Hampel, H., Reiser, M.F., & Schoenberg, S.O. (2007). White matter damage in Alzheimer disease and mild cognitive impairment: Assessment with diffusion-tensor MR imaging and parallel imaging techniques. *Radiology*, 243(2), 483–492.
- Stenset, V., Bjørnerud, A., Fjell, A.M., Walhovd, K.B., Hofoss, D., Due-Tønnessen, P., ... Fladby, T. (2011). Cingulum fiber diffusivity and CSF T-tau in patients with subjective and mild cognitive impairment. *Neurobiology of Aging*, 32(4), 581–589.
- Sturm, V.E., McCarthy, M.E., Yun, I., Madan, A., Yuan, J.W., Holley, S.R., ... Levenson, R.W. (2011). Mutual gaze in Alzheimer's disease, frontotemporal and semantic dementia couples. *Social Cognitive and Affective Neuroscience*, 6(3), 359–367.
- Sturm, V.E., Yokoyama, J.S., Seeley, W.W., Kramer, J.H., Miller, B.L., & Rankin, K.P. (2013). Heightened emotional contagion in mild cognitive impairment and Alzheimer's disease is associated with temporal lobe degeneration. *Proceedings of the National Academy of Sciences of the United States of America*, 110(24), 9944–9949.



- Supekar, K., Menon, V., Rubin, D., Musen, M., & Greicius, M.D. (2008). Network analysis of intrinsic functional brain connectivity in Alzheimer's disease. *PLoS Computational Biology*, 4(6), e1000100.
- Tahmasian, M., Pasquini, L., Scherr, M., Meng, C., Forster, S., Mulej Bratec, S., ... Drzezga, A. (2015). The lower hippocampus global connectivity, the higher its local metabolism in Alzheimer disease. *Neurology*, 84(19), 1956–1963.
- Teipel, S., Ehlers, I., Erbe, A., Holzmann, C., Lau, E., Hauenstein, K., ... Berger, C. (2015). Structural connectivity changes underlying altered working memory networks in mild cognitive impairment: A three-way image fusion analysis. *J Neuroimaging*, 25(4), 634–642.
- Teipel, S.J., Bokde, A.L., Meindl, T., Amaro, E. Jr., Soldner, J., Reiser, M.F., ... Hampel, H. (2010). White matter microstructure underlying default mode network connectivity in the human brain. *Neuroimage*, 49(3), 2021–2032.
- Teipel, S.J., Grothe, M.J., Filippi, M., Fellgiebel, A., Dyrba, M., Frisoni, G.B., ... group, E.S. (2014). Fractional anisotropy changes in Alzheimer's disease depend on the underlying fiber tract architecture: A multiparametric DTI study using joint independent component analysis. *Journal of Alzheimer's Disease*, 41(1), 69–83.
- Teipel, S.J., Lerche, M., Kilimann, I., O'Brien, K., Grothe, M., Meyer, P., ... Hauenstein, K. (2014). Decline of fiber tract integrity over the adult age range: A diffusion spectrum imaging study. *Journal of Magnetic Resonance Imaging*, 40(2), 348–359.
- Teipel, S.J., Meindl, T., Grinberg, L., Grothe, M., Cantero, J.L., Reiser, M.F., ... Hampel, H. (2011). The cholinergic system in mild cognitive impairment and Alzheimer's disease: An in vivo MRI and DTI study. *Human Brain Mapping*, 32(9), 1349–1362.
- Teipel, S.J., Meindl, T., Wagner, M., Stieltjes, B., Reuter, S., Hauenstein, K.H., ... Hampel, H. (2010). Longitudinal changes in fiber tract integrity in healthy aging and mild cognitive impairment: A DTI follow-up study. *Journal of Alzheimer's Disease*, 22(2), 507–522.
- Teipel, S.J., Pogarell, O., Meindl, T., Dietrich, O., Sydykova, D., Hunklinger, U., ... Hampel, H. (2009). Regional networks underlying interhemispheric connectivity: An EEG and DTI study in healthy ageing and amnesic mild cognitive impairment. *Human Brain Mapping*, 30(7), 2098–2119.
- Teipel, S.J., Reuter, S., Stieltjes, B., Acosta-Cabronero, J., Ernemann, U., Fellgiebel, A., ... Hampel, H. (2011). Multicenter stability of diffusion tensor imaging measures: A European clinical and physical phantom study. *Psychiatry Research*, 194(3), 363–371.
- Teipel, S.J., Sabri, O., Grothe, M., Barthel, H., Prvulovic, D., Buerger, K., ... Hampel, H. (2013). Perspectives for multimodal neurochemical and imaging biomarkers in Alzheimer's disease. *Journal of Alzheimer's Disease*, 33(Suppl. 1), S329–S347.
- Teipel, S.J., Wegrzyn, M., Meindl, T., Frisoni, G., Bokde, A.L., Fellgiebel, A., ... Ewers, M. (2012). Anatomical MRI and DTI in the diagnosis of Alzheimer's disease: A European multicenter study. *Journal of Alzheimer's Disease*, 31(Suppl. 3), S33–S47.
- Thal, D.R., Attems, J., & Ewers, M. (2014). Spreading of amyloid, tau, and microvascular pathology in Alzheimer's disease: Findings from neuropathological and neuroimaging studies. *Journal of Alzheimer's Disease*, 42(Suppl. 4), S421–S429.
- van den Heuvel, M., Mandl, R., Luigjes, J., & Hulshoff Pol, H. (2008). Microstructural organization of the cingulum tract and the level of default mode functional connectivity. *The Journal of Neuroscience*, 28(43), 10844–10851.
- van den Heuvel, M.P., Mandl, R.C., Kahn, R.S., & Hulshoff Pol, H.E. (2009). Functionally linked resting-state networks reflect the underlying structural connectivity architecture of the human brain. *Human Brain Mapping*, 30(10), 3127–3141.
- van den Heuvel, M.P., & Sporns, O. (2011). Rich-club organization of the human connectome. *Journal of Neuroscience*, 31(44), 15775–15786.
- Vecchio, F., Miraglia, F., Curcio, G., Altavilla, R., Scarscia, F., Giambattistelli, F., ... Rossini, P.M. (2015). Cortical brain connectivity evaluated by graph theory in dementia: A correlation study between functional and structural data. *Journal of Alzheimer's Disease*, 45, 745–756.
- Vidal-Pineiro, D., Valls-Pedret, C., Fernandez-Cabello, S., Arenaza-Urquijo, E.M., Sala-Llonch, R., Solana, E., ... Bartres-Faz, D. (2014). Decreased default mode network connectivity correlates with age-associated structural and cognitive changes. *Frontiers in Aging Neuroscience*, 6, 256.
- Villain, N., Fouquet, M., Baron, J.C., Mezenge, F., Landeau, B., de La Sayette, V., ... Chetelat, G. (2010). Sequential relationships between grey matter and white matter atrophy and brain metabolic abnormalities in early Alzheimer's disease. *Brain*, 133(11), 3301–3314.
- Villemagne, V.L., Pike, K.E., Chetelat, G., Ellis, K.A., Mulligan, R.S., Bourgeat, P., ... Rowe, C.C. (2011). Longitudinal assessment of Abeta and cognition in aging and Alzheimer disease. *Annals of Neurology*, 69(1), 181–192.
- Vincent, J.L., Patel, G.H., Fox, M.D., Snyder, A.Z., Baker, J.T., Van Essen, D.C., ... Raichle, M.E. (2007). Intrinsic functional architecture in the anaesthetized monkey brain. *Nature*, 447(7140), 83–86.
- Voineskos, A.N., Lerch, J.P., Felsky, D., Shaikh, S., Rajji, T.K., Miranda, D., ... Kennedy, J.L. (2011). The brain-derived neurotrophic factor Val66Met polymorphism and prediction of neural risk for Alzheimer disease. *Archives of General Psychiatry*, 68(2), 198–206.
- Wang, D., Liu, B., Qin, W., Wang, J., Zhang, Y., Jiang, T., ... Yu, C. (2013). KIBRA gene variants are associated with synchronization within the default-mode and executive control networks. *Neuroimage*, 69, 213–222.
- Wang, J., Wang, X., He, Y., Yu, X., Wang, H., & He, Y. (2015). Apolipoprotein E epsilon4 modulates functional brain connectome in Alzheimer's disease. *Human Brain Mapping*, 36, 1828–1846.
- Wang, K., Liang, M., Wang, L., Tian, L., Zhang, X., Li, K., ... Jiang, T. (2007). Altered functional connectivity in early Alzheimer's disease: A resting-state fMRI study. *Human Brain Mapping*, 28(10), 967–978.
- Wedeen, V.J., Wang, R.P., Schmahmann, J.D., Benner, T., Tseng, W.Y., Dai, G., ... de Crespigny, A.J. (2008). Diffusion spectrum magnetic resonance imaging (DSI) tractography of crossing fibers. *Neuroimage*, 41(4), 1267–1277.
- Wee, C.Y., Yap, P.T., Zhang, D., Denny, K., Browndyke, J.N., Potter, G.G., ... Shen, D. (2012). Identification of MCI individuals using structural and functional connectivity networks. *Neuroimage*, 59(3), 2045–2056.
- Weiler, M., de Campos, B.M., Nogueira, M.H., Pereira Damasceno, B., Cendes, F., & Balthazar, M.L. (2014). Structural connectivity of the default mode network and cognition in Alzheimers disease. *Psychiatry Research*, 223(1), 15–22.
- Westlye, L.T., Reinvang, I., Rootwelt, H., & Espeseth, T. (2012). Effects of APOE on brain white matter microstructure in healthy adults. *Neurology*, 79(19), 1961–1969.

- Whitwell, J.L., Przybelski, S.A., Weigand, S.D., Knopman, D.S., Boeve, B.F., Petersen, R.C., ... Jack, C.R. Jr. (2007). 3D maps from multiple MRI illustrate changing atrophy patterns as subjects progress from mild cognitive impairment to Alzheimer's disease. *Brain*, *130*(Pt 7), 1777–1786.
- Xie, S., Xiao, J.X., Gong, G.L., Zang, Y.F., Wang, Y.H., Wu, H.K., ... Jiang, X.X. (2006). Voxel-based detection of white matter abnormalities in mild Alzheimer disease. *Neurology*, *66*(12), 1845–1849.
- Xiong, C., Roe, C.M., Buckles, V., Fagan, A., Holtzman, D., Balota, D., ... Morris, J.C. (2011). Role of family history for Alzheimer biomarker abnormalities in the adult children study. *Archives of Neurology*, *68*(10), 1313–1319.
- Yakushev, I., Schreckenberger, M., Muller, M.J., Schermuly, I., Cumming, P., Stoeter, P., ... Fellgiebel, A. (2011). Functional implications of hippocampal degeneration in early Alzheimer's disease: A combined DTI and PET study. *European Journal of Nuclear Medicine and Molecular Imaging*, *38*(12), 2219–2227.
- Yeo, B.T., Krienen, F.M., Sepulcre, J., Sabuncu, M.R., Lashkari, D., Hollinshead, M., ... Buckner, R.L. (2011). The organization of the human cerebral cortex estimated by intrinsic functional connectivity. *Journal of Neurophysiology*, *106*(3), 1125–1165.
- Zhang, H.Y., Wang, S.J., Liu, B., Ma, Z.L., Yang, M., Zhang, Z.J., ... Teng, G.J. (2010). Resting brain connectivity: Changes during the progress of Alzheimer disease. *Radiology*, *256*(2), 598–606.
- Zhang, Y., Schuff, N., Jahng, G.H., Bayne, W., Mori, S., Schad, L., ... Weiner, M.W. (2007). Diffusion tensor imaging of cingulum fibers in mild cognitive impairment and Alzheimer disease. *Neurology*, *68*(1), 13–19.
- Zhou, J., Gennatas, E.D., Kramer, J.H., Miller, B.L., & Seeley, W. W. (2012). Predicting regional neurodegeneration from the healthy brain functional connectome. *Neuron*, *73*(6), 1216–1227.
- Zhou, J., Greicius, M.D., Gennatas, E.D., Growdon, M.E., Jang, J.Y., Rabinovici, G.D., ... Seeley, W.W. (2010). Divergent network connectivity changes in behavioural variant frontotemporal dementia and Alzheimer's disease. *Brain*, *133*(Pt 5), 1352–1367.
- Zhuang, L., Sachdev, P.S., Trollor, J.N., Kochan, N.A., Reppermund, S., Brodaty, H., ... Wen, W. (2012). Microstructural white matter changes in cognitively normal individuals at risk of amnesic MCI. *Neurology*, *79*(8), 748–754.
- Zuo, X.N., Ehmke, R., Mennes, M., Imperati, D., Castellanos, F.X., Sporns, O., ... Milham, M.P. (2012). Network centrality in the human functional connectome. *Cerebral Cortex*, *22*(8), 1862–1875.