



Operative Management of Avascular Necrosis of the Femoral Head in Skeletally Immature Patients: A Systematic Review

Filippo Migliorini ^{1,*}, Gerardo La Padula ², Francesco Oliva ², Ernesto Torsiello ², Frank Hildebrand ¹ and Nicola Maffulli ^{2,3,4}

¹ Department of Orthopaedic, Trauma and Reconstructive Surgery, RWTH University Hospital, 52074 Aachen, Germany; fhildebrand@ukaachen.de

² Department of Medicine, Surgery and Dentistry, University of Salerno, 84081 Baronissi, SA, Italy; gerardo.lp@outlook.it (G.L.P.); olivafrancesco@hotmail.com (F.O.); ernesto.torsiello94@gmail.com (E.T.); n.maffulli@qmul.ac.uk (N.M.)

³ Faculty of Medicine, School of Pharmacy and Bioengineering, Keele University, Stoke on Trent ST4 7QB, UK

⁴ Centre for Sports and Exercise Medicine, Barts and the London School of Medicine and Dentistry, Queen Mary University of London, Mile End Hospital, London E1 4DG, UK

* Correspondence: migliorini.md@gmail.com; Tel.: +49-024-1803-5529

Abstract: Purpose: Osteonecrosis of the femoral head (ONFH) is common in skeletally immature patients. The management of ONFH is controversial, with limited evidence and unpredictable results. This study systematically reviewed the current operative modalities and clinical outcomes of surgical management for ONFH in skeletally immature patients. Methods: The present study was conducted according to the PRISMA 2020 guidelines. PubMed, Google Scholar, Embase, and Web of Science databases were accessed in October 2021. All the published clinical studies reporting data concerning the surgical management of ONFH in skeletally immature patients were included. Results: This review included 122 patients (127 hips). 38.2% (46 of 122) were female. The mean age of the patients was 14.2 ± 2.3 years. The mean duration of the follow-up was 55.3 ± 19.6 months. The Harris Hip Score improved from 68.8 ± 11.9 at baseline to 90.5 ± 6.5 at last follow-up ($p < 0.0001$). Femoral head collapse and secondary hip degeneration were the most common complications. Conclusion: Several surgical techniques are available and effective for the management of ONFH in skeletally immature patients. This study evidenced high heterogeneity of the surgical procedures and eligibility criteria. Further high-quality investigations are required to establish proper indications and surgical modalities.

Keywords: osteonecrosis; femoral head; skeletally immature



Citation: Migliorini, F.; La Padula, G.; Oliva, F.; Torsiello, E.; Hildebrand, F.; Maffulli, N. Operative Management of Avascular Necrosis of the Femoral Head in Skeletally Immature Patients: A Systematic Review. *Life* **2022**, *12*, 179. <https://doi.org/10.3390/life12020179>

Academic Editor: Gopal J. Babu

Received: 20 December 2021

Accepted: 21 January 2022

Published: 26 January 2022

Publisher's Note: MDPI stays neutral with regard to jurisdictional claims in published maps and institutional affiliations.



Copyright: © 2022 by the authors. Licensee MDPI, Basel, Switzerland. This article is an open access article distributed under the terms and conditions of the Creative Commons Attribution (CC BY) license (<https://creativecommons.org/licenses/by/4.0/>).

1. Introduction

Osteonecrosis of the femoral head (ONFH) is a disabling condition which leads to progressive pain, deformity, and early-onset osteoarthritis [1,2]. The growth plate acts as a barrier for the intraosseous blood vessels, and femoral head vascularisation is guaranteed by the lateral epiphyseal vessels [3–5]. Once bone maturity has been reached, the lateral epiphyseal vessels, the vessels of the metaphysis, epiphysis, and round ligament of the femur anastomose [3–6]. The aetiology of ONFH can be traumatic and atraumatic [7]. In traumatic ONFH, a fracture may cause an interruption of the blood supply to the femoral head [8]. Although proximal femur fractures in skeletally immature patients are rare, the risk of ONFH insurgence is high, and affects approximately 20% of such patients [9–12]. Several causes of atraumatic ONFH in the young population have been described; prolonged steroids consumption [7,13,14] and Legg-Calvé-Perthes disease [15,16] represent the most common etiological factors; sickle cell disease [17,18], lymphoblastic leukaemia [19,20], human immunodeficiency virus (HIV) infection [21,22] and Gaucher's disease [23] are other less common causes. The management of ONFH in skeletally immature patients

is controversial, with limited evidence and unpredictable results [24]. Several operative strategies have been developed to regenerate or avoid further femoral head collapse, but no consensus has been reached. This study systematically reviewed the current available evidence on the surgical management of ONFH in skeletally immature patients, focusing on techniques, efficacy, and the safety profile.

2. Material and Methods

2.1. Eligibility Criteria

All of the clinical studies evaluating the efficacy and safety of operative management of ONFH in skeletally immature patients were considered. According to the authors language capabilities, articles in English, German, and Italian were eligible. Only studies published in peer-reviewed journals were eligible. Only level I to IV of evidence articles, according to Oxford Centre of Evidence-Based Medicine [25], were considered. Reviews, opinions, letters, and editorials were not considered. Animals, biomechanics, computational, and cadaveric studies were not eligible. Only studies investigating a population with a mean age ≤ 18 years were eligible. Studies which involved less than five patients were excluded, as were those with a mean follow-up ≤ 24 months, or studies focusing on Legg-Calve-Perthes disease. Only studies which reported quantitative data under the outcomes of interest were considered.

2.2. Search Strategy

This systematic review was conducted according to the Preferred Reporting Items for Systematic Reviews and Meta-Analyses: the 2020 PRISMA statement [26]. The following algorithm was preliminary pointed out:

- Problem: ONFH;
- Intervention: operative management;
- Comparison: operative techniques;
- Outcomes: efficacy and safety profile;
- Timing: minimum 24 months follow-up;
- Age: ≤ 18 years.

In October 2021, the following databases were accessed: Pubmed, Web of Science, Google Scholar, EMBASE. No time constraints were used for the search. The following keywords were used: osteonecrosis, avascular, necrosis, collapsed, femur, femoral, head, fractures, ONFH, adolescent, paediatric, skeletally immature, surgery, operative, treatment, management, osteotomy. The keywords were combined using the Boolean operator AND/OR.

2.3. Selection and Data Collection

Two authors (F.M.; G.L.P.) independently performed the database search. All resulting titles were screened and the abstract of the articles which matched the topic were accessed. If the abstract matched the topic, the full-text article was accessed. A cross-reference of the bibliography of the full-text articles was also undertaken. Disagreements were debated and the final decision was made by a third author (N.M.).

2.4. Data Items

Two authors (F.M.; G.L.P.) independently performed data extraction. Generalities of the articles were retrieved: author and year, journal, duration of the follow-up, type of study. The following data were extracted: age, sex, aetiology, type of treatment, Harris Hip Score (HHS) [27], and complications.

2.5. Study Risk of Bias Assessment

The Coleman Methodology Score (CMS) was used to assess the quality of the methodological assessment [28]. Each article was assessed by a single reviewer (G.L.P.). The CMS is divided in two sections: A and B. Section A evaluated seven items: study size (number of

patients), mean follow-up (from <12 month to >60 month), number of surgical approaches, type of study (randomized, prospective, or retrospective), and the description of diagnosis, surgical procedure, and rehabilitation. Section B evaluated the outcome criteria, method of assessing outcomes, and subject selection process. The final score ranges from 0 to 100 points, with values > 60.

2.6. Synthesis Methods

All statistical analyses were performed using the IBM SPSS Software version 25. For descriptive statistics, mean and standard deviation were calculated. To evaluate the improvement of the HHS from baseline to the last follow-up, the mean difference (MD) and T-test were performed. The confidence interval (CI) was set at 95%. Values of $p < 0.05$ were considered statistically significant.

3. Results

3.1. Study Selection

The initial literature search resulted in 209 studies. Of them, 70 were excluded for being duplicates. Another 120 were not eligible, either for not matching the topic ($N = 71$), focusing on adults ($N = 22$), focusing on surgical management ($N = 6$), focusing on Legg-Calve-Perthes disease ($N = 16$), the type of study ($N = 2$), full text not accessible ($N = 2$), or uncertain results ($N = 1$). This left 19 articles for inclusion. An additional 11 studies were excluded as they did not report quantitative data under the outcomes of interest. This resulted in eight studies for analysis. The literature search results are shown in Figure 1.

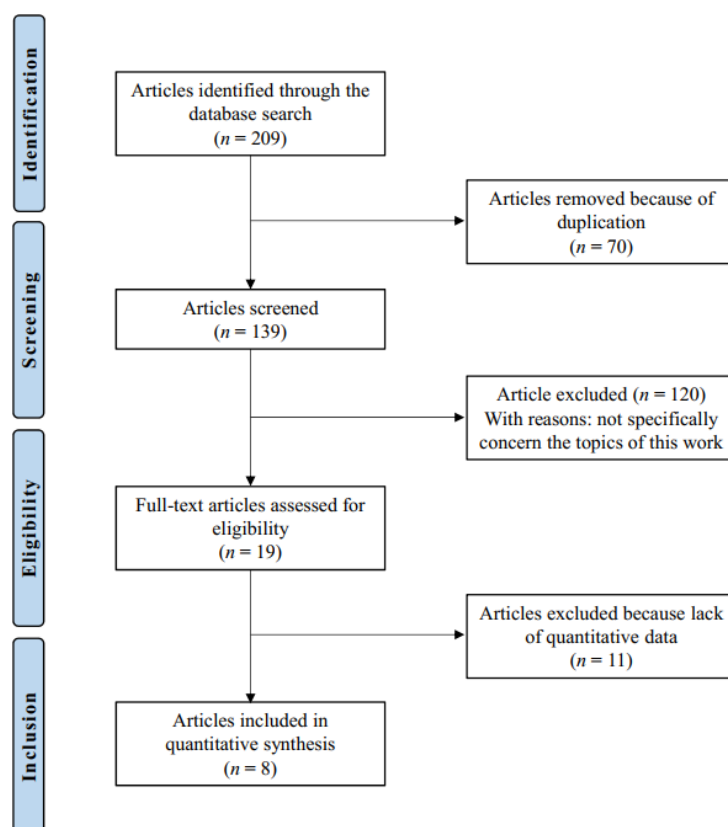


Figure 1. Flow chart of the literature search.

3.2. Study Risk of Bias Assessment

The length of the follow-up was acceptable in most studies. Surgical technique, diagnosis, and rehabilitation protocols were generally well described. The study size and the retrospective design of most of the included studies represented the main limitations highlighted by the CMS. Outcome measures, assessment timing, and selection process were

also clearly defined by most studies. Finally, the mean methodology score of 73.8 (range: 69 to 79) suggested an overall good quality of the methodological assessment (Table 1).

Table 1. Methodological quality assessment.

Endpoint	Mean	Range
Part A: only one score to be given for each of the 7 sections		
Study size: number of patients	1	0 to 4
Mean follow-up	7.75	4 to 10
Surgical approach	8.87	7 to 10
Type of study	3.75	0 to 10
Descriptions of diagnosis	5	5 to 5
Descriptions of surgical technique	10	10 to 10
Description of postoperative rehabilitation	5	5 to 5
Part B: may be given for each option in each of the 3 sections		
Outcome criteria	10	10 to 10
Procedure of assessing outcomes	13	12 to 15
Description of subject selection process	9.37	5 to 10

3.3. Patient Demographics

Data from a total of 120 patients (125 hips) were collected; 38.3% (46 of 120) were females. The mean age of the patients was 14.2 ± 2.3 years. The mean follow-up was 55.3 ± 19.6 months. The aetiology of ONFH was: 72.8% (91 of 125) traumatic, 17.6% (22 of 125) caused by sickle cell disease, 3.2% (4 of 125) idiopathic, and 4.8% (6 of 125) other (infection, steroids use, lymphocytic leukemia, post-adrenal tumor excision). The demographic data are shown in Table 2.

Table 2. Generalities and patient demographic of included studies.

Author, Year	Journal	Study Design	Purpose	Participants (n)	Mean Age	Female (%)	Follow-Up (Mean Months)
Bartoníček et al., 2011 [2]	<i>Arch. Orthop. Trauma Surg.</i>	Prospective	Medium-term outcome assessment of valgus-flexion intertrochanteric osteotomy for ONFH after slipped capital femoral epiphysis	5	12.5	40	73
Bartoníček et al., 2012 [29]	<i>Int. Orthop.</i>	Prospective	Outcome assessment of post traumatic ONFH treated with total hip replacement or valgus intertrochanteric osteotomy	11	17	82	89
Gatin et al., 2016 [30]	<i>Haemoglobin</i>	Prospective	Medium-term outcome assessment of triple acetabular osteotomy or femoral varus osteotomy for ONFH in sickle cell patients	10 (11 hips)	10.2	50	63.6
Ko et al., 1995 [31]	<i>J. Paed. Orthop.</i>	Retrospective	Report outcome of trapdoor bone grafting procedure combined with containment osteotomy of femur and acetabulum	12 (13 hips)	15.5	46	53

Table 2. Cont.

Author, Year	Journal	Study Design	Purpose	Participants (n)	Mean Age	Female (%)	Follow-Up (Mean Months)
Li et al., 2018 [32]	<i>Int. J. Clin. Exp. Med.</i>	Retrospective	Compare the outcome of non-vascularized bone grafting via trapdoor procedure in traumatic collapsed-stage ONFH with conservative methods	37	15.1	27	44.5
Nötzli et al., 1995 [33]	<i>J. Paed. Orthop.</i>	Retrospective	Report outcome of extruded femoral head reorientation with combined open reduction and intertrochanteric osteotomy in Ficat stage III and IV ONFH	6	14.5	14	46
Novais et al., 2015 [34]	<i>J. Paed. Orthop.</i>	Retrospective	Results of Multiple Epiphyseal Drilling and autologous bone marrow implantation for ONFH secondary to sickle cell disease in children	11 (14 hips)	12.7	18	25
Zhang et al., 2011 [35]	<i>J. Bone Joint Surg.</i>	Retrospective	Free vascularised fibular graft for post-traumatic osteonecrosis of the femoral head in teenage patients	28	16.3	28	48

3.4. Efficacy

Five articles [2,29,30,32,35] reported data concerning the Harris Hip Score data. Irrespective of the surgical technique, the mean HHS improved from 68.8 ± 11.9 at baseline to 90.5 ± 6.5 at last follow-up ($+21.7$; 95% CI 20.06 to 23.33; $p < 0.0001$). Pre- and post-operative plain radiographies [2,29–35] and magnetic resonance imaging (MRI) [2,29,30] were evaluated. All surgical techniques were effective in regenerating the femoral head or in blocking the progression of degeneration [2,29–35]. Improvement in range of motion and pain relief was also observed [2,29–35]. THA and femoral osteotomies have been used to correct leg shortening [2,29,30,33]. The efficacy of each surgical technique is reported in greater detail in Table 3.

Table 3. Efficacy of each surgical technique.

Author, Year	Intervention	Efficacy
Bartoniček et al., 2011 [2]	Valgus-flexion intertrochanteric osteotomy (five hips)	In all patients, the osteotomy healed within three months without complications. Limb shortening was fully corrected in all the patients. Radiographs and MRI scans after osteotomy proved resorption of the necrotic segment of the femoral head and its remodeling in all the patients.
Bartoniček et al., 2012 [29]	Valgus intertrochanteric osteotomy (six hips); Total hip replacement (five hips)	VITO: in five of six patients osteotomy healed within three months without complications. Leg shortening was fully corrected in four of six patients. MRI scans after surgery showed resorption of the necrotic segment of the femoral head and its remodeling in all six patients. THR: all patients healed without complications. Shortening of the affected limb was compensated in all patients. The range of movement was only minimally limited compared with the contralateral side. All patients were highly satisfied. No signs of implant loosening were noted at the final follow-up.

Table 3. Cont.

Author, Year	Intervention	Efficacy
Bartoniček et al., 2011 [2]	Valgus-flexion intertrochanteric osteotomy (five hips)	In all patients, the osteotomy healed within three months without complications. Limb shortening was fully corrected in all the patients. Radiographs and MRI scans after osteotomy proved resorption of the necrotic segment of the femoral head and its remodeling in all the patients.
Gatin et al., 2016 [30]	Triple acetabular osteotomy (seven hips); Varus osteotomy (2 hips); Combination of both (two hips)	All patients had an objective functional improvement in terms of pain and range of motion. X-ray and MRI showed bone reconstruction in all the patients. At the last follow-up, joint congruency was satisfactory for all patients. No postoperative complications related to the surgery were reported.
Ko et al., 1995 [31]	Non-vascularised bone grafting via trapdoor procedure combined with containment osteotomy of femur and acetabulum (14 hips)	On clinical evaluation all patients had improvement in pain, activity, and hip motion. The pain score improved from 2.3 to 4.6. The activity score improved from 1.8 to 4.5, and the motion score from 2.8 to 3.9
Li et al., 2018 [32]	- Non-vascularized bone grafting via trapdoor procedure	Surgery provided a lower risk of femoral head collapse progression, improved clinical function, and prevented rapid hip degeneration compared to conservative treatment
Nötzli et al., 1995 [33]	- Open reduction and intertrochanteric osteotomy	Postoperative joint motion improves in four of the six patients; all six patients had widening of the joint space and improved congruency at last follow-up radiographs; all six patients had improvement in gait
Novais et al., 2015 [34]	- Multiple Epiphyseal Drilling and Autologous Bone Marrow Implantation	Four of 14 hips had radiologically improvement. No further progression of the necrotic process was observed in seven of 14 hips at the latest follow-up. Pain relief and improvement in range of motion was also observed in all the patients
Zhang et al., 2011 [35]	- Free vascularised fibular graft	No patient had complication at the site of the fibular graft harvesting. No patients required conversion to a total hip replacement. 22 of 28 hips (79%) improved radiologically, whit sign of resorption of the necrotic segment of the femoral head and its remodeling. Pain relief and improvement in range of motion was observed in all the patients

3.5. Complications

Failure of treatment to prevent the progression of femoral head collapse, secondary hip degeneration, and reoperation were the main complications [2,29–35]. These complications were reported in 46 of the 120 patients analysed (38.3%). 54.3% (25 of 46) of the patients who experienced complications were treated conservatively. Failure of treatment to prevent the progression of femoral head collapse was observed in 11 of 100 (11%) surgically treated patients [31–35]. They included the following. One-quarter (5 of 20) of the patients were treated with the trapdoor procedure [31,32], 21.4% (3 of 14) of patients were treated with multiple epiphyseal drilling and autologous bone marrow implantation [34], two of 28 (7.1%) were treated with free vascularised fibular graft [35], and 14% (one of six) of patients was treated with an intertrochanteric osteotomy [33]. Secondary hip degeneration was observed in 18 patients. Of them, 33.3% (6 of 18) were treated with non-vascularized bone grafting via the trapdoor procedure [32]. A total of four patients underwent reoperation. Of them, 18.1% two of 11) had undergone a valgus intertrochanteric osteotomy [2,29], and 14.2% (two of 14) had received multiple epiphyseal drilling and autologous bone marrow implantation [34]. The major complications of each surgical technique are reported in greater detail in Table 4.

Table 4. Main complications of each surgical technique.

Author, Year	Intervention	Complications
Bartoniček et al., 2011 [2]	Valgus-flexion intertrochanteric osteotomy (five hips)	One of the five patients was performed another osteotomy at one year after the surgery for the presence of a necrotic segment of the femoral head
Bartoniček et al., 2012 [29]	Valgus intertrochanteric osteotomy (six hips); Total hip replacement (five hips)	VITO: one of six patients was reoperated five months after osteotomy for nonunion THR: no complications were observed
Gatin et al., 2016 [30]	Triple acetabular osteotomy (seven hips); Varus osteotomy (two hips); Combination of both (two hips)	In one patient, femoral osteotomy was performed in addition to a triple acetabular osteotomy. Pneumonia occurred in a patient at two days postoperatively
Ko et al., 1995 [31]	Non-vascularized bone grafting via trapdoor procedure combined with containment osteotomy of femur and acetabulum (13 hips)	Trapdoor procedure failed in two patients, one patient was subsequently treated by THA and the other one by femoral head allograft, at three and two years, respectively. Several patients had a mild to moderate limp but did not have pain. One patient at the latest follow-up had a 3.2 cm limb length discrepancy
Li et al., 2018 [32]	Non-vascularized bone grafting via trapdoor procedure	In the surgical group the progression of femoral head collapse was found in three of 17 patients, secondary hip degeneration was found in six of 17 patients. In the conservative group, progression of femoral head collapse was found in 13 of 20 patients, secondary hip degeneration was in 12 of 20 patients
Nötzli et al., 1995 [33]	Open reduction and intertrochanteric osteotomy	Treatment failed in one patient, his hip subluxed, causing loss of motion and ongoing destruction of the femoral head. The patient also developed pain and his limp was more pronounced
Novais et al., 2015 [34]	Multiple Epiphyseal Drilling and Autologous Bone Marrow Implantation	Three hips had disease progression and two patients have required subsequent surgical procedures at latest follow-up
Zhang et al., 2011 [35]	Free vascularised fibular graft	Radiologically, four of 28 hips were not improved and two of 28 hips were worse

4. Discussion

According to the main findings of the present study, surgical management is effective to improve symptoms, and decelerate or arrest the evolution of ONFH. Overall pain reduction, motion and gait improvement were reported by most patients. Surgical management aims to revitalize the femoral head, favour spherical remodeling, induce necrosis resorption, and improve hip motion.

Conservative management consists mostly in physiotherapy, bisphosphonates and/or non-steroidal anti-inflammatory drug (NSAID) administration, vitamins supplementation, weight-bearing limitation, and, if possible, removal of the underlying cause [17,36–39]. These therapeutic measures demonstrated limited potential in stimulating femoral head remodeling, resorption of necrotic tissue, or improvement of hip motion. Most conservatively managed patients evidenced worsening of the HHS, progression of the osteonecrosis, and further joint degeneration [32,40,41]. Irrespective to the surgical strategy, the mean HHS significantly improved by approximately 21%. This improvement overcomes the minimally clinical important difference (MCID) [2,29,30,32,35,42,43].

The mean age of the population included for analysis was 14 years. At the approximate age of 14 years in girls and 16 years in boys, the growth plates of the femur start to fuse [44,45]. Hence, the population included was likely to still have open epiphyseal growth plates. Patients with open epiphyseal growth plates demonstrated higher bone marrow derived stem cell concentration compared to adults [46–48]. Moreover, the open physis promotes greater self-healing [49]. In this context, the use of bone marrow stimulating

techniques should promote a greater regenerative potential in this population compared to adults. Further studies investigating the efficacy of bone marrow stimulating techniques of simple execution (e.g., isolated core decompression) in early ONFH should be considered. Multiple epiphyseal drilling augmented with autologous bone marrow implantation has been investigated in skeletally immature patients with ONFH secondary to sickle cell anaemia [34]. 29% (four of 14) of patients treated with multiple epiphyseal drilling augmented autologous bone marrow demonstrated significant improvements in symptoms and motion, and no further necrosis progression was evidenced in the half of the patients (seven of 14) [34]. Valgus and varus intertrochanteric osteotomy and triple acetabular osteotomy have been successfully performed in the early stages of ONFH to promote bone healing by discharging weight bearing over the necrotic area [2,29,30]. In patients with moderate to advanced ONFH, bone grafting may be performed [50–52]. Bone grafting replaces necrotic material, stimulates revascularisation, and, given its osteoinductive properties, promotes bone reconstruction [35,52,53]. The trapdoor procedure was effective in reducing the risk of femoral head collapse progression, improving clinical function in patients with moderate ONFH [32,54]. The trapdoor procedure aims to replace the necrotic area, promote revascularisation, and prevent collapse [31,54]. Ko et al. [31] investigated the potential of the trapdoor procedure in isolation and in combination with femoral and/or acetabular osteotomy on 13 young patients with advanced ONFH. The isolated procedure failed in two of three patients, while those operated with the combined procedure reported significant improvement in symptoms, activity, and range of motion [31]. These results indicated that the isolated procedure may be recommended for early-stage degeneration, and should be performed in combination in more advanced stages of ONFH. Zhang et al. [35] reported the outcome of 28 skeletally immature patients treated with a free vascularised fibular graft. Regardless of the extent of ONFH, all patients experienced an excellent outcome, with an improvement in HHS from 60.4 to 94.2 points on average [35]. In patients with advanced ONFH, THA improved joint function and symptoms, restored leg length difference, and led to the greatest improvement of the HHS [35]. However, despite its excellent results, THA should be performed only as last resort, as long-term survival of the implants is not ensured [55–57].

Current evidence on ONFH management refers almost exclusively to the adult population or mixed cohort populations. Rotational osteotomies, core decompression in isolation or in combination with vascularised bone grafts, bone morphogenetic proteins, bone marrow-derived cells, mesenchymal stem cells, or combinations of the above, are the most commonly reported surgical procedures performed for early to moderate ONFH [58–66]. Total hip replacement is recommended for end stage ONFH or in cases of failure of the index procedures [67–69]. Core decompression augmented with autologous bone marrow-derived transplantation or combined with autologous bone graft are effective in reducing symptoms of ONFH and the need for arthroplasty in the adult population [63,64]. The regenerative potential of autologous mesenchymal stem cells have been poorly investigated in the younger population, and further investigations are required.

This study certainly has limitations. The reduced number of included studies and consequently analysed procedures do not allow for the provision of accurate evidence-based recommendations. The cohort of included patients is not homogeneous in terms of pathogenesis of ONFH. Proximal femur fractures [2,29,31–33,35], sickle cell anemia [30,31,34], idiopathic causes [31], infection [33], steroid use [31], lymphocytic leukemia [31], and post-adrenal tumor excision [31] are the most common causes of ONFH reported. With regard to proximal femur fractures, transepiphyseal, transcervical, cervicotrochanteric, and intertrochanteric fractures were reported. Furthermore, most authors used the HHS for patient evaluation. However, this score has not been validated for skeletally immature patients. When considering paediatric populations, child-friendly patient reported outcomes measures (PROMs) should be used. Most of the included studies were retrospective, with the lack of a control group and limited information. Given the lack of quantitative data, bilaterality of ONFH it was not possible to investigate separately. Finally, articles concern-

ing Perthes disease have been excluded, as the management of these patients has been extensively analysed in the literature [70–82], and evidence on non-Perthes related ONFH is limited. Two studies which have been included for analysis reported data on patients with Perthes disease [31,33]; however, since the authors reported the results separately, data from patients with Perthes disease were not considered. Ko et al. [31] included for analysis 12 patients (13 hips). Of them, nine patients (nine hips) were affected by Perthes disease, and three patients (four hips) by idiopathic ONFH. In the present study, only the patients with idiopathic ONFH were considered for analysis. Current evidence on the surgical management of ONFH in skeletally immature patients is hence very limited. Therefore, larger studies should be undertaken to establish clearer indications and protocols in the paediatric population.

5. Conclusions

Several surgical techniques are available and effective for the management of ONFH in skeletally immature patients. This study evidenced high heterogeneity of the surgical procedures and eligibility criteria. Further high-quality investigations are required to establish proper indications and surgical modalities.

Author Contributions: F.M. conception and design, drafting, final approval; N.M.: supervision, revision, final approval; E.T.: supervision, final approval; F.O.: supervision, final approval; F.H.: supervision, final approval; G.L.P.: interpretation of the data, drafting, final approval. All authors have read and agreed to the published version of the manuscript.

Funding: The authors received no financial support for the research, authorship, and/or publication of this article.

Institutional Review Board Statement: Not applicable.

Informed Consent Statement: Not applicable.

Data Availability Statement: The datasets generated during and/or analysed during the current study are available throughout the manuscript.

Conflicts of Interest: The authors declare that they do not have any competing interests.

Abbreviations

Harris Hip Score (HHS), Coleman Methodology Score (CMS), osteonecrosis of the femoral head (ONFH).

References

1. Krahn, T.H.; Canale, S.T.; Beaty, J.H.; Warner, W.C.; Lourenco, P. Long-term follow-up of patients with avascular necrosis after treatment of slipped capital femoral epiphysis. *J. Pediatr. Orthop.* **1993**, *13*, 154–158. [[PubMed](#)]
2. Bartonicek, J.; Vavra, J.; Bartoska, R. Operative treatment of avascular necrosis of the femoral head after slipped capital femoral epiphysis. *Arch. Orthop. Trauma Surg.* **2011**, *131*, 497–502. [[CrossRef](#)] [[PubMed](#)]
3. Boardman, M.J.; Herman, M.J.; Buck, B.; Pizzutillo, P.D. Hip fractures in children. *J. Am. Acad. Orthop. Surg.* **2009**, *17*, 162–173. [[CrossRef](#)] [[PubMed](#)]
4. Pinto, D.A.; Aroojis, A. Fractures of the Proximal Femur in Childhood: A Review. *Indian J. Orthop.* **2021**, *55*, 23–34. [[CrossRef](#)]
5. Ferguson, A.B., Jr. Segmental vascular changes in the femoral head in children and adults. *Clin. Orthop. Relat. Res.* **1985**, *200*, 291–298. [[CrossRef](#)]
6. Trueta, J. The normal vascular anatomy of the human femoral head during growth. *J. Bone Joint Surg. Br.* **1957**, *39*, 358–394. [[CrossRef](#)]
7. Guerado, E.; Caso, E. The physiopathology of avascular necrosis of the femoral head: An update. *Injury* **2016**, *47*, S16–S26. [[CrossRef](#)]
8. Patterson, J.T.; Tangtiphaiboonjana, J.; Pandya, N.K. Management of Pediatric Femoral Neck Fracture. *J. Am. Acad. Orthop. Surg.* **2018**, *26*, 411–419. [[CrossRef](#)]
9. Yeraniosian, M.; Horneff, J.G.; Baldwin, K.; Hosalkar, H.S. Factors affecting the outcome of fractures of the femoral neck in children and adolescents: A systematic review. *Bone Joint J.* **2013**, *95*, 135–142. [[CrossRef](#)]

10. Wang, W.T.; Li, Y.Q.; Guo, Y.M.; Li, M.; Mei, H.B.; Shao, J.F.; Xiong, Z.; Li, J.; Canavese, F.; Chen, S.Y. Risk factors for the development of avascular necrosis after femoral neck fractures in children: A review of 239 cases. *Bone Jt. J.* **2019**, *101*, 1160–1167. [[CrossRef](#)]
11. Inan, U.; Kose, N.; Omeroglu, H. Pediatric femur neck fractures: A retrospective analysis of 39 hips. *J. Child. Orthop.* **2009**, *3*, 259–264. [[CrossRef](#)] [[PubMed](#)]
12. Jureus, J.; Geijer, M.; Tiderius, C.J.; Tagil, M. Vascular evaluation after cervical hip fractures in children: A case series of eight children examined by scintigraphy after surgery for cervical hip fracture and evaluated for development of secondary radiological changes. *J. Pediatr. Orthop. B* **2016**, *25*, 17–23. [[CrossRef](#)] [[PubMed](#)]
13. Petek, D.; Hannouche, D.; Suva, D. Osteonecrosis of the femoral head: Pathophysiology and current concepts of treatment. *EFORT Open Rev.* **2019**, *4*, 85–97. [[CrossRef](#)] [[PubMed](#)]
14. Powell, C.; Chang, C.; Naguwa, S.M.; Cheema, G.; Gershwin, M.E. Steroid induced osteonecrosis: An analysis of steroid dosing risk. *Autoimmun. Rev.* **2010**, *9*, 721–743. [[CrossRef](#)] [[PubMed](#)]
15. Ibrahim, T.; Little, D.G. The Pathogenesis and Treatment of Legg-Calve-Perthes Disease. *JBJS Rev.* **2016**, *4*, e4. [[CrossRef](#)]
16. Divi, S.N.; Bielski, R.J. Legg-Calve-Perthes Disease. *Pediatr. Ann.* **2016**, *45*, e144–e149. [[CrossRef](#)]
17. Mallet, C.; Abitan, A.; Vidal, C.; Holvoet, L.; Mazda, K.; Simon, A.L.; Ilharreborde, B. Management of osteonecrosis of the femoral head in children with sickle cell disease: Results of conservative and operative treatments at skeletal maturity. *J. Child. Orthop.* **2018**, *12*, 47–54. [[CrossRef](#)]
18. Milner, P.F.; Kraus, A.P.; Sebes, J.I.; Sleeper, L.A.; Dukes, K.A.; Embury, S.H.; Bellevue, R.; Koshy, M.; Moohr, J.W.; Smith, J. Sickle cell disease as a cause of osteonecrosis of the femoral head. *N. Engl. J. Med.* **1991**, *325*, 1476–1481. [[CrossRef](#)]
19. Barr, R.D.; Sala, A. Osteonecrosis in children and adolescents with cancer. *Pediatr. Blood Cancer* **2008**, *50*, 483–485. [[CrossRef](#)]
20. Mattano, L.A., Jr.; Sather, H.N.; Trigg, M.E.; Nachman, J.B. Osteonecrosis as a complication of treating acute lymphoblastic leukemia in children: A report from the Children’s Cancer Group. *J. Clin. Oncol.* **2000**, *18*, 3262–3272. [[CrossRef](#)]
21. Gaughan, D.M.; Mofenson, L.M.; Hughes, M.D.; Seage, G.R., 3rd; Ciupak, G.L.; Oleske, J.M.; Pediatric, A.C.T.G.P.T. Osteonecrosis of the hip (Legg-Calve-Perthes disease) in human immunodeficiency virus-infected children. *Pediatrics* **2002**, *109*, E74. [[CrossRef](#)] [[PubMed](#)]
22. Glesby, M.J.; Hoover, D.R.; Vaamonde, C.M. Osteonecrosis in patients infected with human immunodeficiency virus: A case-control study. *J. Infect. Dis.* **2001**, *184*, 519–523. [[CrossRef](#)] [[PubMed](#)]
23. Katz, K.; Horev, G.; Grunebaum, M.; Yosipovitch, Z. The natural history of osteonecrosis of the femoral head in children and adolescents who have Gaucher disease. *J. Bone Jt. Surg. Am.* **1996**, *78*, 14–19. [[CrossRef](#)] [[PubMed](#)]
24. Te Winkel, M.L.; Pieters, R.; Wind, E.J.; Bessems, J.H.; van den Heuvel-Eibrink, M.M. Management and treatment of osteonecrosis in children and adolescents with acute lymphoblastic leukemia. *Haematologica* **2014**, *99*, 430–436. [[CrossRef](#)] [[PubMed](#)]
25. Howick, J.; Chalmers, I.; Glasziou, P.; Greenhalgh, T.; Heneghan, C.; Liberati, A.; Moschetti, I.; Phillips, B.; Thornton, H.; Goddard, O.; et al. The 2011 Oxford CEBM Levels of Evidence. Oxford Centre for Evidence-Based Medicine. Available online: <https://www.cebm.net/index.aspx?o=5653> (accessed on 12 January 2021).
26. Page, M.J.; McKenzie, J.E.; Bossuyt, P.M.; Boutron, I.; Hoffmann, T.C.; Mulrow, C.D.; Shamseer, L.; Tetzlaff, J.M.; Akl, E.A.; Brennan, S.E.; et al. The PRISMA 2020 statement: An updated guideline for reporting systematic reviews. *BMJ* **2021**, *372*, n71. [[CrossRef](#)] [[PubMed](#)]
27. Harris, W.H. Traumatic arthritis of the hip after dislocation and acetabular fractures: Treatment by mold arthroplasty. An end-result study using a new method of result evaluation. *J. Bone Jt. Surg. Am.* **1969**, *51*, 737–755. [[CrossRef](#)]
28. Coleman, B.D.; Khan, K.M.; Maffulli, N.; Cook, J.L.; Wark, J.D. Studies of surgical outcome after patellar tendinopathy: Clinical significance of methodological deficiencies and guidelines for future studies. *Scand. J. Med. Sci. Sports* **2000**, *10*, 2–11. [[CrossRef](#)]
29. Bartonicek, J.; Vavra, J.; Bartoska, R.; Havranek, P. Operative treatment of avascular necrosis of the femoral head after proximal femur fractures in adolescents. *Int. Orthop.* **2012**, *36*, 149–157. [[CrossRef](#)]
30. Gatin, L.; Rogier de Mare, A.; Mary, P.; Vialle, R.; Damsin, J.P. Osteonecrosis of the Femoral Head: A Proposed New Treatment in Homozygous Sickle Cell Disease. *Hemoglobin* **2016**, *40*, 1–9. [[CrossRef](#)]
31. Ko, J.Y.; Meyers, M.H.; Wenger, D.R. “Trapdoor” procedure for osteonecrosis with segmental collapse of the femoral head in teenagers. *J. Pediatr. Orthop.* **1995**, *15*, 7–15. [[CrossRef](#)]
32. Li, Z.-Q.; Chen, D.; Chen, Z.; Wei, Q.-S.; Fang, B.; Zhang, Q.; He, W.; Chen, P. Treatment of collapsed traumatic osteonecrosis of the femoral head in adolescents using non-vascularized bone grafting via the trapdoor procedure. *Int. J. Clin. Exp. Med.* **2018**, *11*, 7830–7838.
33. Notzli, H.P.; Chou, L.B.; Ganz, R. Open-reduction and intertrochanteric osteotomy for osteonecrosis and extrusion of the femoral head in adolescents. *J. Pediatr. Orthop.* **1995**, *15*, 16–20. [[CrossRef](#)] [[PubMed](#)]
34. Novais, E.N.; Sankar, W.N.; Wells, L.; Carry, P.M.; Kim, Y.J. Preliminary Results of Multiple Epiphyseal Drilling and Autologous Bone Marrow Implantation for Osteonecrosis of the Femoral Head Secondary to Sickle Cell Disease in Children. *J. Pediatr. Orthop.* **2015**, *35*, 810–815. [[CrossRef](#)] [[PubMed](#)]
35. Zhang, C.Q.; Sun, Y.; Chen, S.B.; Jin, D.X.; Sheng, J.G.; Cheng, X.G.; Xu, J.; Zeng, B.F. Free vascularised fibular graft for post-traumatic osteonecrosis of the femoral head in teenage patients. *J. Bone Jt. Surg. Br.* **2011**, *93*, 1314–1319. [[CrossRef](#)]
36. Rajpura, A.; Wright, A.C.; Board, T.N. Medical management of osteonecrosis of the hip: A review. *Hip Int.* **2011**, *21*, 385–392. [[CrossRef](#)]

37. Cohen-Rosenblum, A.; Cui, Q. Osteonecrosis of the Femoral Head. *Orthop. Clin. N. Am.* **2019**, *50*, 139–149. [[CrossRef](#)]
38. Musso, E.S.; Mitchell, S.N.; Schink-Ascani, M.; Bassett, C.A. Results of conservative management of osteonecrosis of the femoral head. A retrospective review. *Clin. Orthop. Relat. Res.* **1986**, *207*, 209–215. [[CrossRef](#)]
39. Klumpp, R.; Trevisan, C. Aseptic osteonecrosis of the hip in the adult: Current evidence on conservative treatment. *Clin. Cases Miner. Bone Metab.* **2015**, *12*, 39–42. [[CrossRef](#)]
40. Mont, M.A.; Carbone, J.J.; Fairbank, A.C. Core decompression versus nonoperative management for osteonecrosis of the hip. *Clin. Orthop. Relat. Res.* **1996**, *324*, 169–178. [[CrossRef](#)]
41. Castro, F.P., Jr.; Barrack, R.L. Core decompression and conservative treatment for avascular necrosis of the femoral head: A meta-analysis. *Am. J. Orthop.* **2000**, *29*, 187–194.
42. Nwachukwu, B.U.; Chang, B.; Rotter, B.Z.; Kelly, B.T.; Ranawat, A.S.; Nawabi, D.H. Minimal Clinically Important Difference and Substantial Clinical Benefit After Revision Hip Arthroscopy. *Arthroscopy* **2018**, *34*, 1862–1868. [[CrossRef](#)] [[PubMed](#)]
43. Nwachukwu, B.U.; Beck, E.C.; Kunze, K.N.; Chahla, J.; Rasio, J.; Nho, S.J. Defining the Clinically Meaningful Outcomes for Arthroscopic Treatment of Femoroacetabular Impingement Syndrome at Minimum 5-Year Follow-up. *Am. J. Sports Med.* **2020**, *48*, 901–907. [[CrossRef](#)] [[PubMed](#)]
44. Schuenke, M.; Schulte, E.; Schumacher, U.; Ross, L.; Lampert, E. Lower Limb-Bones, Ligaments, and Joints: 1.15 The Development of the Hip Joint. In *General Anatomy and Musculoskeletal System—Latin Nomencl (THIEME Atlas of Anatomy)*; Thieme Medical Publishers: New York, NY, USA, 2011.
45. Scheuer, L.; MacLaughlin-Black, S. The lower limb. In *The Juvenile Skeleton*; Academic Press: Cambridge, MA, USA, 2004.
46. Palomares Cabeza, V.; Hoogduijn, M.J.; Kraaijeveld, R.; Franquesa, M.; Witte-Bouma, J.; Wolvius, E.B.; Farrell, E.; Brama, P.A.J. Pediatric Mesenchymal Stem Cells Exhibit Immunomodulatory Properties Toward Allogeneic T and B Cells Under Inflammatory Conditions. *Front. Bioeng. Biotechnol.* **2019**, *7*, 142. [[CrossRef](#)] [[PubMed](#)]
47. Ball, L.M.; Bernardo, M.E.; Locatelli, F.; Egeler, R.M. Potential role of mesenchymal stromal cells in pediatric hematopoietic SCT. *Bone Marrow Transplant.* **2008**, *42*, S60–S66. [[CrossRef](#)]
48. Giuliani, N.; Lisignoli, G.; Magnani, M.; Racano, C.; Bolzoni, M.; Dalla Palma, B.; Spolzino, A.; Manferdini, C.; Abati, C.; Toscani, D.; et al. New insights into osteogenic and chondrogenic differentiation of human bone marrow mesenchymal stem cells and their potential clinical applications for bone regeneration in pediatric orthopaedics. *Stem Cells Int.* **2013**, *2013*, 312501. [[CrossRef](#)]
49. Mithoefer, K.; Saris, D.B.; Farr, J.; Kon, E.; Zaslav, K.; Cole, B.J.; Ranstam, J.; Yao, J.; Shive, M.; Levine, D.; et al. Guidelines for the Design and Conduct of Clinical Studies in Knee Articular Cartilage Repair: International Cartilage Repair Society Recommendations Based on Current Scientific Evidence and Standards of Clinical Care. *Cartilage* **2011**, *2*, 100–121. [[CrossRef](#)]
50. Li, M.; Ma, Y.; Fu, G.; Zhang, R.; Li, Q.; Deng, Z.; Zheng, M.; Zheng, Q. 10-year follow-up results of the prospective, double-blinded, randomized, controlled study on autologous bone marrow buffy coat grafting combined with core decompression in patients with avascular necrosis of the femoral head. *Stem Cell Res. Ther.* **2020**, *11*, 287. [[CrossRef](#)]
51. Urbaniak, J.R.; Coogan, P.G.; Gunneson, E.B.; Nunley, J.A. Treatment of osteonecrosis of the femoral head with free vascularized fibular grafting. A long-term follow-up study of one hundred and three hips. *J. Bone Jt. Surg. Am.* **1995**, *77*, 681–694. [[CrossRef](#)]
52. Korompilias, A.V.; Beris, A.E.; Lykissas, M.G.; Kostas-Agnantis, I.P.; Soucacos, P.N. Femoral head osteonecrosis: Why choose free vascularized fibula grafting. *Microsurgery* **2011**, *31*, 223–228. [[CrossRef](#)]
53. Lau, H.W.; Wong, K.C.; Ho, K.; Chung, K.Y.; Chiu, W.K.; Kumta, S.M. Long-term outcome of vascularized iliac bone grafting for osteonecrosis of femoral head: A retrospective study with 17-year follow-up. *J. Orthop. Surg.* **2021**, *29*, 2309499021996842. [[CrossRef](#)]
54. Mont, M.A.; Einhorn, T.A.; Sponseller, P.D.; Hungerford, D.S. The trapdoor procedure using autogenous cortical and cancellous bone grafts for osteonecrosis of the femoral head. *J. Bone Jt. Surg. Br.* **1998**, *80*, 56–62. [[CrossRef](#)]
55. Hannouche, D.; Devriese, F.; Delambre, J.; Zadegan, F.; Tourabaly, I.; Sedel, L.; Chevret, S.; Nizard, R. Ceramic-on-ceramic THA Implants in Patients Younger Than 20 Years. *Clin. Orthop. Relat. Res.* **2016**, *474*, 520–527. [[CrossRef](#)] [[PubMed](#)]
56. Mont, M.A.; Seyler, T.M.; Plate, J.F.; Delanois, R.E.; Parvizi, J. Uncemented total hip arthroplasty in young adults with osteonecrosis of the femoral head: A comparative study. *J. Bone Jt. Surg. Am.* **2006**, *88*, 104–109. [[CrossRef](#)]
57. Daras, M.; Macaulay, W. Total hip arthroplasty in young patients with osteoarthritis. *Am. J. Orthop.* **2009**, *38*, 125–129.
58. Ito, H.; Tanino, H.; Yamanaka, Y.; Nakamura, T.; Takahashi, D.; Minami, A.; Matsuno, T. Long-term results of conventional varus half-wedge proximal femoral osteotomy for the treatment of osteonecrosis of the femoral head. *J. Bone Jt. Surg. Br.* **2012**, *94*, 308–314. [[CrossRef](#)]
59. Sakano, S.; Hasegawa, Y.; Torii, Y.; Kawasaki, M.; Ishiguro, N. Curved intertrochanteric varus osteotomy for osteonecrosis of the femoral head. *J. Bone Jt. Surg. Br.* **2004**, *86*, 359–365. [[CrossRef](#)]
60. Sugioka, Y. Transstrochanteric anterior rotational osteotomy of the femoral head in the treatment of osteonecrosis affecting the hip: A new osteotomy operation. *Clin. Orthop. Relat. Res.* **1978**, *130*, 191–201. [[CrossRef](#)]
61. Leibold, C.S.; Schmaranzer, F.; Siebenrock, K.A.; Steppacher, S.D. Femoral osteotomies for the treatment of avascular necrosis of the femoral head. *Oper. Orthop. Traumatol.* **2020**, *32*, 116–126. [[CrossRef](#)]
62. Zalavras, C.G.; Lieberman, J.R. Osteonecrosis of the femoral head: Evaluation and treatment. *J. Am. Acad. Orthop. Surg.* **2014**, *22*, 455–464. [[CrossRef](#)]

63. Migliorini, F.; Maffulli, N.; Baroncini, A.; Eschweiler, J.; Tingart, M.; Betsch, M. Failure and progression to total hip arthroplasty among the treatments for femoral head osteonecrosis: A Bayesian network meta-analysis. *Br. Med. Bull.* **2021**, *138*, 112–125. [[CrossRef](#)]
64. Migliorini, F.; Maffulli, N.; Eschweiler, J.; Tingart, M.; Baroncini, A. Core decompression isolated or combined with bone marrow-derived cell therapies for femoral head osteonecrosis. *Expert Opin. Biol. Ther.* **2021**, *21*, 423–430. [[CrossRef](#)] [[PubMed](#)]
65. Hua, K.C.; Yang, X.G.; Feng, J.T.; Wang, F.; Yang, L.; Zhang, H.; Hu, Y.C. The efficacy and safety of core decompression for the treatment of femoral head necrosis: A systematic review and meta-analysis. *J. Orthop. Surg. Res.* **2019**, *14*, 306. [[CrossRef](#)] [[PubMed](#)]
66. Gangji, V.; Hauzeur, J.P. Treatment of osteonecrosis of the femoral head with implantation of autologous bone-marrow cells. Surgical technique. *J. Bone Jt. Surg. Am.* **2005**, *87*, 106–112. [[CrossRef](#)]
67. Osawa, Y.; Seki, T.; Morita, D.; Takegami, Y.; Okura, T.; Ishiguro, N. Total Hip Arthroplasty After Transtrochanteric Rotational Osteotomy for Osteonecrosis of the Femoral Head: A Mean 10-Year Follow-Up. *J. Arthroplast.* **2017**, *32*, 3088–3092. [[CrossRef](#)]
68. Shigemura, T.; Yamamoto, Y.; Murata, Y.; Sato, T.; Tsuchiya, R.; Mizuki, N.; Toki, Y.; Wada, Y. Total hip arthroplasty after failed transtrochanteric rotational osteotomy for osteonecrosis of the femoral head: A systematic review and meta-analysis. *Orthop. Traumatol. Surg. Res.* **2018**, *104*, 1163–1170. [[CrossRef](#)]
69. Wang, T.I.; Hung, S.H.; Su, Y.P.; Feng, C.Q.; Chiu, F.Y.; Liu, C.L. Noncemented total hip arthroplasty for osteonecrosis of the femoral head in elderly patients. *Orthopedics* **2013**, *36*, e271–e275. [[CrossRef](#)] [[PubMed](#)]
70. Maleki, A.; Qoreishy, S.M.; Bahrami, M.N. Surgical Treatments for Legg-Calve-Perthes Disease: Comprehensive Review. *Interact. J. Med. Res.* **2021**, *10*, e27075. [[CrossRef](#)]
71. Hefti, F.; Clarke, N.M. The management of Legg-Calve-Perthes' disease: Is there a consensus?: A study of clinical practice preferred by the members of the European Paediatric Orthopaedic Society. *J. Child. Orthop.* **2007**, *1*, 19–25. [[CrossRef](#)]
72. Volpon, J.B. Comparison between innominate osteotomy and arthrodistraction as a primary treatment for Legg-Calve-Perthes disease: A prospective controlled trial. *Int. Orthop.* **2012**, *36*, 1899–1905. [[CrossRef](#)]
73. Vukasinovic, Z.; Slavkovic, S.; Milickovic, S.; Sijeca, A. Combined salter innominate osteotomy with femoral shortening versus other methods of treatment for Legg-Calve-Perthes disease. *J. Pediatr. Orthop. B* **2000**, *9*, 28–33. [[CrossRef](#)]
74. Herring, J.A. Legg-Calve-Perthes disease at 100: A review of evidence-based treatment. *J. Pediatr. Orthop.* **2011**, *31*, S137–S140. [[CrossRef](#)] [[PubMed](#)]
75. Braito, M.; Wolf, S.; Dammerer, D.; Giesinger, J.; Wansch, J.; Biedermann, R. Global differences in the treatment of Legg-Calve-Perthes disease: A comprehensive review. *Arch. Orthop. Trauma Surg.* **2021**, *141*, 1–16. [[CrossRef](#)] [[PubMed](#)]
76. Galloway, A.M.; van-Hille, T.; Perry, D.C.; Holton, C.; Mason, L.; Richards, S.; Siddle, H.J.; Comer, C. A systematic review of the non-surgical treatment of Perthes' disease. *Bone Jt. Open* **2020**, *1*, 720–730. [[CrossRef](#)]
77. Leo, D.G.; Leong, W.Y.; Gambling, T.; Long, A.; Murphy, R.; Jones, H.; Perry, D.C. The outcomes of Perthes' disease of the hip: A study protocol for the development of a core outcome set. *Trials* **2018**, *19*, 374. [[CrossRef](#)] [[PubMed](#)]
78. Price, C.T.; Thompson, G.H.; Wenger, D.R. Containment methods for treatment of Legg-Calve-Perthes disease. *Orthop. Clin. N. Am.* **2011**, *42*, 329–340. [[CrossRef](#)] [[PubMed](#)]
79. Wenger, D.R.; Pandya, N.K. Advanced containment methods for the treatment of Perthes disease: Salter plus varus osteotomy and triple pelvic osteotomy. *J. Pediatr. Orthop.* **2011**, *31*, S198–S205. [[CrossRef](#)]
80. Futami, T.; Suzuki, S. Different methods of treatment related to the bilateral occurrence of Perthes' disease. *J. Bone Jt. Surg. Br.* **1997**, *79*, 979–982. [[CrossRef](#)]
81. Aly, T.A.; Amin, O.A. Arthrodiastasis for the treatment of Perthes' disease. *Orthopedics* **2009**, *32*, 817. [[CrossRef](#)]
82. Kotilingam, D.; Sherlock, D.; Rosenstein, A. Treatment options for symptomatic degenerative joint disease secondary to Legg-Calve-Perthes disease. *Am. J. Orthop.* **2011**, *40*, E10–E13.