

# 'Study of the maxillary yaw on cone beam computed tomography: A preliminary report and comparison between two different dento-skeletal malocclusions'

R. A. Vernucci<sup>1,2</sup>  | L. Da Mommio<sup>1</sup> | V. Vellone<sup>1</sup>  | A. De Stefano<sup>1</sup>  | E. Barbato<sup>1</sup>  |  
R. Di Giorgio<sup>1,2</sup>  | G. Galluccio<sup>1</sup> 

<sup>1</sup>Department of Oral and Maxillofacial Sciences, School of Dentistry, 'Sapienza' University of Rome, Rome, Italy

<sup>2</sup>Department of Sense Organs, 'Sapienza' University of Rome, Rome, Italy

## Correspondence

R. A. Vernucci, Viale del Policlinico, 155-00161 Rome, Italy.

Email: [roberto.vernucci@uniroma1.it](mailto:roberto.vernucci@uniroma1.it)

## Abstract

**Objectives:** To assess the skeletal and dental maxillary transverse compensation (yaw) on the cone beam computed tomography (CBCT) three-dimensional reconstructed image of the skull in two groups of patients, both clinically affected by a class III malocclusion with deviation of the lower midline.

**Materials and Methods:** An observational retrospective study was designed to analyse differences in two groups of patients, the first one was composed by patients affected by horizontal condylar hyperplasia, the second one by patients affected by dento-skeletal asymmetric class III malocclusion. Each group was composed by 15 patients. Transverse analysis was performed by measuring five landmarks (three bilateral and two uneven) with respect to a mid-sagittal plane; sagittal analysis was performed by measuring the sagittal distance on the mid-sagittal plane between bilateral points. Means were compared through inferential analysis.

**Results:** In the condylar hyperplasia group, all differences between the two sides were not statistically significant, nor for canines' difference ( $P = .0817$ ), for molars ( $P = .1105$ ) or for jugular points ( $.05871$ ). In the class III group, the differences between the two sides were statistically significant for molars ( $P = .0019$ ) and jugular points ( $P = .0031$ ) but not for canines ( $P = .1158$ ). Comparing the two groups, significant differences were found only for incisors' midline deviation ( $P = .0343$ ) and canine ( $P = .0177$ ).

**Conclusion:** The study of the yaw on CBCT should be integrated into three-dimensional cephalometry and could help in differentiating the various malocclusion patterns.

## KEYWORDS

class III, cone beam CT, facial asymmetry, three-dimensional cephalometrics, unilateral condylar hyperplasia

This is an open access article under the terms of the [Creative Commons Attribution](https://creativecommons.org/licenses/by/4.0/) License, which permits use, distribution and reproduction in any medium, provided the original work is properly cited.

© 2023 The Authors. *Orthodontics & Craniofacial Research* published by John Wiley & Sons Ltd.

## 1 | INTRODUCTION

The pathological rotation of the cranio-facial complex around a given axis may affect the physiological development during the age of growth; the greater the degree of rotation, the greater will be the contribution to the malocclusion. Pathological rotations on the sagittal (pitch) and on the frontal plane (roll), both from the clinical and from the cephalometric point of view, are well known: pitch may affect divergence or rotation of the occlusal, palatal, and mandibular planes, while roll may lead to maxillary canting.<sup>1</sup>

The yaw is the rotation of the maxillo-facial complex on the transverse plane and could determine a facial asymmetry with dental compensations: deviation of dental midlines, shifting of the skeletal Menton on the healthy side, occlusal class III on the affected side and class II on the contralateral. On the transverse plane, the compensation forces create distortion of the arch form, different levels of scissor bite on the affected side, buccal inclination (positive torque) of the upper teeth on the healthy side, and lingual inclination on the lower teeth, leading to cross bite on the healthy side.<sup>1-4</sup> Treatment of a yawing-dominant may often require orthognathic surgery, and, conversely, Ho et al. have reported that a correction of the yaw is needed in 60% of their surgical cases.<sup>5</sup> Modern surgical programming of these kind of malocclusions should take into account the effects of a pathological rotation on the three planes of the space, and require a three-dimensional cephalometric evaluation, including the assessment of the transverse position of the upper jaw; pre-surgical transverse orthodontic preparation could be difficult too.<sup>2,5,6</sup>

The cephalometric evaluation of the yaw on standard 2-dimensional images has always been difficult, for the limited availability of clinical data and for the technological limits of the two-dimensional cephalometric radiographs.<sup>7-9</sup> From the literature available, a maxillary yaw may cause different transverse distance between the occlusal surface of the first molars from the palatal midline, deviations of the torque values of the upper and lower molars, and positive torque of the upper molars, as consequence of the dental compensation.<sup>4,10</sup> Song et al. reported the transverse inclination of the palatal plane with respect to a mid-sagittal plane (MSP) taken as reference, and a different posterior-anterior distance between the cusps of the right and left upper canines and first molars.<sup>10</sup> Thiesen et al. reported differences of the transversal distance of the maxillo-zygomatic suture between the deviated and the contralateral side.<sup>7</sup>

The use of cone beam computed tomography (CBCT) in three-dimensional diagnosis is boosting the radiographic characterization of different types of facial asymmetry, and the protocols to measure the transverse rotation of the maxillo-facial complex are becoming fast and simple.<sup>7,11-14</sup>

In this study, we have tested a cephalometric method to assess the yaw on a CBCT three-dimensional reconstructed image of the skull, by evaluating the amount of the maxillary skeletal and dental yawing compensations in two groups of patients clinically affected by a similar malocclusion, a class III with deviation of the lower

midline. The aim of the statistical analysis was to compare the measurements of the rotating side with respect to the healthy one in each group, and to analyse if two aetiologically different types of facial asymmetry could significantly affect the transverse maxillary rotation.

## 2 | MATERIALS AND METHODS

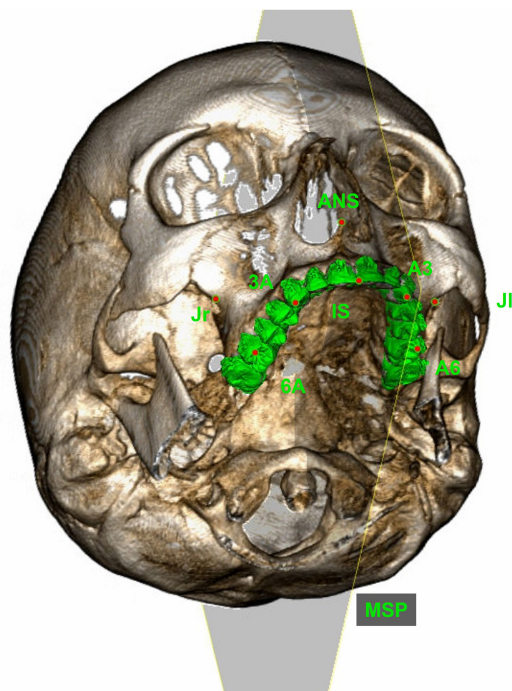
Two groups of consecutive patients were selected for this observational retrospective study among the population of patients who sought referral for orthognathic-surgical treatment in our Unit of Orthodontics in the period 2019-2021; the first one was composed by patients affected by the horizontal type of unilateral condylar hyperplasia (UCH), the second one by those affected by dento-skeletal class III with deviation of the mandibular midline. The inclusion criteria of the first group (G1) were: diagnosis of horizontal UCH and class III dental occlusion and deviation of the lower midline more than 4 mm. The diagnostic path we follow for the diagnosis of UCH consists in: anamnesis and medical history, which also includes old photographs and radiographs; clinical extra-oral and intra-oral examination, photographic records; study of plaster models; radiographic study, composed by panoramic radiograph, lateral and posterior-anterior cephalograms, now replaced by CBCT-reconstructed images; assessment of condylar functionality with TMJ MRI and electrokinesiography, if patients were affected by temporo-mandibular disorders. Condylar activity was assessed with single-photon emission computed tomography (SPECT), while canting of the occlusal plane was assessed with plaster casts mounted on articulator or on the CBCT-reconstructed three-dimensional image of the skull.

The criteria for the second group (G2) were skeletal class III with ANB angle  $<0^\circ$ , class III molar relationships and deviation of the lower midline greater than 4 mm.

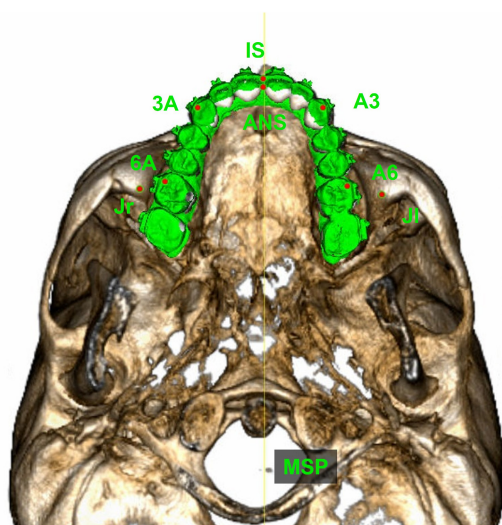
Patients with history of previous orthodontic treatments, affected by other malocclusions or syndromic were excluded. Furthermore, only patients whose CBCT was performed with the same machine (NewTom Vgi, QR srl, Verona, Italy) and the same parameters (376 slices with a  $0.3 \times 0.3 \times 0.3$  mm voxel resolution, FOV  $21 \times 19$ , tube voltage 110 kV, current 6.30 mA for each second of the scan, exposure time 5.4 s) were selected.

The protocol has provided the conversion of the pre-treatment CBCT slices in DICOM format on the cephalometric software (Dolphin version 11.95 beta, Dolphin Imaging and Management Systems, Chatsworth, CA, USA). In the three-dimensional volumetric rendering, a mid-sagittal plane (MSP) was traced as reference plane using the following cephalometric landmarks: Nasion (N), the most anterior point of the fronto-nasal suture on the sagittal plane, and more central and superior on the frontal plane; PCM, the mid-point between the posterior clinoid processes; Basion (Ba), the most anterior, lower, and central point of the large occipital foramen.<sup>15</sup>

The following landmarks, three dental and two skeletal, were identified on the maxilla (Figure 1):



**FIGURE 1** General view of the landmarks used for the study. The positioning of the dental landmarks could be improved by matching the digital models on the CBCT. See the main text for the definitions.



**FIGURE 2** Landmarks used in the study and distances measured on the maxilla, bottom view.

1. 6A/A6, the margin of the mesio-buccal cusp of the right and left upper first molar.
2. 3A/A3, the margin of the crown of the permanent right and left upper canine.
3. IS, the contact point of the upper central incisors.
4. ANS, the most anterior, medial and inferior point of the anterior nasal spine.

5. Jr/Jl points (jugular point), the most concave and central point of the right and left maxillary tuberosity.

The sagittal discrepancy on the horizontal plane between each couple of points was measured, using the MSP as reference. First, we located the digital projection of each landmark to the MSP, using the program function 'Dist. to midline', usually used to measure the perpendicular distance between a landmark and a reference plane.

The following distances were measured (Figure 2):

1. 3A-MSP: distance between the right upper canine and the MSP.
  2. A3-MSP: distance between the left upper canine and the MSP.
  3. 6A-MSP: distance between the mesio-buccal cusp of the upper right first molar and the MSP.
  4. A6-MSP: distance between the margin of the mesio-buccal cusp of the upper left first molar and the MSP.
  5. Jr-MSP: distance between the most concave and central point of the right maxillary tuberosity and MSP;
  6. Jl-MSP: distance between the most concave and central point of the left maxillary tuberosity and MSP.
  7. ANS-MSP: distance on the horizontal plane between the ANS point and the MSP.
  8. IS-PMS: distance on the horizontal plane between the contact point of the upper incisors and the MSP.
- Then, the '2D distance' function was used to measure the distance between each couple of projection points on the MSP in mm.
9. 3-3 AP: sagittal distance between the projection of the 3A and A3 on the MSP.
  10. 6-6AP: sagittal distance between the projection of the 6A and A6 on the MSP.
  11. J-J AP: sagittal distance between the projection of the Jr and Jl on the MSP.

One operator (L.D.M.) has performed all the measurements; the same operator has repeated the measurements after 1 month on 10 patients in each group in random order. Another Author (V.V.) has performed the entire protocol for the assessment of the inter-rater reliability. Dahlberg formula was calculated to evaluate the intra- and inter-rater reliability.

To properly compare measurements in the statistical analysis, we used the terms 'rotating side', represented by the side from which the rotation starts, and 'healthy side', that is the side towards the midline was shifted. Landmarks were renamed accordingly (i.e., R3, the upper canine of the rotating side; H3, the upper canine of the healthy side; similarly, R6 and H6; RJ and HJ).

As regards statistical analysis, normality of distributions was assessed with the Shapiro-Wilk test, while homogeneity of the variances was calculated with the Fisher's F test for comparisons between independent data. The means of bilateral measurements were compared to evaluate if differences between the rotating and

the healthy side could be statistically significant. Student's *t* test was used for comparisons with normal distribution and Wilcoxon sign rank test in non-normal distribution.

Means of the measurements were compared between the groups to verify, as null hypothesis (H0), that there are no statistically significant differences between the two groups. The Student's *t* test for independent data was used for normal distributions and rank sum Wilcoxon sign rank test was used for non-normal distributions. Significance was set with  $P < .05$ . The study was approved by the local Department and by the Ethical Board, protocol n.4663. Data were analysed with the R software, version 4.1.1 (<https://www.rproject.org/>).

### 3 | RESULTS

The G1 was composed of 15 patients affected by horizontal condylar hyperplasia, 12 females and three males, the mean age was 26.73 years old, SD = 5.05 (Table 1). The mean ANB angle was  $0.3^\circ$  (SD 1.6), the mean value of the Wits appraisal was 0.2 mm (SD 2.6).

The G2 was composed of 15 patients, 10 females and five males, affected by dento-skeletal class III and mandibular deviation, with a mean age of 27.07 years old, SD = 8.86. (Table 2) The mean ANB angle was  $-1.5^\circ$  (SD 1.4), the mean value of the Wits appraisal was  $-4.1$  mm (SD 1.5).

The results of the Dahlberg formula for intra-rater repeatability were found between 0.58 (measure R3-PMS) and 1.34 mm (HJ-PMS). Results of inter-rater reliability were found between 0.69 (molar of the rotating side) and 1.95 mm (HJ-PMS).

As results from descriptive analysis, in the G1 the mean distances between canine, molar and jugular points and the MSP were longer in the rotating side than in the healthy side. The ANS (mean = 2.4 mm, SD 1.4) and the upper incisors' midline (mean 2.7 mm, SD 1.7) were

rotated towards the deviated side. The mean A-P distance between canines was 2.3 mm (SD 1.4), that of first molars was 2.1 mm (SD 1.1) and that of jugular points was 2.1 mm (SD 1.3). (Table 3).

The mean distances between canine, molar and jugular points and the MSP were longer in the rotating side in the G2 too. The ANS (mean 1.9 SD 0.7) and the upper incisors' midline (1.5 SD 1.4) were rotated towards the deviated side. The mean A-P distance between canines was 1.2 mm (SD 0.6), that of first molars was 2.2 mm (SD 1) and that of jugular points was 1.7 mm (SD 1.3). (Table 3) In both groups, the difference between rotating and healthy side was higher at dental level than at the skeletal level.

The measurements between the rotating side and the healthy side were then compared in both groups with inferential statistics, to evaluate if the differences between the two sides could be significant. (Table 4) In the G1, the difference of the mean measurements of canines ( $P = .0259$ ), molars ( $P = .0271$ ) and jugular points (.0079) between rotating and healthy side were all statistically significant; in the G2 group too, the difference of the means between the two couple of measures were statistically significant for canines ( $P = .029$ ), molars ( $P < .000$ ) and jugular points ( $P = .0001$ ).

As regards the comparison between the groups, the difference of the mean age between the malocclusions examined was not statistically significant ( $P = .6472$ ), while differences of ANB angle ( $P = .0035$ ) and Wits appraisal ( $P < .000$ ) values were statistically significant. The differences between the means were not statistically significant for bilateral measurements. (Table 5) Both malocclusions produce a rotation of the ANS, with no significant difference of the mean measurements ( $P = .2226$ ), and of the upper incisors' midline, that instead was significant ( $P = .0343$ ). About the sagittal discrepancy measured on the MSP, the difference of mean measurements was significant for canines ( $P = .0177$ ), but not for molars ( $P = .9860$ ) and jugular points ( $P = .1092$ ).

TABLE 1 Demographic data of the G1 (OGS, orthognathic surgery; C, condylectomy).

Patient no.	Sex	Age (years old)	Side affected by CH	Deviated side	SPECT	ANB	Wits	Treatment
1	F	20	R	L	-	1	-1	OGS
2	F	19	L	R	-	-2	-5	OGS
3	F	38	R	L	-	-3	-1	OGS
4	F	30	L	R	-	-2	-3	OGS
5	F	25	R	L	-	2	1	OGS
6	M	27	R	L	+	0	2	C
7	F	26	L	R	+	1	2	C
8	F	27	L	R	+	0	3	C
9	M	34	R	L	-	1	3	OGS
10	F	26	L	R	-	1	2	OGS
11	F	21	R	L	+	2	-2	C
12	F	23	R	L	-	-1	-3	OGS
13	F	29	L	R	-	1	3	OGS
14	M	27	L	R	+	2	0	C
15	F	29	R	L	+	2	2	C

TABLE 2 Demographic data of the G2 (OGS, orthognathic surgery).

Patient no.	Sex	Age (years old)	Deviated side	ANB	Wits	Treatment
1	M	19	L	0	-1	OGS
2	F	55	R	-1	-4	OGS
3	F	20	L	0	-3	OGS
4	F	28	R	-2	-6	OGS
5	F	19	R	-1	-3	OGS
6	M	25	L	0	-3	OGS
7	F	24	L	-4	-7	OGS
8	M	27	R	-1	-4	OGS
9	M	29	R	-2	-3	OGS
10	F	23	R	0	-4	OGS
11	F	34	R	-3	-6	OGS
12	F	28	L	-3	-5	OGS
13	F	21	R	0	-4	OGS
14	F	24	L	-3	-4	OGS
15	M	30	L	-2	-5	OGS

## 4 | DISCUSSION

The three-dimensional description of maxillo-mandibular relationships is a key concept in modern orthodontic diagnosis, especially for patients affected by facial asymmetry, whose dento-facial malocclusion is consequence of a three-dimensional alteration of development of the maxillo-facial skeleton.<sup>1,12,14</sup> We tested the hypothesis if the asymmetric prognathism resulting from different aetiology, pattern, and rate of skeletal growth (slower in cases affected by class III, faster in patients with condylar hyperplasia) could determine the same compensatory mechanisms on the transverse plane of the maxilla, by studying both dental and skeletal cephalometric points.

UCH is a well-known cause of facial asymmetry, characterized by the progressive and self-limiting pathological hyperdevelopment of a mandibular condyle with respect to the contralateral; the skeletal and occlusal asymmetry stops when the condyle ends the pathological growth. The horizontal pattern, also known as hemimandibular elongation, is characterized by deviation of dental midline and chin towards the healthy side, crossbite on the healthy side and absence of canting of the occlusal plane. All patients of the UCH group have presented a midline deviation on the opposite side of the Hyperplasia, and the occlusal plane was not canted; these are the typical clinical features of the 'pure' horizontal pattern of the UCH. While the mandibular asymmetry could be noticed even with panoramic radiograph, CBCT is actually the gold standard for diagnosis and orthodontic-surgical programming (Figure 3).<sup>16</sup>

Different aetiological causes, often difficult to identify completely, may cause a skeletal class III malocclusion. In addition to the sagittal discrepancy, also the vertical (divergence, open bite) or the transverse alterations (cross bite, transverse maxillary underdevelopment, deviations of the mandibular midline) could give a clinical pattern of a three-dimensional malocclusion (Figure 4).<sup>11</sup> The onset

of a mandibular asymmetry in patients affected by prognathism has been also associated with the increased volume of the ipsilateral cranial base, or with lengthening of the ramus and/or of the mandibular body with respect to non-asymmetric patients.<sup>8,17</sup> The interest for the asymmetric class III malocclusion has greatly increased in the last years, and Ha et al. reported that two-thirds of class III patients who underwent orthognathic surgery were affected by some degree of facial asymmetry.<sup>11,12,14,18-20</sup> In this malocclusion pattern, maxillary yaw develops as a gradual dental compensation, in the attempt to find the best dental intercuspatation which may ensure function; especially in age of growth, the dental characteristics of the occlusion (missing teeth, premature contacts, cross bites, etc.) may affect the severity an asymmetric pattern of growth that may affect occlusion and create multiple dental compensations, if not corrected. An interceptive therapy is required in the age of growth, because both the asymmetric position and the pathological functions could lead to an asymmetric skeletal growth and to a structural mandibular asymmetry in adult patients, if not treated.<sup>8,14</sup>

From a clinical point of view, the differences useful to help in differential diagnosis are worthy of a discussion. Medical history helps to establish when patients start to feel that the lower jaw is becoming asymmetric. The growth rate of a hyperplastic condyle is faster than the normal condylar growth rate, and, besides, the unilateral growth continues beyond the age of physiological growth.<sup>21</sup>

Given the progressive nature of the UCH, the clinical picture that clinicians may observe is very different among patients; the facial asymmetry is related to the time between the onset of the hyperactivity and the first consultation, and from the speed of the condylar growth. SPECT is the examination adopted to detect differences in the growth activity of the two condyles: a difference of the radionuclide uptake between the two condyles greater than 10% will indicate active growth and SPECT will result 'positive'; when the affected condyle has ceased its growth, SPECT will not report uptake

TABLE 3 Descriptive analysis for G1 and G2.

	Measure	Mean	SD	SE	Lower 95	Upper 95	Min.	Max.
G1	ANB	0.3	1.6	0.4	-0.5	1.2	-3.0	2.0
	Wits Appraisal	0.2	2.6	0.7	-1.1	1.5	-5.0	3.0
	R3 -MSP	18.4	2.0	0.5	17.4	19.5	15.9	23.1
	H3-MSP	15.8	2.7	0.7	14.5	17.2	10.6	19.6
	R6-MSP	26.1	3.1	0.8	24.6	27.7	20.6	31.1
	H6-MSP	23.1	3.1	0.8	21.6	24.7	15.2	27.0
	RJ-MSP	44.8	2.7	0.7	43.5	46.1	41.0	47.8
	HJ-MSP	43.3	2.9	0.7	41.9	44.8	37.4	47.0
	ANS-MSP	2.4	1.4	0.4	1.7	3.1	0.1	4.7
	IS-MSP	2.7	1.7	0.4	1.8	3.5	0.2	6.1
	3-3 AP	2.3	1.4	0.4	1.5	3.0	1.0	6.3
	6-6 AP	2.1	1.1	0.3	1.6	2.7	0.3	4.1
J-J AP	2.1	1.0	0.3	1.6	2.7	0.2	4.1	
G2	ANB	-1.5	1.4	0.4	-2.2	-0.8	-4.0	0.0
	Wits appraisal	-4.1	1.5	0.4	-4.9	-3.4	-7.0	-1.0
	R3-MSP	18.2	2.4	0.6	17.0	19.5	12.3	23.0
	H3-MSP	16.1	2.8	0.7	14.7	17.5	10.1	20.3
	R6-MSP	27.4	2.0	0.5	26.4	28.5	23.5	29.4
	H6-MSP	25.0	2.1	0.5	24.0	26.1	19.7	28.1
	Jr-MSP	45.8	3.6	0.9	44.0	47.6	39.3	51.8
	Jl-MSP	43.9	3.6	0.9	42.1	45.8	37.6	51.1
	ANS-MSP	1.9	0.7	0.2	1.5	2.3	0.7	3.6
	IS-MSP	1.5	1.4	0.4	0.8	2.2	0.0	4.5
	3-3 AP	1.2	0.6	0.2	0.9	1.5	0.2	2.1
	6-6 AP	2.2	1.0	0.2	1.7	2.6	0.5	4.5
J-J AP	1.7	0.8	0.2	1.2	2.1	0.9	4.5	

TABLE 4 Results of the comparison between rotating and healthy side in each group.

Comparison	Analysis	Mean of the differences	V	T	P-value	Significance
G1						
R3-MSP vs H3-MSP	t-test	2.6267		2.4906	.0259	*
R6-MSP vs H6-MSP	t-test	2.9867		2.4672	.0271	*
RJ-MSP vs HJ-MSP	Wilcoxon signed ranks	1.4667	84		.0079	*
G2						
R3-MSP vs H3-MSP	t-test	2.1333		2.4329	.0290	*
R6-MSP vs H6-MSP	Wilcoxon signed ranks	2.3933	120		<.000	*
RJ-MSP vs HJ-MSP	t-test	1.8467		5.2749	.0001	*

\*Significant for  $P < .05$ .

differences between the two sides and will result as 'negative'. Some types of Class III malocclusion with severe bilateral mandibular overgrowth were considered as a type of bilateral condylar hyperplasia in the Wolford's classification and, in this case, SPECT cannot help in diagnosis.<sup>22</sup>

Besides, the radiographic characterization of the morphology of condyles, along with the comparison between hyperplastic and healthy condyle, could help in differential diagnosis.

From the raw data, both groups present a distortion of the upper arch symmetry towards the healthy side, both of dental both of

TABLE 5 Comparison between groups; results of the inferential analysis.

Comparison G1 vs G2	Analysis	W	t	P-value	Significance
Age	Wilcoxon rank sum	123.5		.6472	
ANB	Wilcoxon rank sum			.0035	*
Wits appraisal	t-test		5.6362	<.000	*
R3 -MSP	t-test		0.2525	.8025	
H3-MSP	t-test		-0.2868	.7764	
R6-MSP	Wilcoxon rank sum	135		.3505	
H6-MSP	t-test		-1.9854	.0570	
RJ-MSP	Wilcoxon rank sum	133		.3951	
HJ-MSP	t-test		-0.4898	.6281	
ANS-MSP	t-test		1.2556	.2226	
IS-MSP	Wilcoxon rank sum	163.5		.0343	*
3-3 AP	Wilcoxon rank sum	169.5		.0177	*
6-6 AP	t-test		-0.0178	.9860	
J-J AP	Wilcoxon rank sum	151		.1092	

\*Significant for  $P < .05$ .

skeletal points, as result of dental compensation of the mandibular growth. While the dental compensations of the pathological rotation may be present, a skeletal yaw is rare, however.<sup>1</sup> Dental measurements are obviously affected also by the characteristics of the dental malocclusion of every patient, such as rotations, ectopias or cross-bites.<sup>7</sup>

In the condylar hyperplasia group, the rotation on the transverse plane occurs mainly at the canine level, but the difference between rotating and healthy side was not significant. In the class III group, the difference of measurements between rotating and healthy side, both at skeletal and at first molars' level, was found significant. We suppose that the different speed in the expression of the pathogenetic factors and the different force vectors acting during the rotation could explain these differences. In a class III malocclusion, the slow and prolonged expression of the aetiopathogenetic factors leads the upper maxilla to 'follow' the altered mandibular growth, in the attempt to maintain an overall occlusal balance. In UCH, the speed of the unilateral hyperdevelopment does not allow the maxilla to compensate promptly, and the different distance at canine level could be related to a faster action of compensation forces on canines and on the anterior sector, compared to first molars and jugular points. Lee et al. found that, in patients affected by skeletal class III and asymmetry, canines and first upper molars undergo a buccal inclination on the deviated side more significant than the distance between teeth and the MSP.<sup>6</sup> Noh and Park found a significant difference of the anterior-posterior position of the maxillary points, but this difference was only of 0.65 mm, and confirmed that the transverse

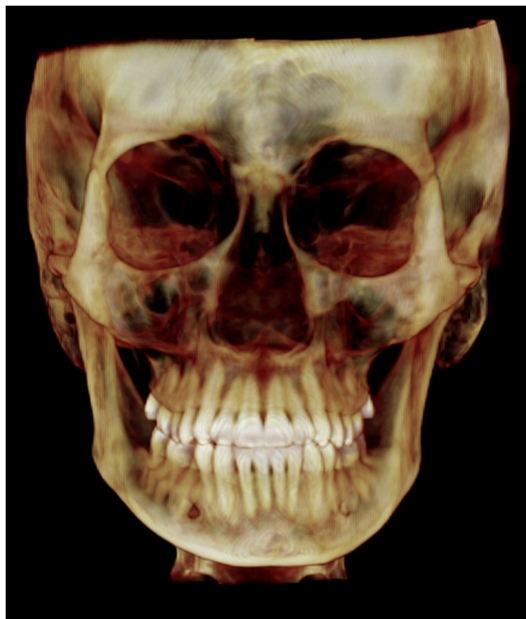
movement of the maxilla towards the healthy side was larger than the sagittal compensation.<sup>20</sup>

In contrast with our findings, Udomlarphat et al. reported shorter distance between the deviating side and the MSP, compared to the healthy side.<sup>23</sup> The differences in findings demonstrate that the characterization of the various rotation patterns is far to be perfectly described by three-dimensional cephalometry, for technical and methodological reasons, and because the links between the different aetiological causes and the resulting patterns of asymmetry are not completely explained.<sup>8,11,12,14</sup>

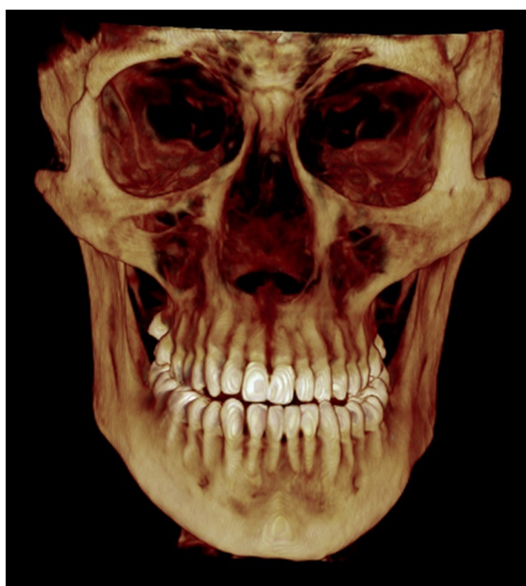
Both the examined malocclusions may produce a deviation of the anterior nasal spine and the upper incisors' midline towards the healthy side, as consequence of the rotation on the transverse plane, and our findings agree with the literature.<sup>3,10</sup> We found greater mean deviation of the upper inter-incisor line in the CH group, but the difference was not statistically significant.

Song et al. confirmed that yaw is not only characterized with a translation, but also with a rotation, given by the different sagittal position of right and left canines and first molars, with a more posterior position in the deviated side.<sup>10</sup> We have measured the difference in the sagittal position between bilateral points (right and left upper canines, first molars, and jugular points) as the sagittal distance between the projections on the MSP.

About differences between the two malocclusions, the difference of the mean age between the two groups was not statistically significant. We have found a significant difference of the mean values of the ANB angle and of the Wits appraisal. This finding may suggest a greater growth stimulus in the sagittal axis in the class III



**FIGURE 3** CBCT reconstructed panoramic and three-dimensional image of a patient, affected by active right horizontal UCH, involved in the study: the dental midline and chin are deviated towards the healthy side without involvement of the occlusal plane. Dental compensations are present, especially on the transverse plane.



**FIGURE 4** CBCT reconstructed panoramic and three-dimensional image of a patient involved in the study, affected by asymmetric class III. In the second group the sagittal discrepancy may be greater with respect to the first group. The sagittal discrepancy increases the severity of the lateral cross bite.

group, compared to UCH. The sagittal skeletal discrepancy should be considered as a major element in the differential diagnosis between UCH asymmetric skeletal class III, as patients suffering from horizontal UCH have a less severe sagittal relationship.

The sagittal position of the bilateral points was different in both groups, but the difference between groups was not statistically significant. Only differences of the mean length in the transverse plane of jugular and first molars' position were significant. Therefore, both malocclusions generate a similar compensative rotation of the upper jaw, but not the same effects on the transverse plane.

The study has various limitations. The low sample numerosity was influenced by the low prevalence of the horizontal UCH, although we have tried to minimize the selection biases.

Finally, we have chosen an anatomic MSP as reference in the three-dimensional environment, currently used for diagnosis and surgical programming, identified by median landmarks which are not influenced by the skull base asymmetry or by the position variations of the Porion.<sup>7,13,15</sup> We used as reference a MSP, but a universal reference that can be used for all patients does not still exist.<sup>7</sup> The clear theoretical superiority of three-dimensional assessments needs an important work to establish the accuracy and precision of landmarks and measurements. In the method tested, the results of intra- and inter-rater reliability have reported higher errors for skeletal landmarks, confirming that the jugular points, as all concave landmarks, are often difficult to locate on CBCT. Dental points are instead more reliable, and their positioning could be improved by matching the digital models on the CBCT. The landmark identification on the cephalometric software requires a learning curve by operators and could be influenced by clinical experience; for this reason, we used landmarks easy to locate in order to improve repeatability and enhance the routine use in common cephalometric analysis.<sup>13</sup>

## 5 | CONCLUSIONS

The CBCT cephalometric study of the maxillary jaw should be integrated in a comprehensive cephalometric description of the three-dimensional position of jaws that includes sagittal (pitch) and vertical (roll) rotations. The method we have chosen should be tested in other types of facial asymmetry, such as vertical condylar hyperplasia or hemifacial microsomia, for a better radiological characterization of facial asymmetries in the three planes of space.

When a transverse rotation occurs, the upper jaw adapts itself rotating in the same direction of the lateral deviation. Cephalometry could help to differentiate the various malocclusion patterns: when the malocclusion develops slowly, compensations are more visible at the skeletal level than the dental, while in a rapid development, dental compensation prevails.

## AUTHOR CONTRIBUTIONS

VRA: Writing—Original draft preparation, formal analysis, methodology. DML: Writing—Original draft preparation. VV: Investigation, Resources, Visualization. DSA: writing—reviewing and editing. BE: Investigation, Supervision. DGR: investigation, conceptualization. GG: methodology, supervision.



## ACKNOWLEDGEMENTS

The authors would thank Dr. Biagia Elisabetta Perrucci and Mr. Gabriele Monachesi for the help in improving the text. Open Access Funding provided by Università degli Studi di Roma La Sapienza within the CRUI-CARE Agreement.

## CONFLICT OF INTEREST STATEMENT

Potential sources of conflict of interest: none for all authors.

## DATA AVAILABILITY STATEMENT

Data available on request from the authors.

## ORCID

R. A. Vernucci  <https://orcid.org/0000-0002-3412-0030>

V. Vellone  <https://orcid.org/0000-0001-6048-1190>

A. De Stefano  <https://orcid.org/0000-0001-5115-3582>

E. Barbato  <https://orcid.org/0000-0002-5328-3580>

R. Di Giorgio  <https://orcid.org/0000-0002-7416-5970>

G. Galluccio  <https://orcid.org/0000-0002-6876-8839>

## REFERENCES

- Proffit WR, Fields HW, Larson B, Sarver DM, Proffit WR, Fields HW. Biologic basis of orthodontic therapy. In: Proffit WR, Fields HW, Içinde HW, eds. *Contemporary orthodontics*. Mosby Inc.; 2000.
- Kim KA, Lee JW, Park JH, Kim BH, Ahn HW, Kim SJ. Targeted pre-surgical decompensation in patients with yaw-dependent facial asymmetry. *Korean J Orthod*. 2017;47(3):195-206. doi:10.4041/kjod.2017.47.3.195
- Baek C, Paeng JY, Lee JS, Hong J. Morphologic evaluation and classification of facial asymmetry using 3-dimensional computed tomography. *J Oral Maxillofac Surg*. 2012;70(5):1161-1169. doi:10.1016/j.joms.2011.02.135
- Tyan S, Park HS, Janchivdorj M, Han SH, Kim SJ, Ahn HW. Three-dimensional analysis of molar compensation in patients with facial asymmetry and mandibular prognathism. *Angle Orthod*. 2016;86(3):421-430. doi:10.2319/030915-142.1
- Ho CT, Lin HH, Liou EJW, Lo LJ. Three-dimensional surgical simulation improves the planning for correction of facial prognathism and asymmetry: a qualitative and quantitative study. *Sci Rep*. 2017;7(1):40423. doi:10.1038/srep40423
- Lee JY, Han SH, Ryu HS, Lee HM, Kim SC. Cone-beam computed tomography analysis of transverse dental compensation in patients with skeletal class III malocclusion and facial asymmetry. *Kor J Orthodont*. 2018;48(6):357-366. doi:10.4041/kjod.2018.48.6.357
- Thiesen G, Freitas MPM, Araújo EA, Gribel BF, Kim KB. Three-dimensional evaluation of craniofacial characteristics related to mandibular asymmetries in skeletal class I patients. *Am J Orthod Dentofacial Orthop*. 2018;154(1):91-98. doi:10.1016/j.ajodo.2017.10.031
- Kamata H, Higashihori N, Fukuoka H, Shiga M, Kawamoto T, Moriyama K. Comprehending the three-dimensional mandibular morphology of facial asymmetry patients with mandibular prognathism. *Prog Orthod*. 2017;18(1):43. doi:10.1186/s40510-017-0197-6
- Impellizzeri A, Horodyski M, de Stefano A, et al. CBCT and intra-oral scanner: the advantages of 3D technologies in orthodontic treatment. *Int J Environ Res Public Health*. 2020;17(24):9428. doi:10.3390/ijerph17249428
- Song WW, Kim SS, Sándor GKB, Kim YD. Maxillary yaw as the primary predictor of maxillary dental midline deviation: 3D analysis using cone-beam computed tomography. *J Oral Maxillofac Surg*. 2013;71(4):752-762. doi:10.1016/j.joms.2012.07.043
- Chen YJ, Yao CC, Chang ZC, Lai HH, Lu SC, Kok SH. A new classification of mandibular asymmetry and evaluation of surgical-orthodontic treatment outcomes in class III malocclusion. *J Craniomaxillofac Surg*. 2016;44(6):676-683. doi:10.1016/j.jcms.2016.03.011
- López DF, Botero JR, Muñoz JM, Cárdenas-Perilla R, Moreno M. Are there mandibular morphological differences in the various facial asymmetry etiologies? A tomographic three-dimensional reconstruction study. *J Oral Maxillofac Surg*. 2019;77(11):2324-2338. doi:10.1016/j.joms.2019.05.020
- Baldini B, Cavagnetto D, Baselli G, Sforza C, Tartaglia GM. Cephalometric measurements performed on CBCT and reconstructed lateral cephalograms: a cross-sectional study providing a quantitative approach of differences and bias. *BMC Oral Health*. 2022;22(1):98. doi:10.1186/s12903-022-02131-3
- Ha SW, Kim SJ, Choi JY, Baek SH. Characterization of facial asymmetry phenotypes in adult patients with skeletal class III malocclusion using three-dimensional computed tomography and cluster analysis. *Korean J Orthod*. 2022;52(2):85-101. doi:10.4041/kjod.2022.52.2.85
- Aghazada H, Vernucci RA, Ramieri V, et al. Assessment of maxillary canting on cone beam computed tomography and digital models: a retrospective study and proposal of a method. *J Stomatol Oral Maxillofac Surg*. 2022;123(2):128-135. doi:10.1016/j.jormas.2021.03.005
- Niño-Sandoval TC, Maia FPA, Vasconcelos BCE. Efficacy of proportional versus high condylectomy in active condylar hyperplasia—a systematic review. *J Craniomaxillofac Surg*. 2019;47(8):1222-1232. doi:10.1016/j.jcms.2019.03.024
- Kim SJ, Lee KJ, Lee SH, Baik HS. Morphologic relationship between the cranial base and the mandible in patients with facial asymmetry and mandibular prognathism. *Am J Orthod Dentofacial Orthop*. 2013;144(3):330-340. doi:10.1016/j.ajodo.2013.03.024
- Chen YJ, Yao CC, Chang ZC, Lai HH, Yeh KJ, Kok SH. Characterization of facial asymmetry in skeletal class III malocclusion and its implications for treatment. *Int J Oral Maxillofac Surg*. 2019;48(12):1533-1541. doi:10.1016/j.ijom.2019.06.014
- Liu LC, Chen YA, Chen RF, Yao CF, Liao YF, Chen YR. Type of mandibular asymmetry affects changes and outcomes of bimaxillary surgery for class III asymmetry. *Clin Oral Investig*. 2022;26(1):1077-1088. doi:10.1007/s00784-021-04092-3
- Noh HK, Park HS. Does maxillary yaw exist in patients with skeletal class III facial asymmetry? *Am J Orthod Dentofacial Orthop*. 2021;160(4):573-587. doi:10.1016/j.ajodo.2020.05.025
- Goulart DR, Muñoz P, Olate S, de Moraes M, Fariña R. No differences in morphological characteristics between hyperplastic condyle and class III condyle. *Int J Oral Maxillofac Surg*. 2015;44(10):1281-1286. doi:10.1016/j.ijom.2015.05.018
- Wolford LM, Movahed R, Perez DE. A classification system for conditions causing condylar hyperplasia. *J Oral Maxillofac Surg*. 2014;72(3):567-595. doi:10.1016/j.joms.2013.09.002
- Udomlarptham N, Lin CH, Wang YC, Ko EWC. Does two-dimensional vs. three-dimensional surgical simulation produce better surgical outcomes among patients with class III facial asymmetry? *Int J Oral Maxillofac Surg*. 2018;47(8):1022-1031. doi:10.1016/j.ijom.2018.02.014

**How to cite this article:** Vernucci RA, Da Mommio L, Vellone V, et al. 'Study of the maxillary yaw on cone beam computed tomography: A preliminary report and comparison between two different dento-skeletal malocclusions'. *Orthod Craniofac Res*. 2023;00:1-9. doi:10.1111/ocr.12652