

New Indications for TIPSs: What Do We Know So Far?

Lucia Lapenna ^{*,a}, Simone Di Cola ^{*,a}, Jakub Gazda [†], Ilaria De Felice ^{*}, Stefania Gioia ^{*},
Manuela Merli ^{*}



^{*}Department of Translational and Precision Medicine, Sapienza University of Rome, Italy and [†]2nd Department of Internal Medicine, PJ Safarik University and L. Pasteur University Hospital in Kosice, Slovakia

Since 1988, transjugular intrahepatic portosystemic shunt (TIPS) has been an effective therapy for portal hypertension in many settings. Thanks to continuous technical improvements and a wiser selection of patients, excellent results have been achieved with this therapeutic strategy. The historical indications for TIPS placement, in the context of liver cirrhosis, such as refractory ascites and variceal bleeding are now well established and known. However, in recent years, new indications are emerging. These have been investigated and approved in some studies but are not yet included in guidelines and clinical practice. This review aims to highlight what is new for the role of TIPS in portal vein thrombosis (especially in patients awaiting liver transplantation), in recurrent ascites and not only refractory ascites, as a neoadjuvant therapy before abdominal surgery and, finally, in the setting of noncirrhotic portal hypertension. All these new aspects are addressed in this review with a critical approach based on the literature revision and clinical practice. Future research is needed to explore and validate the new role of TIPS in these scenarios. (J CLIN EXP HEPATOL 2023;13:794–803)

The transjugular intrahepatic portosystemic shunt (TIPS) is an artificial channel within the liver that establishes communication between the inflow portal vein and the outflow hepatic vein. The first successful TIPS insertions were performed in 1988 at the University of Freiburg, and it has since become the standard of care for certain complications of liver cirrhosis.¹ However, it was not a process without its setbacks. TIPS dysfunction due to thrombosis or intimal hyperplasia and subsequent graft stenosis or complete occlusion limited the use of bare grafts by leading to a clinical relapse of portal hypertensive (PH) complications.² Polytetrafluoroethylene (PTFE)-covered stent graft reduced the rates of TIPS dysfunction, and it was the single most important factor allowing the widespread use of TIPS in the clinical practice. Currently, refractory ascites (RefA) and variceal bleeding are routine indications for TIPS placement in the context of liver cirrhosis. Importantly, PTFE-covered stent grafts allowed new indications to emerge as well. However, there is currently no recommendation in the clinical practice guidelines for or against using TIPS in

these clinical settings. Therefore, this review aimed to highlight what is new for the role of TIPS in portal vein thrombosis (PVT; especially in patients awaiting liver transplantation), in recurrent ascites (RecA), or as neoadjuvant therapy before abdominal surgery, and finally, in the setting of noncirrhotic PH. All these new aspects are addressed in this review with a critical approach based on the literature revision and clinical practice. Future research is needed to explore and validate the role of TIPS in these new scenarios (Figure 1).

CURRENT INDICATIONS AND CONTRAINDICATIONS

TIPS is an intrahepatic shunt that connects the portal circulation to the systemic one, reducing the pressures that insist on the portal system. It is an interventional radiology procedure, which should be performed only in third-level centers that have matured experience of the procedure and possible complications. The classic procedure consists of the catheterization of one of the hepatic veins, achieved by puncturing the internal jugular vein under ultrasound guidance. The hepatic parenchyma is punctured until one of the main branches of the portal vein is reached. Then, it is possible to measure the portosystemic pressure gradient between the portal circulation (indirectly) and the inferior vena cava. Finally, through balloon dilatation, the channel is created where the stent is positioned, which can be further dilated as needed.

To date, there are no recent international guidelines on the placement of TIPS. Based on the European guidelines on decompensated cirrhosis and the Italian consensus on the positioning of TIPS, it is possible to derive the following^{3,4}:

Keywords: transjugular intrahepatic portosystemic shunt, portal hypertension, surgery, portal vein thrombosis, Budd-Chiari syndrome

Received: 8.12.2022; **Accepted:** 29.1.2023; **Available online** 10 February 2023

Address for correspondence: Prof. Manuela Merli, Department of Translational and Precision Medicine, Sapienza University of Rome, Italy.

E-mail: manuela.merli@uniroma1.it

^a Lucia Lapenna and Simone Di Cola shared co-first authorship.

Abbreviations: AC: anticoagulation; BCS: Budd-Chiari syndrome; HE: hepatic encephalopathy; HVP: hepatic venous pressure gradient; LVP + A: large-volume paracentesis with albumin infusion; MELD: model for end-stage liver disease; PH: portal hypertension; PSVD: porto-sinusoidal vascular disease; PTFE: polytetrafluoroethylene; PVT: portal vein thrombosis; RecA: recurrent ascites; RefA: refractory ascites; TIPS: transjugular intrahepatic portosystemic shunt

<https://doi.org/10.1016/j.jceh.2023.01.017>

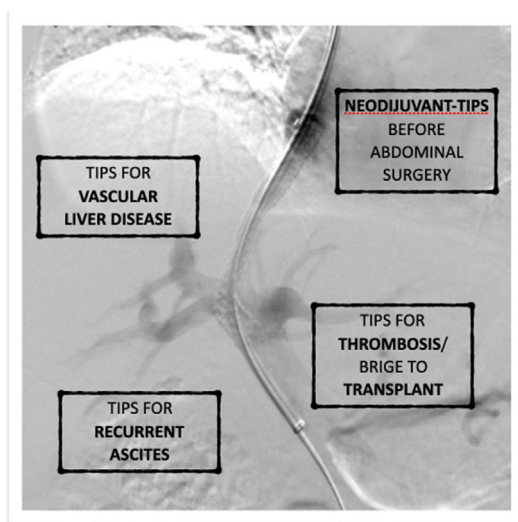


Figure 1 New indications for TIPS. Abbreviation: TIPS, transjugular intrahepatic portosystemic shunt.

The classic indications for the placement of TIPS are as follows:

- Refractory ascites, as it improves the control of ascites and survival.
- Recurrent symptomatic hepatic hydrothorax
- Failed treatment of gastroesophageal varices with nonselective beta-blockers (NSBBs) and variceal ligation
- Early preemptive covered TIPS (placed within 24–72 h) in selected high-risk patients, such as those with Child class C with score <14 or Child class B with active bleeding
- Bridge treatment in patients listed for liver transplantation
- Transfusion-dependent Portal Hypertensive Gastropathy (PHG) in whom NSBBs fail or are not tolerated
- Treatment of gastroesophageal varices type 2 or isolated varices type 1 with TIPS placement with or without embolization
- Hepatorenal syndrome type 2 associated to refractory/recidivant ascites although there are no clear and definitive data on this context.
- Failure of anticoagulation (AC) and mechanical revascularization in Budd-Chiari syndrome (BCS) patients with persistent ascites or other related complications
- Patients with porto-sinusoidal vascular disorder (PSVD), when the same indications of the patient with cirrhosis exist.

However, it should be considered that TIPS is a procedure that causes substantial hemodynamic changes in patients with PH, particularly in patients with liver cirrhosis. Therefore, this procedure is not without periprocedural complications and long-term implications.

It is therefore necessary to consider the possible contraindications to the placement of TIPS. First of all, the first

limitation is the technical one. The placement of TIPS is not always technically feasible. The absence of a vascular access represents a technical contraindication to stent placement although there are alternative techniques to the classic one which can bypass the technical obstacle. The presence of a portal cavernoma may make it impossible to locate a vascular access, but in general, it is not an absolute contraindication and each case must be studied individually.

The creation of a shunt that draws blood away from the portal circulation could further worsen liver and kidney function. For this reason, the presence of hepatic (total bilirubin >3 mg/dL,³ or 5 g/dL⁴ and renal (creatinine >3 g/dL) insufficiency could constitute a contraindication to TIPS. Large quantities of portal blood are discharged directly to the right heart and small pulmonary circulation. For this reason, heart failure and the presence of high pulmonary pressures (severe pulmonary hypertension, mPAP >45 mmHg) are perhaps the only absolute contraindications to TIPS placement. Finally, an active infection and in particular an uncontrolled state of sepsis is a contraindication to TIPS.

Both the choice of TIPS placement and its contraindication, however, should not be guided only by current guidelines but should be personalized for the individual patient that we are treating.

In fact, more than looking at the single contraindications, the most important thing is to make a good selection of patients, taking care of factors that may play a prognostic role on the therapeutic success of TIPS placement or on the development of complications.

Hepatic encephalopathy (HE) is the most frequent complication after TIPS. It is usually transitory but can affect quality of life and is associated with an increase in mortality.⁵ For these reasons, previous episodes of HE or the presence of covert HE must be considered before TIPS placement. Moreover, the presence of sarcopenia is considered a risk factor of the development of HE after TIPS, and a complete nutritional assessment is recommended as part of a correct evaluation of the patient before the TIPS placement.⁶

Over the years knowledge, management of complications and technical progress have been made in TIPS field, making this therapeutic option widely used in the treatment of complications of PH and allowing a continuous expansion of indications even beyond the more conventional ones.

RECURRENT ASCITES

Recently, a significant progress has been made in the understanding of underlying pathophysiological mechanisms leading to liver cirrhosis decompensation. A detailed description of ascites formation is beyond this review's scope; however, the individual roles of PH, systemic

inflammation, metabolic alterations, and mitochondrial dysfunction are now widely acknowledged.⁷⁻⁹ The development of ascites is an important milestone, while about 20% of cirrhotic patients presenting with it die within the first year following its manifestation.¹⁰ Refractory ascites (RefA) is defined as ascites that cannot be mobilized or the early recurrence of which (i.e., after large-volume paracentesis) cannot be satisfactorily prevented by medical therapy. However, there is no universally accepted definition of RecA. Most frequently, it is defined as ascites that recurs on at least three occasions within 12 months despite dietary sodium restriction and adequate diuretic dosage.¹¹ The current practice for RecA control (dietary sodium restriction, diuretics, and repeated large-volume paracentesis with albumin infusion (LVP + A)) acts downstream of the pathogenic cascade, and it does not improve the poor transplant-free survival. Therefore, other approaches for its control have been widely sought out, including TIPS placement, which is the only method acting directly on the pathogenesis of ascites. The rationale for this is to decrease the portal pressure and the filtration into the peritoneal space to a volume which will be drained by the lymphatic system. TIPS is an artificially created low-resistance channel within the liver that establishes communication between the inflow portal vein and the outflow hepatic vein. Due to this nature, TIPS placement has immediate hemodynamic consequences. It results in rapid blood shunting from the high-pressure portal vein to the low-pressure inferior vena cava. In turn, blood shunting causes a drop in portal pressure, increases heart preload, and ultimately improves cardiac output.¹²⁻¹⁵ The improved cardiac output, however, attenuates compensatory mechanisms (such as systemic vascular resistance), so that the mean arterial pressure remains unchanged early after TIPS placement.¹⁶ Despite that, following TIPS insertion, blood redistribution and increased effective arterial blood volume improves renal perfusion and reduce both plasma aldosterone levels and plasma renin activity, altogether resulting in an improved urinary sodium excretion and ascites control.¹⁷ However, most of the aforementioned evidence comes from patients with either RefA only or from highly heterogeneous populations of patients. Given the plausible pathophysiological background, we can presume a similar impact of TIPS insertion on hemodynamics and kidney function in patients with RecA although the evidence supporting it is still missing. On the other side, most of the studies that showed a survival benefit for TIPS were those that included a significant percentage of patients with only RecA.¹⁸ Furthermore, Shen *et al.* showed that early placement of TIPS appears to be a cost-effective strategy for management of specific patients with cirrhosis and RecA.¹⁹ Even though Li *et al.*²⁰ suggest that earlier TIPS placement improves the overall prognosis, most of the randomized control trials comparing the net benefit of TIPS insertion against

LVP + A were performed in patients with RefA,²¹⁻²⁴ and only one was dedicated to those with RecA.¹² Bureau *et al.* prospectively included 62 patients with RecA randomly assigned to the TIPS group (n = 29) or the LVP + A group (n = 33). They showed that 1-year transplantation-free survival (TFS) was greater in the TIPS group (93% vs. 52%, $P = 0.003$) and that the total count of paracentesis was 32 and 320 in the TIPS and LVP + A groups, respectively ($P < 0.05$). Importantly, no difference was observed in the probability of remaining free of overt HE between the two groups (65%). These results suggest that placing TIPS before the ascites gets refractory is beneficial although they will have to be confirmed in larger and adequately powered studies. On the other side, patient selection for TIPS should also integrate extrahepatic factors that modify the prognosis following TIPS placement as well. Deltenre *et al.* have recently reviewed these factors in patients with RefA elsewhere.²⁵ The impaired cardiac reserve is one of the most important factors associated with the worse prognosis of cirrhotic patients with ascites following TIPS. As mentioned above, TIPS insertion is followed by rapid blood shunting from the portal vein to the inferior vena cava, which effectively increases heart preload. Increased heart preload may unmask or worsen preexisting cirrhotic cardiomyopathy or cardiomyopathy of other etiology, effectively causing cardiac decompensation. Kidney dysfunction is also associated with an unfavorable response to TIPS placement, while preserved kidney function is required to achieve the elimination of ascites.²⁴ In the study by Bureau *et al.*, TIPS and LVP + A groups had well balanced MELD score and creatinine levels, but the information on cardiac reserve and sarcopenia was not presented.¹⁴ However, Vizzutti and colleagues concluded that chances for a favorable response to TIPS insertion decrease with age.²⁶ Finally, a specific target in the reduction of HVPG is still controversial in patients with ascites.^{27,28} It is well known that the larger the diameter, the larger volume of blood shifts from the portal vein to the inferior vena cava, which translates into higher reduction of HVPG on one side but higher risk of HE on the other. Furthermore, the timing of the measurement needs to be resolved as well, while it seems that measuring post-TIPS HVPG the same day of the TIPS placement is less accurate.²⁹ Older studies have utilized bare-stent grafts and PTFE-covered stent grafts for patients with RefA. Recently, however, it has been shown that the new generation of controlled expansion stent grafts improve ascites control and survival even further compared to previous stent grafts.³⁰ In their study, Bureau *et al.* used legacy Viatorr stents dilated to 8 mm and 10 mm according to hemodynamic response (reduction of HVPG).¹⁴ Therefore, future studies should focus on determining the most suitable target in the reduction of HVPG and the timing of its measurement and on further strengthening the evidence on the benefit of controlled expansion stent grafts. To

Table 1 Largest Studies on the Use of TIPS in Patients with Portal Vein Thrombosis.

Authors	Type of work	Patients	PVT	Technical feasibility	Response	Major complications	HE post TIPS
Rodrigues Susana G, Alimont 2019 ¹⁶	Systematic review	399 (92% cirrhosis)	Complete PVT 46%; Cavernoma 17%	95% (95% CI: 89–98%)	79% (95% CI: 67–88%)	10%	17%–29%
Veilentin N Eur J Gastroenterol Hepatol 2018 ¹⁵	Systematic review	18 articles/abstracts	Very heterogeneous over a long period of time (1993–2016)	86.7%	84.4% (Complete 73%)	0%	25%
Lv Y, Am J Gastroenterol. 2021 ¹³	Prospective Observational Study	88 cirrhotics	Complete PVT 15.9%; Cavernoma 21.6%	88% ^a	100% (Complete 89%)	3.4%	26%
Davis JPE. Clin Appl Thromb Hemost 2019 ¹⁴	Systematic review	3 articles = 148 patients	Complete thrombosis 0–35%; Cavernomatosis 0–46%	96–100%	91–100%	0–17%	17–25%

HE, hepatic encephalopathy; PVT, portal vein thrombosis; TIPS, transjugular intrahepatic portosystemic shunt.

^aConsidering the whole group of TIPS examined in the study (197 TIPS + AC and 88 TIPS alone).

conclude, Bureau *et al.* presented promising results of TIPS positioning in cirrhotic patients with RecA with regard to both ascites control and TFS as well as the incidence of overt HE.¹⁴ These results, however, remain to be validated in external cohorts of patients. In real-world clinical practice, it will be challenging to select suitable patients with RecA for TIPS placement because difficulties will arise from the existence of several factors affecting outcomes. On top of that, technical aspects of TIPS placement will have to be resolved as well.

TIPS FOR PORTAL VEIN THROMBOSIS

Flow into the portal vein is greatly slowed in cirrhotic patients due to PH. As it is known, alterations in blood flow, which are included in the Virchow triad, increase the risk of thrombosis. In cirrhosis, the pathophysiology is certainly more complicated and changes in the endothelial layer and coagulations with rebalanced hemostasis can also be observed. Overall, the risk of nonmalignant portal vein thrombosis (PVT) in cirrhotic patients is very high (from 0.6% to 16% depending on the stage of liver disease).^{31,32} The impact of PVT in the natural history of cirrhotic patients is controversial.^{33,34} However, it has been widely demonstrated that this event is associated with a worse prognosis in patients on transplant waiting list.^{35–39} The impact on the prognosis is linked to the increased mortality in patients listed for liver transplantation, to the surgical technical difficulties of transplantation and for the increased recurrence of thrombosis and the increased mortality in the post transplantation period.³⁹ Complete PVT or the involvement of superior mesenteric vein reduces the possibility to perform portal-to-portal vein anastomosis, even if other techniques are possible in order to overcome the issue (e.g., reno-portal anastomosis).⁴⁰ Although the data in the literature are not sufficient and are sometimes conflicting, it is known that AC therapy must be used in the first line for the treatment of PVT, with much higher recanalization rates than in controls.^{41,42} Partial thrombosis and the time of starting of therapy appear to be critical in obtaining a response.

In these situations, TIPS placement is becoming increasingly used as a strategy to treat PVT before liver transplantation. Indeed, several studies conducted over the years in cirrhotic patients in which there was an indication to TIPS placement for other PH-related reasons have shown that TIPS is often feasible and that it led to good rates of resolution of thrombosis (see Table 1). A recent prospective study evaluated the effect of AC and TIPS placement in PVT, and both strategies were found to be effective in achieving portal vein recanalization.⁴³ A 2019 systematic review compared for the first time the efficacy of AC and TIPS in the management of PVT for the first time. Both choices were effective and

safe with excellent recanalization rates (OR 6.00; IC95%: 2.38–15.07 for AC vs. OR 3.80; IC95%: 1.47–9.83 for TIPS). This review also showed a significant increase in survival in patients treated with AC, which is not observed in patients undergoing TIPS placement. The authors suggest an antifibrotic effect of AC that may ameliorate liver disease, as demonstrated in experimental models; however, in consideration of the many limitations of the review, this statement make further studies on this topic necessary.⁴⁴ In a recent meta-analysis, the technical success rate of TIPS placement in cirrhotics with portal thrombosis was 86.7% (95% CI = 78.6–92.1%),⁴⁵ while in a systematic review of 2019 on 399 patients (92% cirrhosis), it was about 95% (95% CI: 89%–98%), despite the important heterogeneity of the group mainly due to the percentage of patients with cavernomatosis.⁴⁶ The principal aspects to consider before TIPS placement are thrombosis' extension (partial or total), presence of cavernomatosis, concomitant clinical conditions (e.g., ascites, varices).⁴⁷ Partial PVT makes TIPS placement more feasible, while a complete thrombosis or evolution to cavernomatosis can make the radiological procedure impossible. However, even these cases do not represent an absolute contraindication; if a sufficiently large cavernoma vessel or a residual portal vein lumen is visible, the procedure is considered feasible, in highly specialized centers. Transsplenic or transhepatic puncture have also been used for these more difficult cases, and these techniques lead to near 100% success rates, making liver transplant surgery feasible in initially excluded patients.^{48,49} The use of portal vein collateral vessels should be a second choice as it is associated with higher postprocedural complication rates. Finally, the concomitance of PH-related complications (ascites or GI varices) and PVT, strengthen the indication for TIPS placement, as PVT resolution significantly reduce the PH-related complications, improving disease control. There are no clear indications on AC therapy after TIPS placement in PVT patients; however, the patency of the portal vein appears to be well controlled by the stent even in the long term period and post-TIPS AC therapy does not appear to be necessary, in the absence of other indications for chronic AC (e.g., thrombophilia).⁵⁰ In some cases, the rate of procedural complications is not negligible (about 10%) although also in this case, the data are affected by the heterogeneity of the groups analyzed and the type of procedure (e.g., TIPS + thrombectomy has the highest rate of major adverse events compare to TIPS alone, such as death, bleeding, hematoma).⁴⁶ The rate of HE post-TIPS placement could be lower than in patients who undergo TIPS for traditional reasons (about 10%) for adaptive systems already present in consideration of the previous thrombosis.⁵¹ In summary, larger and more prospective studies are needed to analyze the effect of TIPS in the management of PVT; currently, in clinical practice, the indication for TIPS placement should be the treatment of chronic PVT that has not

responded to anticoagulant therapy, especially in patients on the waiting list for liver transplantation, as suggested by European guidelines.⁵² The same recommendation is now included in the new Baveno VII consensus for the first time.²⁷

PRESURGICAL TIPS PLACEMENT

It has long been known that cirrhotic patients undergoing extrahepatic and hepatic surgery have a significantly higher risk of peri and postoperative complications and mortality (10–30% in various studies) compared to the general population.^{53,54} This has been attributed to the type of surgery, presence of comorbidities, and to various liver-related factors mainly the grade of hepatic dysfunction (usually assessed with Child-Pugh and Meld score) and the presence of PH.^{55,56,57,58} Liver dysfunction and PH affect the risks of bleeding and infection, the most common postoperative complications in patients with cirrhosis.⁵³ Even though there are no strategies to improve liver function before surgery, TIPS has been proposed to resolve PH in the short term. This represents a nonstandard indication for TIPS placement. In 2001, Azoulay *et al.*⁵⁹ were among the first to propose a two-step management of cirrhotic patients with severe PH needing abdominal surgery: decompression of the portal system by TIPS followed by elective surgery. They analyzed seven cases of patients otherwise not considered eligible for surgery for the presence of complications of PH (history of variceal bleeding, varices at risk of bleeding, or intractable ascites). In the following years, technical progress in TIPS placement and the advent of new types of stents made this therapeutic intervention more feasible and indications wider. In 2020, Schmitz *et al.*⁶⁰ retrospectively showed how in 22 patients TIPS allowed successful abdominal operation in 52.4% of patients with 30-day postoperative mortality rate 0%. At variance, Vinet *et al.*⁶¹ showed, in a retrospective comparative study, that preoperative TIPS placement did not improve postoperative evolution after abdominal surgery in cirrhotic patients with good or moderately impaired liver function. Finally, in the study by Tabchouri *et al.*,⁶² even if no significant differences were found between TIPS and no-TIPS groups in terms of postoperative complications and mortality, TIPS placement made surgery feasible in 85% of 66 cirrhotic patients. This finding points out that reasonable outcomes to consider in these groups of patients are not only death and postoperative complications but also the access to surgery (“TIPS risk/surgery benefit”).⁶³ The main limits in these studies are the small number of patients, the retrospective design, and the lack of a control group in some. They also lack a precise definition of severe PH, without an HVPG measurement that could allow objectiveness. In 2019, Reverter *et al.*⁶⁴ showed for the first time prospectively the prognostic impact of HVPG on extrahepatic surgery in

cirrhosis. HVPG resulted as a prognostic factor of 1-year mortality in cirrhotic patients undergoing elective extrahepatic surgery. As the Baveno VII consensus highlighted, HVPG values >16 mmHg are associated with a high risk of short-term mortality after surgery and HVPG >20 mmHg identify the patients at highest risk.²⁷ We are still far from having sufficient evidence to support a routine TIPS placement before extrahepatic surgery,⁶⁵ but it is important to know that this is a possible option in patients with a high measurable risk. Furthermore, an important gap still exists in literature about the optimum timing of surgery after TIPS positioning. In the study by Fares *et al.*,⁶⁶ surgery was performed within a median of 25 days after TIPS while in the study by Gil *et al.*⁶⁷ within 14–45 days. However, the timing is not well defined, and it is unclear whether a reevaluation of HVPG after TIPS is needed preliminarily to surgery. In conclusion, many factors surgery related (complexity and indication, oncological vs. other), liver related (HVPG, liver function), and presence of indications or contraindications for TIPS placement could shift the balance toward one or the other approach. Future multicentric studies are needed to better select patients that can benefit from a neoadjuvant TIPS before extrahepatic surgery.

TIPS IN VASCULAR LIVER DISEASE

Porto-sinusoidal Vascular Disorder (PSVD)

The term porto-sinusoidal vascular disorder (PSVD) refers to a vascular liver disease characterized by typical histological lesions involving the portal venules or sinusoids in absence of cirrhosis occurring in patients with or without signs of PH.⁶⁸ To date, few studies investigating natural history of PSVD exist, and most of them were conducted on small series of patients due to the infrequency of the disease. Thus, a specific treatment of PSVD does not exist and guidelines on vascular liver diseases still suggest to manage PH occurring in patients with PSVD as PH occurring in patients with cirrhosis.²⁷ The indications for TIPS placement in PSVD and selection criteria of the patients should be similar to those of cirrhosis: failure of endoscopic and medical treatment in patients with gastroesophageal variceal bleeding and RefA.^{69,70} In the setting of variceal bleeding that represents the main complication of PSVD, TIPS can be used in emergency, for control of acute variceal bleeding in patients who failed to achieve hemostasis despite endoscopic and medical treatment, and electively, for the prevention of rebleeding in patients that received and failed secondary prophylaxis. An observational study conducted in China described that patients with PSVD treated with TIPS placement for variceal bleeding had a similar progression of PH (rebleeding and shunt dysfunction) but a lower risk of complications of hepatic disease and mortality compared to cirrhotic patients with similar liver impairment.⁷¹ The explanation may be that while

PH is marked in PSVD, the hepatocellular damage is only minimal. Differently from cirrhosis, the histological lesions, mainly involving the vascular system (portal venules and sinusoids), are not progressive and rarely lead to liver insufficiency. The lower mortality rate due to variceal bleeding and bleeding-related complications in PSVD patients than in cirrhotic may be explained by the reduced hepatic impairment in PSVD patients as well. Bissonnette *et al.*, also described, in a retrospective multicenter study, that TIPS is a valid option to treat complications of PH in PSVD. In particular, good results in terms of mortality and outcomes were obtained in PSVD patients without relevant comorbidities or kidney failure with an 80% 2,5 years survival after the procedure.⁷² Patients who had both serum creatinine of 100 mol/L or more and a significant extrahepatic comorbidity had a high risk of death compared to others who did not meet both criteria ($P < 0.001$, log-rank test). Indeed, the authors underlined the importance of an accurate selection of the patients to submit to TIPS. PVT is a frequent complication of PSVD occurring in up to 40% of the patients, with an incidence higher than in patients with cirrhosis, probably because of the high prevalence of prothrombotic conditions together with the low portal vein velocity secondary to PH. PVT and portal vein cavernoma may represent a technical issue that compromise the feasibility and the success of TIPS placement being responsible for intraoperative failures and complications. Regnault *et al.* conducted a study on 25 patients with PSVD submitted to TIPS with a 10-year follow-up, and they confirmed the effectiveness of TIPS in prevention of rebleeding but they suggested performing TIPS earlier, possibly selecting PSVD patients at risk of cavernoma (portal or portomesenteric thrombosis, etc.) to avoid difficulties in the radiological approach.⁷³ The role of TIPS in patients at a high risk of variceal bleeding but, at the same time, candidate to lifelong anticoagulant therapy for PVT is still a topic to be discussed on a case-by-case basis in centers of excellence.

TIPS insertion is considered also in refractory and chronic ascites, but in this setting, it is associated with elevated short-term mortality.⁷² Ascites represents a non-usual characteristic of PSVD, probably its onset represents a terminal phase of the disease, where the reduced blood supply leads to hepatic atrophy and presence of extrahepatic comorbidities (chronic kidney failure). Furthermore, in Regnault's monocentric study, the authors paid attention to recurrence of ascites which is more typical in the long term, especially using bare stents. Indeed, the presence of RecA was around 40% using bare stents rather than covered ones (10%). Overt HE represents a tangible complication of TIPS placement also in PSVD patients, even if it is often transient and responsive to medical therapy.^{72,73} In fact, as reported by Nicoletti *et al.*, in PSVD, HE occurrence is strictly correlated to presence of portal systemic shunts, both spontaneous and iatrogenic.⁷⁴ However, the incidence of overt

HE after TIPS placement is significantly lower in PSVD than in cirrhotic patients (14% vs. 32%).⁶⁹ Finally, the authors underlined that the rate of HE in PSVD was lower than that reported in previous works (31–56%), probably an effect of the use of covered 8 mm stents.

Budd-Chiari Syndrome

TIPS in Budd-Chiari syndrome (BCS) is a part of stepwise therapeutic algorithm and appears as potential and curative treatment. Primarily, it's indicated when medical therapy with AC fails or hepatic vein interventions (angioplasty or stenting) are not possible or unsuccessful, in case of an acute presentation of the disease or in case of small hepatic vessels BCS.^{52,75} Although there are no randomized trials on TIPS placement in BCS, numerous observational and retrospective studies have documented very good long-term outcomes and symptoms resolution. In particular, Sonovane *et al.* showed that an important improvement in ascites, gastrointestinal bleeding, and laboratory parameters about renal and hepatic function was observed in patients affected by BCS submitted to TIPS. Their encouraging results confirmed the role of TIPS in therapeutic strategy of BCS patients, showing fairly low mortality, and suggesting the use of PTFE-covered stents rather than bare ones, as potentially stent occlusion or dysfunction were lower. With the accessibility of TIPS procedure, the need for liver transplantation has been shown to decrease.⁷⁶ Moreover, a study from Germany demonstrated a survival rate of 92.3% in the TIPS group and 75% in the liver transplantation group during a median follow-up of 4 and 11.5 years, respectively.⁷⁷ Despite its success in this setting, the feasibility of TIPS in patients with BCS may be more difficult than in cirrhotic patients because of hepatic vein obstruction and severe complications, especially periprocedural. This is the reason why it's better to refer these patients to centers of high expertise.⁷⁸ Nowadays, the role of TIPS in the BCS is relevant, replacing the surgical decompression of the portal system used until a few years ago and acting as a “bridge” to liver transplantation. TIPS represents a much less invasive decompression technique than surgery and is associated with fewer comorbidities and lower mortality.⁷⁹ In conclusion, the role of TIPS placement in BCS is even more relevant than in cirrhotic and noncirrhotic PH representing a possible curative treatment: the elimination of the hepatic outflow obstruction leads not only to the resolution of ascites and other complications of the disease but also to the prevention of a chronic liver damage and of the evolution to and to cirrhosis.

DISCUSSION

TIPS is an interventional radiology procedure performed for the first time in 1988 and since then widely used worldwide for the treatment of the complications of PH in the cirrhotic and noncirrhotic patients. Over the years, the

use of TIPS has been limited, except in sporadic cases, to the treatment of classic episodes of decompensation of liver cirrhosis, such as esophageal varices and RefA. In recent years, it has been found that its use in other indications, for the purpose of reducing PH, has also brought significant benefits. TIPS positioning, by inducing a decrease in PH, allows to reduce the risk of postsurgery liver decompensation. This may increase the eligibility for surgery in the treatment of extra hepatic intraabdominal tumors or other relevant lifesaving operations. The indication of TIPS before surgery has been focused only recently, and the potential of TIPS for this purpose has been recognized in important consensus (as in Baveno VII). TIPS has long been thought to be infeasible in PVT. PVT can, on the contrary, be an indication for TIPS, as it is curative especially in those patients who do not respond to AC therapy and in those in whom the extension of the thrombosis would compromise future liver transplant. Technical knowledge, improved experience, and new skills, especially in expert centers, have been obtained to overcome procedural restrictions and to perform TIPS placements with success even in presence of portal cavernoma. New alternative TIPS procedures to obtain portal recanalization as a combined approach through the suprahepatic veins and the splenic vein following a percutaneous transsplenic puncture have been proposed. The indication for TIPS has also been extended to patients with noncirrhotic PH, following the indications for liver cirrhosis and sometimes with some specific clues (e.g., positioning of TIPS even for mild ascites in patients with BCS as this is an indirect sign of persistent obstruction to venous outflow). In this group of patients, TIPS is followed by a lower complication rate as liver function is generally preserved for a long time. Future studies, thanks to the greater knowledge of this heterogeneous population, will be able to designate better the role and timing of TIPS in these patients. Finally, the role of TIPS is progressively changing not only in regard to the indications but also of the better timing. An “earlier” TIPS, in some settings, can improve patients outcome, without waiting for the development of RefA or multiple bleeding episodes unresponsive to endoscopic therapy. The most recent revolution is precisely that of seeing in TIPS not necessarily “a second choice” or a “rescue therapy,” but a useful and safe tool that can modify the natural history of PH.

FURTHER PERSPECTIVES

Given the small number of studies and data available, we are still far from validating and easily applying these indications of TIPS placement in everyday clinical practice. However, these indications must be known, studied, and applied on a case-by-case basis critically and in expert centers. Further studies (prospective, randomized, multicentric) are awaited to consolidate these indications and to be able to better

understand not only what we know so far but also how far we can go utilizing this important therapeutic tool.

CREDIT AUTHORSHIP CONTRIBUTION STATEMENT

Lucia Lapenna & Simone Di Cola: conceptualization, investigation, writing-review & editing. Jakub Gazda, Ilaria De Felice, Stefania Gioia: investigation, writing original draft. Manuela Merli: supervision and project administration. All authors have read and agreed to the published version of the manuscript.

CONFLICTS OF INTEREST

All authors have none to declare.

FUNDING

All the authors declare that they have not received any funding for this study.

REFERENCES

- Rössle M, Richter GM, Nöldge G, Palmaz JC, Wenz W, Gerok W. New non-operative treatment for variceal haemorrhage. *Lancet*. 1989 Jul 15;2:153.
- Eesa M, Clark T. Transjugular intrahepatic portosystemic shunt: state of the art. *Semin Roentgenol*. 2011 Apr;46:125–132.
- European Association for the Study of the Liver. EASL Clinical Practice Guidelines for the management of patients with decompensated cirrhosis. *J Hepatol*. 2018 Aug;69:406–460.
- Fagiuoli S, Bruno R, Debernardi Venon W, et al. AIF TIPS Special Conference. Consensus conference on TIPS management: techniques, indications, contraindications. *Dig Liver Dis*. 2017 Feb;49:121–137.
- Rose CF, Amodio P, Bajaj JS, et al. Hepatic encephalopathy: novel insights into classification, pathophysiology and therapy. *J Hepatol*. 2020 Dec;73:1526–1547.
- Nardelli S, Lattanzi B, Torrisi S, et al. Sarcopenia is risk factor for development of hepatic encephalopathy after transjugular intrahepatic portosystemic shunt placement. *Clin Gastroenterol Hepatol*. 2017 Jun;15:934–936.
- Schrier RW, Arroyo V, Bernardi M, Epstein M, Henriksen JH, Rodés J. Peripheral arterial vasodilation hypothesis: a proposal for the initiation of renal sodium and water retention in cirrhosis. *Hepatology*. 1988;8:1151–1157.
- Arroyo V, Angeli P, Moreau R, et al. The systemic inflammation hypothesis: towards a new paradigm of acute decompensation and multiorgan failure in cirrhosis. *J Hepatol*. 2021;74:670–685.
- Engelmann C, Clària J, Szabo G, Bosch J, Bernardi M. Pathophysiology of decompensated cirrhosis: portal hypertension, circulatory dysfunction, inflammation, metabolism and mitochondrial dysfunction. *J Hepatol*. 2021;75:S49–S66.
- Fleming KM, Aithal GP, Card TR, West J. The rate of decompensation and clinical progression of disease in people with cirrhosis: a cohort study. *Aliment Pharmacol Ther*. 2010;32:1343–1350.
- Biggins SW, Angeli P, Garcia-Tsao G, et al. Diagnosis, evaluation, and management of ascites, spontaneous bacterial peritonitis and hepatorenal syndrome: 2021 practice guidance by the American Association for the Study of Liver Diseases. *Hepatology*. 2021;74:1014–1048.
- Salerno F, Merli M, Riggio O, et al. Randomized controlled study of TIPS versus paracentesis plus albumin in cirrhosis with severe ascites. *Hepatology*. 2004;40:629–635.
- Gines P, Uriz J, Calahorra B, et al. Transjugular intrahepatic portosystemic shunt versus repeated paracentesis plus intravenous albumin for refractory ascites in cirrhosis. A multicenter randomized comparative study. *Gastroenterology*. 2002;123:1839–1847.
- Bureau C, Thabut D, Oberti F. Transjugular intrahepatic portosystemic shunts with covered stents increase transplant-free survival of patients with cirrhosis and recurrent ascites (vol 152, pg 157, 2017). *Gastroenterology*. 2017;153:870.
- Rössle M, Ochs A, Gülberg V, et al. A comparison of paracentesis and transjugular intrahepatic portosystemic shunting in patients with ascites. *N Engl J Med*. 2000;342:1701–1707.
- Fili D, Falletta C, Luca A, et al. Circulatory response to volume expansion and transjugular intrahepatic portosystemic shunt in refractory ascites: relationship with diastolic dysfunction. *Dig Liver Dis*. 2015;47:1052–1058.
- Wong W, Liu P, Blendis L, Wong F. Long-term renal sodium handling in patients with cirrhosis treated with transjugular intrahepatic portosystemic shunts for refractory ascites. *Am J Med*. 1999;106:315–322.
- García-Pagán JC, Saffo S, Mandorfer M, Garcia-Tsao G. Where does TIPS fit in the management of patients with cirrhosis? *JHEP Rep*. 2020 May 23;2:100122.
- Shen NT, Schneider Y, Congly SE, et al. Cost effectiveness of early insertion of transjugular intrahepatic portosystemic shunts for recurrent ascites. *Clin Gastroenterol Hepatol*. 2018;16:1503–1510.
- Li J, Tang S, Zhao J, et al. Long-term survival prediction for transjugular intrahepatic portosystemic shunt in severe cirrhotic ascites: assessment of ten prognostic models. *Eur J Gastroenterol Hepatol*. 2021;33:1547–1555.
- Lebrec D, Giully N, Hadengue A, et al. Transjugular intrahepatic portosystemic shunts: comparison with paracentesis in patients with cirrhosis and refractory ascites: a randomized trial. *J Hepatol*. 1996;25:135–144.
- Ginès P, Uriz J, Calahorra B, et al. Transjugular intrahepatic portosystemic shunting versus paracentesis plus albumin for refractory ascites in cirrhosis. *Gastroenterology*. 2002;123:1839–1847.
- Sanyal AJ, Genning C, Reddy KR, et al. The North American study for the treatment of refractory ascites. *Gastroenterology*. 2003;124:634–641.
- Narahara Y, Kanazawa H, Fukuda T, et al. Transjugular intrahepatic portosystemic shunt versus paracentesis plus albumin in patients with refractory ascites who have good hepatic and renal function: a prospective randomized trial. *J Gastroenterol*. 2011;46:78–85.
- Deltenre P, Zanetto A, Saltini D, Moreno C, Schepis F. The role of transjugular intrahepatic portosystemic shunt in patients with cirrhosis and ascites: recent evolution and open questions. *Hepatology*. 2023 Feb 1;77:640–658.
- Vizzutti F, Celsa C, Calvaruso V, et al. Mortality after transjugular intrahepatic portosystemic shunt in older adult patients with cirrhosis: a validated prediction model. *Hepatology*. 2022;1–13.
- De Franchis R, Bosch J, Garcia-Tsao G, Reiberger T, Ripoll C, Baveno VII Faculty. Baveno VII - Renewing consensus in portal hypertension. *J Hepatol*. 2022 Apr;76:959–974. <https://doi.org/10.1016/j.jhep.2021.12.022>. Epub 2021 December 30. Erratum in: *J Hepatol*. 2022 Apr 14.
- Boike JR, Thornburg BG, Asrani SK, et al. North American practice-based recommendations for transjugular intrahepatic portosystemic shunts in portal hypertension. *Clin Gastroenterol Hepatol*. 2022;20.
- Silva-Junior G, Turon F, Baiges A, et al. Timing affects measurement of portal pressure gradient after placement of transjugular intrahepatic portosystemic shunts in patients with portal hypertension. *Gastroenterology*. 2017;152.
- Praktikjnjo M, Abu-Omar J, Chang J, et al. Controlled underdilation using novel VIATORR® controlled expansion stents improves

- survival after transjugular intrahepatic portosystemic shunt implantation. *JHEP Rep*. 2021;3:100264.
31. Anton A, Campreciós G, Pérez-Campuzano V, Orts L, García-Pagán JC, Hernández-Gea V. The pathophysiology of portal vein thrombosis in cirrhosis: getting deeper into Virchow's triad. *J Clin Med*. 2022 Feb 2;11:800. <https://doi.org/10.3390/jcm11030800>. PMID: 35160251; PMCID: PMC8837039.
 32. Violi F, Corazza GR, Caldwell SH, et al, PRO-LIVER Collaborators. Portal vein thrombosis relevance on liver cirrhosis: Italian Venous Thrombotic Events Registry. *Intern Emerg Med*. 2016 Dec;11:1059–1066.
 33. Chen H, Turon F, Hernández-Gea V, et al. Nontumoral portal vein thrombosis in patients awaiting liver transplantation. *Liver Transpl*. 2016 Mar;22:352–365.
 34. Nery F, Chevret S, Condat B, et al, Groupe d'Etude de de Traitement du Carcinome Hépatocellulaire. Causes and consequences of portal vein thrombosis in 1,243 patients with cirrhosis: results of a longitudinal study. *Hepatology*. 2015 Feb;61:660–667.
 35. Ghabril M, Agarwal S, Lacerda M, Chalasani N, Kwo P, Tector AJ. Portal vein thrombosis is a risk factor for poor early outcomes after liver transplantation: analysis of risk factors and outcomes for portal vein thrombosis in waitlisted patients. *Transplantation*. 2016 Jan;100:126–133.
 36. Englesbe MJ, Schaubel DE, Cai S, Guidinger MK, Merion RM. Portal vein thrombosis and liver transplant survival benefit. *Liver Transpl*. 2010 Aug;16:999–1005.
 37. Qi X, Dai J, Jia J, et al. Association between portal vein thrombosis and survival of liver transplant recipients: a systematic review and meta-analysis of observational studies. *J Gastrointest Liver Dis*. 2015 Mar;24:51–59, 4 p following 59.
 38. Rodríguez-Castro KI, Porte RJ, Nadal E, Germani G, Burra P, Senzolo M. Management of non neoplastic portal vein thrombosis in the setting of liver transplantation: a systematic review. *Transplantation*. 2012 Dec 15;94:1145–1153.
 39. Stine JG, Pelletier SJ, Schmitt TM, Porte RJ, Northup PG. Pre-transplant portal vein thrombosis is an independent risk factor for graft loss due to hepatic artery thrombosis in liver transplant recipients. *HPB*. 2016 Mar;18:279–286.
 40. Senzolo M, Garcia-Tsao G, García-Pagán JC. Current knowledge and management of portal vein thrombosis in cirrhosis. *J Hepatol*. 2021 Aug;75:442–453.
 41. Luca A, Miraglia R, Caruso S, et al. Short- and long-term effects of the transjugular intrahepatic portosystemic shunt on portal vein thrombosis in patients with cirrhosis. *Gut*. 2011 Jun;60:846–852.
 42. Qi X, De Stefano V, Li H, Dai J, Guo X, Fan D. Anticoagulation for the treatment of portal vein thrombosis in liver cirrhosis: a systematic review and meta-analysis of observational studies. *Eur J Intern Med*. 2015 Jan;26:23–29.
 43. Lv Y, Bai W, Li K, et al. Anticoagulation and transjugular intrahepatic portosystemic shunt for the management of portal vein thrombosis in cirrhosis: a prospective observational study. *Am J Gastroenterol*. 2021 Jul 1;116:1447–1464.
 44. Davis JPE, Ogurick AG, Rothermel CE, Sohn MW, Intagliata NM, Northup PG. Anticoagulation and transjugular intrahepatic portosystemic shunting for treatment of portal vein thrombosis in cirrhosis: a systematic review and meta-analysis. *Clin Appl Thromb Hemost*. 2019 Jan-Dec;25, 1076029619888026.
 45. Valentin N, Weisberg I. The role of transjugular intrahepatic portosystemic shunt in the management of portal vein thrombosis. *Eur J Gastroenterol Hepatol*. 2019;31:403–404.
 46. Rodrigues SG, Sixt S, Abalde JG, et al. Systematic review with meta-analysis: portal vein recanalisation and transjugular intrahepatic portosystemic shunt for portal vein thrombosis. *Aliment Pharmacol Ther*. 2019 Jan;49:20–30.
 47. Lv Y, Qi X, He C, et al, PVT-TIPS Study Group. Covered TIPS versus endoscopic band ligation plus propranolol for the prevention of variceal rebleeding in cirrhotic patients with portal vein thrombosis: a randomised controlled trial. *Gut*. 2018 Dec;67:2156–2168.
 48. Thornburg B, Desai K, Hickey R, et al. Portal vein recanalization and transjugular intrahepatic portosystemic shunt creation for chronic portal vein thrombosis: technical considerations. *Tech Vasc Interv Radiol*. 2016 Mar;19:52–60.
 49. Salem R, Vouche M, Baker T, et al. Pretransplant portal vein recanalization-transjugular intrahepatic portosystemic shunt in patients with complete obliterative portal vein thrombosis. *Transplantation*. 2015 Nov;99:2347–2355.
 50. Wang Z, Jiang MS, Zhang HL, et al. Is post-TIPS anticoagulation therapy necessary in patients with cirrhosis and portal vein thrombosis? A randomized controlled trial. *Radiology*. 2016 Jun;279:943–951.
 51. Vizzutti F, Schepis F, Arena U, et al. Transjugular intrahepatic portosystemic shunt (TIPS): current indications and strategies to improve the outcomes. *Intern Emerg Med*. 2020 Jan;15:37–48.
 52. EASL Clinical Practice Guidelines: Vascular diseases of the liver. *J Hepatol*. 2016;64:179–202.
 53. Ziser A, Plevak DJ, Wiesner RH, Rakela J, Offord KP, Brown DL. Morbidity and mortality in cirrhotic patients undergoing anesthesia and surgery. *Anesthesiology*. 1999 Jan;90:42–53.
 54. Del Olmo JA, Flor-Lorente B, Flor-Civera B, et al. Risk factors for non-hepatic surgery in patients with cirrhosis. *World J Surg*. 2003;27:647–652.
 55. Newman KL, Johnson KM, Cornia PB, Wu P, Itani K, Ioannou GN. Perioperative evaluation and management of patients with cirrhosis: risk assessment, surgical outcomes, and future directions. *Clin Gastroenterol Hepatol*. 2020 Oct;18:2398–2414. e3.
 56. Wong M, Busuttill RW. Surgery in patients with portal hypertension. *Clin Liver Dis*. 2019 Nov;23:755–780.
 57. Jadaun Shekhar S, Saigal Sanjiv. Surgical risk assessment in patients with chronic liver diseases. *J Clin Exp Hepatol*. 2022;12:1175–1183. ISSN 0973-6883.
 58. Neeff H, Mariaskin D, Spangenberg HC, Hopt UT, Makowicz F. Perioperative mortality after non-hepatic general surgery in patients with liver cirrhosis: an analysis of 138 operations in the 2000s using Child and MELD scores. *J Gastrointest Surg*. 2011 Jan;15:1–11.
 59. Azoulay Daniel, Buabse Fernando, Damiano Ivana, et al. Neoadjuvant transjugular intrahepatic portosystemic shunt: a solution for extrahepatic abdominal operation in cirrhotic patients with severe portal hypertension. *J Am Coll Surg*. July 2001;193:46–51.
 60. Schmitz A, Haste P, Johnson MS. Transjugular intrahepatic portosystemic shunt (TIPS) creation prior to abdominal operation: a retrospective analysis. *J Gastrointest Surg*. 2020;24:2228–2232.
 61. Vinet E, Perreault P, Bouchard L, et al. Transjugular intrahepatic portosystemic shunt before abdominal surgery in cirrhotic patients: a retrospective, comparative study. *Can J Gastroenterol*. 2006 Jun;20:401–404.
 62. Tabchouri N, Barbier L, Menahem B, et al. Original study: transjugular intrahepatic portosystemic shunt as a bridge to abdominal surgery in cirrhotic patients. *J Gastrointest Surg*. 2019;23:2383–2390.
 63. Lahat E, Lim C, Bhangui P, et al. Transjugular intrahepatic portosystemic shunt as a bridge to non-hepatic surgery in cirrhotic patients with severe portal hypertension: a systematic review. *HPB*. 2018;20:101–109.
 64. Reverter E, Cirera I, Albillos A, et al. The prognostic role of hepatic venous pressure gradient in cirrhotic patients undergoing elective extrahepatic surgery. *J Hepatol*. 2019;71:942–950.
 65. Rajesh S, George T, Philips CA, et al. Transjugular intrahepatic portosystemic shunt in cirrhosis: an exhaustive critical update. *World J Gastroenterol*. 2020;26:5561–5596.

66. Fares N, Robic MA, Péron JM, et al. Transjugular intrahepatic portosystemic shunt placement before abdominal intervention in cirrhotic patients with portal hypertension: lessons from a pilot study. *Eur J Gastroenterol Hepatol*. 2018 Jan;30:21–26.
67. Gil A, Martínez-Regueira F, Hernández-Lizoain JL, et al. The role of transjugular intrahepatic portosystemic shunt prior to abdominal tumoral surgery in cirrhotic patients with portal hypertension. *Eur J Surg Oncol*. 2004 Feb;30:46–52.
68. De Gottardi A, Rautou PE, Schouten J. Porto-sinusoidal vascular disease: proposal and description of a novel entity. *Lancet Gastroenterol Hepatol*. 2019 May;4:399–411.
69. Gioia S, Nardelli S, Ridola L, Riggio O. Causes and management of non-cirrhotic portal hypertension. *Curr Gastroenterol Rep*. 2020 Sep 17;22:56.
70. Hernández-Gea V, Baiges A, Turon F, Garcia-Pagán JC. Idiopathic portal hypertension. *Hepatology*. 2018 Dec;68:2413–2423.
71. Lv Y, Li K, He C, et al. TIPSS for variceal bleeding in patients with idiopathic non-cirrhotic portal hypertension: comparison with patients who have cirrhosis. *Aliment Pharmacol Ther*. 2019 Apr;49:926–939.
72. Bissonnette J, Garcia-Pagán JC, Albillos A, et al. Role of the transjugular intrahepatic portosystemic shunt in the management of severe complications of portal hypertension in idiopathic noncirrhotic portal hypertension. *Hepatology*. 2016;64:224–231.
73. Regnault D, d'Alteroche L, Nicolas C, Dujardin F, Ayoub J, Perarnau JM. Ten-year experience of transjugular intrahepatic portosystemic shunt for noncirrhotic portal hypertension. *Eur J Gastroenterol Hepatol*. 2018;30:557–562.
74. Nicoletti V, Gioia S, Lucatelli P, et al. Hepatic encephalopathy in patients with non-cirrhotic portal hypertension: description, prevalence and risk factors. *Dig Liver Dis*. 2016 Sep;48:1072–1077.
75. Tripathi D, Stanley AJ, Hayes PC, et al. Transjugular intrahepatic portosystemic stent-shunt in the management of portal hypertension. *Gut*. 2020 Jul;69:1173–1192.
76. Sonavane AD, Amarpurkar DN, Rathod KR, Punamiya SJ. Long term survival of patients undergoing TIPS in Budd-Chiari syndrome. *J Clin Exp Hepatol*. 2019 Jan-Feb;9:56–61.
77. Zahn A, Gotthardt D, Weiss KH, et al. Budd Chiari syndrome: long term success via hepatic decompression using transjugular intrahepatic porto-systemic shunt. *BMC Gastroenterol*. 2010 Mar 1;10:25.
78. Hayek G, Ronot M, Plessier A, et al. Long-term outcome and analysis of dysfunction of transjugular intrahepatic portosystemic shunt placement in chronic primary Budd-Chiari syndrome. *Radiology*. 2017 Apr;283:280–292.
79. Corso R, Intotero M, Solcia M, Castoldi MC, Rampoldi A. Treatment of Budd-Chiari syndrome with transjugular intrahepatic portosystemic shunt (TIPS). *Radiol Med*. 2008 Aug;113:727–738. English, Italian.