

Long term efficacy, safety, and tolerability of tildrakizumab in epileptic patient with psoriasis and eczema

Nicoletta Bernardini, Nevena Skroza, Giovanni Rossi, Alessandra Mambrin, Ersilia Tolino, Federica Marraffa, Martina Caviglia, Antonio Di Guardo, Salvatore Volpe, Iaria Proietti, Concetta Potenza

Department of Medico-surgical Sciences and Biotechnologies, Sapienza University of Rome, Polo Pontino, Italy

Abstract

Psoriasis is a chronic inflammatory disease which mostly affects skin. Tildrakizumab is a specific anti-IL-23p19 monoclonal antibody approved for the treatment of plaque psoriasis in adults. Herein, we report about a patient who came to our attention for a moderate-to-severe plaque psoriasis, involving primarily upper limbs, elbow, abdomen and knees (PASI 18 – DLQI 22). His medical history was relevant for epilepsy controlled pharmacologically. In addition, an eczematous and edematous appearance of the tibial area was detected; the histologic findings did not contradict the diagnostic hypothesis of subacute spongiotic dermatitis. The patient was treated with Tildrakizumab. After 12 weeks the clinical lesions improved significantly, and the eczematous component disappeared in the tibial area bilaterally. The clinical improvement was maintained even after one year of therapy. Tildrakizumab showed excellent results in the control of psoriasis, with an excellent safety profile. The promising results of clinical trials have been confirmed in a real-life setting. There are no reports about its safety in epileptic patients. In our case, neurological adverse events did not verify and tildrakizumab managed to control both the psoriatic and eczematous components.

Introduction

Psoriasis is a chronic inflammatory disease which mostly affects skin, but may also affect the joints and different organ

systems.

Its severity can vary depending on numerous genetic and environmental factors.¹ The IL-23 and the downstream T-helper cell 17 (Th17) pathway are key drivers of psoriasis pathogenesis.^{1,2}

The treatment of psoriasis has undergone a revolution with the advent of biologic therapies that target specific components of the immune system.³

Tildrakizumab is a specific anti-IL-23p19 monoclonal antibody approved in US and Europe for the treatment of moderate-to-severe chronic plaque psoriasis,⁴ which binds specifically to the p19 protein subunit of the cytokine 23 (IL-23) inhibiting its interaction with the specific IL-23 receptor.⁵

The promising results of phase one studies in terms of efficacy of Tildrakizumab (Kopp *et al.*)⁶ have been confirmed by double-blind randomized phase III trials (reSURFACE1 and reSURFACE2);⁷ the rate of severe infections, malignancies, skin cancers, major cardiovascular events, and drug-related hypersensitivity reactions was low.

Case Report

Herein, we describe the case of a 45-year-old man with moderate-to-severe plaque psoriasis.

He had a history of cortical dysplasia, cerebellar vermis atrophy, corpus callosum dysplasia and mono-lateral microgyria determining prominent progressive spastic ataxia, sensory motor axonal neuropathy mild intellectual disability and frequent epileptic events controlled pharmacologically.

The patient came to our attention for a moderate-to-severe plaque psoriasis, involving primarily upper limbs, elbow, abdomen and knees (PASI 18 – DLQI 22). He referred itching, burning and skin tightness. On skin examination skin dryness, cracking, scaling, flaking, redness and bleeding were detectable. In addition, skin lesions not attributable to psoriatic disease were detected on clinical examination. Indeed, eczematous areas and edematous appearance of the tibial areas with hyperpigmented reddish-brown spots were detected. For this reason, an incisional biopsy on tibial area was performed before starting therapy. Histological examination showed a mild and focal orthokeratosis hyperkeratosis, hyper granulosis, spongiotic vesicles with neutrophilic granulocytic infiltrate and sporadic images of lymphocytic exocytosis. Moreover, an inflammato-

Correspondence: Nicoletta Bernardini, Dermatology Unit “Daniele Innocenzi”, “A. Fiorini” Hospital, Via Firenze, 1, 04019, Terracina (LT), Italy.
Tel.: +39.0773.708811.
E-mail: nicoletta.bernardini@libero.it

Key words: Psoriasis, Eczema, Tildrakizumab.

Contributions: NB, NS: conception and study design. GR, AM, ET and IP: writing-original draft. MC, ADG, FM, SV: writing-review and editing. CP: supervision.

Conflict of interest: The authors declare no potential conflict of interest.

Funding: None.

Informed consent statement: The patient has given written informed consent to the publication of his case details.

Availability of data and material: Data and materials are available by the authors.

Received for publication: 22 December 2021.
Accepted for publication: 16 September 2022.

This work is licensed under a Creative Commons Attribution-NonCommercial 4.0 International License (CC BY-NC 4.0).

©Copyright: the Author(s), 2022

Licensee PAGEPress, Italy
Dermatology Reports 2022; 14:9447
doi:10.4081/dr.2022.9447

Publisher's note: All claims expressed in this article are solely those of the authors and do not necessarily represent those of their affiliated organizations, or those of the publisher, the editors and the reviewers. Any product that may be evaluated in this article or claim that may be made by its manufacturer is not guaranteed or endorsed by the publisher.

ry lymphocytic infiltrate circumscribed the ectatic vessels of the superficial dermis. The morphologic findings described did not contradict the diagnostic hypothesis of subacute spongiotic dermatitis.

The patient had previously been treated with cyclosporine, acitretin and systemic steroids, which proved ineffective.

Considering this clinical information, we started treatment with Tildrakizumab 100 mg every 12 weeks in March 2020. After 12 weeks the clinical lesions improved significantly, and the eczematous component disappeared in the tibial area bilaterally. The clinical improvement was maintained even after one year of therapy with Tildrakizumab as showed in Figure 1.

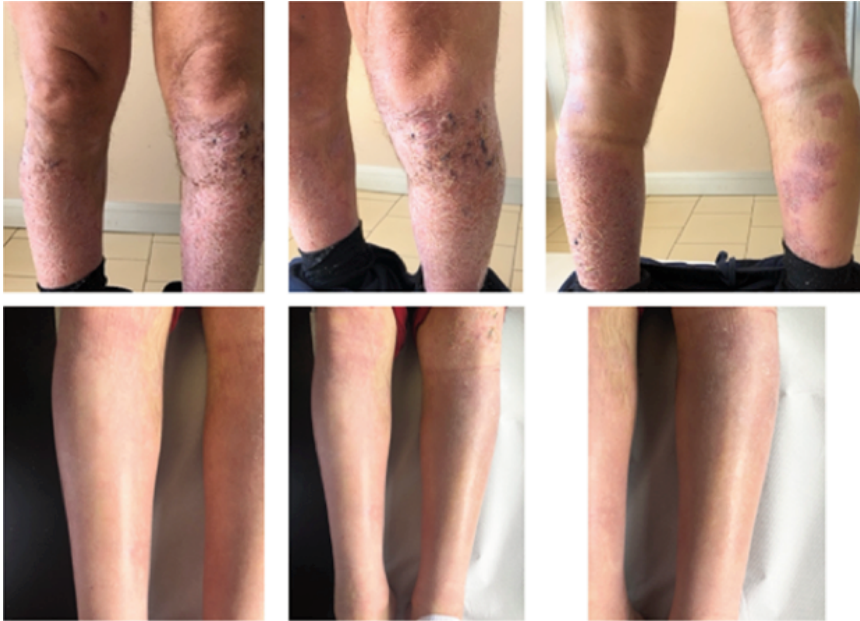


Figure 1. Clinical improvement after 12 weeks of treatment with tildrakizumab.

Discussion

As demonstrated elsewhere, tildrakizumab showed excellent results in the control of psoriasis in the short term, with an excellent safety profile. The promising results of the clinical trials have been confirmed even in a real-life setting.⁸

Consistently with the literature, our case confirms the long-lasting durability of the therapeutic effects of tildrakizumab. This sustained response over time has been related to inhibition of IL-23, which acts upstream in the IL-23/Th17 pathway.⁹

Tildrakizumab is a valid therapeutic choice in special population including patients with IBD, cardiovascular disease, metabolic syndrome, advanced age, and history of malignancy; however, there are no reports about its safety in epileptic patients. In our case, neurological adverse events did not verify. Furthermore, there is a growing body of evidence about the involvement of inflammatory mediators-released by brain cells and peripheral immune cells in both the origin of individual seizures and the epileptogenic process, which include the IL23-Th17 axis.¹⁰

In addition, our patient had a histologically demonstrated eczematous component. Historically, psoriasis and eczema were considered as opposite diseases, especially

regarding their pathophysiology, psoriasis being Th17 dominant and eczema being Th2 dominant. However, it is now recognized that these entities can co-exist.¹¹ In our case, it is interesting to note that tildrakizumab managed to control both the psoriatic and eczematous components. Moreover, there are anecdotal reports of IL12/23 inhibitors in atopic dermatitis with good outcomes, highlighting that the impact of anti-IL-12/IL-23p40 therapy in eczematous diseases is still unclarified.¹²

Conclusions

Our case highlights that tildrakizumab is a promising drug for the biological treatment of plaque psoriasis in the moderate or severe stage and confirms its safety and efficacy even in special populations and the complex settings offered by the real-life practice.

References

1. AlQassimi S, AlBrashdi S, Galadari H, Hashim MJ. Global burden of psoriasis - comparison of regional and global epidemiology, 1990 to 2017. *Int J*

Dermatol 2020;59:566-71.

2. Rendon A, Schäkel K. Psoriasis Pathogenesis and Treatment. *Int J Mol Sci* 2019;20:1475.
3. Sivamani RK, Goodarzi H, Garcia MS, et al. Biologic therapies in the treatment of psoriasis: a comprehensive evidence-based basic science and clinical review and a practical guide to tuberculosis monitoring. *Clin Rev Allergy Immunol* 2013;44:121-40.
4. Reich K, Warren RB, Iversen L, et al. Long-term efficacy and safety of tildrakizumab for moderate-to-severe psoriasis: pooled analyses of two randomized phase III clinical trials (reSURFACE 1 and reSURFACE 2) through 148 weeks. *Br J Dermatol* 2020;182:605-17.
5. Tildrakizumab, Summary of Product Characteristics.
6. Kopp T, Riedl E, Bangert C, et al. Clinical improvement in psoriasis with specific targeting of interleukin-23. *Nature* 2015;521:222-6.
7. Reich K, Papp KA, Blauvelt A, et al. Tildrakizumab versus placebo or etanercept for chronic plaque psoriasis (reSURFACE 1 and reSURFACE 2): results from two randomised controlled, phase 3 trials. *Lancet* 2017;390:276-88.
8. Drerup KA, Seemann C, Gerdes S, Mrowietz U. Effective and Safe Treatment of Psoriatic Disease with the Anti-IL-23p19 Biologic Tildrakizumab: Results of a Real-World Prospective Cohort Study in Nonselected Patients. *Dermatology* 2021;1-5.
9. Di Cesare A, Di Meglio P, Nestle FO. The IL-23/Th17 axis in the immunopathogenesis of psoriasis. *J Invest Dermatol* 2009;129:1339-50.
10. Mao LY, Ding J, Peng WF, et al. Interictal interleukin-17A levels are elevated and correlate with seizure severity of epilepsy patients. *Epilepsia* 2013;54:e142-5.
11. Barry K, Zancanaro P, Casseres R, et al. Concomitant atopic dermatitis and psoriasis - a retrospective review. *J Dermatolog Treat* 2021;32:716-20.
12. Husein-ElAhmed H, Steinhoff M. Effectiveness of ustekinumab in patients with atopic dermatitis: analysis of real-world evidence. *J Dermatolog Treat* 2021;1-6.