

How to perform shear wave elastography. Part II

Giovanna Ferraioli¹, Richard G Barr², André Farrokh³, Maija Radzina⁴, Xin Wu Cui⁵, Yi Dong⁶, Laurence Rocher⁷, Vito Cantisani⁸, Eleonora Polito⁸, Mirko D’Onofrio⁹, Davide Roccarina^{10,11}, Yasunobu Yamashita¹², Manjiri K. Dighe¹³, Daniela Fodor¹⁴, Christoph F Dietrich¹⁵

¹Department of Clinical, Surgical, Diagnostic and Pediatric Sciences, Medical School University of Pavia, Pavia, Italy, ²Northeastern Ohio Medical University, Rootstown, Ohio, USA, ³University Hospital Schleswig-Holstein, Campus Kiel, Department of Gynecology and Obstetrics, Germany, ⁴Paula Stradina Clinical University Hospital, Diagnostic Radiology Institute University of Latvia, Medical Faculty Radiology Research Laboratory, Riga Stradins University Riga, Latvia, ⁵Sino-German Tongji-Caritas Research Center of Ultrasound in Medicine, Department of Medical Ultrasound, Tongji Hospital, Tongji Medical College, Huazhong University of Science and Technology, Wuhan, China, ⁶Department of Ultrasound, Zhongshan Hospital, Fudan University, Shanghai, China, ⁷Service de Radiologie, APHP Hôpitaux Paris Saclay, Hôpital Antoine Bécélère, Clamart, France. Université Paris Saclay, Le Kremlin-Bicêtre, France, ⁸Department of Radiology, Oncology, Anatomic-Pathology, Sapienza-University of Rome, Rome, Italy, ⁹Department of Radiology, University Hospital G.B. Rossi, University of Verona, Italy, ¹⁰Sheila Sherlock Liver Unit and UCL Institute for Liver and Digestive Health, Royal Free Hospital, London, UK, ¹¹SOD Medicina Interna ed Epatologia, Azienda Ospedaliero-Universitaria Careggi, Florence, Italy, ¹²Second Department of Internal Medicine, Wakayama Medical University, Wakayama, Japan, ¹³Department of Radiology, University of Washington, Seattle, USA, ¹⁴2nd Internal Medicine Department, “Iuliu Hatieganu” University of Medicine and Pharmacy, Cluj-Napoca, Romania, ¹⁵Department Allgemeine Innere Medizin (DAIM), Kliniken Hirslanden Beau Site, Salem und Permance, Bern, Switzerland

Abstract

Recently a series of papers was introduced describing on “how to do” certain techniques. More specifically we published on how to perform strain imaging using the transcutaneous and endoscopic ultrasound approach and shear wave elastography (SWE). In the first part we describe how to optimize the examination technique, discussing normal values, pitfalls, artefacts and specific tips for applying SWE to specific organs (liver, breast, thyroid, salivary glands) as part of a diagnostic US examination. In part II, the use of SWE in the pancreas, spleen, kidney, prostate, scrotum, musculoskeletal system, lymph nodes and future developments are discussed.

Keywords: ultrasound; shear wave elastography; elastometry; guideline

Introduction

In the first part on how to perform shear wave elastography (SWE) we described how to optimize the ex-

amination technique, discussing normal values, pitfalls, artefacts and specific tips for applying SWE to specific organs (liver, breast, thyroid, salivary glands) as part of a diagnostic US examination.

In part II, the use of SWE in the pancreas, spleen, kidney, prostate, scrotum, musculoskeletal system, lymph nodes and future developments are discussed. It describes how to optimize the examination technique, discussing normal values, and pitfalls and artifacts. The manuscript provides more specific tips for applying SWE to specific organs as part of a diagnostic US examination [1-11].

Received 05.03.2021 Accepted 25.05.2021

Med Ultrason

2022, Vol. 24, No 2, 196-210

Corresponding author: Prof. Christoph F. Dietrich

Department Allgemeine Innere Medizin (DAIM),

Kliniken Hirslanden Beau Site,

Salem und Permance, Bern, Switzerland

Phone: +41798347180

E-mail: c.f.dietrich@googlemail.com

Pancreas

Main objective, clinical value

SWE is able to assess the biomechanical properties of tissue; generally, malignant lesions are stiffer than the healthy parenchyma [12-23]. Principal applications are: assessment of diffuse pancreatic diseases, e.g., to determine fibrosis and autoimmune diseases [24,25]; characterization of pancreatic lesions as stiff, therefore suspected for pancreatic cancer; guiding biopsy in the stiff part of a focal area; characterization of pancreatic gland stiffness in suspected chronic pancreatitis; evaluation of the pancreatic gland stiffness before surgical resection to predict fistula complication; assessment of the response to treatment of autoimmune pancreatitis.

Due to its limited clinical role in the differential diagnosis, elastography cannot replace pathologic examination with FNA or biopsy.

“Knobology”

SWE is performed with the transabdominal approach. By using 2D-SWE, results can be both qualitative and quantitative.

Prerequisites

A correct visualization of the pancreatic gland in B-mode is of utmost importance. Pancreatic gland and peri-pancreatic area must be perfectly explorable without gas interposition along the path of the US beam.

Select an appropriate transducer

The convex probe is used because it allows the exploration of the retroperitoneum and the pancreatic area that is located in a deep plane.

Patient preparation and compression technique

Pancreatic US examination is generally performed after a minimum fasting period of 6 hours, thus ensuring an empty stomach and limiting overlying bowel gas. To completely visualize the pancreas, it is sometimes useful to examine the patient during an inspiration or expiration. Compression with the transducer to displace bowel gas may allow to visualize the retroperitoneum and to improve the visualization of the pancreatic gland. Therefore, the maneuver of filling the stomach with water is contraindicated because it may introduce air into the stomach and may decrease the degree of the abdominal compression.

If the visualization of the pancreas is poor in the supine position, it is suggested to change to the upright position or to left/ right decubitus in order to move the stomach, the bowel loops and the transverse colon away from the path of the US beam. Gradual and progressive compression is generally mandatory for better pancreatic gland visualization and therefore for elastography examination performed by means of the percutaneous approach.

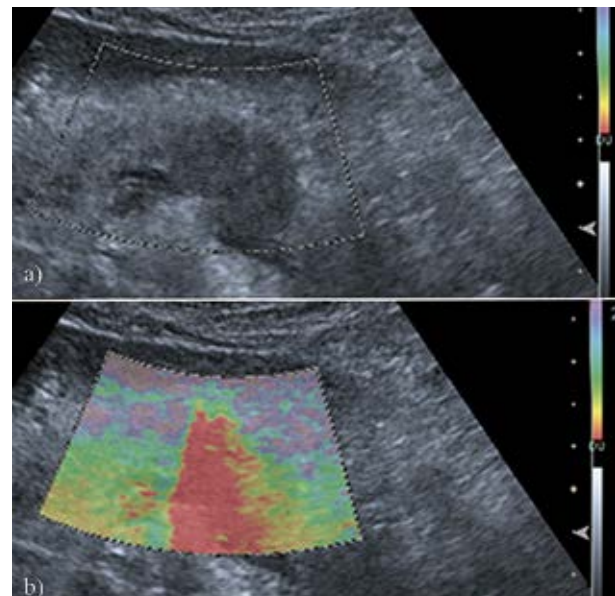


Fig 1. Adenocarcinoma of the pancreas body: (a) 2D-SWE box includes both the hypoechoic mass and the surrounding tissue for comparison of relative stiffness: (b) The hypoechoic mass is stiffer (red).

Region of interest (ROI) size, shape, others

ROI size should be changed depending on the structure under examination. The 2D-SWE FOV box must be sufficiently large to contain both the area to be examined and the surrounding tissue for comparison of relative stiffness (fig 1). However, by increasing the ROI size the examination time may unnecessarily increase, due to the difficulty in obtaining a correct elastogram. In fact, movement artefacts could affect the image quality and the final result. The ROI size must allow comparison with adjacent parenchyma; however, the inclusion of unnecessary structures, such as the peripancreatic area, must be avoided. pSWE has a fixed ROI.

Description of quality parameters

During the elastographic examination with 2D-SWE, the absence of adequate color filling indicates a bad quality measurement. More than one measurement must be performed to improve the quality of the study.

Checking reproducibility

Large lesions should be evaluated in more than one point and with more than one measurement to confirm the obtained data. Malignant lesions are often very heterogeneous in stiffness and therefore need to be completely evaluated. In these case 2D-SWE is recommended because the color display helps in determining the area of the highest stiffness.

Tips and tricks

Percutaneous SWE of the pancreas requires the correct visualization of the pancreatic gland by means of

B-mode US. A thorough B-mode and Doppler study must be performed before elastography. If a contrast-enhanced US study is required to characterize masses, it must be performed after SWE examination to avoid artifacts from microbubbles. Regarding the methodology, more than one elastogram and more than one measurement must always be performed for each examination. It is reported that five measurements need to be performed for each lesion or area under investigation [3]. To avoid artifacts and invalid measurements, vessels must not be included in the ROI. Also, bowel and calcifications must be avoided during ROI placement for analysis.

Reference values

As reported in literature, the mean shear wave speed (SWS) value obtained with pSWE in healthy pancreas is around 1.40 m/s [8]. Higher values suggest that the tissue is stiffer than a healthy pancreas, especially in case of ductal adenocarcinoma if a pancreatic mass is under investigation.

What to avoid

For the study of the pancreas, it is very important to consider an US multiparametric approach and to perform all the available techniques in the correct order. An artifact that may appear when contrast-enhanced US is performed before Doppler study or elastography must be avoided.

Specific artifacts

The most important artifacts are due to movements during the examination. Motion artifacts are related to the patient and/or structures near the ROI, such as the bowel or the vessels. Air through the bowel or the stomach within the path of the US beam leads to artifacts that are visible as meteorism artifacts during the examination.

Pancreas: endoscopic SWE

Endoscopic ultrasonography (EUS) elastography is a novel diagnostic method based on measurement of tissue elasticity. Until recently, strain elastography was the only technique available for EUS studies. Currently, only the ARIETTA 850 US system (Fujifilm, previously Hitachi Ltd, Japan) with a convex endoscope can perform SW-EUS. The system automatically calculates the proportion of the net amount of effective SWS for each measurement. This reliability criterion is the VsN. The 10 consecutive measurements together with the VsN of each measurement are displayed on the screen. There are only two published studies with promising results, one was performed in patients with chronic pancreatitis and the other one assessed activity in autoimmune pancreatitis [20,26].

How to use SWE

1. The pancreatobiliary region should be studied initially with conventional US imaging to determine the target area.

2. Check whether the B-mode EUS image is drawn in detail up to an area of 30 degrees to the left and to the right from the center of ROI.
3. The ROI may have a size of 0.5 cm, 1.0 cm, and 1.5 cm. As a point of caution, when a small ROI is selected, the number of samples for measuring SWS is decreased. An ROI of 0.5 cm in size is often selected to position the ROI within the target in chronic pancreatitis and small lesions.
4. Check whether the depth of the ROI is within 30 mm and the ROI is set within the target.
5. The ROI should be set avoiding blood vessels, reverberation areas, pancreatic ducts, and areas of shadowing.

Tips and Tricks

1. When performing SW-EUS, the compression with the EUS probe must be avoided, because it may cause an increase in stiffness.
2. In order to obtain a stable measurement, the acquisition must be launched while the patient holds the breath.
3. With the Hitachi system, the VsN shows whether the measurement is appropriate. For liver, it is reported that the measurement is reliable when the VsN is 50% or higher [27,28].

Reference values

Normal pancreatic parenchyma: mean SWS value ranges from 1.52 m/s to 1.99 m/s. SWS cut-off value for diagnosing chronic pancreatitis: 2.19 m/s.

Spleen

Main objective, clinical value

The spleen is the largest lymphatic organ in the human body and plays multiple roles as formation, storage, release and breakdown of blood cells, as well as taking part to the immune response with the biosynthesis of antibody by lymphocytes in splenic lymph follicles [29]. Due to the multiple roles played by this organ, several local and systemic diseases as infectious diseases, hemolytic anemia, myeloproliferative disorders, lymphoproliferative diseases, acute leukemia or autoimmune diseases, can cause splenomegaly and increase the spleen stiffness (SS). Moreover, the splenic vein is directly connected to the portal vein and diseases that affect the blood flow of the portal vein might decrease the ability of the blood to drain from the spleen through the splenic vein, causing an increase of the pressure inside the spleen, which makes it stiffer. For this reasons, the spleen is an important target organ for the use of elastography and portal hypertension is the main field where the usefulness of elastography in the diagnostic process of liver fibrosis,

portal hypertension (PH), esophageal varices (EVs) as well as risk of upper-gastrointestinal (UGI) bleeding has been largely proved [30].

“Knobology”

Prerequisites

Since all studies carried out on splenic stiffness (SS) assessment applied the same main rules approved for the measurement of liver stiffness (LS), at the moment, despite its increasing use, there is a lack of guidelines about the application of validated criteria to obtain a valid SS value and thus the criteria validated for LS assessment are generally applied [3]. Spleen elastography should be performed after at least 3 hours of fasting and after at least 10 minutes of rest, with the patient in dorsal decubitus and with the left arm in maximal adduction [31-33].

TE: Probe selection

Usually, spleen stiffness assessed by VCTE is performed US-guided and the transducer should be placed between the left intercostal spaces in an area with a good ultrasound window [34].

ARFI-based techniques: transducer (frequency) selection

In adults, the convex transducer is used for performing the elastography studies. There is only one study on SS assessed in a pediatric population and the convex transducer was used [35]. Despite the lack of data, the transducer, either the linear or the curvilinear one, might be chosen depending on the body habitus and age of the patient, as we do for the assessment of the LS in children. However, when using the linear transducer, the different stiffness values, given in the same subject due to the difference in frequency between the two probes, needs to be kept in mind.

Description of (other) parameters

The strength of the push-pulse is higher in the center of the transducer, thus the sampling should be done in the central area of the image, whereas the sampling at the edge should be avoided. The influence of depth on the estimation of the elastic properties is not negligible [36] since the acoustic push pulse is progressively attenuated as it traverses the tissue.

Region of interest (ROI) size, shape, others

The region of interest (ROI) should be placed straight ahead (perpendicular) at least 2 cm below the capsule, with the measurement preferably being performed at the inferior pole (fig 2) [37-39]. In pSWE the size of the region of interest (ROI) is small and fixed by the manufacturer because the technique assesses the stiffness at a single location by using a sequence of push-pulses. In 2D-SWE the size of the ROI is user-adjustable and can theoretically be as large as the B-mode image. However, the larger the ROI the higher the risk of including ar-

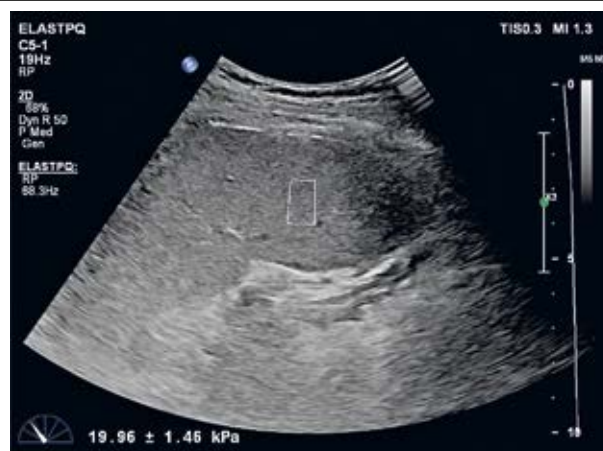

Fig 2. Spleen stiffness measurement with the region of interest placed at the inferior pole of the spleen.

tifacts in the measurement. Thus, generally the ROI's size in SWE technique may influence the quality of the elastogram. There are no guidelines on the ROI size for the SS assessment. Thus, following EFSUMB guidelines and recommendations for LS, we suggest using an ROI of 2.5x2.5 cm in size [3].

Position of the transducer

The measurements should be performed through the intercostal space rather than the subcostal approach yielding the highest intra- and interobserver agreement.

Description of quality parameters

At the moment there are no established quality criteria for a good quality SS measurement. Thus, we apply the most important criterion for a LS measurement of good quality, which is an IQR/M \leq 30% when the results are reported in Young's modulus. This ratio, in fact, is a measure of the variability between consecutive acquisitions, and studies on LS reported a decrease in accuracy when this criterion was not fulfilled [40-44].

Pre-compression

Pre-compression in general should be avoided.

How many measurements?

Ten valid measurements are recommended when using VCTE. For the pSWE technique the EFSUMB and WFUMB guidelines recommend using the median value of 10 acquisitions [3,4,9]. SS measurement assessed using 2D-SWE has been investigated in very few studies, so data on the number of valid measurements needed are not available at the moment.

Applicability and reproducibility

VCTE has an applicability of approximately 70%, mainly because of high BMI, presence of ascites, lung or colonic gas interposition, transverse spleen diameter $<$ 4 cm [33,34,45] or patients who reach the maximum value (75 kPa) measured by the conventional machine

[33,45]. pSWE has applicability better than VCTE; however, it is lower compared to the applicability for LS assessment due high BMI or small spleen size [46]. Insufficient data are available regarding the applicability of 2D-SWE. Reproducibility of VCTE is good with an ICC of 0.89 in patients with chronic liver disease and it depends on the operator experience. Data on the reproducibility of pSWE are scarce but inter-observer variability seems to be acceptable even though lower to that of LS. No data are available on 2D-SWE reproducibility [47].

How to use SWE

The transducer should be positioned in an intercostal space, perpendicular to the spleen, avoiding the ribs or the lung artifacts. The quality of the B-mode US image affects the quality of the SWE acquisitions. The most common limitations encountered with US, i.e. poor acoustic window, limited penetration, and rib or lung shadowing, may influence both the feasibility and the performance of the SWE techniques. Some of these limitations can be avoided, thus the operator should obtain a correct scan of the spleen before launching the acquisition. The perpendicular position of the transducer can be assessed by looking at the spleen capsule that appears as a sharp white line, parallel to the transducer's line. Motion of the probe or of the patient affects the quality of the measurement as well.

Normal reference values

Normal SS values, assessed in healthy volunteers, depend on the elastography technique used and, in case of same technique, on the manufacturer. Approximately, normal SS values are 20.5 kPa, 22.01 kPa and 18.14 kPa with 2D-SWE, VCTE and pSWE, respectively [33,48,49].

What to avoid?

Eating may increase the stiffness of the spleen; thus, measurements are performed in the fasting status. Spleen stiffness does not necessarily reflect portal hypertension but can reflect other physiological or pathological conditions as well, including hematologic or infectious diseases.

Kidney

Main objectives, clinical value

Stiffness values of the kidney have been evaluated using both p-SWE and 2D-SWE to assess chronic renal disease, hydronephrosis, renal transplants and renal masses [50-59]. SWE is performed by applying several ARFI pulses, which cause the formation of shear waves perpendicular to them. The SWS is estimated by monitoring the tissue displacement caused by the shear waves with B-mode US [6]. In order to estimate an accurate

shear wave speed there needs to be adequate displacement of tissue by the shear waves as well as adequate signal to noise. Shear waves are attenuated and refracted. It is well known that refractive artifacts cause an artifactual increased in stiffness in the approximately 1.5 cm below the liver capsule [8,60]. We expect the same to occur with the renal capsule. Several reports of the use of SWE to evaluate both normal and abnormal kidneys have inconsistent results irrespective of ultrasound vendor [50-52,54-59,61]. The kidney is a complex organ with cortex, medulla, central fat, vasculature, collecting system and a capsule. The medulla is composed of tubules that are aligned perpendicular to the renal capsule and are therefore anisotropic. Therefore, the positioning of transducer to the medulla will affect SWS estimates substantially. Diffusion MRI has shown the fractional anisotropy of approximately 22% in the renal cortex and 40% in the renal medulla [62]. Shear wave propagation is highly sensitive to tissue anisotropy with the shear wave speeds higher when propagating along spatially oriented structures than those perpendiculars. This difference is apparent when evaluating muscles with shear wave imaging [63]. The renal cortex is approximately 1.2-2 cm thick. If similar refractive artifacts occur as with the liver capsule it is possible that accurate SWS estimates cannot be calculated in the renal cortex near the renal capsule [60]. Anisotropy is present in the renal cortex due to the spherical glomeruli and proximal and distal tubules which have a convoluted shape [64]. Other possible confounding factor includes intrarenal pressure. It is well known that increases in perfusion pressure will increase stiffness values [53].

A recent study [65] evaluating the raw data from renal SWE demonstrated that accurate SWS estimates could not be obtained from most vendors systems. The displacement curves were evaluated from several manufacturers to determine if accurate shear wave speeds could be estimated in the kidney, both cortex and medulla. Based on the displacement curves both p-SWE and 2D-SWE techniques were not capable in obtaining accurate stiffness values most likely due to artifacts from reverberation from the renal capsule and/or anisotropy of the kidney (fig 3). However, introduction of new software by one vendor appears to overcome this problem (fig 4). It is therefore uncertain if any of the literature on renal SWE is accurate. Although the results may be reproducible, they are most likely inaccurate. Although all vendors have rejections algorithms, they are not accurate enough to reject all data sets that are not able to calculate accurate SWS. Improved algorithms are needed that more accurately provide a quality measure of the SWS estimation. No studies with the new software available

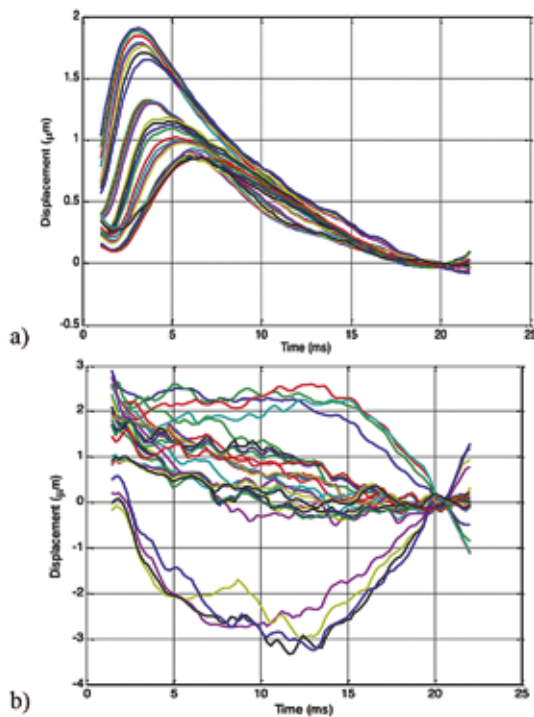


Fig 3. a) Displacement curves obtained from a normal liver. Note the nice family of curves from which the time to peak and distance from the ARFI pulse can be obtained to generate the slope of the line to accurately estimate the shear wave speed; b) One example from one vendor of the displacement curves from a normal renal cortex. Note that the time to peak is not clearly evident and estimates of SWS could not be estimated accurately from these curves. Copied with permission from reference 51.

from the one vendor with the new renal algorithm are yet published. Clinical studies are needed also to assess whether the raw data of this new algorithm can overcome the limitations of the existing algorithms.

Kidney elastography may be feasible, however specific/unique shear wave generation pulsing and processing algorithms may be needed.

Prostate

Main objective, clinical value

Prostate cancer (PCa) is the most common non-skin cancer diagnosed in men. PCa is typically stiffer than the surrounding normal prostate parenchyma, and preliminary studies have shown that SWE has high sensitivity, specificity, and negative predictive value (all >90%) when compared to current modalities in the peripheral zone. This high NPV especially will allow patients with high prostatic specific antigen (PSA) levels but negative elastic examinations to be monitored and spared the usual sextant biopsy [66,67]. One disadvantage of SWE is

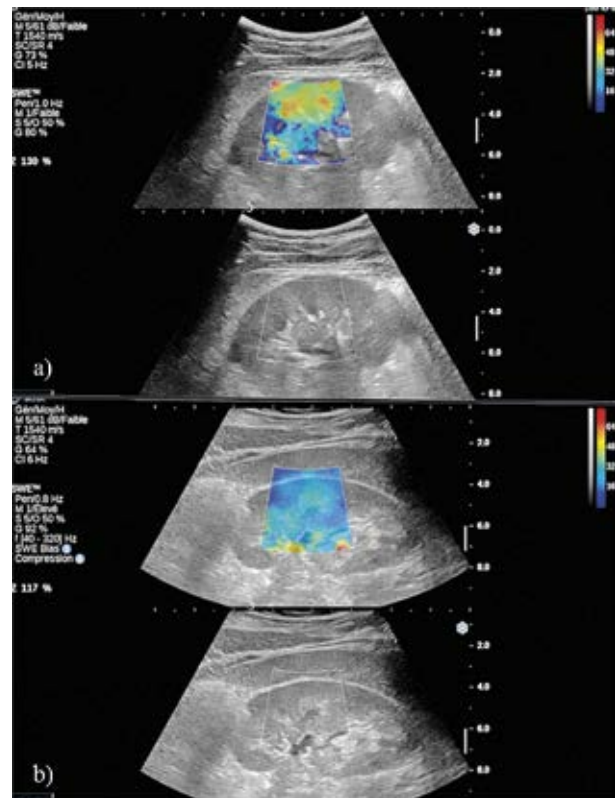


Fig 4. 2D-SWE from one vendor demonstrating using (a) the old algorithm (that used for liver) and the new algorithm (b) used exclusively for kidney imaging. Note the marked difference in the SWS estimates, the heterogeneous speeds using the old algorithm and the more uniform values using the new renal specific algorithm. Copied with permission from reference 51.

that benign prostatic hypertrophy (BPH) is also stiff and limits prostate SWE in the evaluation of the transitional zone and anterior gland [66].

“Knobology”

Most vendors have preset values for SWE on the endocavity probes for prostate SWE. These work very well, and changes are usually not required. If using a real time 2D-SWE system remain at each location for 3-4 seconds for the SWE to stabilize. Do not move the transducer while obtaining SWE measurements. For one-shot 2D-SWE technique hold the transducer still for each measurement. Setting the stiffness scale around 70-90 kPa is helpful as most nodules stiff enough to be a cancer will appear red while benign tissue will appear blue (fig 5).

Prerequisites

To be able to localize areas of increased stiffness suggestive of a prostate cancer and to be able to guide a biopsy 2D-SWE is required. With p-SWE it is not possible to identify the area(s) of concern in a timely fashion or accurately. A complete prostate TRUS exam should be per-

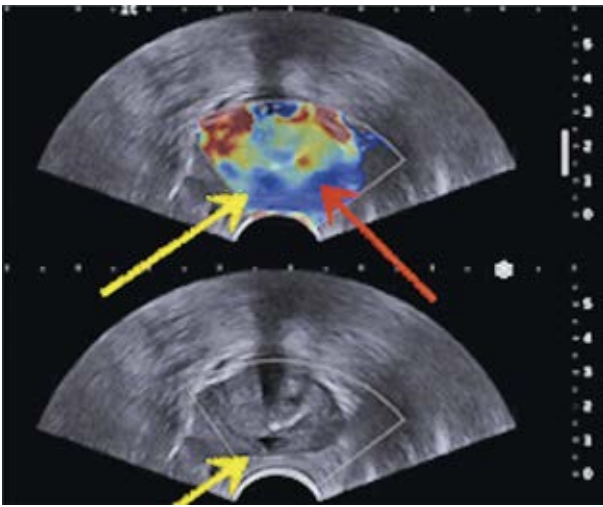


Fig 5. Transrectal 2D-SWE demonstrates a patient with a hypoechoic nodule on B-mode (yellow arrow), which has a low stiffness on SWE (20 kPa) and was biopsy proven benign. Another lesion is identified (red arrow) that has a high stiffness (75 kPa) with no B-mode correlate. The lesion was a Gleason 7 lesion on biopsy.

formed before performing the SWE examination. That examination should include B-mode imaging as well as colour or power Doppler through the whole gland. There is not patient preparation needed although some recommend an enema before performing the examination.

Select an appropriate transducer

The examination should be performed using an endocavitary transducer, which has shear wave capabilities. These are usually 5 MHz to 9 MHz transducers. An end fire or side fire transducer can be used. The transducer should be covered with a transducer cover and high-level disinfection of the transducer used after the procedure [66].

Patient preparation and compression technique

Prostate SWE is also conducted after a complete evaluation of the prostate using B-mode and color or power Doppler imaging, with the patient lying in the left lateral position [66,68]. Some recommend the use of lidocaine gel applied to the anus/rectum to help reduce discomfort with the examination. SWE mode is activated and the gland evaluated in the axial position from the apex to the base using light pressure. Each suspicious focal lesion is analyzed, avoiding any pressure on the transducer. Optimized settings should include maximized penetration and appropriate elasticity scale (70–90 kPa). The entire gland can also be scanned to detect stiff areas in the transverse plane. The SWE box is enlarged to the maximum to cover as much of the gland as possible. If the gland is large scanning the right lobe then the left lobe can be done. The prostate is scanned from base to apex, and cine

loops are stored. For each plane, the transducer is maintained in a steady position for 3 to 4 sec. until the signals stabilize.

Region of interest (ROI) size, shape, others

Hypo-echoic lesions coded stiff (red) are highly suspicious for malignancy. The digital cine loop can be reviewed, and the ROI can be positioned over suspicious areas detected on either B-mode or SWE, even during the review process. The elasticity values (mean, standard deviation, min and max) are then calculated for each ROI. The ROI should be adjusted as to only include the nodule.

Description of quality parameters

No specific quality parameters are advised for prostate SWE. However, confirming that the normal peripheral zone tissue is within the normal range of stiffness will help to confirm that added pressure from the transducer is being applied.

Checking reproducibility

After taking the cine clips of the entire gland, repositioning the transducer to confirm results on each lesion of concern can be performed.

Tips and tricks

1. Hold the transducer lightly as not to apply added pressure
2. For more accurate measurements try to center the area of concern in the middle of the image
3. The use of lidocaine gel may help decrease patient discomfort and allow for a better examination
4. In most systems the 2D-SWE FOV is not large enough to image the entire gland. In those cases, scan the right lobe and left lobes separately

Normal results and reference values

Several studies have used a cut-off value of 35 kPa for characterization of prostate nodules as benign or malignant. With this cut-off value, the sextant-level sensitivity, specificity, PPV, NPV, and AUROC for differentiating benign from malignant lesions were 96%, 85%, 48%, 99%, and 95%, respectively [67,69].

What to avoid

Precompression (preload) should be avoided as this can increase the stiffness value of both normal and abnormal tissues. The exam should be done with a light touch. Since the endocavitary probe is curved evaluating the area of concern in the center of the transducer may be better results. Obtaining measurements obtained at the sides of the image may have different pressures applied and therefore give less accurate results [66].

Specific artifacts

Prostate calcifications, which are usually benign, will give higher stiffness values and can be mistaken for a malignancy. Comparison to the B-mode image is important to avoid this pitfall [66,68].

Scrotum

Main objectives, clinical value

SWE has a limited value in the assessment of scrotal pathology. It must be emphasized that some pathological process such as infarcts, hematoma and dermoid cyst may also mimic a testicular tumor. Proper and accurate characterization of such lesions is highly important, as their management can range from a conservative approach to surgical resection. SWE can have an added value but is not conclusive. Testicular SWE has also been used as a functional biomarker in male infertility (obstructive versus non-obstructive azoospermia) and varicocele with significant results, but overlapped values do not prompt sonographers to use it routinely [70]. SWE may be also used to detect palpable extra testicular lesions, such as adenomatous tumor, which may be isoechoic and poorly vascularized but quite stiff at elastography.

“Knobology”

An accurate B-mode is obtained using a linear probe, with sufficient gel in order to avoid the trapped air in the scrotal hair and the pleated pattern of the scrotal skin. In case of thickened skin, the thinnest approach will be privileged. When evaluating a lesion depicted on B-mode, the examiner must not move the US probe while the elastogram is being created. An appropriate stiffness scale should be initially used: as the testis is a quite smooth organ with 2.4 kPa in the middle and the hilum and the periphery, a scale of 20 kPa is initially recommended (fig 6). It could be adapted afterwards if the lesion is stiff; however, the possible heterogeneity on the elastogram should be shown.

Quantitative analysis

After acquired the elastogram of the lesion, a measurement box will be placed on the whole lesion (E mean),

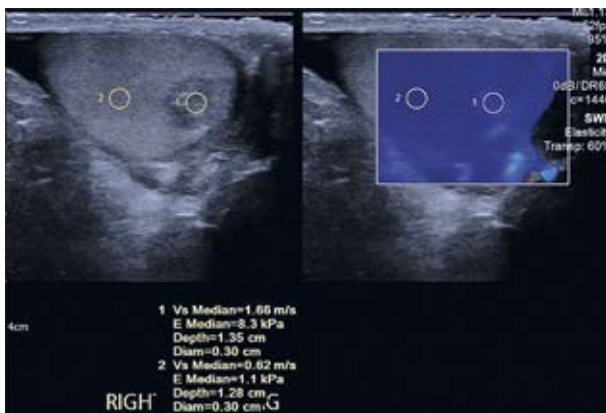


Fig 6. 2D-SWE of a testis with a small tumor. Note the uniform stiffness of the normal testes with a stiffness of 1.1 kPa (0.62 m/s). The mass has a higher stiffness of 8.3 kPa (1.66 m/s).

and another one in the normal parenchyma (E ref) in order to obtain a ratio. If there is no normal parenchyma, the contralateral testis could be used as reference. Another measurement box will be placed in the stiffest part of the lesion, determined by varying the scale (E_{max}), and another ratio is then obtained between the stiffest part of the lesion and the normal parenchyma. This last parameter seems the most accurate to differentiate malignant or burned-out tumors from benign Leydig cell tumors.

What to avoid?

Excessive compression should be avoided. In cryptorchidism, when the testis is located in the groin space, it is naturally compressed by surrounding tissue and the stiffness is therefore increased.

Specific artifacts

Because of the low stiffness of the testis, some “push” artifacts are frequently observed especially if the scale is low. In our experience, they are more frequent in the longitudinal view compared to the axial view. Some filling defects could be observed in some very stiff lesions, and a ROI should not be placed in such areas. If available, a penetration mode can be chosen, in order to improve the elastogram).

Normal values

Testicular SWS in healthy men assessed using 2D-SWE at the poles varied from 0.9 to 1.15 m/s, which correspond approximately to stiffness values in kPa ranging from 2.4 to 4.0 kPa [71]. Those values are quite similar compared to Rocher’s study (using the same US scan): 2.4 kPa (IQR 2, 2.9) [70]. Testicular stiffness is negatively correlated with age [72]. 2D-SWE: inner part of the testis: 2.4 kPa (IQR 2, 2.9); hilum: ~ 10 kPa.

Musculoskeletal system

Main objective, clinical value

US examination is one of the first-choice diagnostic methods in patients with musculoskeletal pathology. Although highly operator dependent, it is often used as alternative to cross-sectional and plain film imaging, with the additional benefit of real time evaluation, lower cost and absence of contraindications [73-75]. Modern US equipment with high resolution transducers can provide dynamic visualization of muscles, tendons, ligaments, nerves and joints; findings can be instantly compared with the contralateral side [75]. Additional evaluation of tissue elastic properties is a new technique, that allows the detection and confirmation of pathologies such as neoplastic masses, and non-neoplastic changes such as tendinitis, myositis, fasciopathy, sprains and tears [75]. Special situations such as spastic cerebral palsy, neuro-

logical disorders, prediction of contractures and joint motion limitation in patients [76] and peripheral nerve assessment [77] can also be evaluated. The earlier diagnosis of degeneration and the ability to perform follow-up evaluations of healing and the effects of treatment are possible. SWE is considered the most suitable type of US elastography for the musculoskeletal system.

“Knobology”

Prerequisites

Due to the anisotropy effects of muscles and tendons, it is critical to align the probe perpendicularly or near to 90° to avoid false positive hypoechoic appearance that can mimic pathology and give inadequate images. If the probe is not located perpendicular to the target tissue, the refraction effect extinguishes the shear waves and stiffness value will not be accurate [78]. The SWS in tendons is very high (up to 15 cm/s) and if the US system cannot measure these high SWS inaccurate measurements may be obtained.

Transducer (frequency) selection

High frequency (12-18MHz) linear probes are recommended for MSK imaging and performing SWE. However, deeper located structures may require a lower frequency (3-12 MHz) linear transducer or a convex transducer (1-6 MHz).

Description of (other) parameters

In pSWE, a small ROI is placed on the area of interest and when activated the stiffness is obtained in the small ROI. With 2D-SWE, a large FOV is placed over the area of interest and when activated the SWSs for each pixel are calculated and displayed as a color-coded map. A small measurement box can then be placed to obtain the stiffness value of a certain location either as a single shot or in real-time. The transducer must remain stable in one location for several seconds to get an accurate measurement.

Region of interest (ROI) size, shape, others

Some claim that SWE shows more objective measurements compared to the SE, as it is less influenced by the operator, but some limitations as depth of ROI, size of the target and selected plane have to be considered [79]. Slight change in variability is related to depth of ROI, and quantitative values are unreliable beyond depth of 4 cm [80]. Shallow depths may be accommodated by applying a 5-mm layer of coupling US gel as stand-off.

Description of quality parameters

The high anisotropy of tendons requires perfectly parallel or perpendicular position of the US beam to the fibers, during the SWE examination. Shear waves travel faster along the fibers and slower between fibers. Motion of both the operator and the patient should be avoided.

Pre-compression

Precompression should be avoided in order not to increase the stiffness of the tissues. Consistent light pressure is advised [80].

Checking reproducibility

The joints and limb position as well as the patients' age should be taken into consideration during the SWE ultrasound examination [81]. The SWE examination of muscles and tendons should be performed with the lightest transducer pressure and a shorter acquisition time than for the strain assessment. The ROI size does not influence the mean elastic modulus [82].

How to use SWE

It is recommended to use mild pressure with the transducer during the SWE examination [79]. The transducer must be oriented longitudinally to the muscle fibers in order to achieve accurate and reliable SWE measurements. The shear waves propagate faster in the contracted tendons and muscles and along the long axis of tendons [83]. The ligaments should be examined in the same position as the corresponding joints [84].

Tips and tricks

With real-time 2D-SWE, stabilization of the image for few seconds before the measurement is taken is very important. As soft tissues give a wide range of stiffness, it is recommended to adjust the scale to maximum. SWE has a high specificity in the detection of tendinopathy and subclinical tendinopathy, showing the softening of the tissues. Inflamed plantar fascia, epicondylar and rotator cuff tendons with tendinopathy show soft areas [85]. Torn and sprained ligaments and tendons become softer, where the contracted muscle is stiff [78]. Posttraumatic changes as hematoma, loss of tendon tissue and effusion shows a significant decrease in stiffness [86], while post surgical tendons have an increased stiffness due to the healing process, where collagen Type III is predominant. It is important to remember that the contralateral tendon may show an increase of its stiffness also, due to overload [79]. Stretched tendons and the measurements taken parallel to the fibers show increased SWS [79]. 2D-SWE is widely used to evaluate the stiffness of the muscles and degrees of the contraction. For different groups of the muscles, the stiffness values range from 14.5 kPa at rest and up to 268.2 kPa during the contraction [87] (fig 7). Fascia may become stiff with age and even in the absence of pathology may appear as abnormality [88].

Normal reference values

According to the literature the normal speed in Achilles tendon is 74.4+/- 45.7 kPa in longitudinal measurement and 51.5+/- 25.1 kPa in transverse measurement [89]. In neutral position, measurement showed average 15.55 m/s in the longitudinal plane and 5.29 m/s in

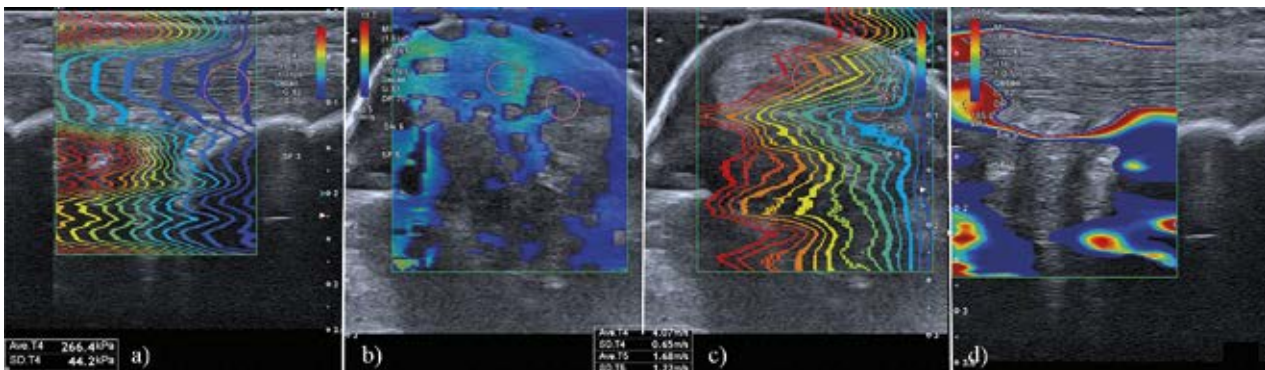


Fig 7. Normal 2D-SWE of contracted Achilles tendon: a) Longitudinal shear wave propagation map demonstrates marked distortion of waves at the tendon fibers; b) Transverse color-coded map; c) Transverse shear wave propagation map, distortion seen due to difference among tendon fibers; d) Filling defects due to very hard fibers.

transverse plane. In plantar flexion they were 4.76 m/s (transverse) and 7.03 m/s (longitudinal). Relaxed Achilles tendon SWS values were 8.26 m/s (longitudinal) and 4.10 m/sec (transverse). It is recommended to take the Achilles tendons 2D-SWE measurements 3-5cm from the insertion to calcaneus or at the myotendinous junction. For the gastrocnemius muscle stiffness values were 16.5 kPa (relaxation) and 225 kPa (contraction); for tibialis anterior muscle 40.6 kPa (relaxation) and 268 kPa (contraction); for soleus muscle 14.5 kPa (relaxation) and 55 kPa (contraction). In children with cerebral palsy gastrocnemius muscle values are 15-25 kPa. Supraspinatus muscle average velocity is 3.0 m/s.

What to avoid?

A minimum distance of 1-2 mm is recommended between the area of interest and the skin. When relaxed, even a normal tendon may demonstrate soft areas. Controlling the tendon tension is important for obtaining consistent results.

Specific artifacts

In case of precompression a reverberation can appear showing a high stiffness result. Similar reverberations effects, called “bang” artifact, can appear in the near field. The SWS is measured over only a few millimeters. When the ARFI pulses are spaced too far apart, the speed-reading can be inaccurate as the shear waves are attenuated between the ARFI pulses. Low stiffness values may appear at the interfaces between tissues due to tissue shifting, around calcifications, behind bone or at the superficial edge of a homogeneous lesion. Fluctuant changes at the borders of the tendon in axial elastogram can be seen due to varying contact with the skin [90].

Lymph nodes

Main objective, clinical value

Differentiating abnormal lymph nodes in benign conditions such as infection or inflammation from ma-

lignant conditions such as metastatic disease or primary malignances such as lymphoma is clinically important as prognostic factor. However, health professionals often encounter challenging overlapping imaging features on B-mode and color Doppler mode in differentiating benign process from malignant or an inflammatory disease [91-93] in various locations, mostly in the neck, but also axillary, groin and other abdominal locations with the same principles [94].

US elastography is a new imaging biomarker that may help in differentiating malignant LN (including both metastatic lymphadenopathy and lymphoma) from benign [95-99]. Several meta-analyses report malignant LN to be stiffer (higher elasticity and higher speed) than benign nodes and show that SWE for diagnosing malignant cervical LN has sensitivity of 81% and specificity of 85%, and the area under the curve is 0.88 [100,101]. A recent study showed that SWE evaluation of LN is helpful to provide additional information in case of thyroid carcinoma, but in the case of autoimmune disease (such as Hashimoto’s disease) there could be false negative results [94].

“Knobology”

Prerequisites

Knowledge of the normal lymph node appearance on B-mode US is mandatory (homogenous hypoechoic, ovoid shaped with a hyperechoic hilum, dominantly the hilar vascularization, long to short axis ratio <2). Main task is to clearly visualize and select the target lymph node, preferably in two perpendicular planes. Correct image is a color-coded display of relative shear wave velocities within the user-defined ROI superimposed onto a conventional B-mode US image.

Select an appropriate transducer

The linear probe with a wide range of frequency (3-18 MHz) can be used, selecting lower frequencies for

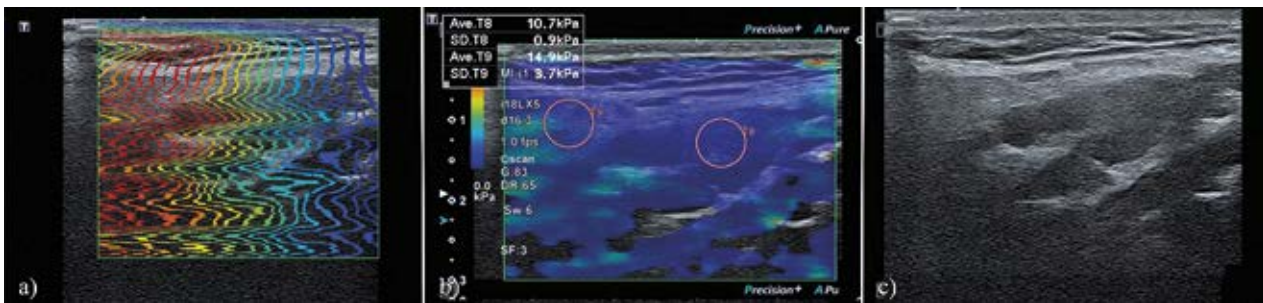


Fig 8. Normal 2D-SWE of a submandibular lymph node: (a) Longitudinal shear wave propagation map, wave propagation differences in subcutaneous tissues and lymph node central and peripheral part; (b) Color coded map and artifact of missing data in the deep layers; (c) B-mode submandibular benign non-specific lymph node.

deeper locations (3-12 MHz) and higher frequencies for superficial locations (5-18 MHz) [102].

Description of examination technique

The examination has to be started in a patient's supine position in cases of cervical lymphadenopathy, but may require comprehensive evaluation of various LN groups, including supraclavicular region with the extended neck over the pillow or in the sitting position. Initially, the standard B-mode evaluation of the lymph node includes size, shape, contours, vascularization, and presence of hilum. Endoscopy US LN elastography is performed as an additional element during examination.

Region of interest (ROI) size, shape, others

The stiffest area of the LN is measured with ROI on average of 1.5-2.0 mm in diameter [102] with a maximum size up to 5 mm in diameter in an artifact free area. With pSWE the ROI is fixed by the manufacturer. Using 2D-SWE, the ROI size can be changed and can be sufficiently large to contain target area and the surrounding tissue (subcutaneous fat or muscle) for comparison of relative stiffness. The selection of the field of view (box size, shape, distance from transducer), and the color scale of elastograms are not standardized.

Description of quality parameters

During the elastographic examination, the absence of a result indicates a poor quality of the study. More than one measurement must be performed to improve the quality of the study. Different tissue layers should be included within the colour-coded region.

Pre-compression

Pre-compression should be avoided in the superficial organ SWE examination, although minimal pressure can be used to reduce LN mobility in superficial locations.

How many measurements?

It is advised to perform at least 2 measurements of the target LN.

Checking Reproducibility

Substantial interobserver agreement has been observed for SWE homogeneity ($\kappa=0.66$) and for maximum

elasticity ($\kappa=0.80$) when performed by experienced specialist [103].

How to use SWE

The patient is asked to avoid swallowing and hold their breath to prevent movement of the lymph node in the neck. The stiffest region within the node is selected by visual inspection according to the color-coded elastogram and elasticity indices (EIs) and measured in Young's modulus unit (kPa). Minimal pressure during the evaluation and 5 mm x 5 mm ROI box is used [104]. For 2D-SWE, the transducer has to be held still over the lymph node for 2-3 seconds with a minimal pressure. Too strong pressure during the measurements can show high values and false positive result. The ROI box sizes can be changed, with a minimal size 2mm x 2mm and has to be placed over an artifact-free area [93, 105].

Tips and tricks

During the SWE imaging the patient can be asked to hold his breath to minimize motion-related artifacts. It is also suggested to avoid large vessel or other moving structures within the scanning window or measurement area.

Normal reference values

According to a study, the maximum Young's modulus value to distinguish between benign and malignant lymph node in the neck is a 19.44 kPa (sensitivity 91% and specificity 97%) [106]. A cut-off value of 2.93 m/s has been shown to predict malignant cervical LN [102]. There are no defined cut-off values for other LN locations.

What to avoid?

During the SWE examination the depth of the ROI has to be controlled and should not exceed 3cm from the skin, where the signal starts to attenuate (fig 8). Metastatic lymph nodes may present filling defect in color elastic maps and can be misdiagnosed as benign. In these cases, quantitative parameters should not be used to assess LN status [107].

Specific artifacts

Little areas of a pathologic process may complicate the SWE measurements and show a false-negative result, e.g. “black hole”, as filling defect on color maps or localized colored area at the margin. Therefore, the high SWE values have to correlate with the histology of the primary process. SWE artifacts in malignant LN may be related to the inability to produce, amplify, propagate or measure shear waves or in cases of stiff rim patterns caused by attenuation of the energy of the shear wave at the margin of LN [107]. False-negative results may also be obtained due to focal cortical metastatic foci too small to be detected by SWE. Lymphomatous LN may appear soft and hence to contribute to the false negative results.

Acknowledgement: The authors thank the Bad Mergentheimer Leberzentrum e.V. for support.

Conflict of interest: none.

References

- Bamber J, Cosgrove D, Dietrich CF, et al. EFSUMB guidelines and recommendations on the clinical use of ultrasound elastography. Part 1: Basic principles and technology. *Ultraschall Med* 2013;34:169-184.
- Cosgrove D, Piscaglia F, Bamber J, et al. EFSUMB guidelines and recommendations on the clinical use of ultrasound elastography. Part 2: Clinical applications. *Ultraschall Med* 2013;34:238-253.
- Dietrich CF, Bamber J, Berzigotti A, et al. EFSUMB Guidelines and Recommendations on the Clinical Use of Liver Ultrasound Elastography, Update 2017 (Long Version). *Ultraschall Med* 2017;38:e16-e47.
- Dietrich CF, Bamber J, Berzigotti A, et al. EFSUMB Guidelines and Recommendations on the Clinical Use of Liver Ultrasound Elastography, Update 2017 (Short Version). *Ultraschall Med* 2017;38:377-394.
- Săftoiu A, Gilja OH, Sidhu PS, et al. The EFSUMB Guidelines and Recommendations for the Clinical Practice of Elastography in Non-Hepatic Applications: Update 2018. *Ultraschall Med* 2019;40:425-453.
- Shiina T, Nightingale KR, Palmeri ML, et al. WFUMB guidelines and recommendations for clinical use of ultrasound elastography: Part 1: basic principles and terminology. *Ultrasound Med Biol* 2015;41:1126-1147.
- Barr RG, Nakashima K, Amy D, et al. WFUMB guidelines and recommendations for clinical use of ultrasound elastography: Part 2: breast. *Ultrasound Med Biol* 2015;41:1148-1160.
- Ferraioli G, Filice C, Castera L, et al. WFUMB guidelines and recommendations for clinical use of ultrasound elastography: Part 3: liver. *Ultrasound Med Biol* 2015;41:1161-1179.
- Ferraioli G, Wong VW, Castera L, et al. Liver Ultrasound Elastography: An Update to the World Federation for Ultrasound in Medicine and Biology Guidelines and Recommendations. *Ultrasound Med Biol* 2018;44:2419-2440.
- Dietrich CF, Barr RG, Farrokh A, et al. Strain Elastography - How To Do It? *Ultrasound Int Open* 2017;3:E137-E149.
- Dietrich CF, Bibby E, Jenssen C, Saftoiu A, Iglesias-Garcia J, Havre RF. EUS elastography: How to do it? *Endosc Ultrasound* 2018;7:20-28.
- Goertz RS, Schuderer J, Strobel D, Pfeifer L, Neurath MF, Wildner D. Acoustic radiation force impulse shear wave elastography (ARFI) of acute and chronic pancreatitis and pancreatic tumor. *Eur J Radiol* 2016;85:2211-2216.
- Onoyama T, Koda M, Fujise Y, et al. Utility of virtual touch quantification in the diagnosis of pancreatic ductal adenocarcinoma. *Clin Imaging* 2017;42:64-67.
- D’Onofrio M, De Robertis R, Crosara S, et al. Acoustic radiation force impulse with shear wave speed quantification of pancreatic masses: A prospective study. *Pancreatology* 2016;16:106-109.
- Park MK, Jo J, Kwon H, et al. Usefulness of acoustic radiation force impulse elastography in the differential diagnosis of benign and malignant solid pancreatic lesions. *Ultrasonography* 2014;33:26-33.
- Dietrich CF, Jenssen C. Modern ultrasound imaging of pancreatic tumors. *Ultrasonography* 2020;39:105-113.
- Dietrich CF, Burmeister S, Hollerbach S, et al. Do we need elastography for EUS? *Endosc Ultrasound* 2020;9:284-290.
- Dietrich CF, Hocke M. Elastography of the Pancreas, Current View. *Clin Endosc* 2019;52:533-540.
- Tana C, Schiavone C, Ticinesi A, et al. Ultrasound imaging of abdominal sarcoidosis: State of the art. *World J Clin Cases* 2019;7:809-818.
- Ohno E, Hirooka Y, Kawashima H, et al. Feasibility and usefulness of endoscopic ultrasonography-guided shear-wave measurement for assessment of autoimmune pancreatitis activity: a prospective exploratory study. *J Med Ultrason* (2001) 2019;46:425-433.
- Dietrich CF, Dong Y, Jenssen C, et al. Serous pancreatic neoplasia, data and review. *World J Gastroenterol* 2017;23:5567-5578.
- Dietrich CF, Shi L, Koch J, et al. Early detection of pancreatic tumors by advanced EUS imaging. *Minerva Gastroenterol Dietol* 2020.
- Dietrich CF, Shi L, Wei Q, et al. What does liver elastography measure? Technical aspects and methodology. *Minerva Gastroenterol Dietol* 2020.
- Dong Y, D’Onofrio M, Hocke M, et al. Autoimmune pancreatitis: Imaging features. *Endosc Ultrasound* 2018;7:196-203.
- Dietrich CF, Hirche TO, Ott M, Ignee A. Real-time tissue elastography in the diagnosis of autoimmune pancreatitis. *Endoscopy* 2009;41:718-720.
- Yamashita Y, Tanioka K, Kawaji Y, et al. Utility of Elastography with Endoscopic Ultrasonography Shear-Wave Measurement for Diagnosing Chronic Pancreatitis. *Gut Liver* 2019.
- Dietrich CF, Dong Y. Shear wave elastography with a new reliability indicator. *J Ultrason* 2016;16:281-287.

28. Yada N, Sakurai T, Minami T, et al. A Newly Developed Shear Wave Elastography Modality: With a Unique Reliability Index. *Oncology* 2015;89 Suppl 2:53-59.
29. Bronte V, Pittet MJ. The spleen in local and systemic regulation of immunity. *Immunity* 2013;39:806-818.
30. Mazur R, Celmer M, Silicki J, Holownia D, Pozowski P, Miedzybrodzki K. Clinical applications of spleen ultrasound elastography - a review. *J Ultrason* 2018;18:37-41.
31. Arena U, Lupsor Platon M, Stasi C, et al. Liver stiffness is influenced by a standardized meal in patients with chronic hepatitis C virus at different stages of fibrotic evolution. *Hepatology* 2013;58:65-72.
32. Berzigotti A, De Gottardi A, Vukotic R, et al. Effect of meal ingestion on liver stiffness in patients with cirrhosis and portal hypertension. *PLoS One* 2013;8:e58742.
33. Stefanescu H, Grigorescu M, Lupsor M, Procopet B, Maniu A, Badea R. Spleen stiffness measurement using Fibroscan for the noninvasive assessment of esophageal varices in liver cirrhosis patients. *J Gastroenterol Hepatol* 2011;26:164-170.
34. Colecchia A, Montrone L, Scaiola E, et al. Measurement of spleen stiffness to evaluate portal hypertension and the presence of esophageal varices in patients with HCV-related cirrhosis. *Gastroenterology* 2012;143:646-654.
35. Caliskan E, Atay G, Kara M, et al. Comparative evaluation of liver, spleen, and kidney stiffness in HIV-monoinfected pediatric patients via shear wave elastography. *Turk J Med Sci* 2019;49:899-906.
36. Hall TJ, Milkowski A, Garra B, et al. RSNA/QIBA: shear wave speed as a biomarker for liver fibrosis staging. In: *Ultrasonics Symposium (IUS), 2013 I.E. International*; 2013.397-400.
37. Procopet B, Berzigotti A, Abraldes JG, et al. Real-time shear-wave elastography: applicability, reliability and accuracy for clinically significant portal hypertension. *J Hepatol* 2015;62:1068-1075.
38. Karlas T, Lindner F, Troltzsch M, Keim V. Assessment of spleen stiffness using acoustic radiation force impulse imaging (ARFI): definition of examination standards and impact of breathing maneuvers. *Ultraschall Med* 2014;35:38-43.
39. Jansen C, Bogs C, Verlinden W, et al. Shear-wave elastography of the liver and spleen identifies clinically significant portal hypertension: A prospective multicentre study. *Liver Int* 2017;37:396-405.
40. Bota S, Sporea I, Sirlu R, Popescu A, Jurchis A. Factors which influence the accuracy of acoustic radiation force impulse (ARFI) elastography for the diagnosis of liver fibrosis in patients with chronic hepatitis C. *Ultrasound Med Biol* 2013;39:407-412.
41. Ferraioli G, De Silvestri A, Reiberger T, et al. Adherence to quality criteria improves concordance between transient elastography and ElastPQ for liver stiffness assessment-A multicenter retrospective study. *Dig Liver Dis* 2018;50:1056-1061.
42. Ferraioli G, Maiocchi L, Lissandrin R, Tinelli C, De Silvestri A, Filice C, Liver Fibrosis Study G. Accuracy of the ElastPQ Technique for the Assessment of Liver Fibrosis in Patients with Chronic Hepatitis C: a "Real Life" Single Center Study. *J Gastrointestin Liver Dis* 2016;25:331-335.
43. Roccarina D, Iogna Prat L, Buzzetti E, et al. Establishing Reliability Criteria for Liver ElastPQ Shear Wave Elastography (ElastPQ-SWE): Comparison Between 10, 5 and 3 Measurements. *Ultraschall Med* 2021;42:204-213.
44. Fang C, Jaffer OS, Yusuf GT, et al. Reducing the Number of Measurements in Liver Point Shear-Wave Elastography: Factors that Influence the Number and Reliability of Measurements in Assessment of Liver Fibrosis in Clinical Practice. *Radiology* 2018:172104.
45. Calvaruso V, Bronte F, Conte E, Simone F, Craxi A, Di Marco V. Modified spleen stiffness measurement by transient elastography is associated with presence of large oesophageal varices in patients with compensated hepatitis C virus cirrhosis. *J Viral Hepat* 2013;20:867-874.
46. Cassinotto C, Charrie A, Mouries A, et al. Liver and spleen elastography using supersonic shear imaging for the non-invasive diagnosis of cirrhosis severity and oesophageal varices. *Dig Liver Dis* 2015;47:695-701.
47. Giunta M, Conte D, Fraquelli M. Role of spleen elastography in patients with chronic liver diseases. *World J Gastroenterol* 2016;22:7857-7867.
48. Cho YS, Lim S, Kim Y, Sohn JH, Jeong JY. Spleen Stiffness Measurement Using 2-Dimensional Shear Wave Elastography: The Predictors of Measurability and the Normal Spleen Stiffness Value. *J Ultrasound Med* 2019;38:423-431.
49. Giuffrè M, Macor D, Masutti F, et al. Evaluation of spleen stiffness in healthy volunteers using point shear wave elastography. *Ann Hepatol* 2019;18:736-741.
50. Bob F, Bota S, Sporea I, Sirlu R, Petrica L, Schiller A. Kidney shear wave speed values in subjects with and without renal pathology and inter-operator reproducibility of acoustic radiation force impulse elastography (ARFI)--preliminary results. *PLoS One* 2014;9:e113761.
51. Bob F, Bota S, Sporea I, Sirlu R, Popescu A, Schiller A. Relationship between the estimated glomerular filtration rate and kidney shear wave speed values assessed by acoustic radiation force impulse elastography: a pilot study. *J Ultrasound Med* 2015;34:649-654.
52. Dillman JR, Smith EA, Davenport MS, et al. Can Shear-Wave Elastography be Used to Discriminate Obstructive Hydronephrosis from Nonobstructive Hydronephrosis in Children? *Radiology* 2015;277:259-267.
53. Gennisson JL, Grenier N, Combe C, Tanter M. Supersonic shear wave elastography of in vivo pig kidney: influence of blood pressure, urinary pressure and tissue anisotropy. *Ultrasound Med Biol* 2012;38:1559-1567.
54. Grenier N, Gennisson JL, Cornelis F, Le Bras Y, Couzi L. Renal ultrasound elastography. *Diagn Interv Imaging* 2013;94:545-550.
55. Hassan K, Loberant N, Abbas N, Fadi H, Shadia H, Khazim K. Shear wave elastography imaging for assessing the chronic pathologic changes in advanced diabetic kidney disease. *Ther Clin Risk Manag* 2016;12:1615-1622.

56. Hu Q, Wang XY, He HG, Wei HM, Kang LK, Qin GC. Acoustic radiation force impulse imaging for non-invasive assessment of renal histopathology in chronic kidney disease. *PLoS One* 2014;9:e115051.
57. Lee J, Oh YT, Joo DJ, Ma BG, et al. Acoustic Radiation Force Impulse Measurement in Renal Transplantation: A Prospective, Longitudinal Study With Protocol Biopsies. *Medicine (Baltimore)* 2015;94:e1590.
58. Samir AE, Allegritti AS, Zhu Q, et al. Shear wave elastography in chronic kidney disease: a pilot experience in native kidneys. *BMC Nephrol* 2015;16:119.
59. Sohn B, Kim MJ, Han SW, Im YJ, Lee MJ. Shear wave velocity measurements using acoustic radiation force impulse in young children with normal kidneys versus hydro-nephrotic kidneys. *Ultrasonography* 2014;33:116-121.
60. Barr RG, Ferraioli G, Palmeri ML, et al. Elastography Assessment of Liver Fibrosis: Society of Radiologists in Ultrasound Consensus Conference Statement. *Ultrasound Q* 2016;32:94-107.
61. Grenier N, Poulain S, Lepreux S, et al. Quantitative elastography of renal transplants using supersonic shear imaging: a pilot study. *Eur Radiol* 2012;22:2138-2146.
62. Ries M, Jones RA, Basseau F, Moonen CT, Grenier N. Diffusion tensor MRI of the human kidney. *J Magn Reson Imaging* 2001;14:42-49.
63. Gennisson JL, Deffieux T, Mace E, Montaldo G, Fink M, Tanter M. Viscoelastic and anisotropic mechanical properties of in vivo muscle tissue assessed by supersonic shear imaging. *Ultrasound Med Biol* 2010;36:789-801.
64. Madsen K NSTC: Anatomy of the kidney. In: B B, ed. *The Kidney*. Philadelphia: Sanders Elsevier 2008;25-90.
65. Barr RG. Can Accurate Shear Wave Velocities Be Obtained in Kidneys? *J Ultrasound Med* 2020;39:1097-1105.
66. Barr RG, Cosgrove D, Brock M, et al. WFUMB Guidelines and Recommendations on the Clinical Use of Ultrasound Elastography: Part 5. Prostate. *Ultrasound Med Biol* 2017;43:27-48.
67. Barr RG, Memo R, Schaub CR. Shear wave ultrasound elastography of the prostate: initial results. *Ultrasound Q* 2012;28:13-20.
68. Correas JM, Halpern EJ, Barr RG, et al. Advanced ultrasound in the diagnosis of prostate cancer. *World J Urol* 2021;39:661-676.
69. Correas JM, Tissier AM, Khairoune A, et al. Prostate cancer: diagnostic performance of real-time shear-wave elastography. *Radiology* 2015;275:280-289.
70. Rocher L, Criton A, Gennisson JL, et al. Testicular Shear Wave Elastography in Normal and Infertile Men: A Prospective Study on 601 Patients. *Ultrasound Med Biol* 2017;43:782-789.
71. Trottmann M, Marcon J, D'Anastasi M, et al. Shear-wave elastography of the testis in the healthy man - determination of standard values. *Clin Hemorheol Microcirc* 2016;62:273-281.
72. Shin HJ, Yoon H, Lee YS, et al. Normal Changes and Ranges of Pediatric Testicular Volume and Shear Wave Elasticity. *Ultrasound Med Biol* 2019;45:1638-1643.
73. Klauser AS, Tagliafico A, Allen GM, et al. Clinical indications for musculoskeletal ultrasound: a Delphi-based consensus paper of the European Society of Musculoskeletal Radiology. *Eur Radiol* 2012;22:1140-1148.
74. McNally EG. The development and clinical applications of musculoskeletal ultrasound. *Skeletal Radiol* 2011;40:1223-1231.
75. Rumack C, Levine D (eds). *Diagnostic Ultrasound*: Elsevier, 2017.
76. Ryu J, Jeong WK. Current status of musculoskeletal application of shear wave elastography. *Ultrasonography* 2017;36:185-197.
77. Kantarci F, Ustabasioglu FE, Delil S, et al. Median nerve stiffness measurement by shear wave elastography: a potential sonographic method in the diagnosis of carpal tunnel syndrome. *Eur Radiol* 2014;24:434-440.
78. Barr RG (ed). *Elastography: A Practical Approach*. New York: Thieme Publishers, 2017.
79. Prado-Costa R, Rebelo J, Monteiro-Barroso J, Preto AS. Ultrasound elastography: compression elastography and shear-wave elastography in the assessment of tendon injury. *Insights Imaging* 2018;9:791-814.
80. Davis LC, Baumer TG, Bey MJ, Holsbeeck MV. Clinical utilization of shear wave elastography in the musculoskeletal system. *Ultrasonography* 2019;38:2-12.
81. Greening J, Dille A. Posture-induced changes in peripheral nerve stiffness measured by ultrasound shear-wave elastography. *Muscle Nerve* 2017;55:213-222.
82. Kot BC, Zhang ZJ, Lee AW, Leung VY, Fu SN. Elastic modulus of muscle and tendon with shear wave ultrasound elastography: variations with different technical settings. *PLoS One* 2012;7:e44348.
83. Taljanovic MS, Gimber LH, Becker GW, et al. Shear-Wave Elastography: Basic Physics and Musculoskeletal Applications. *Radiographics* 2017;37:855-870.
84. Wu CH, Chang KV, Mio S, Chen WS, Wang TG. Sonoelastography of the plantar fascia. *Radiology* 2011;259:502-507.
85. Arda K, Ciledag N, Aktas E, Aribas BK, Kose K. Quantitative assessment of normal soft-tissue elasticity using shear-wave ultrasound elastography. *AJR Am J Roentgenol* 2011;197:532-536.
86. Aubry S, Nueffer JP, Tanter M, Becce F, Vidal C, Michel F. Viscoelasticity in Achilles tendonopathy: quantitative assessment by using real-time shear-wave elastography. *Radiology* 2015;274:821-829.
87. Shinohara M, Sabra K, Gennisson JL, Fink M, Tanter M. Real-time visualization of muscle stiffness distribution with ultrasound shear wave imaging during muscle contraction. *Muscle Nerve* 2010;42:438-441.
88. Miyamoto H, Siedentopf C, Kastlunger M, et al. Intracarpal tunnel contents: evaluation of the effects of corticosteroid injection with sonoelastography. *Radiology* 2014;270:809-815.
89. Chen XM, Cui LG, He P, Shen WW, Qian YJ, Wang JR. Shear wave elastographic characterization of normal and torn achilles tendons: a pilot study. *J Ultrasound Med* 2013;32:449-455.

90. Drakonaki EE, Allen GM, Wilson DJ. Ultrasound elastography for musculoskeletal applications. *Br J Radiol* 2012;85:1435-1445.
91. Lyshchik A, Higashi T, Asato R, et al. Cervical lymph node metastases: diagnosis at sonoelastography--initial experience. *Radiology* 2007;243:258-267.
92. Furukawa MK, Kubota A, Hanamura H, Fujita Y, Furukawa M. Diagnosis of cervical lymph node metastasis of head and neck squamous cell carcinoma. *MEDIX* 2017; Suppl:20-23.
93. Barr RG. Elastography. A practical approach. Thieme 2017; 8:100-114.
94. Tang GX, Xiao XY, Xu XL, et al. Diagnostic value of ultrasound elastography for differentiation of benign and malignant axillary lymph nodes: a meta-analysis. *Clin Radiol* 2020;75:481 e489-481 e416.
95. Chae SY, Jung HN, Ryoo I, Suh S. Differentiating cervical metastatic lymphadenopathy and lymphoma by shear wave elastography. *Sci Rep* 2019;9:12396.
96. Jiang M, Li C, Tang S, et al. Nomogram Based on Shear-Wave Elastography Radiomics Can Improve Preoperative Cervical Lymph Node Staging for Papillary Thyroid Carcinoma. *Thyroid* 2020;30:885-897.
97. Li J, Chen M, Cao CL, et al. Diagnostic Performance of Acoustic Radiation Force Impulse Elastography for the Differentiation of Benign and Malignant Superficial Lymph Nodes: A Meta-analysis. *J Ultrasound Med* 2020;39:213-222.
98. Dong Y, Jurgensen C, Puri R, et al. Ultrasound imaging features of isolated pancreatic tuberculosis. *Endosc Ultrasound* 2018;7:119-127.
99. Dietrich CF, Jenssen C, Herth FJ. Endobronchial ultrasound elastography. *Endosc Ultrasound* 2016;5:233-238.
100. Suh CH, Choi YJ, Baek JH, Lee JH. The diagnostic performance of shear wave elastography for malignant cervical lymph nodes: A systematic review and meta-analysis. *Eur Radiol* 2017;27:222-230.
101. Sigrist RMS, Liao J, Kaffas AE, Chammas MC, Willmann JK. Ultrasound Elastography: Review of Techniques and Clinical Applications. *Theranostics* 2017;7:1303-1329.
102. Azizi G, Keller JM, Mayo ML, et al. Shear Wave Elastography and Cervical Lymph Nodes: Predicting Malignancy. *Ultrasound Med Biol* 2016;42:1273-1281.
103. Bae SJ, Park JT, Park AY, et al. Ex Vivo Shear-Wave Elastography of Axillary Lymph Nodes to Predict Nodal Metastasis in Patients with Primary Breast Cancer. *J Breast Cancer* 2018;21:190-196.
104. Choi YJ, Lee JH, Baek JH. Ultrasound elastography for evaluation of cervical lymph nodes. *Ultrasonography* 2015;34:157-164.
105. Bhatia KS, Cho CC, Tong CS, Yuen EH, Ahuja AT. Shear wave elasticity imaging of cervical lymph nodes. *Ultrasound Med Biol* 2012;38:195-201.
106. Choi YJ, Lee JH, Lim HK, et al. Quantitative shear wave elastography in the evaluation of metastatic cervical lymph nodes. *Ultrasound Med Biol* 2013;39:935-940.
107. Luo S, Yao G, Hong Z, et al. Qualitative Classification of Shear Wave Elastography for Differential Diagnosis Between Benign and Metastatic Axillary Lymph Nodes in Breast Cancer. *Front Oncol* 2019;9:533.