



Detection of human neurotropic JCPyV DNA sequence in pediatric anaplastic xanthoastrocytoma

Sara Passerini¹ · Carla Prezioso² · Annalisa Prota¹ · Giulia Babini¹ · Lavinia Bargiacchi³ · Daniela Bartolini⁴ · Ugo Moens⁵ · Manila Antonelli³ · Valeria Pietropaolo¹

Received: 17 February 2023 / Revised: 10 March 2023 / Accepted: 28 March 2023
© The Author(s) 2023

Abstract

Due to its peculiar histopathological findings, pleomorphic xanthoastrocytoma (PXA), a rare cerebral tumor of young adults with a slow growth and a good prognosis, resembles to the lytic phase of progressive multifocal leukoencephalopathy, a fatal neurodegenerative disease caused by JC polyomavirus (JCPyV). Therefore, the presence of JCPyV DNA was examined in an 11-year-old child with xanthoastrocytoma, WHO grade 3, by quantitative PCR (qPCR) and nested PCR (nPCR) using primers amplifying sequences encoding the N- and C-terminal region of large T antigen (LTag), the non-coding control region (NCCR), and viral protein 1 (VP1) DNA. The expression of transcripts from *LTag* and *VP1* genes was also evaluated. In addition, viral microRNAs' (miRNAs) expression was investigated. Cellular p53 was also searched at both DNA and RNA level. qPCR revealed the presence of JCPyV DNA with a mean value of 6.0×10^4 gEq/mL. nPCR gave a positive result for the 5' region of the *LTag* gene and the NCCR, whereas 3' end *LTag* and *VP1* DNA sequences were not amplifiable. Only *LTag* transcripts of 5' end were found whereas *VP1* gene transcript was undetectable. Although in most cases, either Mad-1 or Mad-4 NCCRs have been identified in association with JCPyV-positive human brain neoplasms, the archetype NCCR structure was observed in the patient's sample. Neither viral miRNA miR-J1-5p nor p53 DNA and RNA were detected. Although the expression of *LTag* supports the possible role of JCPyV in PXA, further studies are warranted to better understand whether the genesis of xanthoastrocytoma could depend on the transformation capacity of *LTag* by Rb sequestration.

Keywords Xanthoastrocytoma · JCPyV · LTag · Transformation · Rb · NCCR

Abbreviations

PXA	Pleomorphic xanthoastrocytoma
PML	Progressive multifocal leukoencephalopathy
JCPyV	JC polyomavirus
qPCR	Quantitative polymerase chain reaction
nPCR	Nested polymerase chain reaction
LTag	Large T antigen
NCCR	Non-coding control region
VP1	Viral protein 1
miRNAs	MicroRNAs
Rb	Retinoblastoma
CNS	Central nervous system

Sara Passerini and Carla Prezioso contributed equally to this work.
Ugo Moens, Manila Antonelli, and Valeria Pietropaolo jointly share senior authorship.

✉ Valeria Pietropaolo
valeria.pietropaolo@uniroma1.it

- ¹ Department of Public Health and Infectious Diseases, "Sapienza" University of Rome, P.le Aldo Moro, 5, 00185 Rome, Italy
- ² Laboratory of Microbiology of Chronic-Neurodegenerative Diseases, IRCCS San Raffaele Roma, Rome, Italy
- ³ Department of Radiological, Oncological and Anatomic-Pathological Sciences, "Sapienza" University of Rome, Rome, Italy
- ⁴ Pathology Unit, Bufalini Hospital, Cesena, Italy
- ⁵ Department of Medical Biology, Faculty of Health Sciences, University of Tromsø, The Arctic University of Norway, Tromsø, Norway

Introduction

JC polyomavirus (JCPyV) is a ubiquitous human virus isolated in 1971 from the brain of a patient with Hodgkin disease (Padgett et al. 1971). It is the etiological agent of the progressive multifocal leukoencephalopathy (PML), a

demyelinating disease of the brain, caused by lytic infection of oligodendrocytes upon viral reactivation (Pietropaolo et al. 2018). The viral genome comprises the early and late gene region and the non-coding control region (NCCR). The early region encodes for nonstructural proteins, large T antigen (LTA_g), small t antigen (stAg), and T' 135, T' 136, and T' 165 proteins involved in the regulation of the virus cycle and in cell transformation (Frisque et al. 1984; Khalili 2001). The N-terminal region of LTA_g can interact with members of the retinoblastoma (Rb) protein family, whereas the C-terminal domain can bind p53 (Zheng et al. 2022). The interaction with these tumor suppressors induces progression of the cell cycle and is a major feature of the oncogenic properties (Del Valle et al. 2001). The late region encodes for the capsid proteins VP1, VP2, and VP3, for the agnoprotein (Frisque et al. 1984), and for two mature microRNAs (miRNAs), miR-J1-3p and miR-J1-5p, which can modulate viral replication by downregulating LTA_g expression (Giovannelli et al. 2015). The NCCR, encompassing the origin of replication and transcription control sequences, has a hypervariable structure that contributes to neurotropism and neurovirulent properties of JCPyV (Pietropaolo et al. 2018). The archetype NCCR structure has been isolated in the kidney and urine from healthy subjects (Yogo et al. 1990) whereas the rearranged or “prototype” strain is frequently disease-associated (Frisque et al. 1984). JCPyV-mediated oncogenesis has been described both in in vitro and in vivo studies (White and Khalili 2005). Inoculation of JCPyV into rodents, owl, or squirrel monkeys produces central nervous system (CNS) tumors including medulloblastoma, astrocytoma, glioblastoma, and neuroblastoma (Khalili 2001; Del Valle and Khalili 2021). JCPyV DNA was also detected in human brain tumors such as glioblastomas, astrocytomas, and medulloblastomas (Ahye et al. 2020).

In 1998, JCPyV DNA with a Mad-4 type NCCR was detected in the brain tissue of a 9-year-old child with pleomorphic xanthoastrocytoma (PXA) (Boldorini et al. 1998). So far, no additional cases of JCPyV-positive PXA have been reported.

Case presentation

An 11-year-old child (Table 1) was admitted to the hospital in January 2022 with a right temporo-parietal mass on magnetic resonance scan images. Pathology slides revealed an anaplastic PXA (WHO grade III). Increased cellularity, mitotic index (7 mitoses/10 hpf), and necrotic foci were evident. Anaplastic features, such as big nucleolus and an abundant eosinophilic cytoplasm absorbed by a fibrillary stroma, were displayed by the cells, and some of these showed big and pleomorphic nuclei, nuclear pseudo inclusions, and

Table 1 Summary of JCPyV viral load, DNA sequences, LTA_g/VP1 transcripts, and miRNA detected in tumor tissue

Tumor type	Age, gender	Viral load (gEq/mL)	LTA _g	NCCR	VP1	LTA _g transcripts	VP1 transcript	JC-miR-5p
Anaplastic xanthoastrocytoma (PXA) (gr. III WHO 2021)	11, M	6.0×10 ⁴	+	-	-	+	-	-

gEq/mL genome equivalents/milliliter

foamy cytoplasm. Pseudo-papillary and fascicular growth areas and eosinophilic granular bodies were also observed.

Immunohistochemical analysis showed diffuse positivity for glial fibrillary acid protein and patchy positivity for synaptophysin; however, positivity for mutated BRAFV600E protein has also been demonstrated (Fig. 1).

Total DNA was extracted from the paraffin-embedded tissue sections using Quick-DNA FFPE Miniprep (Zymo Research, Irvine, CA) and was evaluated for its PCR suitability by amplifying the β -globin gene sequences. To detect the presence of JCPyV DNA, a quantitative PCR (qPCR), targeting LTA_g DNA sequence, was performed. JCPyV DNA was further subjected to nested PCR (nPCR) using primers mapping sequences encoding the N- and C-terminal region of LTA_g, the NCCR, and the VP1 gene (Flaegstad et al. 1991; Krynska et al. 1999). Positive PCR products were purified using miPCR purification kit (Metabion, Planegg, Germany) and sequenced in a dedicated facility (Bio-Fab Research, Roma, Italy). In addition, the expression of transcripts from JCPyV LTA_g and VP1 genes was investigated. Total RNA was extracted using Quick-RNA Miniprep Plus Kit (Zymo Research, Irvine, CA), reverse transcribed by ZymoScript RT PreMix Kit (Zymo Research, Irvine, CA), and used for a PCR carried out with the same primers used on DNA. In order to investigate JCPyV miRNA expression, the reverse-transcribed RNA was used for PCR amplification of miR-J1-5p coding region (Giovannelli et al. 2015). DNA and cDNA were further analyzed for cellular p53 by PCR (Malekpour Afshar et al. 2016). JCPyV DNA was detected with a viral load value of 6.0×10^4 gEq/mL. nPCR for LTA_g region gave a positive result for the 5' end, whereas sequences encoding the C-terminal region and the VP1 gene were undetectable. Only LTA_g transcripts of 5' were identified. The NCCR had the archetype A-B-C-D-E-F box arrangement. miRNAs' investigation showed no

miR-J1-5p expression. Moreover, p53 analysis showed a negative result at both DNA and RNA level as well as by immunohistochemical analysis.

Discussion

Viral sequences have been detected in human brain tissue corroborating the hypothesis that JCPyV could be involved in the development of human brain tumors (Ahye et al. 2020). In our study, qPCR showed that PXA, a rare brain tumor with histopathological features resembling PML, harbored JCPyV DNA. To define JCPyV as infectious agent associated with brain cancer, JCPyV DNA positivity alone is not sufficiently specific to establish its etiological role. For this reason, in this study the expression of the LTA_g and VP1 at the DNA and RNA level was investigated.

In 1998, Boldorini et al. identified JCPyV LTA_g and VP1 DNA sequences, but not virus particles in the brain tissue of a 9-year-old boy with PXA (Boldorini et al. 1998). In our case, we detected DNA sequences and transcripts, corresponding to the 5' end but not the 3' end of the LTA_g gene and VP1 was undetectable both at DNA and RNA level.

During viral replication, JCPyV displays an orderly gene expression cascade in which LTA_g transcript is expressed first followed by the expression of the VP1 gene. Loss of the viral replication capacity is a common feature of virus-associated tumors. In this case, the hampered viral replication could explain the expression of LTA_g but not VP1 gene.

Since NCCR and miRNA could represent independent modalities of regulating JCPyV replication at the transcriptional and post-transcriptional levels, in this study, NCCR architecture and miRNA expression were investigated.

We detected a NCCR with archetype architecture and the absence of miR-J1-5p expression. Since JCPyV miRNA-5p

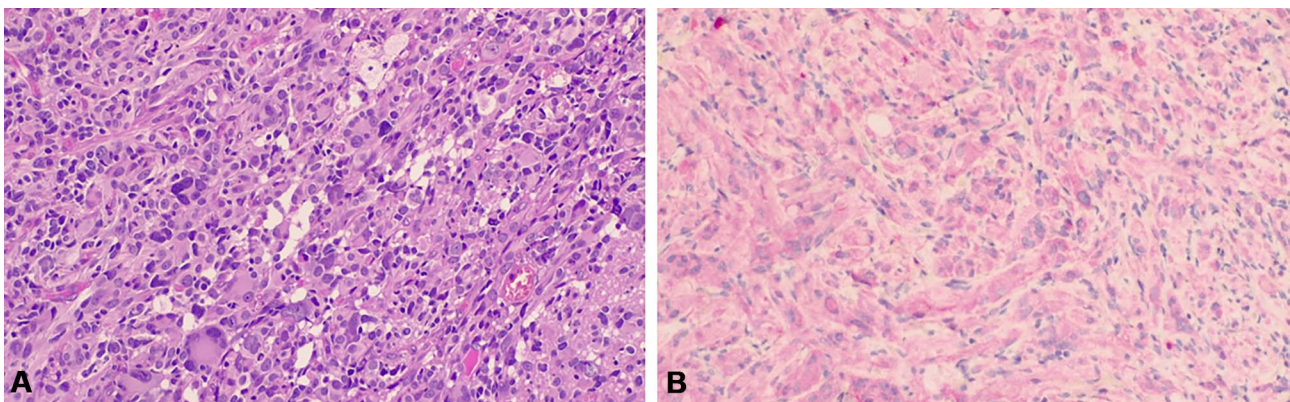


Fig. 1 Brain histopathology findings. **A** Pleomorphic tumor cells with occasional bizarre-looking nuclei and admixture of spindle neoplastic and neoplastic cells with bizarre nuclei or multi-nucleation. The neo-

plastic cells show multi-vacuolated cytoplasm. Granular cell bodies are also evident. **B** BRAFV600E immunohistochemical stain highlights pleomorphic tumor cells

has been proposed to act as an important safeguard, reducing LTag expression during viral persistence, in our study we could speculate that the absence of JCPyV-miRNA expression and the detection of LTag contribute to a persistence state rather than a viral reactivation.

We failed to detect p53 at the DNA, RNA, and protein level in our tumor specimen. As previously described, the C-terminal region of LTag can interact with p53 (Zheng et al. 2022) although inactivation of p53 is not absolutely required for polyomaviruses to induce cancer as shown for MCPyV and MCC. In fact, the LTag expressed in MCPyV-positive MCC lacks the p53 binding domain but retains the Rb domain (DeCaprio 2021), as observed in our case. Therefore, further studies are required to establish whether the genesis of PXA could depend on the transformation capacity of LTag by Rb sequestration, as demonstrated in the MCC. Additional studies are required (i) to establish whether full-length or C-terminal truncated LTag is expressed; (ii) to establish whether the truncation is the result of a deletion in the LTag gene rather than nonsense mutation (as is the case in the LTAG gene of MCPyV-positive MCCs); and (iii) to explain the lack of p53 DNA detection in the tumor.

Conclusion

JCPyV detection in brain tumor tissue reinforces the idea that this virus could be involved in tumor development. However, further studies are warranted to define its role in oncogenesis of brain tumors.

Funding Open access funding provided by Università degli Studi di Roma La Sapienza within the CRUI-CARE Agreement. Valeria Pietropaolo funding acquisition (MIUR Research Grant: RP12218149017F23). Carla Prezioso was supported by Italian Ministry of Health-Ricerca corrente.

Data availability No datasets were generated during the study.

Declarations

Institutional review board statement The study was performed according to local Ethical and Institutional Review Board approval (Protocol Number: 1337/20) and informed consent was obtained in accordance with the Declaration of Helsinki.

Ethical publication statement We confirm that we have read the journal's position on issues involved in ethical publication and affirm that this report is consistent with those guidelines.

Conflict of interest The authors declare no competing interests.

Open Access This article is licensed under a Creative Commons Attribution 4.0 International License, which permits use, sharing, adaptation, distribution and reproduction in any medium or format, as long as you give appropriate credit to the original author(s) and the source, provide a link to the Creative Commons licence, and indicate if changes were made. The images or other third party material in this article are

included in the article's Creative Commons licence, unless indicated otherwise in a credit line to the material. If material is not included in the article's Creative Commons licence and your intended use is not permitted by statutory regulation or exceeds the permitted use, you will need to obtain permission directly from the copyright holder. To view a copy of this licence, visit <http://creativecommons.org/licenses/by/4.0/>.

References

- Ahye N, Bellizzi A, May D, Wollebo HS (2020) The role of the JC virus in central nervous system tumorigenesis. *Int J Mol Sci* 21(17):6236. <https://doi.org/10.3390/ijms21176236>
- Boldorini R, Caldarelli-Stefano R, Monga G, Zocchi M, Mediati M, Tosoni A, Ferrante P (1998) PCR detection of JC virus DNA in the brain tissue of a 9-year-old child with pleomorphic xanthoastrocytoma. *J Neurovirol* 4(2):242–245. <https://doi.org/10.3109/13550289809114524>
- DeCaprio JA (2021) Molecular pathogenesis of Merkel cell carcinoma. *Annu Rev Pathol* 16:69–91. <https://doi.org/10.1146/annurev-pathmechdis-012419-032817>
- Del Valle L, Baehring J, Lorenzana C, Giordano A, Khalili K, Croul S (2001) Expression of a human polyomavirus oncoprotein and tumour suppressor proteins in medulloblastomas. *Mol Pathol* 54(5):331–337. <https://doi.org/10.1136/mp.54.5.331>
- Del Valle L, Khalili K (2021) Induction of brain tumors by the archetype strain of human neurotropic JCPyV in a transgenic mouse model. *Viruses* 13(2):162. <https://doi.org/10.3390/v13020162>
- Flaegstad T, Sundsfjord A, Arthur RR, Pedersen M, Traavik T, Subramani S (1991) Amplification and sequencing of the control regions of BK and JC virus from human urine by polymerase chain reaction. *Virology* 180(2):553–560. [https://doi.org/10.1016/0042-6822\(91\)90069-N](https://doi.org/10.1016/0042-6822(91)90069-N)
- Frisque RJ, Bream GL, Cannella MT (1984) Human polyomavirus JC virus genome. *J Virol* 51(2):458–469. <https://doi.org/10.1128/jvi.51.2.458-469.1984>
- Giovannelli I, Martelli F, Repice A, Massacesi L, Azzi A, Giannecchini S (2015) Detection of JCPyV microRNA in blood and urine samples of multiple sclerosis patients under natalizumab therapy. *J Neurovirol* 21(6):666–670. <https://doi.org/10.1007/s13365-015-0325-3>
- Khalili K (2001) Human neurotropic JC virus and its association with brain tumors. *Dis Markers* 17(3):143–147. <https://doi.org/10.1155/2001/423875>
- Krynska B, Del Valle L, Croul S, Gordon J, Katsetos CD, Carbone M, Giordano A, Khalili K (1999) Detection of human neurotropic JC virus DNA sequence and expression of the viral oncogenic protein in pediatric medulloblastomas. *Proc Natl Acad Sci U S A* 96(20):11519–11524. <https://doi.org/10.1073/pnas.96.20.11519>
- Malekpour Afshar R, Mollaei HR, Zandi B, Iranpour M (2016) Evaluation of JC and cytomegaloviruses in glioblastoma tissue. *Asian Pac J Cancer Prev* 17(11):4907–4911. <https://doi.org/10.22034/APJCP.2016.17.11.4907>
- Padgett BL, Walker DL, ZuRhein GM, Echroade RJ, Dessel BH (1971) Cultivation of papova-like virus from human brain with progressive multifocal leukoencephalopathy. *Lancet* 1(7712):1257–1260. [https://doi.org/10.1016/S0140-6736\(71\)91777-6](https://doi.org/10.1016/S0140-6736(71)91777-6)
- Pietropaolo V, Prezioso C, Bagnato F, Antonelli G (2018) John Cunningham virus: an overview on biology and disease of the etiological agent of the progressive multifocal leukoencephalopathy. *New Microbiol* 41(3):179–186
- White MK, Khalili K (2005) Expression of JC virus regulatory proteins in human cancer: potential mechanisms for tumorigenesis. *Eur J Cancer* 41(16):2537–2548. <https://doi.org/10.1016/j.ejca.2005.08.019>

WHO Classification of Tumours Editorial Board (2021) World Health Organization Classification of Tumours of the Central Nervous System, 5th ed. Lyon: International Agency for Research on Cancer

Yogo Y, Kitamura T, Sugimoto C, Ueki T, Aso Y, Hara K, Taguchi F (1990) Isolation of a possible archetypal JC virus DNA sequence from nonimmunocompromised individuals. *J Virol* 64(6):3139–3143. <https://doi.org/10.1128/jvi.64.6.3139-3143.1990>

Zheng HC, Xue H, Zhang CY (2022) The oncogenic roles of JC polyomavirus in cancer. *Front Oncol* 12:976577. <https://doi.org/10.3389/fonc.2022.976577>

Publisher's Note Springer Nature remains neutral with regard to jurisdictional claims in published maps and institutional affiliations.