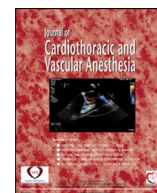


Contents lists available at [ScienceDirect](https://www.sciencedirect.com)

Journal of Cardiothoracic and Vascular Anesthesia

journal homepage: [www.jcvaonline.com](http://www.jcvaonline.com)

Original Article

## Bilateral Ultrasound-Guided Erector Spinae Plane Block for Pectus Excavatum Surgery: A Retrospective Propensity-Score Study

Silvia Fiorelli, MD<sup>\*,1</sup>, Cecilia Menna, MD<sup>†</sup>,  
 Claudio Andreotti, MD<sup>†</sup>, Valentina Peritore, MD<sup>†</sup>,  
 Monica Rocco, MD<sup>\*</sup>, Roberto Alberto De Blasi, MD<sup>\*</sup>,  
 Erino Angelo Rendina, MD<sup>†</sup>, Domenico Massullo, MD<sup>\*</sup>,  
 Mohsen Ibrahim, MD<sup>†</sup>

<sup>\*</sup>Anesthesia and Intensive Care Medicine, Department of Clinical and Surgical Translational Medicine, Sant'Andrea Hospital, Sapienza University of Rome, Rome, Italy

<sup>†</sup>Thoracic Surgery, Department of Clinical and Surgical Translational Medicine, Sant'Andrea Hospital, Sapienza University of Rome, Rome, Italy



**Objective:** Pectus excavatum (PE) repair is burdened by severe postoperative pain. This retrospective study aimed to determine whether the analgesic effect of ultrasound-guided erector spinae plane block (ESPB) plus standard intravenous analgesia (SIVA) might be superior to SIVA alone in pain control after PE surgical repair via Ravitch or Nuss technique.

**Design:** A retrospective cohort study.

**Setting:** At a university hospital.

**Participants:** All participants were scheduled for surgical repair of PE.

**Interventions:** From January 2017 to December 2019, all patients who received ESPB plus SIVA or SIVA alone were investigated retrospectively. A 2:1 propensity-score matching analysis considering preoperative variables was used to compare analgesia efficacy in 2 groups. All patients received a 24-hour continuous infusion of tramadol, 0.1 mg/kg/h, and ketorolac, 0.05 mg/kg/h, via elastomeric pump, and morphine, 2 mg, intravenously as a rescue drug. The ESPB group received preoperative bilateral ESPB block. Postoperative pain, reported using a numerical rating scale at 1, 12, 24, and 48 hours after surgery; the number of required rescue doses; total postoperative morphine milligram equivalents consumption; and the incidence of postoperative nausea and vomit were analyzed.

**Measurement and Main Results:** A total of 105 patients were identified for analysis. Propensity-score matching resulted in 38 patients in the SIVA group and 19 patients in the ESPB group. Postoperative pain, the number of rescue doses, and postoperative nausea and vomit incidences were lower in the ESPB group ( $p < 0.005$ ).

**Conclusions:** Erector spinae plane block may be an effective option for pain management after surgical repair of PE as part of a multimodal approach. This study showed good perioperative analgesia, opioid sparing, and reduced opioid-related adverse effects.

© 2022 Elsevier Inc. All rights reserved.

**Key Words:** erector spinae plane block; regional anesthesia; thoracic anesthesia; pectus excavatum surgery; Ravitch procedure; Nuss procedure

Domenico Massullo and Mohsen Ibrahim are co-senior authors who equally contributed to the paper.

<sup>1</sup>Address correspondence to: Silvia Fiorelli, MD, Anesthesia and Intensive Care Medicine, Department of Clinical and Surgical Translational Medicine, Sapienza University of Rome, Sant'Andrea Hospital, Via di Grottarossa 1035, 00189 Rome, Italy

E-mail address: [silvia.fiorelli@uniroma1.it](mailto:silvia.fiorelli@uniroma1.it) (S. Fiorelli).

PECTUS EXCAVATUM (PE) is the most common chest wall congenital abnormality, affecting approximately 1 in 400 children. Pectus excavatum is more common among men, in a ratio of 5:1. Pectus excavatum is characterized by a depression of the anterior chest wall as a result of dorsal deviation of the

<https://doi.org/10.1053/j.jcva.2022.08.018>

1053-0770/© 2022 Elsevier Inc. All rights reserved.

sternum and of the third-to-seventh ribs or costal cartilage.<sup>1</sup> The 2 surgical techniques mainly used for PE correction are the modified Ravitch procedure and the Nuss procedure (Fig 1).<sup>2</sup> The Ravitch procedure is an open technique performed through a single 4-cm skin incision on the midline of the chest at the deepest point of depression of the chondrosternal deformity, and placement of a metal bar stabilizer. Postoperative pain is considerable due to the dissection of the pectoralis major and rectus abdominis muscles, resection of deformed cartilages, and a transverse wedge sternal osteotomy. The Nuss procedure does not require cartilage resection or osteotomy, and consists of placement of  $\geq 1$  bars behind the sternum through smaller lateral incisions using a video-assisted thoracoscopic technique. Nevertheless, the dislocation of costovertebral joints after the forceful repositioning of the sternum through bar placement also can lead to intense postoperative pain.<sup>3</sup> Even though the Nuss procedure is a minimally invasive thoracoscopic technique, several studies have shown that the perioperative pain was comparable to, or even worse than,

open repair procedures.<sup>4,5</sup> This is likely due to stress on the ribs and sternum, as well as strain on the costal cartilage caused by forcing the sternum into normal alignment.<sup>6</sup>

Although adequate pain management is paramount to encourage early mobilization and facilitate deep breathing,<sup>7</sup> controversy exists on the best technique for postoperative pain management.<sup>3,8</sup> Thoracic epidural analgesia (TEA) has been considered the gold standard for years, and has been widely applied to provide analgesia for patients undergoing a PE repair surgery procedure because of the potential for severe postoperative pain.<sup>9,10</sup> Although TEA provides good postoperative pain relief, there are risks being considered, such as hypotension, infection, and epidural hematoma. There are recent reports of less-invasive truncal blocks, such as paravertebral block (PVB) and erector spinae plane block (ESPB), being used successfully for pain relief for this surgery.<sup>11-16</sup>

The ultrasound-guided ESPB, an interfascial block first described in 2016 for thoracic neuropathic pain treatment,<sup>17</sup> has been successfully employed in previous case reports for

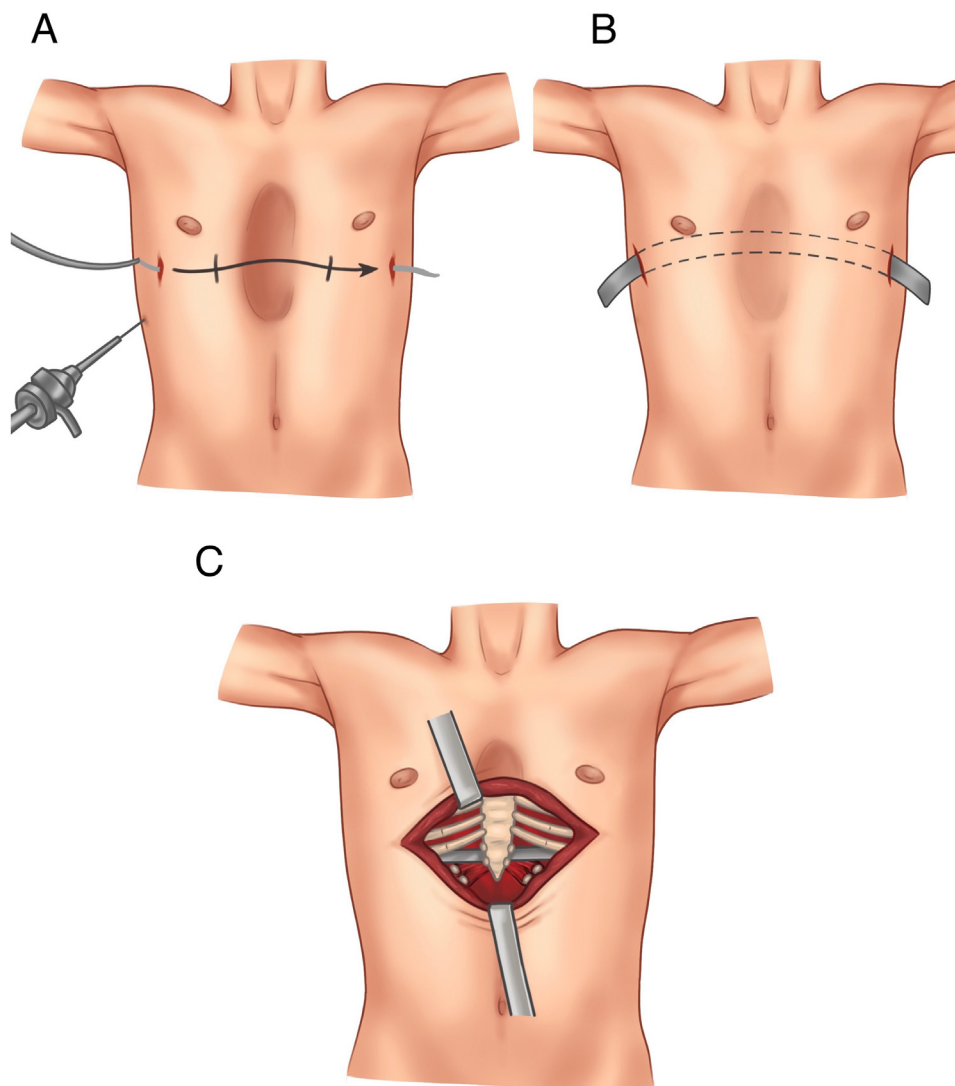


Fig. 1. (A) The Nuss procedure involving bar placement behind the sternum under thoracoscopic vision. (B) The bar is turned over to elevate the sternal depression and laterally stabilized to the ribcage. (C) The Ravitch procedure involving anterior excision of costal cartilage attachments along the sternum.

postoperative pain management in patients undergoing surgical repair of PE via Ravitch and Nuss procedures.<sup>18–22</sup> Currently, no studies have compared ESPB to the standard intravenous analgesia in postoperative pain management after PE surgery.

This retrospective study aimed to determine whether the analgesic effect of preoperative single-shot ESPB plus standard intravenous analgesia (SIVA) might be superior to standard intravenous analgesia alone in pain control after PE surgical repair via Ravitch or Nuss technique.

## Methods

The study was approved by the Bioethics Committee (No. 5641\_2019). From January 1, 2017, to December 31, 2019, patients who underwent surgical repair of PE via Ravitch or Nuss technique were investigated retrospectively. Patients who received standard analgesia were matched to those who received ESP block at a 2:1 ratio using propensity-score matching analysis. This matching was used to obtain groups of patients corresponding to the 2 analgesic modalities that were balanced according to potential confounding baseline variables, including age, sex, body mass index, Haller Index (derived from dividing the transverse diameter of the chest by the anterior-posterior diameter on a simple computed tomography scan),<sup>23</sup> surgical procedure type, and operative time.

Patients in the ESPB group received bilateral, ultrasound-guided ESPB performed by the anesthesiologist 20 minutes before the induction of general anesthesia.<sup>17</sup> This procedure was performed with the patient in a sitting position using a high-frequency (11–13 MHz) linear transducer (MyLab 30 Gold; Esaote, Genoa, Italy). The tip of the T5 transverse process and the erector spinae muscle were identified in longitudinal parasagittal orientation 3 cm lateral to the midline. Using the aseptic technique, a 10-cm 21-gauge block needle (Arrow UltraQuik Echogenic PNB Needle; Teleflex Medical, Markham, Ontario, Canada) was inserted in-plane to the ultrasound beam in a cranial-to-caudal direction to contact the tip of the T5 transverse process (Fig 2). After hydrodissection with 2 mL of the saline solution, 20 mL of 0.5% ropivacaine were injected. The procedure was performed bilaterally, with a total amount of 40 mL of 0.5% ropivacaine injected.

Anesthesia was induced intravenously using propofol (2 mg/kg), fentanyl (2 µg/kg), ketamine (0.3 mg/kg), and rocuronium bromide (0.6 mg/kg); the maintenance of general anesthesia was achieved with desflurane (minimum alveolar concentration–1) and the continuous infusion of remifentanyl using a target-controlled infusion system in effect-site target mode with an Alaris PK Syringe Pump (Minto pharmacokinetic set; Becton, Dickinson and Co, Franklin Lakes, NJ). The target concentration of remifentanyl was titrated according to each patient's hemodynamic changes and surgical conditions (target remifentanyl concentrations range from 1–4 ng/mL). Paracetamol (1,000 mg) and morphine (0.07 mg/kg) were administered 30 minutes before the end of surgery.

At the end of surgery, all patients received, as standard postoperative analgesia, a 24-hour continuous infusion of tramadol (0.1 mg/kg/h) and ketorolac (0.05 mg/kg/h) by elastomeric

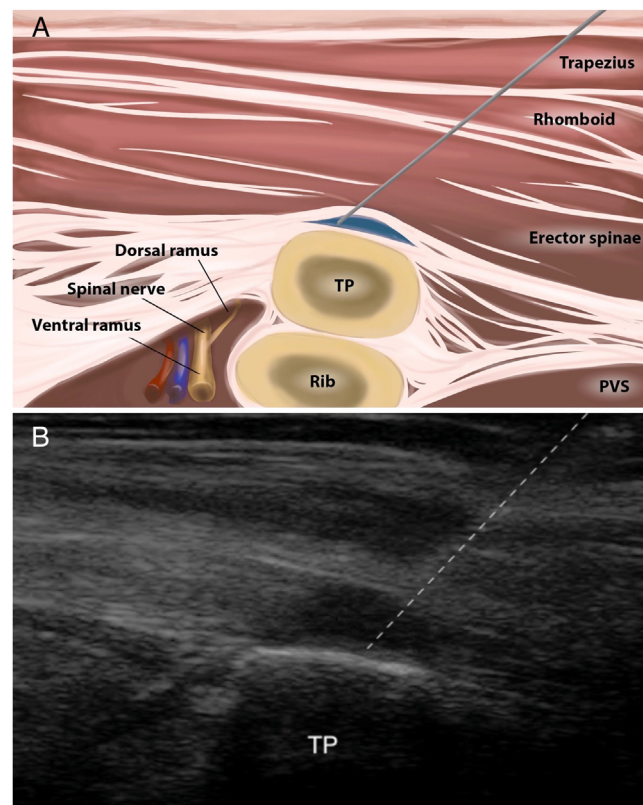


Fig. 2. (A) Illustration of erector spinae plane block performed with needle insertion in-plane. (B) Ultrasound image of erector spinae plane block performance with needle insertion in-plane. ESPB, erector spinae plane block; PVS, paravertebral space; TP, transverse process.

pump (2 mL/h), and the administration of paracetamol (1,000 mg) intravenously every 6 hours (kg/h). A rescue drug (intravenous morphine, 2 mg) at a dosing interval of 60 minutes was administered if the numerical rating scale (NRS) score at rest was >3 and the patient demanded additional analgesia.

Data collected from the electronic medical records system included the following: demographic data, surgical procedure, operative time, surgical approach, perioperative pain management, postoperative levels of pain reported using an NRS at 1, 12, 24, and 48 hours after surgery, the number of required rescue doses, total postoperative opioids consumption converted to morphine milligram equivalents, the incidences of postoperative nausea and vomit episodes, and the length of stay. Major cardiac or hemodynamic events (eg, cardiac or vascular injuries and intraoperative arrhythmias) also were recorded.

The Shapiro-Wilk test was used to assess the normality of distributions. The mean values and SD were determined by Student *t*-test for each quantitative variable. Fisher exact test was applied for qualitative variables. The Mann-Whitney *U*-test was used when the distribution was nonnormal. The data were analyzed using the SPSS v.26.0 software (IBM Corp, Armonk, NY).

## Results

The retrospective review identified 105 relevant records of patients who underwent surgical repair of PE from January

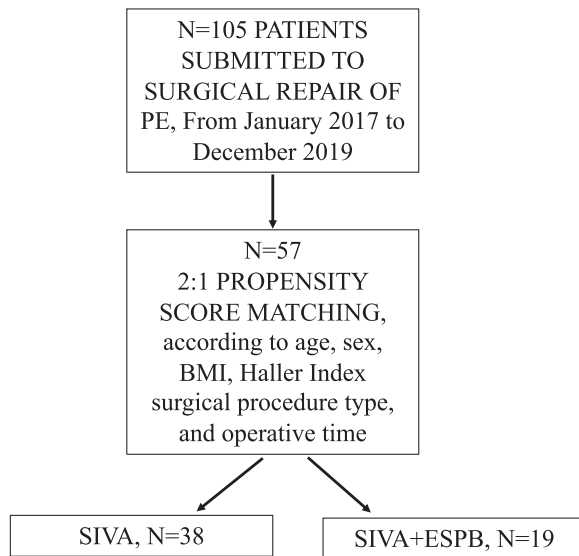


Fig. 3. Flow diagram of the study. BMI, body mass index; ESPB, erector spinae plane block; PE, pectus excavatum; SIVA, standard intravenous analgesia.

2017 to December 2019. Seventy-seven patients received SIVA, and 28 patients received SIVA plus ESPB. These patients were matched successfully on a 2:1 basis based on predetermined confounders and baseline characteristics, including 38 patients in the SIVA group and 19 patients in the ESPB group (Fig 3). Matched patients from both groups showed similar baseline characteristics (Table 1).

Levels of pain at 1, 12, and 24 hours after surgery; the number of rescue doses; total postoperative opioid consumption (the sum of infusion and administered rescue analgesic dose) converted to morphine milligram equivalents consumption; and the incidences of postoperative nausea and vomit were lower in the ESPB group (respectively  $p < 0.001$ ,  $p < 0.001$ ,  $p < 0.001$ ,  $p = 0.037$ , and  $p = 0.003$ ), as shown in Table 2 and Figure 4. No adverse block-related events were reported in the ESPB group.

Table 1  
Patient Characteristics After Propensity-Score Matching; The Data are Expressed as Mean  $\pm$  SD or Number of Patients

Parameter	ESPB (n = 19)	SIVA (n = 38)	p Value
Sex, M/F	17/2	34/4	0.604
Age, y	22.89 $\pm$ 3.26	25.87 $\pm$ 7.13	0.524
BMI, kg/m <sup>2</sup>	20.47 $\pm$ 4.24	21.24 $\pm$ 2.44	0.449
ASA			0.575
I	10	20	
II	9	18	
Haller Index	3.30 $\pm$ 3.05	3.40 $\pm$ 1.45	0.639
Scheduled surgery			
Nuss procedure	12	28	0.243
Ravitch procedure	7	10	
Anesthesia duration, min	126.75 $\pm$ 17.89	126.84 $\pm$ 17.89	0.652
Surgery duration, min	95.53 $\pm$ 23.20	98.16 $\pm$ 32.88	0.959
Length of stay, d	5.59 $\pm$ 1.58	5.63 $\pm$ 1.10	0.501

Abbreviations: ASA, American Society of Anesthesiologists; BMI, body mass index; ESPB, erector spinae plane block; SIVA, standard intravenous analgesia.

\*p value by Student *t*-test or Fisher exact test, as appropriate.

Table 2

Number of Required Rescue Drug, Total Postoperative MME Consumption, and PONV Episodes for the ESPB Group and the SIVA Group

Parameter	ESPB group (n = 19)	SIVA group (n = 38)	p Value
Rescue drug, n <sup>o</sup>	1 $\pm$ 0.81	1.60 $\pm$ 1.20	0.037
MME, mg	17.67 $\pm$ 2.56	20.44 $\pm$ 3.49	0.003
PONV, n <sup>o</sup>	0.26 $\pm$ 0.45	0.76 $\pm$ 0.88	0.007

\*p value by Student *t*-test or Fisher exact test, as appropriate. The data are expressed as mean  $\pm$  SD (95% CI).

Abbreviations: ESPB, erector spinae plane block; MME, morphine milligram equivalents; NRS, numerical rating scale; PONV, postoperative nausea and vomiting; SIVA, standard intravenous analgesia.

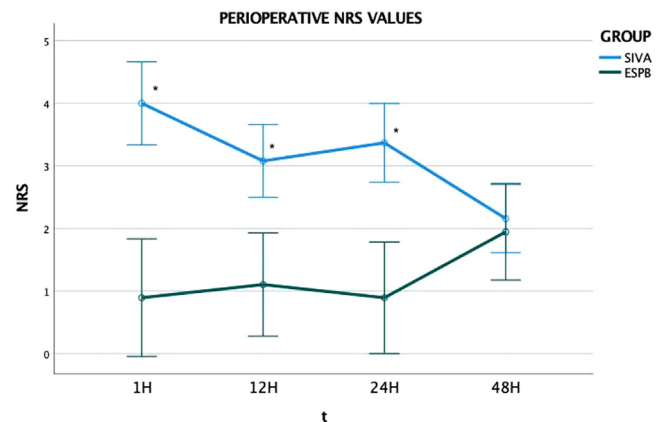


Fig. 4. Perioperative pain scores. \* $<0.001$ , 95% CI error bars. ESPB, erector spinae plane block; NRS, numerical rating scale; SIVA, standard intravenous analgesia; t, time.

The degree of acute postoperative pain was classified as mild-moderate pain (NRS score 1-6) and severe pain (NRS Score 7-10) (Table 3). No patients in the ESPB group experienced severe postoperative pain (NRS score  $>7$ ), versus 13 (34%) patients in the SIVA group ( $p = 0.004$ ).

Considering all patients of both groups, no differences were found in summary postoperative NRS and number of required rescue doses in patients submitted to the Ravitch or Nuss procedure ( $2.53 \pm 1.55$  v  $2.52 \pm 1.58$ ,  $p = 0.96$ ;  $1.35 \pm 1.09$  v  $1.47 \pm 1.17$ ,  $p = 0.72$ ). No major cardiac or hemodynamic events were reported.

## Discussion

Several anesthetic techniques and postoperative pain management strategies have been used over the years for patients

Table 3

Acute Postoperative Pain Classified According to Severity in the ESPB and SIVA Groups

Pain, n (%)	ESPB group (n = 19)	SIVA group (n = 38)	p Value
Mild-moderate	19 (100)	25 (66)	0.004
Severe	0 (0)	13 (34)	0.004

Results are expressed as number of patients and percentage. Mild-moderate pain is considered having an NRS score 1-to-6, and severe pain is considered having an NRS score 7-to-10.

Abbreviations: ESPB, erector spinae plane block; NRS, numerical rating scale; SIVA, standard intravenous analgesia.



undergoing PE surgery. Erector spinae plane block has been demonstrated to be more effective than SIVA alone for pain management after PE surgery, and also can contribute to reducing postoperative opioid requirements and opioid-related adverse effects. Although ESPB has been employed successfully in case reports for postoperative pain management in patients submitted to surgical repair of PE via the Ravitch and Nuss procedures,<sup>18-21</sup> to the authors' knowledge, this was the first study comparing postoperative analgesia between ESPB and SIVA after PE surgery.

Nardiello et al. first reported in 2018 2 cases of adolescents, one diagnosed with PE and the other one with pectus carinatum, undergoing reconstructive surgery in which a bilateral single-shot ESPB was performed successfully as an analgesic technique without long-term opioid use.<sup>19</sup> Three cases of adult patients who underwent PE surgical repair via the Ravitch technique, managed with bilateral ESPB with adequate pain control and very low opioid requirement during the postoperative period, were reported recently by the authors' group.<sup>18</sup> Yoshizaki et al. described effective bilateral ESPB employment in a pediatric patient submitted to surgical repair of PE via the Nuss procedure, placing catheters and using a programmed intermittent bolus technique for perioperative analgesia.<sup>20</sup> The successful use of continuous ESPB for PE repair via the Ravitch procedure also was reported in 2 adult patients with complex medical histories in whom TEA placement was either contraindicated or unsuccessful.<sup>21</sup> A recent study showed that ESPB is a safe and effective alternative to TEA in postoperative pain management after the Nuss procedure, resulting in decreased length of hospital stay.<sup>24</sup>

Erector spinae plane block can be feasible also in patients with altered back anatomy, prior spine procedures, or deformity that represent common conditions in patients with PE and in whom TEA placement cannot be done safely.<sup>22,25</sup> Continuous bilateral ESP catheters were placed effectively in a pediatric patient who previously had posterior spinal fusion and submitted to the Ravitch procedure.<sup>22</sup>

Additionally, although TEA has been considered the gold standard in postoperative pain management after thoracic and PE surgery for years, increasing evidence has suggested that less-invasive peripheral analgesic techniques are equally effective in pain management.<sup>11-16,26</sup> Regional blocks are also favored because of their reduced rates of complications, such as epidural hematoma and extensive sympathetic block.<sup>27</sup> In addition, spinal cord injury with long-term or permanent neurologic complications after TEA for PE surgery also has been reported.<sup>28</sup> Because the surgical repair of PE is performed in some patients for cosmetic reasons, several institutions no longer recommend TEA as an option for PE repair due to the above-mentioned risks.<sup>12</sup> Conversely, ultrasound-guided regional blocks decrease the risk of neurologic damage and pneumothorax in comparison to other techniques.<sup>29</sup>

In postthoracic surgery pain management, ESPB is performed in the posterior thoracic region homolateral to the site of the intervention at the level of the T5 transverse process, representing the ultrasound marker of the block.<sup>20,21</sup> Erector spinae plane block is easy and safe to perform because of the

ultrasound-guided method and the absence of vascular and nerve structures near the injection site. A T5-level block provides analgesia of both the anterolateral thoracic wall and axillary region. When ESPB is performed at the T5 level with 20 mL of anesthetic injected, cadaveric studies have demonstrated the spreading of anesthetics in the cranial-caudal sense (C7-T8), along the fascia of the erector spinae muscle, and in the anteroposterior sense, with block of the thoracic spinal nerve roots.<sup>17</sup> The local anesthetic distribution is similar between ESPB and PVB. They both diffuse anteriorly through the costotransverse foramen, and seem to follow the vessels and dorsal rami of spinal nerves into the adjacent paravertebral and intercostal spaces. This causes potential blocking of not only the ventral and dorsal rami of spinal nerves, but also the rami communicantes-containing sympathetic.<sup>30,31</sup> In addition to sensory block, ESPB also can involve the sympathetic chain, like PVB, thoracic sympathetic chain.<sup>15</sup> Toward the anterior cutaneous branch region, where sternal nerve supply extends from the second to sixth intercostal nerve, a partial sternal dermatomal coverage also has been suggested.<sup>17,32-34</sup>

This study had some limitations. First, due to the observational and retrospective nature, the conclusions of this study may have been limited by potential errors in data collection and documentation. Although using propensity-score matching may have reduced the risk of bias and improved the validity of the authors' analysis, selection bias was not completely eliminated. Thus, a prospective randomized trial would be desirable in order to confirm these results and to evaluate several aspects of postoperative pain using dedicated and validated questionnaires or scales.

Second, the small sample size and the reduced number of patients who received ESPB represent another relevant study limitation. Third, in this study, the authors assessed postoperative pain after surgical repair, including 2 different techniques (Nuss and Ravitch procedures). Fourth, after block execution, an assessment of the extent of the sensory block was not performed. Finally, although no adverse block-related events were reported in this study, due to the large volume of anesthetic, it should be remembered that there is a risk of local anesthetic systemic toxicity with the ESPB for PE surgery. This toxicity is secondary to systemic absorption, similar to that seen with intercostal nerve blocks or other volume-dependent fascial blocks.<sup>35</sup> Further studies are needed to evaluate the systemic absorption of local anesthetic after ESPB.

## Conclusions

In conclusion, this retrospective study suggested that ESPB could be a safe and valuable strategy for pain management after the surgical repair of PE via the Nuss or Ravitch techniques as part of a multimodal approach. The combination of this technique was demonstrated to be superior to systemic analgesia alone and may help assure good perioperative pain management with limited postoperative opioid consumption and consequent reduced opioid-related adverse effects.

## Conflict of Interest

None.

## Acknowledgments

The authors would like to thank Alessia Valentini for the graphical illustrations.

## References

- Fonkalsrud EW. Current management of pectus excavatum. *World J Surg* 2003;27:502–8.
- Frantz FW. Indications and guidelines for pectus excavatum repair. *Curr Opin Pediatr* 2011;23:486–91.
- Mavi J MD. Anesthesia and analgesia for pectus excavatum surgery. *Anesthesiol Clin* 2014;32:175–84.
- Pilegaard HK, Grosen K. Postoperative pain location following the Nuss procedure—what is the evidence and does it make a difference? *Eur J Cardiothorac Surg* 2010;38:208–9.
- Papic JC, Finnell SME, Howenstein AM, et al. Postoperative opioid analgesic use after Nuss versus Ravitch pectus excavatum repair. *J Pediatr Surg* 2014;49:919–23.
- Siddiqui A, Tse A, Paul J, et al. Postoperative epidural analgesia for patients undergoing pectus excavatum corrective surgery: A 10-year retrospective analysis. *Local Reg Anesth* 2016;9:25–33.
- Patvardhan C, Martinez G. Anaesthetic considerations for pectus repair surgery. *J Vis Surg* 2016;2:76.
- Muhly WT, Maxwell LG, Cravero JP. Pain management following the Nuss procedure: A survey of practice and review. *Acta Anaesthesiol Scand* 2014;58:1134–9.
- St Peter SD, Weesner KA, Weissend EE, et al. Epidural vs patient-controlled analgesia for postoperative pain after pectus excavatum repair: A prospective, randomized trial. *J Pediatr Surg* 2012;47:148–53.
- Weber T, Mätzl J, Rokitansky A, et al. Superior postoperative pain relief with thoracic epidural analgesia versus intravenous patient-controlled analgesia after minimally invasive pectus excavatum repair. *J Thorac Cardiovasc Surg* 2007;134:865–70.
- Rawal N. Epidural technique for postoperative pain: Gold standard no more? *Reg Anesth Pain Med* 2012;37:310–7.
- St Peter SD, Weesner KA, Sharp RJ, et al. Is epidural anesthesia truly the best pain management strategy after minimally invasive pectus excavatum repair? *J Pediatr Surg* 2008;43:79–82.
- Hall Burton DM, Boretsky KR. A comparison of paravertebral nerve block catheters and thoracic epidural catheters for postoperative analgesia following the Nuss procedure for pectus excavatum repair. *Paediatr Anaesth* 2014;24:516–20.
- Archer V, Robinson T, Kattail D, et al. Postoperative pain control following minimally invasive correction of pectus excavatum in pediatric patients: A systematic review. *J Pediatr Surg* 2020;55:805–10.
- Qi J, Du B, Gurnaney H, et al. A prospective randomized observer-blinded study to assess postoperative analgesia provided by an ultrasound-guided bilateral thoracic paravertebral block for children undergoing the Nuss procedure. *Reg Anesth Pain Med* 2014;39:208–13.
- Loftus PD, Elder CT, Russell KW, et al. Paravertebral regional blocks decrease length of stay following surgery for pectus excavatum in children. *J Pediatr Surg* 2016;51:149–53.
- Forero M, Adhikary SD, Lopez H, et al. The erector spinae plane block a novel analgesic technique in thoracic neuropathic pain. *Reg Anesth Pain Med* 2016;41:621–7.
- Fiorelli S, Leopizzi G, Saltelli G, et al. Bilateral ultrasound-guided erector spinae plane block for postoperative pain management in surgical repair of pectus excavatum via Ravitch technique. *J Clin Anesth* 2019;56:28–9.
- Nardiello M, Herlitz M. Bilateral single shot erector spinae plane block for pectus excavatum and pectus carinatum surgery in two pediatric patients. *Rev Esp Anesthesiol Reanim* 2018;65:530–3.
- Yoshizaki M, Murata H, Ogami-Takamura K, et al. Bilateral erector spinae plane block using a programmed intermittent bolus technique for pain management after Nuss procedure. *J Clin Anesth* 2019;57:51–2.
- Lowery DR, Raymond DP, Wyler DJ, et al. Continuous erector spinae plane blocks for adult pectus excavatum repair. *Ann Thorac Surg* 2019;108:e19–20.
- Le S, Lo C, Costandi A, et al. Bilateral Erector Spinae Plane (ESP) catheters for Ravitch procedure in a pediatric patient with Harrington rods. *J Clin Anesth* 2020;66:109925.
- Haller JA Jr, Kramer SS, Lietman SA. Use of CT scans in selection of patients for pectus excavatum surgery: A preliminary report. *J Pediatr Surg* 1987;22:904–6.
- Bliss DP, Strandness TB, Derderian SC, et al. Ultrasound-guided erector spinae plane block versus thoracic epidural analgesia: Postoperative pain management after Nuss repair for pectus excavatum. *J Pediatr Surg* 2022;57:207–12.
- Fiorelli S, Leopizzi G, Massullo D, et al. Anesthetic management of a patient with Freeman-Sheldon syndrome in thoracic surgery. *J Clin Anesth* 2018;48:48–9.
- Tore Altun G, Arslantas MK, Corman Dincer P, et al. Ultrasound-guided serratus anterior plane block for pain management following minimally invasive repair of pectus excavatum. *J Cardiothorac Vasc Anesth* 2019;33:2487–91.
- Umari M, Segat M, Lucangelo U. Epidural for mini-invasive thoracic surgery: Do we need a sledgehammer to crack a nut? *J Thorac Dis* 2018;10:S2223–4.
- Meyer MJ, Krane EJ, Goldschneider KR, et al. Case report: Neurological complications associated with epidural analgesia in children: A report of 4 cases of ambiguous etiologies. *Anesth Analg* 2012;115:1365–70.
- Forero M, Rajarathinam M, Adhikary S, et al. Continuous erector spinae plane block for rescue analgesia in thoracotomy after epidural failure: A case report. *A A Case Reports* 2017;8:254–6.
- Diwan S, Garud R, Nair A. Thoracic paravertebral and erector spinae plane block: A cadaveric study demonstrating different site of injections and similar destinations. *Saudi J Anaesth* 2019;13:399–401.
- Bonvicini D, Boscolo-Berto R, De Cassai A, et al. Anatomical basis of erector spinae plane block: A dissection and histotopographic pilot study. *J Anesth* 2021;35:102–11.
- Leyva FM, Mendiola WE, Bonilla AJ, et al. Continuous erector spinae plane (ESP) block for postoperative analgesia after minimally invasive mitral valve surgery. *J Cardiothorac Vasc Anesth* 2018;32:2271–4.
- Taketa Y, Irisawa Y, Fujitani T. Ultrasound-guided erector spinae plane block elicits sensory loss around the lateral, but not the parasternal, portion of the thorax. *J Clin Anesth* 2018;47:84–5.
- Roy N, Brown ML, Parra MF, et al. Bilateral erector spinae blocks decrease perioperative opioid use after pediatric cardiac surgery. *J Cardiothorac Vasc Anesth* 2021;35:2082–7.
- Hessian EC, Evans BE, Woods JA, et al. Plasma ropivacaine concentrations during bilateral transversus abdominis plane infusions. *Br J Anaesth* 2013;111:488–95.