

Contents lists available at [ScienceDirect](https://www.sciencedirect.com)

American Journal of Ophthalmology Case Reports

journal homepage: www.ajocasereports.com/

Topical treatment of dupilumab-associated refractory conjunctivitis and keratitis

Federico Di Staso^{a,*}, Alessandro Lambiase^c, Silvio Di Staso^b, Irene Gattazzo^a, Marco Ciancaglini^b, Gianluca Scuderi^a

^a Ophthalmology Unit, Neurosciences, Mental Health and Sensory Organs Department, St. Andrea Hospital, Sapienza University of Rome, 00100, Rome, Italy

^b Ophthalmic Clinic, Department of Life, Health and Environmental Sciences, University of L'Aquila, 67100, L'Aquila, Italy

^c Department of Sense Organs, Policlinico Umberto I, Sapienza University of Rome, Piazzale Aldo Moro 5, 00185, Rome, Italy

ARTICLE INFO

Keywords:

Atopic dermatitis
Conjunctivitis
Dupilumab
Keratitis

ABSTRACT

Purpose: To report 3 cases of severe dupilumab-related conjunctivitis and keratitis topical treatment.

Observation: Description, management, and outcomes of dupilumab-related refractory conjunctivitis associated with punctate keratitis.

Three patients with atopic dermatitis (AD) experiencing severe ophthalmic complications following dupilumab treatment were referred to us when conventional management methods failed. We treated them topical and external pimecrolimus 10 mg/g cream to the eyelids. The patients showed substantial clinical remission within 10 days.

Conclusions and importance: Those cases are remarkable as a drug applied externally to the eyelid skin successfully treated underlying conjunctivitis and punctate keratitis. The complete clinical remission suggests that pimecrolimus applied topically to the eyelid skin is a safe and effective delivery route. The resolution of the keratitis and conjunctivitis presumably represents either a contiguous effect of the improvement of the cutaneous inflammation, or the effect of transcutaneous pimecrolimus penetration through the eyelid.

Further studies are needed to support the use of this drug for dupilumab-associated conjunctivitis.

1. Introduction

Patients with atopic dermatitis (AD) commonly experience ophthalmic complications, namely allergic conjunctivitis, blepharitis, and keratitis, with an incidence of 32.4–55.8% that increases with the severity of skin disease.^{1,2}

Dupilumab is a monoclonal antibody which binds the alpha subunit of IL-4 receptor. This drug is the first biologic agent approved for treatment of AD in adult patients who are candidates for systemic therapy.³

The aim of this case report is to show the effects of topical application of pimecrolimus to the eyelids in a case series of dupilumab-associated extremely severe refractory conjunctivitis, punctate keratitis and periocular skin involvement.

2. Findings

Three patients (one male and two females) affected with severe

keratoconjunctivitis were enrolled in this study. These patients had started treatment with subcutaneous (SC) administration of dupilumab at 300 mg every 2 week for the treatment of moderate-to-severe AD. The severity of AD was classified using the Eczema Area and Severity Index (EASI Index) at the start of dupilumab treatment and at the latest dermatological follow-up. On this score, four clinical characteristics (erythema, induration, excoriation, and lichenification) are evaluated on a scale of zero (absent) to three (severe), along with disease extension measured at four body sites (head and neck, upper limbs, trunk, lower limbs). EASI can reach a maximum score of 72. In all patients, best corrected visual acuity (BCVA), slit lamp biomicroscopy, Goldmann applanation tonometry, fundus examination and tear break-up time (TBUT) test were performed before enrolment and at end of follow-up.

Written informed consent was obtained from the patients before enrolment. All previous local therapies were discontinued and pimecrolimus 10 mg/g cream was applied to the eyelid skin twice a day for seven days and a follow-up examination was performed at that time. The therapy was then continued at the frequency of two applications daily

* Corresponding author. Via di Boccea 190, Rome, 00167, Italy.

E-mail address: federico.distaso@gmail.com (F. Di Staso).

<https://doi.org/10.1016/j.ajoc.2022.101309>

Received 16 January 2021; Received in revised form 28 July 2021; Accepted 19 January 2022

Available online 25 January 2022

2451-9936/© 2022 The Authors. Published by Elsevier Inc. This is an open access article under the CC BY license (<http://creativecommons.org/licenses/by/4.0/>).

for the first 10 days and then once daily for 30 more days. The study adhered to the tenets of the Declaration of Helsinki.

3. Case 1

A 36-year-old female Caucasian patient presented with extremely severe conjunctivitis and periocular skin involvement which had been present for five years since starting biologic therapy.

EASI Index at the start of dupilumab therapy was 38.2. At the latest dermatological follow-up, the score had reduced to 3.60. She had previously sought medical care for conjunctivitis and treatments to date had included corticosteroid eye drops (3 cycles of dexamethasone 0.1%, 4 times a day for 10–15 days), ketotifen eye drops and artificial tears.

Ocular physical examination showed bilateral eczematoid blepharitis with scattered periocular skin ulcers, caruncular edema, lacrimal punctum swelling, severe conjunctival injection, chemosis, papillary hypertrophy, peri-limbal corneal injection, intense watery discharge (Fig. 1 A) and punctate keratitis (Fig. 2 A). There was significant reduction of tear breakup time (TBUT): 4 seconds in right eye (RE) and 5 seconds in left eye (LE).

The patient was diagnosed with atopic conjunctivitis resistant to steroid ocular preparations. Pimecrolimus 10 mg/g cream was prescribed, to be applied to the eyelid twice daily.

At the 7-day follow-up visit, physical examination showed substantial regression of the conjunctivitis, dramatic improvement of the erythema and lichenification, and resolution of the periocular skin ulcers (Fig. 1 B). The ocular surface symptoms were markedly improved and there was complete resolution of the punctate keratitis (Fig. 2 B).

Pimecrolimus therapy was continued at the frequency of two applications daily to complete 10 days, then once daily for 30 more days. At the final follow-up visit, the clinical resolution was stable, and improvement of lacrimal function was found with increase stability of tear film (TBUT 8 seconds in right eye and 10 seconds in left eye).

4. Case 2

A 33-year-old female caucasian patient, after four weeks of dupilumab therapy for AD, complained of severe itching, eye redness, foreign body sensation and intermittent blurry vision. Patient reported a

previous episode of tacrolimus ointment allergy.

EASI score at the start of dupilumab therapy was 14.0. At the latest dermatological follow-up, the score had reduced to 1.

Ocular physical examination showed eczematoid blepharitis, caruncular edema, lacrimal punctum swelling, moderate conjunctival injection, chemosis, peri-limbal corneal injection and mild diffuse punctate keratitis in both eyes.

The patient was previously treated several times unsuccessfully with corticosteroid eye drop (3 cycles of dexamethasone 0.1%, 3 times a day for 15 days, and 1 cycle of Prednisone 1% 2 times a day for 15 days) and artificial tears.

Therapy with pimecrolimus 10 mg/g cream was started, applied topically to the eyelids twice daily. At the 7-day follow-up visit, physical examination showed complete remission of the conjunctivitis and complete resolution of the punctate keratitis.

Pimecrolimus therapy was continued to complete two applications for the first 10 days and then once daily for 30 more days. A clear increase in tears function was noted at the end of treatment compared to the initial presentation (TBUT test: RE 5 sec before vs 12 sec after treatment, LE 6 sec vs 13 sec after treatment).

5. Case 3

A 35-year-old male caucasian patient, three weeks after the start of dupilumab therapy for AD, complained of severe night-time itching, eye redness, intermittent foreign body sensation, watery discharge, and moderate photophobia. EASI score at the start of dupilumab therapy was 12.2. At the latest dermatological follow-up, the score had reduced to 1.

Ocular physical examination showed bilateral eczematoid blepharitis, moderate conjunctival injection, mild chemosis, peri-limbal corneal injection and mild diffuse punctate keratitis.

Previous dexamethasone and prednisone eye drops treatments were reported by the patient to be unsuccessful, although she was not able to recall the therapeutic schemes.

Even in this case, the pimecrolimus 10 mg/g cream topically to the eyelid twice a day until clinical remission was administered. The patient missed the 7-day follow-up visit and was reassessed 3 days after. Physical examination showed complete clinical remission and the therapy was continued at the frequency of two applications daily for the first 10

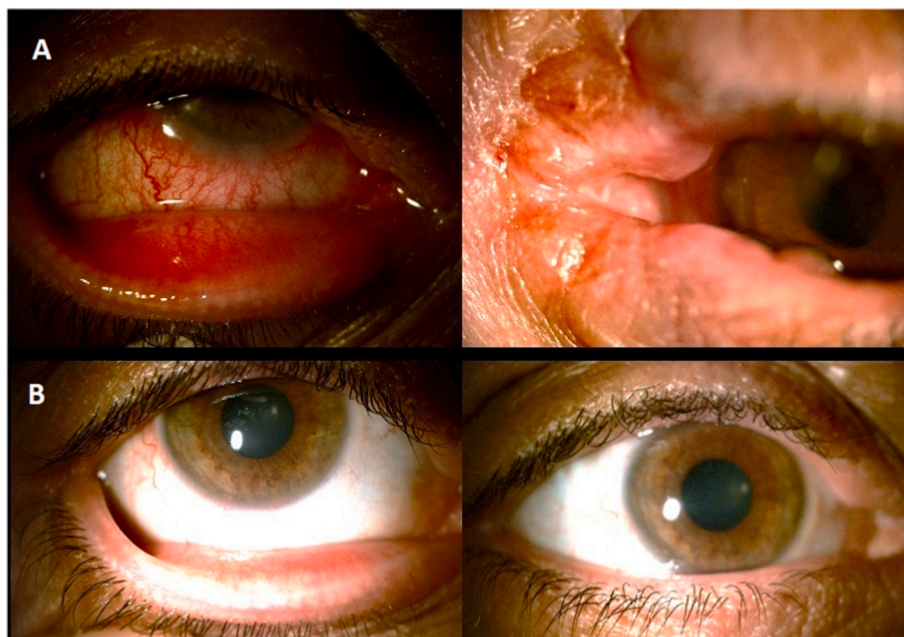

Fig. 1. A: bilateral eczematoid blepharitis with scattered ulcers, caruncular edema, lacrimal punctum swelling, severe conjunctival injection. 1 B: substantial regression of the conjunctivitis, dramatic improvement of the erythema, lichenification and periocular skin ulcers.

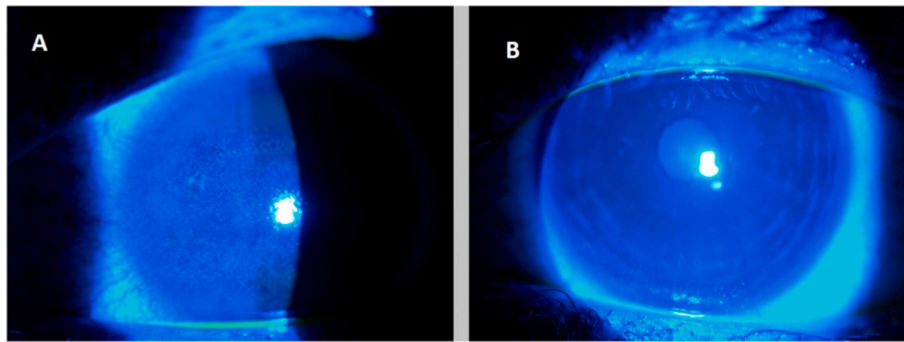


Fig. 2. A: Punctate keratitis before pimecrolimus application. 2B: punctate keratitis resolution after 7 days treatment.

days and then once a day for 30 more days. The resolution of ocular signs and symptoms was followed by an increase of tears stability (TBUT test: RE 6 sec before vs 14 sec after treatment, LE 6 sec vs 14 sec after treatment).

6. Discussion

One of the most frequent side effects of dupilumab therapy is conjunctivitis. Despite this, the pathogenesis of conjunctivitis in dupilumab-treated patients is not well-understood and no standard guidelines exist on how to diagnose and treat this particular clinical condition. Several therapeutic approaches were successfully used in clinical practice for treatment of mild conjunctivitis without discontinuation of dupilumab, including hyaluronic acid eyedrops, tacrolimus eyedrops, topical corticosteroids, artificial tears and compounded oily ciclosporin eyedrops. However, in moderate to severe cases, some authors suggested to either discontinue dupilumab systemic treatment or decreasing dose frequency (e.g. once every 4–8 weeks).⁴

Ocular application of calcineurin inhibitors (tacrolimus 0.1, 0.03 and 0.02% eye ointments) is an effective therapy for various inflammatory conditions of the eye and has been used successfully in the treatment of allergic conjunctivitis and vernal keratoconjunctivitis.^{5,6} Calcineurin inhibitors specifically inhibit calcineurin which plays a central role in T-cell activation. However, a commercial preparation of topical tacrolimus eye drops has been approved only in few countries.

In a recent report, four patients with dupilumab-related conjunctivitis were treated with tacrolimus 0.03% eye ointment or with flurometholone 0.1% eyedrops leading to the recommendation for use of either one of these agents in this setting.⁷ Our previous case report⁸ showed how a treatment with commercially available pimecrolimus cream led to resolution of a case of refractory conjunctivitis, resistant to topical corticosteroid treatment, and appeared to be a viable alternative to off-label uses of other calcineurin inhibitor preparations. In the latter case, there was no sign of corneal involvement, but we prefer external application to the eyelids even in these new patients as it ensures patient compliance due to the easy route of administration, and the avoidance of potential interferences with therapies directed to the eye surface for simultaneous ophthalmic disorders. We postulate that external pimecrolimus cream could maximize the benefits and minimize the drug interactions risk when compared to tacrolimus applied directly to the eye surface.

Additionally, the systemic blockade of IL-4/IL-13 pathways due to dupilumab administration is not risk-free⁹ and we think that the combination with others immune-modulating agents, such as calcineurin inhibitors applied directly to the eye, may impair viral defenses and expose patients to infectious complications such as viral cheratitis and uveitis. In normal human skin, calcineurin inhibitors demonstrated substantial penetration with minimal systemic absorption and low blood concentrations.¹⁰

Previous studies have shown that topical tacrolimus is well tolerated

and efficacious when applied directly to ocular surface,¹¹ and in one study tacrolimus appeared superior to pimecrolimus as an alternative to topical corticosteroids in the treatment of AD.¹² Our experience with the patients in this report suggests that topical pimecrolimus cream application to the eyelid skin could represent an additional therapeutic approach for dupilumab-induced keratoconjunctivitis and has advantage of ease of application.

It is not clear by what mechanism pimecrolimus applied to the eyelid effected improvements in our patients' keratitis. We suspect that either pimecrolimus might penetrate beyond the eyelid skin and reach the conjunctiva, or that conjunctival and corneal inflammation are an extension of the cutaneous inflammatory process, such that treatment of one affects the other.

7. Conclusions

Topical pimecrolimus applied to the eyelids appears efficacious at treating dupilumab associated keratoconjunctivitis and seems to be safe and well tolerated. This approach could represent a valid therapeutic alternative to tacrolimus or corticosteroids eyedrops, especially in complicated cases such as corneal involvement, or where corticosteroids or tacrolimus are poor therapeutic options. Additional studies of this therapy are warranted.

Patient consent

Written informed consent was obtained from patients for publication of these case reports and any accompanying images.

Funding

No funding or grant support.

Authorship

All authors attest that they meet the current ICMJE criteria for Authorship.

Declaration of competing interest

The following authors have no financial disclosures: FDS, AL, SDS, IG, MC, GS.

Acknowledgement

None.

References

1. Bielory B, Bielory L. Atopic dermatitis and keratoconjunctivitis. *Immunol Allergy Clin.* 2010;30(3):323–336.

2. Thyssen JP, Toft PB, Halling-Overgaard AS, Gislason GH, Skov L, Egeberg A. Incidence, prevalence, and risk of selected ocular disease in adults with atopic dermatitis. *J Am Acad Dermatol*. 2017;77(2):280–286.
3. Thaçi D, Simpson EL, Deleuran M, et al. Efficacy and safety of dupilumab monotherapy in adults with moderate-to-severe atopic dermatitis: a pooled analysis of two phase 3 randomized trials. *J Dermatol Sci*. 2019;94(2):266–275.
4. Levine RM, W Tattersall I, Gaudio PA, King BA. Cicatrizing blepharoconjunctivitis occurring during dupilumab treatment and a proposed algorithm for its management. *JAMA Dermatol*. 2018;154(12):1485–1486.
5. Fukushima A, Ohashi Y, Ebihara N, et al. Therapeutic effects of 0.1% tacrolimus eye drops for refractory allergic ocular diseases with proliferative lesion or corneal involvement. *Br J Ophthalmol*. 2014;98(8):1023–1027.
6. Ohashi Y, Ebihara N, Fujishima H, et al. A randomized, placebo-controlled clinical trial of tacrolimus ophthalmic suspension 0.1% in severe allergic conjunctivitis. *J Ocul Pharmacol Therapeut*. 2010;26(2):165–174.
7. Wollenberg A, Ariens L, Thurau S, van Luijk C, Seegräber M, de Bruin-Weller M. Conjunctivitis occurring in atopic dermatitis patients treated with dupilumab—clinical characteristics and treatment. *J Allergy Clin Immunol Pract*. 2018; 6(5):1778–1780.
8. Sernicola A, Gattazzo I, Di Staso F, et al. Treatment of refractory conjunctivitis associated to dupilumab with topical pimecrolimus applied to the eyelid skin. *Dermatol Ther*. 2019;32(6), e13134.
9. Ivert LU, Wahlgren CF, Ivert L, Lundqvist M, Bradley M. Eye complications during dupilumab treatment for severe atopic dermatitis. *Acta Derm Venereol*. 2019;99(4): 375–378.
10. Pariser D. Topical corticosteroids and topical calcineurin inhibitors in the treatment of atopic dermatitis: focus on percutaneous absorption. *Am J Therapeut*. 2009;16(3): 264–273.
11. Aszodi N, Thurau S, Seegräber M, de Bruin-Weller M, Wollenberg A. Management of dupilumab-associated conjunctivitis in atopic dermatitis. *JDDG J der Deutschen Dermatol Gesellschaft*. 2019 May;17(5):488–491.
12. Ashcroft DM, Dimmock P, Garside R, Stein K, Williams HC. Efficacy and tolerability of topical pimecrolimus and tacrolimus in the treatment of atopic dermatitis: meta-analysis of randomised controlled trials. *BMJ*. 2005 Mar 3;330(7490):516.