

Obstructed Hemivagina and Ipsilateral Renal Anomaly Syndrome: A Systematic Review about Diagnosis and Surgical Management

Graziella Moufawad¹, Andrea Giannini², Ottavia D'Oria², Antonio Simone Laganà³, Vito Chiantera³, Aline Khazzaka⁴, Ghida Maziad¹, Elena Nasr¹, Vanessa Geagea¹, Marwa Al Jardali¹, Zaki Sleiman^{1*}

¹Department of Obstetrics and Gynaecology, School of Medicine, Lebanese American University, Beirut, Lebanon, ²Department of Medical and Surgical Sciences and Translational Medicine, Sapienza University, Rome, ³Unit of Gynecologic Oncology, ARNAS "Civico – Di Cristina – Benfratelli", Department of Health Promotion, Mother and Child Care, Internal Medicine and Medical Specialties (PROMISE), University of Palermo, Palermo, Italy, ⁴Department of Obstetrics and Gynaecology, Laboratory of Science and Research, Saint Joseph University, Beirut, Lebanon

Abstract

Obstructed hemivagina and ipsilateral renal agenesis (OHVIRA) syndrome is a rare congenital defect of the Müllerian ducts characterized by uterus didelphys, unilateral obstructed hemivagina, and ipsilateral renal agenesis. The aim of this systematic review is to summarize the main symptoms and presentation of the OHVIRA syndrome, as well as the different types of management, fertility, and obstetrical outcomes. A comprehensive search was performed in PubMed, EMBASE, SCOPUS, and Web of Science databases since inception to May 1, 2022, according to the Preferred Reporting Items for Systematic Reviews and Meta-Analyses statement. After duplicate records removed, the search strategy retrieved 103 articles. The full texts of 73 articles further were assessed for eligibility, and 44 studies were finally included in the systematic review. The mainstay surgical treatment of OHVIRA syndrome is usually a minimally invasive vaginal approach to remove the septum. Ultrasound-guided hysteroscopic resection and laparoscopic resection of the septum have been described as alternatives. Considering the feasibility of minimally invasive approach for the management of the syndrome, laparotomy should be avoided as much as possible and considered only in selected cases.

Keywords: Fertility-sparing surgery, Müllerian anomalies, obstructed hemivagina and ipsilateral renal agenesis syndrome, pelvic pain

INTRODUCTION

Obstructed hemivagina and ipsilateral renal agenesis (OHVIRA) syndrome is a congenital female urogenital tract malformation (previously known as Herlyn–Werner–Wunderlich syndrome).^[1-3] The incidence of OHVIRA syndrome varies from 0.1% to 3.8%.^[4] It is characterized by a triad of uterus didelphys, unilateral obstructed hemivagina, and ipsilateral renal agenesis.^[1-3] The incidence is underestimated due to underdiagnosis and lack of awareness of this syndrome.^[5] A disturbance of the normal embryological

development of the female urogenital tract causes this defect, with an abnormal development of the Müllerian and the Wolffian ducts during embryological development.^[4,6] A failed or an abnormal fusion of Müllerian ducts between 10 and 12 weeks of gestational age would lead to a uterine duplication and vaginal septum formation, depending on the level at which the fusion occurs.^[2] OHVIRA syndrome is one of the syndromes caused by the abnormal development of the Müllerian ducts. Among the other anomalies, Müllerian

Address for correspondence: Dr. Zaki Sleiman, Department of Obstetrics and Gynaecology, School of Medicine, Lebanese American University, Beirut, Lebanon. E-mail: zaki.sleiman@laumcrh.com

Article History:

Submitted: 12-Sep-2022

Revised: 03-Oct-2022

Accepted: 15-Nov-2022

Published: 10-Aug-2023

Access this article online

Quick Response Code:



Website:
<https://journals.lww.com/gmit>

DOI:
10.4103/gmit.gmit_103_22

This is an open access journal, and articles are distributed under the terms of the Creative Commons Attribution-NonCommercial-ShareAlike 4.0 License, which allows others to remix, tweak, and build upon the work non-commercially, as long as appropriate credit is given and the new creations are licensed under the identical terms.

For reprints contact: WKHLRPMedknow_reprints@wolterskluwer.com

How to cite this article: Moufawad G, Giannini A, D'Oria O, Laganà AS, Chiantera V, Khazzaka A, *et al.* Obstructed hemivagina and ipsilateral renal anomaly syndrome: A systematic review about diagnosis and surgical management. *Gynecol Minim Invasive Ther* 2023;12:123-9.

cysts may result from incomplete regression, and Mayer–Rokitansky–Küster–Hauser syndrome may be characterized by one unicornuate uterus and one rudimentary uterine horn.^[7-9] OHVIRA presents with a partial septum leading to one unobstructed and one obstructed vagina.

According to Kudela *et al.*, there are no robust recommendations to screen for Müllerian and renal anomalies in females due to the low incidence of this syndrome. However, due to the high association between Müllerian and renal abnormalities, it is recommended to screen females with prenatally detected renal abnormalities also for Müllerian anomalies.^[4]

The aim of this systematic review is to summarize the main symptoms and presentation of the OHVIRA syndrome, as well as the different types of management, fertility, and obstetrical outcomes.

MATERIALS AND METHODS

A systematic search (PROSPERO registration ID: CRD42022350289) was performed prior to May 1, 2022, using the following databases: MEDLINE, EMBASE, Global Health, The Cochrane Library (Cochrane Database of Systematic Reviews, Cochrane Central Register of Controlled Trials, Cochrane Methodology Register), Health Technology Assessment Database and Web of Science, research registers (such as www.clinicaltrials.gov). The term “OHVIRA syndrome” was search in combination with the following keywords: “causes,” “embryogenesis,” “incidence,” “pathophysiology,” “presentation,” “management,” “minimally invasive,” “fertility sparing,” “non-fertility sparing,” “prognosis,” and “pregnancy outcomes.” Case reports with literature review, meta-analyses, case series, and narrative reviews were included. Studies reporting incomplete data were excluded. Titles and/or abstracts of studies retrieved using the search strategy, and those from additional sources, were screened independently by two review authors to identify studies that potentially meet the aims of this systematic review. The full text of these potentially eligible articles was retrieved and independently assessed for eligibility by other two review team members. Any disagreement between them over the eligibility of particular articles was resolved through discussion with a third (external) collaborator. Two authors independently extracted data from articles about study features and included populations, type of intervention, and outcomes. Any discrepancies were identified and resolved through discussion (with a third external collaborator where necessary).

RESULTS

The search strategy identified a total of 217 articles. One hundred and fourteen articles were removed because they

were duplicate records. The abstracts of the remaining 103 articles were screened, and 30 records were further excluded because they were not relevant for the purpose of the systematic review. The full texts of the remaining 73 were retrieved and assessed for eligibility, and 29 records were further excluded because not relevant. Finally, 44 articles were included for data extraction and discussion, as shown in Figure 1.

Due to the nature of the findings, we opted for a narrative synthesis of the results from the selected articles. We summarized and discussed the available pieces of evidence in each one of the following subsections (Symptoms, presentation, and diagnosis; Fertility-sparing surgery; nonfertility-sparing surgery; Strassman procedure; and Reproductive and obstetric outcomes).

DISCUSSION

Symptoms, presentation, and diagnosis

Complete obstruction of the vagina typically presents with a cyclic or recurrent pelvic pain due to hematocolpos caused by the obstruction preventing external bleeding (median age: 12–16 years). However, the presence of menarche does not exclude obstructive anomalies of the gynecologic tract, because the obstruction can be unilateral. These nonspecific symptoms (dysmenorrhea or pelvic pain) are very common in the female adolescent population. Therefore, the accurate

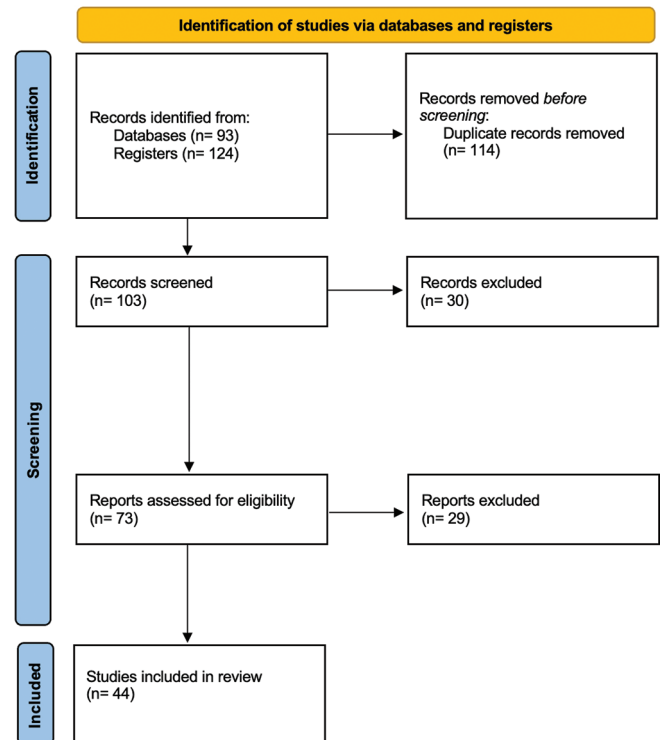


Figure 1: Flowchart for study screening, selection, and inclusion

diagnosis of Müllerian anomalies can be delayed up to years from initial presentation. According to Kapczuk *et al.*, the age at menarche ranged from 11 to 15.6 (median, 12.2) years, and the age at repair of the malformation ranged from 11.4 to 18.2 (median, 13.1) years.^[8-16] In contrast, urologic problems in patients with congenital renal anomalies might lead to the diagnosis of obstructed hemivagina during the prepubertal period, most frequently before the age of 5 years.^[8] In a retrospective cohort study of 65 patients, 44 patients were diagnosed during the prepubertal period. The median age at diagnosis was 8 days, and 19 patients were diagnosed during infancy.^[16]

The clinical presentation of menstruating patients with postpubertal OHVIRA syndrome differs from those of prepubertal patients. In the study conducted by Kimble and Kimble, 36 prepubertal patients out of 44 were asymptomatic at presentation, and the syndrome was diagnosed by prenatal sonography.^[17] Eight patients were symptomatic at the time of diagnosis and presented with a protruding vaginal mass ($n = 5$), vaginal bleeding or discharge ($n = 2$), and recurrent urinary tract infection ($n = 1$). In other studies, most of the patients presented with abdominal pain and dysmenorrhea, and on vaginal examination, the most significant finding was a bulge of hematocolpos in the lateral vaginal wall due to obstructed hemivagina by an oblique vaginal septum. On imaging, the majority of patients had hematometra, associated with hematosalpinx in the same cases.^[16-18] Other studies reported unusual presentations: acute urine and stool retention or acute retention of urine with fever, vomiting, and lower abdominal pain.^[11,19] Laparoscopy often allows to find several endometrial peritoneal deposits over the fallopian tube and ovary and in the Douglas pouch, mainly on the side of vaginal obstruction.^[11,12,18,19] In rare cases, the diagnosis of OHVIRA syndrome is also made after the perforation of the vaginal septum. In our systematic review, we found four patients who had spontaneous perforation of the vaginal septum that resulted in pain relief accompanied by either prolonged menstrual bleeding or purulent vaginal discharge, whereas one patient had a postpartum hemorrhage after massive vaginal rupture.^[8-15] Several articles mentioned the presence of pyocolpos at the time of the diagnosis of OHVIRA syndrome.^[20] Our group reported the case of a 20-year-old patient who presented with a 2-year history of primary infertility and dyspareunia;^[21] in this case, vaginal examination revealed a vaginal fluctuant painful mass obliterating the right part of the vagina, and excision of the right vaginal septum drained a purulent discharge. A similar case was reported by Kozłowski *et al.*: a 17-year-old patient presented with severe lower abdominal pain and a left-sided mass of 10.5 cm in the largest diameter. Upon speculum examination, a 3-mm hole in the

left vaginal vault was demonstrated and yellowish exudate was evacuated.^[22] Further investigations were done, and the patient was diagnosed with uterus didelphys with obstructed left hemivagina, left renal agenesis, pyohematocolpos, and pyohematometra. In other two different case reports, young females presented with abdominal pain, foul-smelling vaginal discharge and a fluctuant vaginal mass, with final diagnosis of OHVIRA syndrome.^[23,24] Drainage of the mass in both cases revealed purulent discharge and pyocolpos was confirmed.^[23] Pelvic ultrasonography (US) is the recommended modality of screening; magnetic resonance imaging (MRI), which is the gold standard for diagnosis, must follow if an abnormal finding was detected on US.^[2] Due to the outflow obstruction, retrograde blood flow can occur leading to endometriosis in 23% of OHVIRA cases.^[10] In a systematic review of 734 cases of OHVIRA syndrome, endometriotic lesions that are ipsilateral to the vaginal septum were found in 13.6% of patients; however, this could be an underestimation because not all patients underwent laparoscopic surgery for accurate diagnosis.^[4]

Fertility-sparing surgery

Early diagnosis in OHVIRA syndrome is very important to avoid delay in management, and associated complications (i.e. pelvic infection, endometriosis, and infertility).^[25] The mainstay treatment is surgery, using a vaginal approach to remove the septum. However, OHVIRA presents mostly early during adolescence, when most patients are still virgo, precluding the vaginal approach.^[26] In such patients, minimally invasive approaches are preferred for symptomatic relief. Traditionally, OHVIRA syndrome was best treated with transvaginal resection of the obstructed septum, followed by anastomosis of the vaginal mucosa, which can be extremely difficult to do in virgin girls due to the tight vaginal opening.^[27,28] Moreover, this requires hymen disruption, limiting this approach in patients refusing to lose their hymen integrity. For instance, Gündüz *et al.* reported the case of a 14-year-old girl with MRI showing right hematocolpos, hematometra, and hematosalpinx.^[18] Diagnostic vaginoscopy was performed. Hymenotomy with right vaginal septal resection was made and 450 ml of blood was drained. The incision was performed and then marsupialized and hymen repair was done at the end of the procedure. One week later, the patient presented with severe abdominal pain. Right hematosalpinx was seen on ultrasound. Laparotomy followed: salpingostomy was performed and hematoma drained.

In the case of virgin patients who wish to maintain their virginity, hysteroscopic resection of the septum under transabdominal guidance has been reported.^[29] Dissecting the vaginal septum made the space wider and the ipsilateral cervix visible.^[27] Hysteroscopic resection of the obstructed

septum is a fast and simple way to preserve the hymen. Accuracy is improved with the use of the transabdominal US, facilitating the procedure in case of small hematocolpos.^[30] Another study reported the case of a 13-year-old girl with uterus didelphys on MRI, and 5 cm fluid-filled mass highly suggestive of hematometrocolpos between the vagina on the left and the cervix on the right. In this case, a mini-laparotomy was performed: hematocolpos and hematosalpinx were present on the right side. Since septum resection could not be accomplished, a unilateral hysterectomy was done and resection of the obstructed hemivagina followed.^[30]

Another alternative option to the traditional vaginal approach while preserving the hymen is the use of transrectal ultrasound (TRUS)-guided vaginoscopic septoplasty, with the use of a novel ultrasound technique, the three-dimensional saline-solution infusion contrast sonovaginocervicography (3D-SVC). In a recent study, 3D-SVC was used for preoperative patients' assessment with the use of TRUS and surgery was planned accordingly. Incision was made under TRUS guidance.^[31]

The standard treatment of OHVIRA syndrome is usually done through the vagina, requiring a two-step or a single-step vaginoplasty approach.^[32,33] A single-step vaginoplasty can be challenging, especially in young girls with narrow vaginas. Thus, the two-step approach can be done as an alternative. We recently described a new laparoscopic approach in virgin patients with OHVIRA syndrome: A 30-year-old sexually inactive woman presented with OHVIRA syndrome with a complete uterine septum and a longitudinal vaginal septum causing hematocolpos.^[32] She refused vaginal surgery and laparoscopy approach was used: A transverse anterior colpotomy was first done and then resection of the longitudinal vaginal septum followed. Finally, intracorporeal suturing was used to close the transverse vaginal incision. The laparoscopy-assisted vaginal resection of the septum was offered to another 16-year-old woman who refused the vaginal approach. In this case, a posterior colpotomy was done through which the hematocolpos was drained. Then, an atraumatic fenestrated laparoscopic grasper was introduced through this posterior colpotomy and pushed downward the high vaginal septum, exposing the vaginal septum outside the hymenal ring, which allowed excision of the septum using the classical resection/marsupialization. The colpotomy was repaired with absorbable simple sutures. This approach allows bringing the high vaginal septum directly to the level of the hymenal ring using the laparoscopic assistance, and classical resection of the septum followed, allowing the conservation of the hymen. Laparotomy could be done, with the disadvantages of more postoperative pain, longer hospital stays, late ambulation, and delayed return to daily activities.^[32,33]

As recently highlighted by Kriplani *et al.*, the mainstay management of OHVIRA syndrome has shifted to minimally invasive techniques.^[16] Several studies highlighted the importance of laparoscopy in OHVIRA management by describing it as the gold standard for diagnosis.^[32-34]

From this overview, a combination of hysteroscopy and laparoscopy as a surgical approach for OHVIRA syndrome management could be considered feasible, except in few cases. Hysteroscopy without laparoscopy should be used if MRI did not reveal any ovarian mass, ectopic ureter, hematosalpinx nor hematometra. Furthermore, the presence of a large bulge which clearly delineates the landmark of the vaginal septum precludes the use of laparoscopy; otherwise, laparoscopy would be needed in cases of small bulge.

Nonfertility-sparing surgery

The gold standard management for OHVIRA syndrome is septum resection and vaginoplasty. Nevertheless, in some rare cases, a surgeon may consider hemi-hysterectomy or even hysterectomy in difficult cases of proximal vaginal septum and impossibility of performing vaginoplasty, or in cases in which diagnosis is delayed leading to pelvic infections, pelvic inflammatory disease, and pyometra with or without microperforations of the septum.^[35] According to Gungor Ugurlucan *et al.*, MRI findings, in particular the distance from hematocolpos to perineum, correlate with surgical outcome.^[3]

Total hysterectomy is usually avoided, and fertility-sparing options are preferred. Cases of large hematometra, pyometra, and altered fallopian tube conditions, or cases of extensive adhesions, might be an indication for hysterectomy. In a systematic review of 734 cases, Kudela *et al.* reported that total hysterectomy was performed only in 0.7% of the cases.^[4]

Strassman procedure

Strassman procedure, which was once used for the treatment of bicornuate uterus, is a procedure during which metroplasty is performed by laparoscopy or laparotomy. A fundal uterine incision is done, followed by dissection layer by layer until reaching the endometrium and then apposition of the two uterine horns followed by uterine suturing in layers.^[36] Nabeshima *et al.* reported the case of laparoscopic Strassman procedure in a 12-year-old girl diagnosed with incomplete OHVIRA syndrome, with the absence of hemivaginal septum.^[37] Laparoscopic metroplasty was successful, and the patient no longer reported dysmenorrhea. However, this procedure did not find success in the management of OHVIRA syndrome due to its increased complications, such as Asherman's syndrome and adverse obstetrical outcomes. According to Zhang *et al.*, severe and potentially deadly complications can arise post Strassman procedure leading to placenta accreta, postpartum hemorrhage, and uterine rupture.^[38] Thus, Strassman procedure should no longer be

used in the fertility-sparing option for OHVIRA syndrome management.

Reproductive and obstetric outcomes

Recent studies and numerous case reports showed that early diagnosis and surgical treatment in OHVIRA patients can prevent complications and preserve future fertility.^[39] Candiani *et al.* have followed up on thirty cases in which vaginal septum was excised, and marsupialization was done.^[40] The pregnancy rate in the 15 women with fertility desire was as high as 87%. The pregnancy terminated in abortion in 3 (23%) cases, preterm birth in 2 (15%), and term birth in 8 (62%), with an overall live birth rate of 77% (95% confidence interval: 60%, 94%) after surgery. A final decision about managing labor in such rare cases of OHVIRA syndrome (vaginal vs. cesarean delivery) is difficult because of lack of guidelines.^[15]

A retrospective long-term follow-up study was done by Zhu *et al.*, including 79 patients diagnosed with OHVIRA syndrome.^[41] There were 52 pregnancies among 28 (85%) of the 33 women who wished to conceive. Pregnancy occurred in the uterus ipsilateral to the hemivaginal septum in 19 (37%) cases, and in the uterus contralateral to the hemivaginal septum in 33 (64%) cases. Eight women had separate pregnancies in each of the bilateral uteri. There were no pathologic pregnancies or pregnancy complications. Excellent outcomes and fertility were found in those who had full resection of the vaginal septum.

Fertility in women with uterus didelphys was not found to be notably impaired, especially with early treatment, as found by Heinonen.^[42] In this study, multiple causes of infertility were found and included anovulatory cycles, endometriosis, male fertility factor, and secondary infertility after tubal pregnancy. Hence, the incidence of primary infertility was not significantly increased in women with uterus didelphys, and an uneventful pregnancy course was common, with a 21% rate of miscarriage, with only three miscarriages occurring during the second trimester. Moreover, uterus didelphys was found to be rarely associated with recurrent abortions as only 2 (6%) patients had three recurrent miscarriages and ectopic pregnancy occurred only once. A higher number of right-sided pregnancies were noted: 54 (76%) out of the 71 pregnancies. Four had pregnancies in the contralateral normal uterus, one in the ipsilateral affected uterus, and one patient had pregnancies alternately in both hemiuteri. Concomitant pregnancy in both hemiuteri did not occur. Two sets of twin pregnancy occurred in two cases, both in the same hemiuterine cavity.^[42] The incidence of fetal malpresentation was significant, thus a higher frequency delivery by cesarean sections was necessary. Preterm delivery occurred in 24% of the 55 deliveries, but only 7% of all deliveries were

associated with a very low birth weight infant. Perinatal mortality occurred in 5.3% of the cases, there were two cases of intrauterine fetal death, and one neonate died after 48 h. The prognosis of pregnancy is comparatively acceptable, while prematurity and intrauterine fetal growth restriction indicate the need for meticulous prenatal care.^[42]

Early diagnosis and treatment of OHVIRA syndrome is essential for preserving fertility as accumulating evidence showed that women treated before conception had a lower abortion rate than those without treatment, but premature delivery was more common in patients presenting for infertility.^[43] Cappello *et al.* reported a case of a 28-year-old nulliparous woman diagnosed during childhood with OHVIRA syndrome associated with ectrodactyly of the right foot and with a history of abdominal left hemi-hysterectomy, ipsilateral salpingectomy, and vaginal reconstruction during her adolescent years.^[44] She already had two abortions occurring at the 7th and 12th weeks, respectively, and presented at 33 weeks and 5 days of gestational for premature rupture of membranes and uterine contractions. The patient was then delivered by cesarean section because of breech presentation and preterm labor.^[44]

In other cases, OHVIRA was diagnosed during an infertility workup. A 27-year-old female with primary infertility, complaining of a dull aching pain in the lower abdomen found to have two unfused uterine cornua with fluid collection within the right endometrial cavity on ultrasound. She underwent drainage of the uterine contents leading to a gradual relief of pain in the following months. Three months later, the patient spontaneously conceived.^[45]

Several cases reported in literature showed that diagnosis of OHVIRA syndrome could be delayed until pregnancy or in postpartum thus had no effect on fertility. Mirković *et al.* reported a case of a primiparous woman at 41-week and 2-day gestational age who had rupture of dextralateral obstructed hemivagina during vaginal delivery.^[46] The patient was known to have right kidney agenesis since childhood and has undergone a laparoscopy and hysteroscopy procedure for large uterine septum and primary infertility. Spontaneous pregnancy was achieved promptly after the procedure.^[12] Another interesting case was reported by Agarwal *et al.*: in this case, OHVIRA syndrome was diagnosed 9 months post cesarean section after she presented with vaginal heaviness and abdominal pain of 8-month duration.^[47] Patients with OHVIRA syndrome may also present with complaints other than infertility. A retrospective cohort analysis included 45 patients affected by OHVIRA syndrome, from July 2004 to June 2015.^[4] Six (14.0%) patients required surgery at a median age of 31.2 months for the following reasons: recurrent urinary tract infection, uncontrolled vaginal

distention compressing adjacent organs, urinary incontinence, and intractable abdominal pain.

CONCLUSIONS

OVHIRA is a complex syndrome requiring accurate diagnosis and appropriate management. According to the available pieces of evidence collected in this systematic review, minimally invasive approach is a feasible option in most of the cases. Considering the acceptable fertility and obstetric outcomes after surgical management, fertility-sparing surgery should be the first-line option in reproductive-age women.

Data statement

This article is a systematic review and does not contain any unpublished data collected/analyzed by the authors.

Financial support and sponsorship

Nil.

Conflicts of interest

There are no conflicts of interest.

REFERENCES

- Albulescu DM, Ceaușescu AE, Sas LM, Comănescu MC, Constantin C, Tudorache Ș. The Herlyn-Werner-Wunderlich triad (OHVIRA syndrome) with good pregnancy outcome – Two cases and literature review. *Rom J Morphol Embryol* 2018;59:1253-62.
- Friedman MA, Aguilar L, Heyward Q, Wheeler C, Caldamone A. Screening for müllerian anomalies in patients with unilateral renal agenesis: Leveraging early detection to prevent complications. *J Pediatr Urol* 2018;14:144-9.
- Gungor Ugurlucan F, Dural O, Yasa C, Kirpinar G, Akhan SE. Diagnosis, management, and outcome of obstructed hemivagina and ipsilateral renal agenesis (OHVIRA syndrome): Is there a correlation between MRI findings and outcome? *Clin Imaging* 2020;59:172-8.
- Kudela G, Wiernik A, Drosdzol-Cop A, Machnikowska-Sokolowska M, Gawlik A, Hyla-Klekot L, *et al.* Multiple variants of obstructed hemivagina and ipsilateral renal anomaly (OHVIRA) syndrome – One clinical center case series and the systematic review of 734 cases. *J Pediatr Urol* 2021;17:653.e1-653.e9.
- Tan YG, Lakshmi NK, Yap TL, Sadhana N, Ong CCP. Preventing the O in OHVIRA (Obstructed Hemivagina Ipsilateral Renal Agnesis): Early diagnosis and management of asymptomatic Herlyn-Werner-Wunderlich syndrome. *J Pediatr Surg* 2020;55:1377-80.
- Han JH, Lee YS, Im YJ, Kim SW, Lee MJ, Han SW. Clinical implications of Obstructed Hemivagina and Ipsilateral Renal Anomaly (OHVIRA) syndrome in the prepubertal age group. *PLoS One* 2016;11:e0166776.
- Isono W, Tsuchiya A, Honda M, Saito A, Tsuchiya H, Matsuyama R, *et al.* Successful management of a noncommunicating rudimentary uterine horn pregnancy by laparoscopic surgery: A case report and literature review. *Gynecol Minim Invasive Ther* 2022;11:7-16.
- Khoiwal K, Singh M, Agarwal A, Chaturvedi J. The path of birth is not always normal: A case report of cervicovaginal agenesis. *Gynecol Minim Invasive Ther* 2021;10:247-51.
- Lee CL, Lee JM, Lin CH, Chen YP, Huang CY, Lee PS, *et al.* Novel neovaginoplasty using rudimentary uterine horn serosa and pelvic peritoneum as a graft in müllerian anomalies with vaginal agenesis. *J Minim Invasive Gynecol* 2019;26:657-66.
- Santos XM, Dietrich JE. Obstructed hemivagina with ipsilateral renal anomaly. *J Pediatr Adolesc Gynecol* 2016;29:7-10.
- Kapczuk K, Friebe Z, Iwaniec K, Kędzia W. Obstructive müllerian anomalies in menstruating adolescent girls: A report of 22 cases. *J Pediatr Adolesc Gynecol* 2018;31:252-7.
- Sabdia S, Sutton B, Kimble RM. The obstructed hemivagina, ipsilateral renal anomaly, and uterine didelphys triad and the subsequent manifestation of cervical aplasia. *J Pediatr Adolesc Gynecol* 2014;27:375-8.
- Smith NA, Laufer MR. Obstructed Hemivagina and Ipsilateral Renal Anomaly (OHVIRA) syndrome: Management and follow-up. *Fertil Steril* 2007;87:918-22.
- Dhar H, Razek YA, Hamdi I. Uterus didelphys with obstructed right hemivagina, ipsilateral renal agenesis and right pyocolpos: A case report. *Oman Med J* 2011;26:447-50.
- Zivković K, Prka M, Zivković N, Bucko A, Habek D. Unusual case of OHVIRA syndrome with a single uterus, unrecognized before labor and followed by an intrapartur rupture of obstructed hemivagina. *Arch Gynecol Obstet* 2014;290:855-8.
- Kriplani A, Dalal V, Kachhawa G, Mahey R, Yadav V, Kriplani I. Minimally invasive endoscopic approach for management of OHVIRA syndrome. *J Obstet Gynaecol India* 2019;69:350-5.
- Kimble RM, Kimble RM. The obstructed hemivagina, ipsilateral renal anomaly, uterus didelphys triad. *Fertil Steril* 2010;93:e15.
- Gündüz R, Ağaçayak E, Evsen MS. OHVIRA syndrome presenting with acute abdomen findings treated with minimally invasive method: Three case reports. *Acta Chir Belg* 2022;122:275-8.
- Mandava A, Prabhakar RR, Smitha S. OHVIRA syndrome (Obstructed Hemivagina and Ipsilateral Renal Anomaly) with uterus didelphys, an unusual presentation. *J Pediatr Adolesc Gynecol* 2012;25:e23-5.
- Tanaka YO, Kurosaki Y, Kobayashi T, Eguchi N, Mori K, Satoh Y, *et al.* Uterus didelphys associated with obstructed hemivagina and ipsilateral renal agenesis: MR findings in seven cases. *Abdom Imaging* 1998;23:437-41.
- Sleiman Z, Zreik T, Bitar R, Sheab R, Al Bederi A, Tanos V. Uncommon presentations of an uncommon entity: OHVIRA syndrome with hematosalpinx and pyocolpos. *Facts Views Vis Obgyn* 2017;9:167-70.
- Kozłowski M, Nowak K, Boboryko D, Kwiatkowski S, Cymbaluk-Płoska A. Herlyn-Werner-Wunderlich syndrome: Comparison of two cases. *Int J Environ Res Public Health* 2020;17:7173.
- Cox D, Ching BH. Herlyn-Werner-Wunderlich syndrome: A rare presentation with pyocolpos. *J Radiol Case Rep* 2012;6:9-15.
- Salastekar N, Coelho M, Majmudar A, Gupta S. Herlyn-Werner-Wunderlich syndrome: A rare cause of abdominal pain and dyspareunia. *Radiol Case Rep* 2019;14:1297-300.
- Yakıştıran B, Şükür YE, Turgay B, Atabekoğlu C. True management of Obstructed Hemi-Vagina and Ipsilateral Renal Anomaly syndrome. *Turk J Obstet Gynecol* 2016;13:208-11.
- Yalçın I, Pabuçcu E, Kahraman K, Sönmez M. Mini-Laparotomic Colpotomy for a cervicovaginal leiomyoma: Preservation of hymenal integrity. *Int J Reprod Biomed* 2016;14:217-20.
- Kim TE, Lee GH, Choi YM, Jee BC, Ku SY, Suh CS, *et al.* Hysteroscopic resection of the vaginal septum in uterus didelphys with obstructed hemivagina: A case report. *J Korean Med Sci* 2007;22:766-9.
- Malarazhagan V, Veerasingham M, Sivanesan K. Right-sided Obstructed Hemivagina Ipsilateral Renal Agnesis (OHVIRA): A case report. *Case Rep Womens Health* 2020;26:e00185.
- Gungor Ugurlucan F, Bastu E, Gulsen G, Kurek Eken M, Akhan SE. OHVIRA syndrome presenting with acute abdomen: A case report and review of the literature. *Clin Imaging* 2014;38:357-9.
- Tug N, Sargin MA, Çelik A, Alp T, Yenidede I. Treatment of virgin OHVIRA syndrome with haematometocolpos by complete incision of vaginal septum without hymenotomy. *J Clin Diagn Res* 2015;9:D15-6.
- Ludwin A, Ludwin I, Bhagavath B, Martins WP, Lindheim SR. Virginity-sparing management of blind hemivagina in obstructed hemivagina and ipsilateral renal anomaly syndrome. *Fertil Steril* 2018;110:976-8.
- Sleiman Z, Wehbe GS, Rassy EE, Zreik T, Bitar R, Samaha M, *et al.* A novel surgical intervention for an uncommon entity: Laparoscopy-Assisted resection of a vaginal septum in obstructed hemivagina and ipsilateral renal anomaly syndrome. *J Laparoendosc Adv Surg Tech A* 2019;29:714-6.
- Boyrac G, Karalok A, Turan T, Özgül N. Herlyn-Werner-Wunderlich syndrome; laparoscopic treatment of obstructing longitudinal vaginal septum in patients with hematocolpos – A different technique for virgin

- patients J Turk Ger Gynecol Assoc 2020;21:303-4.
34. Hee CY. MRI findings of Obstructed Hemivagina and Ipsilateral Renal Agenesis (OHVIRA syndrome) with a blind megareuter: Case report. Korea Sci 2015;19:196.
 35. Huseyin K, Lale TS, Burak Y, Tolga K, Pinar K, Kerem SD. A case of obstructed hemivagina and ipsilateral renal anomaly syndrome complicated with pyometra: Tips and tricks for laparoscopic hemihysterectomy. Fertil Steril 2019;112:177-9.
 36. Gulavi E, Kyende Mutiso S, Mariara Muriuki C, Mukaindo Mwaniki A. Successful pregnancy outcome after open Strassman metroplasty for bicornuate uterus. Case Rep Obstet Gynecol 2018;2018:4579736.
 37. Nabeshima H, Nishimoto M, Shiga N, Utsunomiya H, Yaegashi N. Laparoscopic Strassman metroplasty in a postmenarcheal adolescent girl with Herlyn-Werner-Wunderlich müllerian anomaly variant, obstructed noncommunicating didelphic uterus without gartner duct pseudocyst. J Minim Invasive Gynecol 2013;20:255-8.
 38. Zhang C, Wang X, Jiang H, Hou L, Zou L. Placenta percreta after Strassman metroplasty of complete bicornuate uterus: A case report. BMC Pregnancy Childbirth 2021;21:95.
 39. Tanitame K, Tanitame N, Urayama S, Ohtsu K. Congenital anomalies causing hemato/hydrocolpos: Imaging findings, treatments, and outcomes. Jpn J Radiol 2021;39:733-40.
 40. Candiani GB, Fedele L, Candiani M. Double uterus, blind hemivagina, and ipsilateral renal agenesis: 36 cases and long-term follow-up. Obstet Gynecol 1997;90:26-32.
 41. Zhu L, Chen N, Tong JL, Wang W, Zhang L, Lang JH. New classification of Herlyn-Werner-Wunderlich syndrome. Chin Med J (Engl) 2015;128:222-5.
 42. Heinonen PK. Clinical implications of the didelphic uterus: Long-term follow-up of 49 cases. Eur J Obstet Gynecol Reprod Biol 2000;91:183-90.
 43. Moutos DM, Damewood MD, Schlaff WD, Rock JA. A comparison of the reproductive outcome between women with a unicornuate uterus and women with a didelphic uterus. Fertil Steril 1992;58:88-93.
 44. Cappello S, Piccolo E, Cucinelli F, Casadei L, Piccione E, Salerno MG. Successful preterm pregnancy in a rare variation of Herlyn-Werner-Wunderlich syndrome: A case report. BMC Pregnancy Childbirth 2018;18:498.
 45. Altchek A, Paciuc J. Successful pregnancy following surgery in the obstructed uterus in a uterus didelphys with unilateral distal vaginal agenesis and ipsilateral renal agenesis: Case report and literature review. J Pediatr Adolesc Gynecol 2009;22:e159-62.
 46. Mirković L, Ljubić A, Janjić T, Milićević S, Sparić R, Jeremić K, *et al.* Term pregnancy after minimally invasive surgical treatment of Herlyn-Werner-Wunderlich syndrome. Srp Arh Celok Lek 2013;141:524-7.
 47. Agarwal A, Agarwal S, Sharma A. OHVIRA syndrome in post-cesarean period: An exclusive clinical scenario managed by two-staged operative procedure. Taiwan J Obstet Gynecol 2018;57:613-5.