

# O-RADS MRI SCORE: An Essential First-Step Tool for the Characterization of Adnexal Masses

I. Thomassin-Naggara, MD, PhD,<sup>1,2\*</sup> Y. Dabi, MD,<sup>3</sup> M. Florin, MD,<sup>1</sup> A. Saltel-Fulero, MD,<sup>4</sup>  
L. Manganaro, MD,<sup>5</sup> M. Bazot, MD,<sup>1</sup> and L. Razakamanantsoa, MD<sup>1,2</sup>

The ovarian-adnexal reporting and data system on magnetic resonance imaging (O-RADS MRI) score is now a well-established tool to characterize pelvic gynecological masses based on their likelihood of malignancy. The main added value of O-RADS MRI over O-RADS US is to correctly reclassify lesions that were considered suspicious on US as benign on MRI. The crucial issue when characterizing an adnexal mass is to determine the presence/absence of solid tissue and thus need to perform gadolinium injection. O-RADS MR score was built on a multivariate analysis and must be applied as a step-by-step analysis: 1) Is the mass an adnexal mass? 2) Is there an associated peritoneal carcinomatosis? 3) Is there any significant amount of fatty content? 4) Is there any wall enhancement? 5) Is there any internal enhancement? 6) When an internal enhancement is detected, does the internal enhancement correspond to solid tissue or not? 7) Is the solid tissue malignant? With its high value to distinguish benign from malignant adnexal masses and its high reproducibility, the O-RADS MRI score could be a valuable tool for timely referral of a patient to an expert center for the treatment of ovarian cancers. Finally, to make a precise diagnosis allowing optimal personalized treatment, the radiologist in gynecological imaging will combine the O-RADS MRI score with many other clinical, biological, and other MR criteria to suggest a pathological hypothesis.

**Level of Evidence:** 5

**Technical Efficacy Stage:** 3.

J. MAGN. RESON. IMAGING 2023.

The ovarian-adnexal reporting and data system on magnetic resonance imaging (O-RADS MRI) score is now a well-established tool to characterize pelvic gynecological masses based on their likelihood of malignancy.<sup>1,2</sup> The complexity of managing adnexal masses lies in avoiding underdiagnosis of malignant lesions—implying a bad prognosis and urgent treatment—and overdiagnosis of benign lesions leading to unnecessary surgery and compromising fertility.<sup>3</sup> The prevalence of malignancy in women undergoing ovarian surgery is quite low, especially if surgery is based purely on ultrasonography (US) results,<sup>4</sup> and the risk of infertility after surgery for benign ovarian cysts has been largely demonstrated.<sup>5</sup> In this setting, the first-line technique remains

transvaginal US, which correctly classifies between 70% and 80% of all adnexal masses depending on the experience of ultrasonographer.<sup>6,7</sup> Many scores have been developed to standardize the management of adnexal masses.<sup>8</sup> In 2018, the American College of Radiology in partnership with the International Ovarian Tumor Analysis group created the O-RADS US score.<sup>9,10</sup> This score classifies adnexal masses into five categories: O-RADS US 1 or 2 indicates a positive predictive value (PPV) lower than 1%; O-RADS US 3 a PPV between 1% and 10%; O-RADS US 4 a PPV between 10% and 50%; and O-RADS US 5 a PPV >50%.<sup>11</sup> Accordingly, MRI is recommended for masses rated O-RADS 3 and 4, and further studies are ongoing to determine the benefit of MRI for

View this article online at [wileyonlinelibrary.com](http://wileyonlinelibrary.com). DOI: 10.1002/jmri.28947

Received Jun 9, 2023, Accepted for publication Jul 27, 2023.

\*Address reprint requests to: I.T.-N., Service IRIS, Hospital Tenon, 4 rue de la Chine, 75020, Paris, France. E-mail: [Isabelle.thomassin@aphp.fr](mailto:Isabelle.thomassin@aphp.fr)

From the <sup>1</sup>Assistante Publique des Hôpitaux de Paris, Department of Radiology Imaging and Interventional Radiology (IRIS), Tenon Hospital, APHP, Sorbonne University, 75005, Paris, Paris, France; <sup>2</sup>Saint-Antoine Research Cancer Center, Sorbonne University, Paris, France; <sup>3</sup>Department of Obstetrics and Reproductive Medicine, Tenon Hospital, Paris, France; <sup>4</sup>Department of Radiology, Georges-Pompidou European Hospital, APHP, Paris, France; and <sup>5</sup>University Sapienza, Rome, Italy

This is an open access article under the terms of the [Creative Commons Attribution](https://creativecommons.org/licenses/by/4.0/) License, which permits use, distribution and reproduction in any medium, provided the original work is properly cited.

O-RADS MR 5 that exhibits a PPV of around 50% precluding fertility preservation.<sup>10</sup> In addition, if the lesion is a unilocular cyst measuring more than 10 cm, solid tissue located far from the probe may be missed.<sup>12</sup> From our experience in a referral center for women’s pelvic imaging, MRI is also useful for non-simple unilocular cysts or multilocular cysts measuring more 6 cm and should be recommended in this setting. The main added value of O-RADS MRI over O-RADS US is to correctly reclassify lesions that were considered suspicious on US as benign on MRI.<sup>7,13</sup>

## How to Use the O-RADS MRI Score in Clinical Practice

### Preparation Step

The O-RADS MRI score serves to standardize the MRI protocol and MRI terminology.<sup>14</sup> The crucial issue when characterizing an adnexal mass is to determine the presence/absence of solid tissue (Fig. 1). According to the MRI lexicon,<sup>14</sup> a solid tissue enhances after gadolinium injection and corresponds to the following elements: irregular septa, papillary projection, mural nodule, or purely solid tumor. This distinction is particularly important because most errors in the application of the O-RADS MRI score are attributed to misdiagnosis of solid tissue.<sup>15</sup> Various structures that do not enhance after gadolinium injection—such as fibrinous septa, clots, or debris—may also be mistaken with solid tissue if no gadolinium injection is performed. Thus, learning the definitions provided in the O-RADS MRI lexicon, along with an

in-depth understanding of MRI sequences, their selection, relevance, and implementation, are crucial steps for applying the score.

### MRI Protocol

Adnexal masses contain solid and cystic components, which must be analyzed in a multiparametric way to apply the O-RADS MRI score.

To analyze the solid component, it is crucial to detect solid tissue, identified as an enhanced structure.<sup>14</sup> Thus, as stated above, a conventional gadolinium injection must be performed. A noncontrast score has been reported to have good accuracy to predict malignancy in a nonselected population of adnexal masses.<sup>16</sup> However, MRI must be performed as a second-line technique on a selected population of complex US masses with the aim to reclassify these lesions as benign. Moreover, several studies have demonstrated the impact of dynamic contrast-enhanced (DCE) MRI analysis on diagnostic performance with a significant increase in correct diagnoses (+25%) compared with the conventional injection.<sup>17</sup> If a DCE MRI sequence cannot be acquired or correctly analyzed, the alternative is to perform one acquisition 30–40 sec after the gadolinium injection. This acquisition may help to recognize an O-RADS MRI 5 tumor but remains less accurate than an acquisition with a DCE MRI sequence, that is, fewer benign tumors are correctly reclassified.<sup>18</sup> Several types of solid tissue, such as irregular septa or papillary projection, are really small. Thus, T2-weighted (T2W) thin-section MRI sequences after gadolinium injection are very useful for detecting and characterizing the lesion.<sup>19</sup>

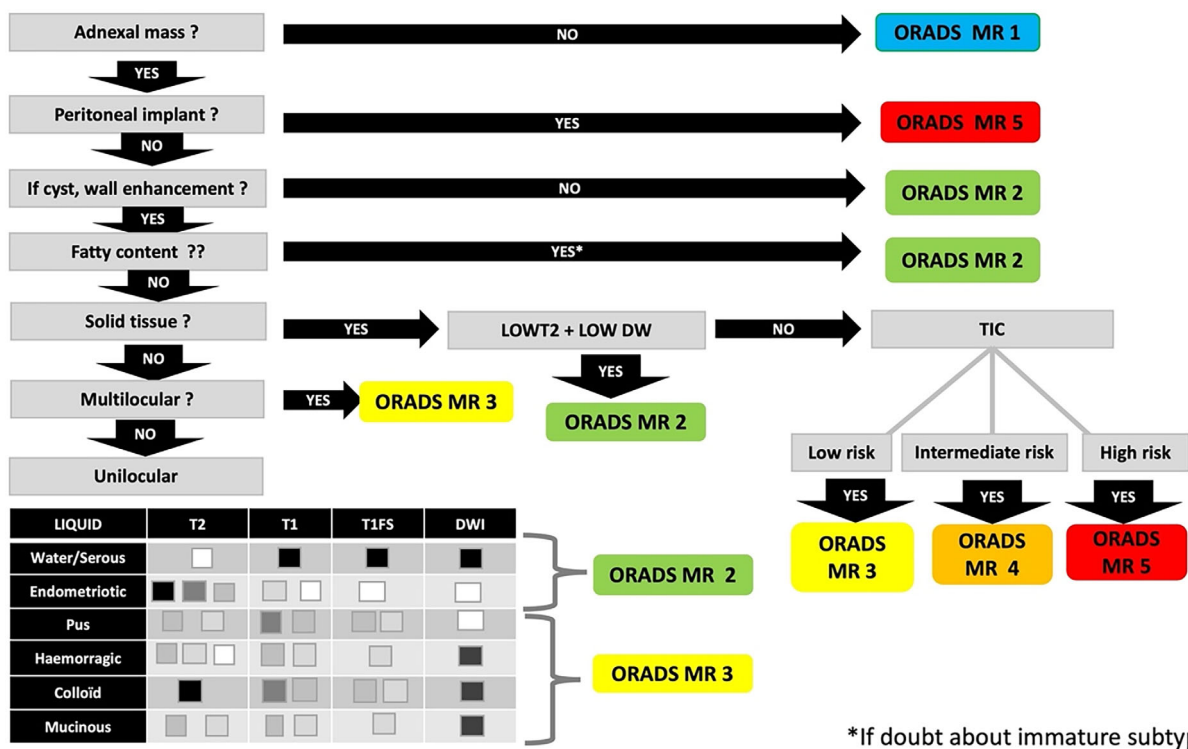


FIGURE 1: O-RADS MRI score: The seven steps.

TABLE 1. MRI Protocol

MRI sequences	Parameters	Main objectives
Sag T2W	Non-fat saturation (Non-FS)	Anatomy and morphology of the uterus and its relationship to the adnexal mass
	Fov: 24 cm	
	Location: From right/left hip to the contralateral one Thickness $\leq 6$ mm	Origin
Ax T2W non-FS	Non-fat saturation (Non-FS)	Origin/cystic component/ solid tissue/ hydronephrosis/peritoneal deposits and retroperitoneal lymph nodes
	Fov: 30 cm	
	Location: From kidney to symphysis (lumbo pelvic) Thickness: 5 mm/1.0 spacing	
Ax T2W thin slices	Thickness: contiguous 3 mm slices or 3DT2	Solid tissue (useful to detect papillary projection)
Ax T1W with/ without Fat sat <sup>a</sup>	Exact same Location as Ax T2 non-FS	Cystic component
	Fov: 30 cm	
	2D: Thickness 5 mm/1.0 spacing or 3D: Thickness 3 mm/0.0 spacing (better choice that allows to reformat)	
Ax DW	Exact same Location as Ax T2 non-FS	Solid tissue/cystic component
	<i>b</i> value: 1000–1400 with black urine and intermediate ovaries in premenopausal women—ADC map	
	Thickness: 6 mm/0.0 spacing or 5 mm/1.0 spacing	
Ax DCE MR sequence	3D isotropic EG T1W	Solid tissue
	Temporal resolution <15 sec	
	Total duration after injection: 4 minutes	
	Spatial resolution and slice thickness = 3 mm/0.0 sp	
	Size of box >15 cm	
	Loc per slab >50	
	Contrast injection start at 30–45 sec	
The injection should be done using a pump-injector with a rate of 2 mL/sec, followed by a 20 mL saline flush of the tubing		
Ax T1W with gadolinium injection <sup>a</sup>	Copy Ax T1 FS without GADO (to allow subtraction)	Solid tissue

General recommendations: 1,5 T or 3 T/body array/decubitus. To limit abdominal wall movement artifact: the patient is instructed to breathe using her chest wall, minimizing the movement of the abdominal wall during respiration, the coil is firmly strapped across the pelvis and abdominal contention. To limit bowel movement artifact: I.V. antispasmodic just before the examination + fasting 4–6 hours before the scan.

<sup>a</sup>Same sequence for subtraction or dixon acquisition.


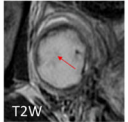


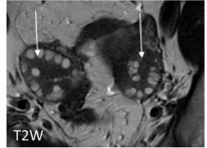

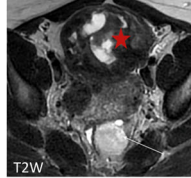

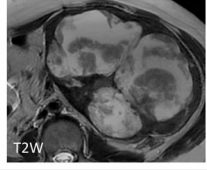



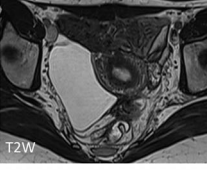
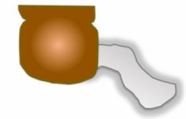
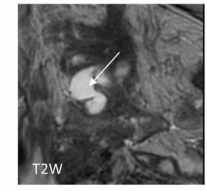

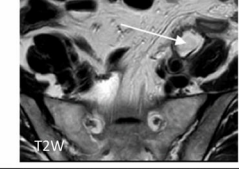

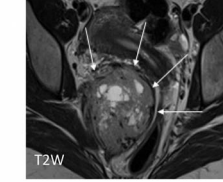
Ovarian functional disease	Luteal cyst (Unilocular without solid tissue) 	 T2W	 T1Wgadi	No internal enhancement Fibrous septation (red arrow) Heterogeneous Strong annular thick enhancement (white arrow)	
	Hyperstimulation (Multilocular without solid tissue) 	 T2W			Bilateral Multiple follicles (no loculus) Ovarian edema
Uterus	Cystic leiomyoma (Unilocular or multilocular without solid tissue) 	 T2W		Claw sign Thick wall / septa (red star) Normal ipsilateral ovary (white arrow)	
	Myxoid leiomyoma (large ligament) 	 T2W			Claw sign Thick wall / septa Normal ipsilateral ovary
	Subserosal leiomyoma 	 T2W			Claw sign Thick wall / septa Normal ipsilateral ovary
Peritoneal	Pseudo-peritoneal cyst (Unilocular or multilocular without solid tissue) 	 T2W		Quadrangular No wall enhancement	
Digestive	Appendicular Mucocele (Unilocular or multilocular without solid tissue) 	 T2W		Tubulate distended appendice (white arrow) Normal ipsilateral ovary Right iliac fossa	
Lymph node	Lymphocele (unilocular without solid tissue) 	 T2W		Retro/subperitoenal space	
Nerve	Schwannoma 	 T2W		Retroperitoneal space located over parietal fascia (white arrows)	

FIGURE 2: Differential diagnosis (O-RADS MRI 1).

Analysis of diffusion-weighted (DW) signals of solid tissue has also been shown to significantly increase the number of correct diagnoses (+15%).<sup>17</sup>

To analyze the cystic component, different signal intensities need to be combined to identify the wide variety of liquids an adnexal mass may contain.<sup>20</sup> Some liquids are easy to

recognize combining only T2W, T1W, and T1W fat-suppressed (FS) sequences: 1) serous (high T2W, low T1W); 2) fatty (high T1W, low T1WFS); 3) endometriotic (very high T1W, low T2W); 4) colloid (very low T2W, moderately high T1W). Other liquids appear in moderate high T1W and must be combined with T2W and DW signal: 1) mucinous (intermediate T2W, low DW); 2) pus (intermediate T2W, very high DW signal); and 3) blood (all T2W and T1W signal, annular high DW signal).<sup>20,21</sup>

Finally, 8.9% of the adnexal masses identified on US were finally classified as extra adnexal masses on surgery.<sup>1</sup> Thus, the role of the radiologist is primarily to determine the origin of any pelvic mass<sup>22</sup> and the need for T2W sequence without FS in a sagittal and axial plan, ideally performed as a lumbopelvic acquisition. The following criteria confirm a mass as being of adnexal origin: 1) Normal ipsilateral ovary (nonovarian mass); 2) Normal ovarian parenchyma with a crescent sign (ovarian origin); 3) Ovarian pedicle connected to the pelvic mass (adnexal origin).<sup>23</sup> The optimal protocol is given in Table 1.<sup>24</sup>

Finally, it is important to note that the O-RADS MRI score is not suitable in specific acute situations that alter the signal independently of the mass type, such as adnexal torsion or ectopic pregnancy.

### O-RADS MRI Score: MRI Analysis Step

As mentioned above, the main added value of the O-RADS MR score is to reclassify certain benign adnexal masses that were initially considered indeterminate or suspicious on US (rated O-RADS US 3, 4, or 5).<sup>25</sup> The O-RADS MRI score was built from a multivariate analysis of the most predictive features of malignancy.<sup>26</sup> According to external validation EURAD study,<sup>1</sup> the most predictive features were: 1) purely fatty mass (positive likelihood ratio (PLR) = 0); 2) absence of wall enhancement (PLR = 0.01<sub>(95%CI = 0–0.09)</sub>); 3) purely cystic mass (PLR = 0.01<sub>(95%CI = 0–0.08)</sub>); 4) purely endometriotic mass (PLR = 0.02<sub>(95%CI = 0–0.17)</sub>); 5) absence of solid tissue (PLR = 0.04<sub>(95%CI = 0.02–0.08)</sub>); 6) dark T2W and DW signal of solid tissue (PLR = 0.09<sub>(95%CI = 0.02–0.35)</sub>); 7) bilocular or multilocular mass without solid tissue (PLR = 0.12<sub>(95%CI = 0.05–0.29)</sub>); 8) time-signal intensity curve type 1 (PLR = 0.32<sub>(95%CI = 0.18–0.56)</sub>), and the most predictive feature for malignancy, time-signal intensity curve type 3 (PLR = 26.3<sub>(95%CI = 17.4–39.7)</sub>); 9) peritoneal carcinomatosis (PLR = 77.63<sub>(95%CI = 28.65–210.37)</sub>).<sup>26</sup> As the multivariate analysis was a recursive partitioning analysis,<sup>26</sup> these criteria must be analyzed in the following order (Fig. 1)

- First step: Is the mass an adnexal mass? If no, the lesion is rated O-RADS MRI 1 and the analysis will be conducted subjectively.

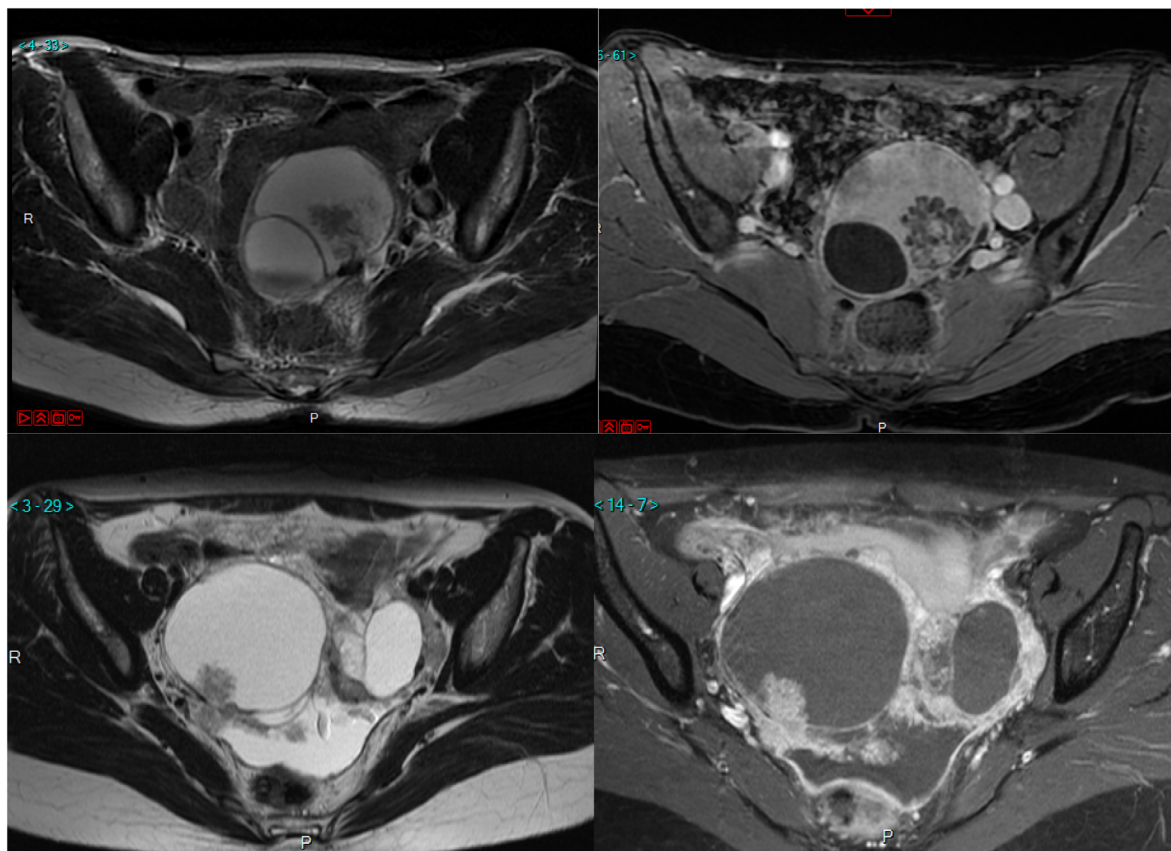


FIGURE 3: A group of papillary projections/A mural nodule. A group of papillary projections showing a central vessel and acute angle with the cystic wall (a,b). In contrast, the mural nodule has a diffuse enhancement with an obtuse angle with the cystic wall (c,d). (a) T2W axial sequence. (b) T1W gadolinium. (c) T2W axial sequence. (d) T1W gadolinium.

This group includes any functional ovarian lesion and all extra adnexal lesions as well as any functional cysts (Fig. 2).

- Second step: Is there an associated peritoneal carcinomatosis? If yes, the lesion is rated O-RADS MRI 5. The PPV of malignancy

is 90% in this category with more than 90% of invasive malignant primitive tumors.<sup>1</sup> The PPV is “only” 90% as some pelvic inflammatory disease (such as tuberculosis) may mimic peritoneal carcinomatosis with thickened nodular peritoneal implants.

**TABLE 2. O-RADS MR Score**

O-RADS	Description
0	Incomplete exam
1. Normal ovaries	No ovarian lesion
	Physiological: <ul style="list-style-type: none"> <li>• Follicle</li> <li>• Corpus luteum</li> </ul>
2. Almost certainly benign <0,5%	Cyst: Unilocular—simple or endometriotic fluid <ul style="list-style-type: none"> <li>• Thin, smooth wall with enhancement</li> <li>• No solid tissue</li> </ul>
	Cyst: Unilocular/multilocular—any type of fluid <ul style="list-style-type: none"> <li>• No wall enhancement</li> <li>• No solid tissue</li> </ul>
	Cyst: Unilocular/multilocular—lipid content <ul style="list-style-type: none"> <li>• No solid tissue</li> </ul>
	Lesions with Solid tissue: homogeneously hypointense on T2 and DWI (dark/dark)
	Para ovarian cyst—simple fluid <ul style="list-style-type: none"> <li>• Thin, smooth wall with enhancement</li> <li>• No solid tissue</li> </ul>
	Dilated fallopian tube simple fluid <ul style="list-style-type: none"> <li>• Thin, smooth wall/endosalpingeal folds</li> <li>• No solid tissue</li> </ul>
3. Low risk <5%	Cyst: Unilocular—hemorrhagic mucinous or proteinaceous fluid <ul style="list-style-type: none"> <li>• Smooth enhancing wall</li> <li>• No solid tissue</li> </ul>
	Cyst: Multilocular—any type of fluid <ul style="list-style-type: none"> <li>• Smooth septae and enhanced wall</li> <li>• No solid tissue</li> </ul>
	Lesion with solid tissue (excluding T2dark/DWI dark) <ul style="list-style-type: none"> <li>• Low risk time intensity curve on DCE MRI</li> </ul>
	Dilated fallopian tube—non-simple fluid <ul style="list-style-type: none"> <li>• No solid tissue</li> </ul>
4. Intermediate risk 5%–90%	Lesion with solid tissue (excluding T2dark/DWI dark) <ul style="list-style-type: none"> <li>• Intermediate time intensity curve on DCE MRI</li> <li>• Enhancing &lt; or = myometrium at 30–40s on non-DCE MRI if TIC unavailable</li> </ul>
	Lesion with lipid content <ul style="list-style-type: none"> <li>• Large volume solid tissue</li> </ul>
5. High risk >90%	Lesion with solid tissue <ul style="list-style-type: none"> <li>• High risk time intensity curve on DCE MRI</li> <li>• Enhancing &gt; myometrium at 30–40s on non-DCE MRI</li> </ul>
	Obvious peritoneal, mesenteric, or omental nodularity or thickening

**TABLE 3. Additional MRI Criteria to Combine with O-RADS MRI to Make Pathological Hypothesis**

<b>General morphology</b>					
Unilocular without ST	Cyst without internal enhancement				
Multilocular without ST	Cyst with internal enhancement corresponding to regular septation				
Unilocular with ST	Cyst with papillary projections or mural nodule				
Multilocular with ST	Cyst with irregular septa, papillary projections, mural nodule				
Purely solid tumor	Solid tissue >80% of the tumor				
<b>Size</b>					
Size >10 cm					
<b>Type of solid component</b>					
Clots/debris/fibrin strand	Solid-appearing material within a cyst that does not enhance				
Rokitansky nodule, hair, calcification	Other components of a dermoid not considered solid tissue				
Endosalpingeal folds	Incomplete septations or short round projections, orthogonal to the length of the tube				
Thin regular septa	Enhanced solid component—non-solid tissue				
Thickened regular septa	Enhanced solid component—non-solid tissue				
Irregular septa/wall <sup>a</sup>	Enhancing linear strand that runs from one internal surface of the cyst to the contralateral side demonstrating an uneven margin				
Papillary projection <sup>a</sup>	Enhancing solid component arising from the inner or outer wall or septation of an adnexal lesion, with a branching architecture				
Mural nodule <sup>a</sup>	Enhancing solid component, measuring >3 mm, arising from the wall or septation of an adnexal lesion, with nodular appearance				
Mixed mass <sup>a</sup>	Enhancing component of an adnexal lesion that does not fit into previous ST categories				
Purely solid tumor <sup>a</sup>	Solid tissue >80% of the tumor				
<b>Shape/contour</b>					
Smooth/lobulated	Regular or even margin of a solid lesion or solid tissue				
Irregular	Uneven margin of a solid lesion or solid tissue				
Tubular	Substantially longer in one than in the two perpendicular dimensions				
<b>Type of cystic component</b>	<b>T2</b>	<b>T1</b>	<b>T1FS</b>	<b>DW</b>	<b>ADC</b>
Serous	High	Low	Low	Very low	High
Mucinous	Intermediate high	intermediate high	Intermediate high	Low	High
Pus	Intermediate	Intermediate high	Intermediate high	High	Low +++
Endometriotic	Low - Very low	High - Very high	High - Very high	Low	High
Colloid	Low	Intermediaite high	Intermediate high	Low	High
Blood	Variable	Variable	Variable	Halo	Variable
Fatty	Intermediate high	High	Low	Low	High
<b>Number of loculi of a cystic lesion</b>					
Unilocularity or Binocularity	Cyst without or with one septation				
Multilocularity	Cyst with at least two septations				
<b>Associated MR signs</b>					
Peritoneal thickening					

**TABLE 3. Continued**

Associated MR signs
Fatty infiltration
Endometrial thickening/adenomyosis
Colic/appendicular mass
Crescent sign normal ipsilateral POVS
Whirlpool sign
Deep pelvic endometriosis

<sup>a</sup>Solid tissue = ST.

- Third step: Is there any significant amount of fatty content? If yes, and in the absence of solid tissue, the lesion is rated O-RADS MRI 2. This category is mostly represented by mature cystic teratomas. The other adnexal masses which contain a significant amount of fatty content are other benign germinal tumors (struma ovarii). Immature teratomas are very rare tumors characterized by a small amount of fatty content, typically with a large amount of solid tissue in young women.<sup>27</sup>
- Fourth step: Is there any wall enhancement? If no, the cyst will be rated O-RADS MRI 2
- Fifth step: Is there any internal enhancement? If no, there is no solid tissue and the mass will be rated O-RADS MRI 2 or 3. In this group, any unilocular cyst with a serous or endometriotic cystic component, or any cyst without wall enhancement is rated O-RADS MRI 2. All other unilocular cysts (mucinous, colloid, pus, etc.) are rated O-RADS MRI 3.
- Sixth step: When an internal enhancement is detected, does the internal enhancement correspond to solid tissue or not? If no, internal enhancement can be due to thin or thick smooth septa in a bilocular or multilocular cyst without solid tissue or endosalpingeal folds in a pyosalpinx. These masses will be rated O-RADS MR 3.
- Seventh step: Is the solid tissue malignant? If internal enhancement corresponds to papillary projections, irregular septa or wall, a mural nodule, mixed, or purely solid mass, the mass contains a solid tissue that must be characterized with a T2W signal, DW signal, and time-signal intensity curve. If the solid tissue is homogeneously dark T2W and dark DW, the lesion has a PPV of malignancy close to zero<sup>28</sup> and can be rated O-RADS MRI 2. If the solid tissue is either intermediate T2W or high DW, the time-signal intensity curve will differentiate between O-RADS MRI 3 (low risk curve: curve with no plateau), O-RADS MRI 4 (intermediate risk curve: curve with a plateau without steeper enhancement than the myometrium), or O-RADS MRI 5 (high risk curve: curve steeper or earlier than the external adjacent myometrium).<sup>19</sup> If time-signal intensity

curves are not available, analysis of signal intensity after gadolinium injection at 30 sec can be an alternative.<sup>29</sup> A higher signal of solid tissue than external myometrium at 30 sec has the same accuracy as a high-risk time-signal intensity curve and the lesion will be classified O-RADS MRI 5.<sup>18</sup> In contrast, if the signal of the solid tissue is lower than that of the external myometrium, we are unfortunately not able to distinguish low from intermediate risk and all the lesions will be rated as O-RADS MRI 4. This analysis decreases the diagnostic accuracy of the O-RADS MRI score as fewer lesions are correctly reclassified as benign by MRI.

Some authors have recently suggested the value of the apparent diffusion coefficient (ADC) in characterizing the cystic and solid components of adnexal masses<sup>20,30</sup> and improving the score. While this parameter could be of interest, the main issue remains the lack of consensus regarding cut-off values and inter-reader consistency, essential factors prior to integration into the O-RADS MRI score.

We applied this analytical step-by-step analysis to build an O-RADS MRI calculator, which is available at <https://www.oradsmriscalc.com/>.

## O-RADS MRI Score: An Essential But Insufficient Tool

### *The Role of Nonexpert and Expert Radiologists*

The O-RADS MRI score integrates the ADNEX-MRI score,<sup>26</sup> which was built 10 years ago. The criteria used to compute the score were selected through a regressive partitioning multivariate analysis: that is, the algorithm selected the most significant criteria and excluded other, potentially relevant, criteria. This is in line with a radiologist's problem-solving approach to analyze and characterize tissue. Using only nine MRI criteria, the model can distinguish benign from malignant adnexal masses with a sensitivity and specificity of over 90%.<sup>1,2</sup> Hence, a radiologist who is familiar with the O-RADS lexicon and step-by-step MRI analysis




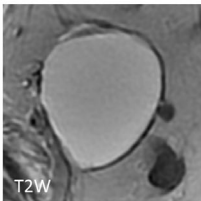
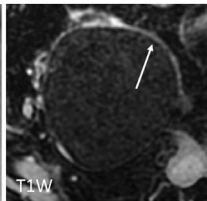
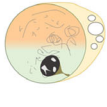
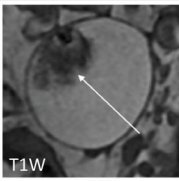


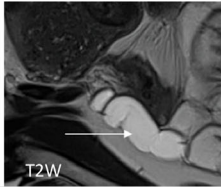
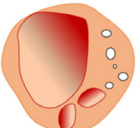
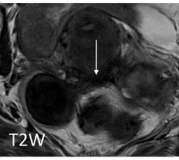
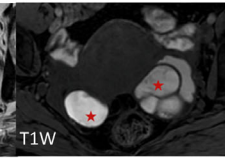
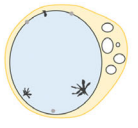
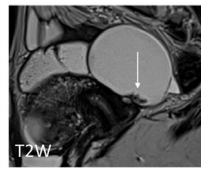
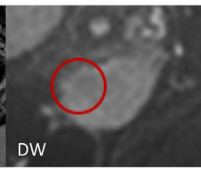

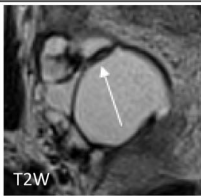
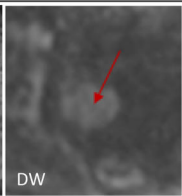
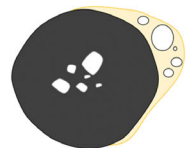
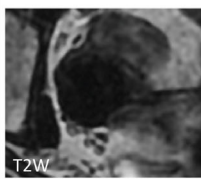

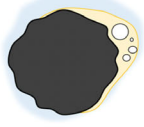
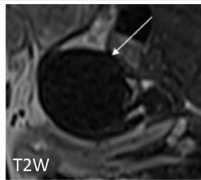
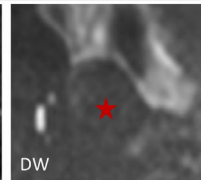
Unilocular without solid tissue				
EP	Benign serous cystadenoma 	 T2W	 T1W	Any age Cystic component: Serous Thin wall (white arrow) Crescent sign
GC	Mature cystic teratoma 	 T1W	 T1WFS	Unilateral Size <10cm Cystic component: Fatty (red star) Solid component: Rokitansky nodule (white arrow)
NL	Salpinx 	 T2W		Premenopausal Bilateral Tubulate (white arrow) Endosalpingeal folds
	Endometrioma 	 T2W	 T1W	Infertility Bilateral – No wall enhancement Cystic component: Endometriotic (red stars) Associated deep pelvic endometriosis (white arrow)
Unilocular with solid tissue (Solid tissue in dark T2W and dark DW)				
EP	Benign serous cystadenoma 	 T2W	 DW	Papillary projection / no mural nodule Endocystic papillary projection (white arrow) with low diffusion signal (red circle) Normal ovarian parenchyma
	Cystadenofibroma 	 T2W	 DW	Solid tissue (red arrow) Pre-menopausal woman Thick regular septa (white arrow) Loculi with different signal intensities Normal ovarian parenchyma
Purely solid				
EP	Brenner tumors 	 T2W	 DW	Unilateral darkT2-dark DW (red star) Central psammomas Associated with other epithelial tumors
SC	Fibrothecoma 	 T2W	 DW	Any age No symptoms darkT2-dark DW (red star) Lobulated margins (white arrow) Posterior shadowing at US Ascites

FIGURE 4: O-RADS MRI 2. EP = epithelial tumor; GC = germ cell tumors; SC = sec cord tumors; NL = nonneoplastic lesions; O = other.

will be able to correctly classify lesions with high agreement between nonexpert and expert readers (kappa values 0.784–0.904).<sup>1,26</sup>

For the expert radiologist, if a pathological hypothesis is made, the O-RADS MRI score could add a degree of certainty. For example, if an expert radiologist

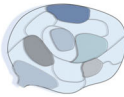
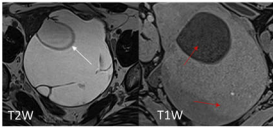



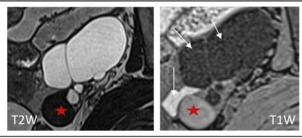
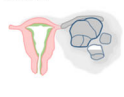
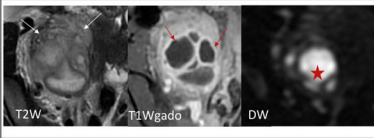
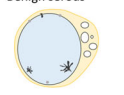
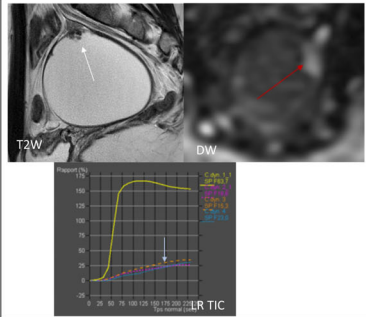

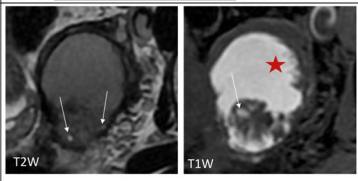

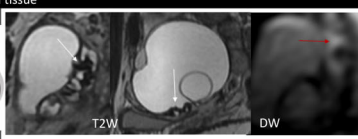



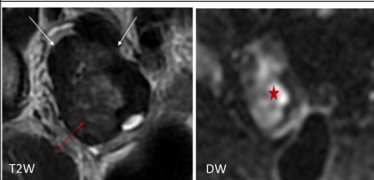
Multilocular without solid tissue			
EP	Mucinous cystadenoma 		Unilateral Thin ungrouped septations (white arrow) Multilocular Loculi with different signal intensities (red arrows)
	Cystadenofibroma 		Premenopausal woman Thick regular septa (white arrow) Loculi with different signal intensities POVS
GC	Struma ovarii 		Any age Multiple loculi with different signal (white arrows) Cystic content: Colloid, proteinaceous (red star)
NL	Tubo-ovarian abscess 		Inflammatory context Bilateral and tubulate Cystic component: Pus (red star) Fatty infiltration (white arrows) Thick wall (red arrows)
Unilocular with solid tissue			
EP	Benign serous 		Papillary projection (white arrow) / no mural nodule High DW signal (red arrow) Endocystic papillary projection Normal ovarian parenchyma
NL	Polypoid Endometrioma 		Cystic component: endometriotic (red star) Mural nodule with cystic degeneration (white arrows) Associated deep pelvic endometriosis
Multilocular with solid tissue			
EP	Cystadenofibroma 		Perimenopausal woman Thick regular septa Mural nodule in low T2W signal (white arrow) and high DW signal (red arrow)
Purely solid tumor			
EP	Brenner tumors 		Unilateral Central psammomas Associated with other epithelial tumors
SC	Fibrothecoma (edematous) 		Any age No symptoms Solid tissue (red arrow / star) Lobulated margins Posterior shadowing at US Ascites

FIGURE 5: O-RADS MRI 3. EP = epithelial tumor; GC = germ cell tumors; SC = sec cord tumors; NL = nonneoplastic lesions; O = other.

suspects a cystadenofibroma, the score can be O-RADS MRI 2, 3, or 4.<sup>31</sup> For an expert-rated cystadenofibroma score of 2, the radiologist is right in nearly 100% of

cases, in 90% of cases for a score of 3, and <90% for a score of 4. Thus, the additional information and degree of certainty provided by the O-RADS MRI score will be

Unilocular with solid tissue		
EP Borderline serous cystadenoma		Papillary projection (arrow) No mural nodule Endo and/or exophytic papillary projection (white arrows) Normal ovarian parenchyma
Epithelial serous cystadenocarcinoma		No visible ovarian parenchyma Mural nodule (arrow) or mixed mass
Multilocular with solid tissue		
EP Cystadenofibroma		Perimenopausal woman Thick regular septation Mural nodule/mixed mass (arrow)
Borderline mucinous cystadenoma		Grouped and irregular septa (white arrow)
Epithelial mucinous/endometrioid/cl ear cells cystadenocarcinoma		Menopausal women Mural nodule (arrow)
GC Struma ovarii		Multiple loculi with different signal Cystic content: colloid, proteinaceous (white arrow) Mural nodule (Thyroid tissue - red arrow)
Immature teratoma		Microcystic tissue portion Cystic content: fatty (white arrows) Microcalcifications
Malignant germ cell tumors		Age < 30YO Alpha FP / beta HCG +++ Mixed mass (arrow)
SC Juvenile granulosa cell tumor		Menopausal women Hyperestrogenic symptoms (red arrow showing internal adenomyosis) Unilateral Loculi with hemorrhagic content (white arrow)
O Metastasis (digestive tract)		Associated tubular lesion in right iliac fossa (red star)

FIGURE 6: O-RADS MR 4. EP = epithelial tumor; GC = germ cell tumors; SC = sec cord tumors; NL = nonneoplastic lesions; O = other.

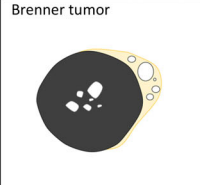
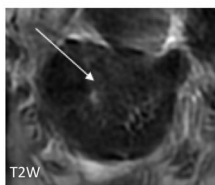
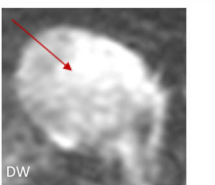
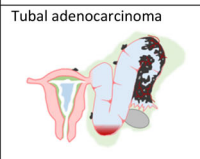
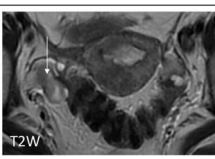
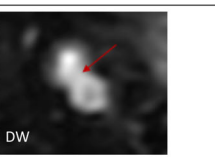
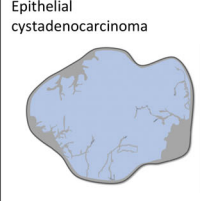
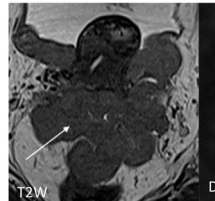
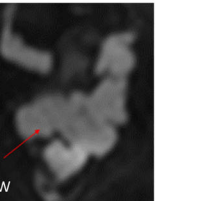

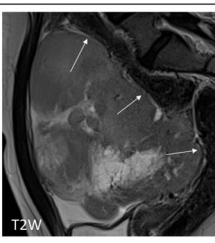
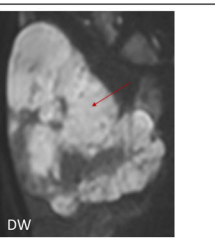
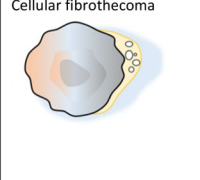
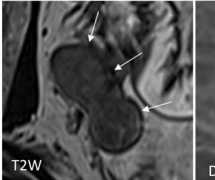
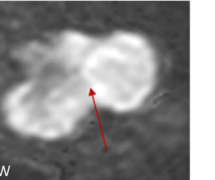
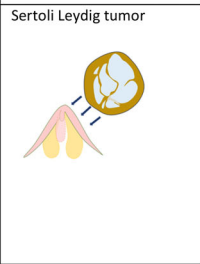
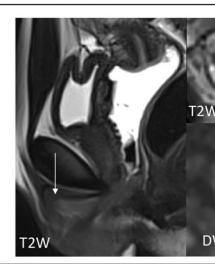
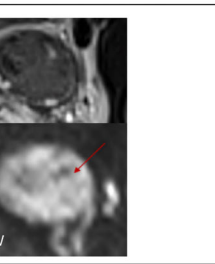

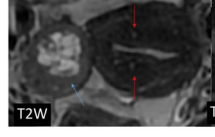
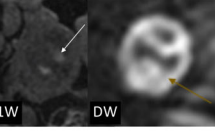
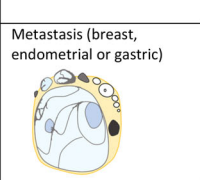

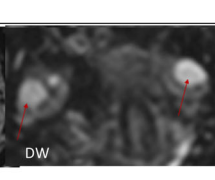
Purely solid tissue					
EP	Brenner tumor				Unilateral Solid mass (arrow) Central psammomas Associated with mature cystic teratoma
	Tubal adenocarcinoma				BRCA 1, BRCA 2 Sero-hematic bleeding Tubal dilatation with mural nodule (white arrow)
	Epithelial cystadenocarcinoma				No visible ovarian parenchyma Mural nodule or mixed mass (arrow)
GC	Dysgerminoma				Age <30YO LDH +++ Size > 10cm Lobulated margins (white arrows) High T1 fibrovascular septa
SC	Cellular fibrothecoma				Any age Size >10cm No symptoms Lobulated margins (white arrows)
	Sertoli Leydig tumor				Young woman Virilization sign (white arrow) Unilateral
	Adult granulosa cell				Menopausal women Hyperestrogenic symptoms (red arrows showing internal adenomyosis) Unilateral High T1W central necrotic zone (white arrow)
O	Metastasis (breast, endometrial or gastric)				Bilateral External invasion of the ovary >>> Possible Visible normal ovarian parenchyma

FIGURE 6: Continued

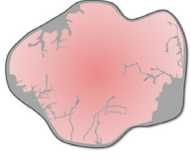
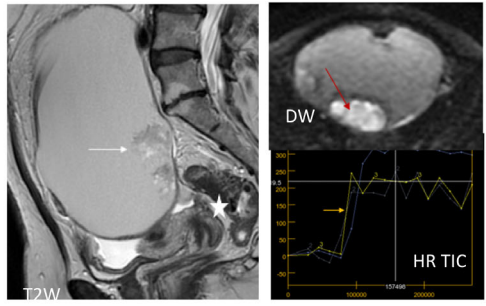

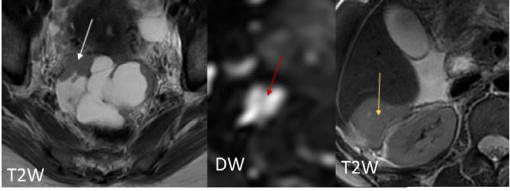
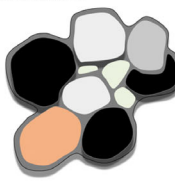
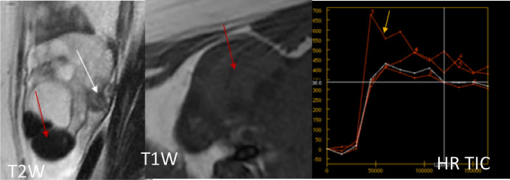
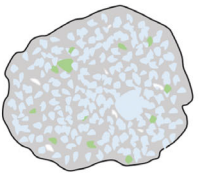
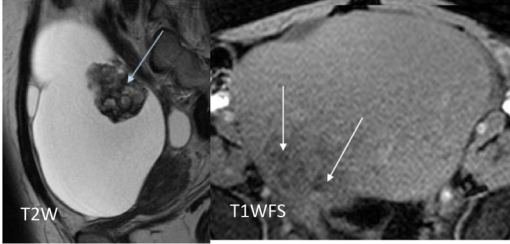

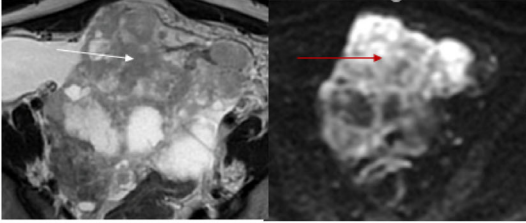
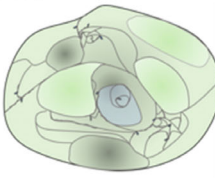
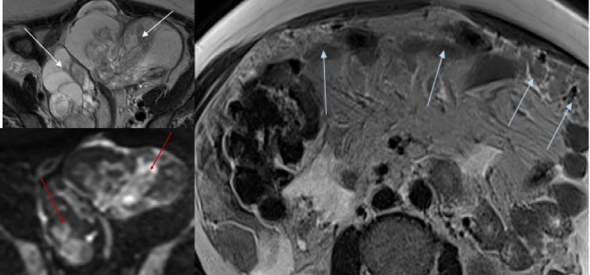
Unilocular with solid tissue			
EP	<p>Malignant degeneration of endometrioma</p> 		<p>Mural nodule (arrow) Associated deep pelvic endometriosis (white star)</p>
Multilocular with solid tissue			
EP	<p>Epithelial cystadenocarcinoma (endometrioid, clear cell)</p> 		<p>Menopausal women Mixed mass Loculi with different signal including blood No POVS +/- peritoneal implants</p>
L im	<p>Struma ovarii</p> 		<p>Multiple loculi with different signal Cystic content: colloid, proteinaceous (red arrow) Mural nodule (thyroid tissue- white arrow)</p>
	<p>Immature teratoma</p> 		<p>Age &lt;30YO Large solid tissue with fatty foci (white arrow)</p>
	<p>Malignant germ cells tumors</p> 		<p>Age &lt; 30YO Alpha FP +++ Mixed mass</p>
O	<p>Metastasis (digestive tract)</p> 		<p>External invasion of the ovary &gt;&gt;&gt; Possible Normal visible ovarian parenchyma Always think: O-RADS MR 5 + age &lt;50YO</p>

FIGURE 7: O-RADS MR 5. EP = epithelial tumor; GC = germ cell tumors; SC = sec cord tumors; NL = nonneoplastic lesions; O = other.


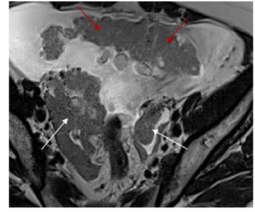
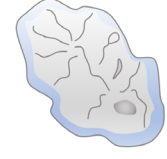
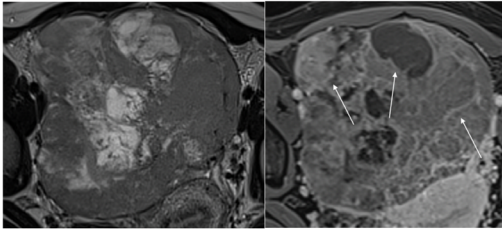
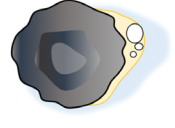
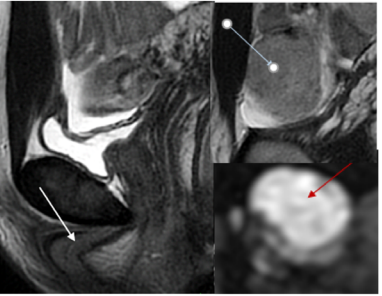
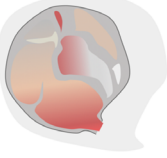
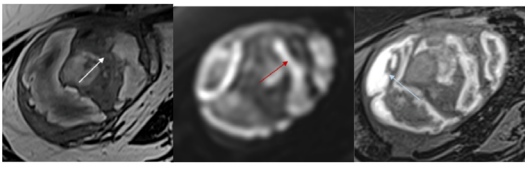
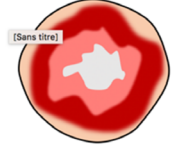
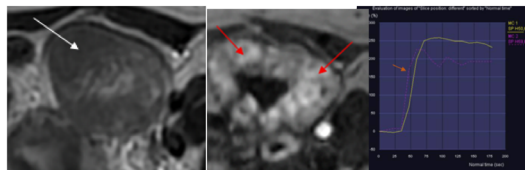
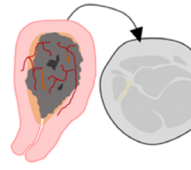
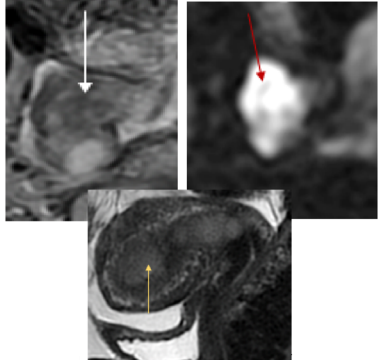
Purely solid tissue			
EP	Epithelial cystadenocarcinoma 		No visible ovarian parenchyma Mural nodule or mixed mass
GC	Dysgerminoma 		Age < 30YO LDH +++ Polylobed contours High vascular internal walls (white arrows)
SC	Sertoli Leydig tumor 		Young woman Virilization sign (white arrow showing a clitoral hypertrophy) Unilateral
	Adult granulosa cell 		Menopausal women Hyperoestrogenic symptoms Unilateral Loculi with hemorrhagic content (blue arrow)
	Stromal sclerosing tumor 		<30YO Unilateral Well circumscribed Washout (TIC) (red arrows)
O	Metastasis (breast, endometrial or gastric) 		External invasion of the ovary >>> Possible Normal ovarian parenchyma visible Always think: O-RADS MRI 5 + age <50YO

FIGURE 7: Continued

helpful during multidisciplinary team sessions for the surgeon to decide whether diagnostic surgery should be performed.

With its ability to distinguish benign from malignant adnexal masses, the O-RADS MRI score could also be a valuable tool for timely referral of a patient to an expert center for the treatment of ovarian cancers (currently recommended for all MRI reports in France).<sup>32</sup> Some studies have demonstrated the impact of the experience of the surgeon as well as the multidisciplinary team on the prognosis.<sup>33</sup> Thus, the radiologist can play a fundamental role using the O-RADS MRI classification by defining two groups of patients: 1) patients with masses with an O-RADS MRI score of 2 or 3 that may be elected either for follow-up or for surgical management in general care centers with unspecialized surgeons; and 2) patients with adnexal masses with an O-RADS score of 4 or 5 that should be referred to an expert center. This would be a way of increasing quality indicators 4 to 6 of the European Society of Gynecologic Oncology for improving care and organizational processes in the surgical management of ovarian cancer.<sup>34</sup>

Clinicians working in expert centers expect more from their radiologists than just to differentiate between benign and malignant disease. First, if there is a suspicion of malignancy, the key question is: “Is this a borderline or invasive tumor?” If a borderline tumor is suspected, then conservative procedures potentially using minimally invasive surgery can be performed.<sup>35,36</sup> Moreover, the distinction between serous and mucinous borderline tumors could have a huge impact on management in premenopausal women, potentially

indicating either a cystectomy or complete adnexectomy, respectively. If an invasive tumor is suspected, the therapeutic strategy could depend on the primitive or secondary nature of the tumor (i.e., cystadenocarcinoma versus metastasis).<sup>36</sup> An expert radiologist in gynecological imaging will combine the O-RADS MRI score with many other criteria to make a precise diagnosis allowing optimal personalized treatment. Overall, a complex combination of all MRI criteria is required.

Thus, the O-RADS MRI score is an evolving tool, and the radiologist needs to combine other MRI features as well as several additional clinical and biological criteria to make a pathological hypothesis.<sup>32</sup>

### Other Useful MRI Features to Combine with the O-RADS MRI Score

There are five general morphologies of adnexal masses as described in the O-RADS MRI lexicon<sup>14</sup>: Unilocular or multilocular cyst with/without solid tissue, and purely solid lesions. While unilocular and multilocular cysts without solid tissue are only found in categories O-RADS MRI 2 and 3, the three other types may be described in all O-RADS MRI categories. Another important MRI criterion in the analysis is the type of solid tissue. The presence of solid tissue is crucial in the O-RADS MRI score, but knowledge of the type of solid tissue (i.e., irregular septa, papillary projections, mural nodule, mixed mass, or purely solid) is very helpful to distinguish a borderline from an invasive tumor. Both invasive and borderline tumors can contain papillary projections,<sup>37</sup> but only invasive tumors have mural nodules or appear as mixed mass. Making the difference between a

**TABLE 4. Biological Markers**

Clinical context	Histological subtypes	Pathological subtypes	
<b>All women</b>	<b>Epithelial tumors (70%)</b>		
	CA 125		
	HE4		
<b>Young women (&lt;30YO)</b>	<b>Germ cell tumors (20%)</b>		
	LDH	Dysgerminoma	
	Alpha fetoprotein	Yolk sac tumor	
<b>Associated clinical symptoms</b>	<b>Sex cord tumor (10%)</b>		
	Virilization (hirsutism, amenorrhea, and clitoris enlargement)	Alpha androstenedione	<u>Sertoli-Leydig</u>
			<u>Steroid cell tumor</u>
Bleeding, adenomyosis, and thickened endometrium	E2	Thecoma	
		Inhibin	Granulosa

group of papillary projections and a mural nodule is essential at this step: a group of papillary projections has a central fibrous tissue and a central vessel, while a mural nodule is the focal thickening of a septa or a wall with a wide angle of connection (Fig. 3).<sup>38</sup> In addition, irregular septa correspond pathologically to small papillary projections (<3 mm) and are typically found in mucinous borderline tumors while papillary projections are over 3 mm in serous borderline tumors. Moreover, papillary projections may be endocytic or exophytic.<sup>39</sup> Exophytic papillary projections are only describe in serous borderline cystadenoma.

The other potentially helpful MRI criteria are detailed in Table 2. Some criteria relate directly to the mass and others are associated criteria relating to the effect of the mass on adjacent structures. As displayed in this table, there are numerous criteria corresponding to the high number of different pathological types of adnexal tumors. This is why a radiologist experienced in gynecological imaging will usually set out to combine the criteria along with clinical and biological parameters when a nonspecific MRI pattern is present.

### **Other Additional Clinical and Biological Features Useful to Combine with the O-RADS MRI Score**

All MRI, clinical, and biological criteria (Tables 3 and 4) should be analyzed in the second step of analysis after the O-RADS MRI score. Figs. 4–7 show how to combine the various diagnostic tools.

### **Conclusion**

The O-RADS MRI score is an essential tool for distinguishing between benign and malignant adnexal masses. It can be used by any radiologist and integrated into a multi-disciplinary decision-making process to define an optimal therapeutic strategy. Moreover, for expert radiologists, the score adds to the degree of certainty and can be combined with clinical, biological, and other MRI criteria to make a pathological hypothesis and assist surgeons in electing the most appropriate procedure in a personalized approach.

### **References**

1. Thomassin-Naggara I, Poncelet E, Jalaguier-Coudray A, et al. Ovarian-adnexal reporting data system magnetic resonance imaging (O-RADS MRI) score for risk stratification of Sonographically indeterminate adnexal masses. *JAMA Netw Open* 2020;3:e1919896.
2. Rizzo S, Cozzi A, Dolciami M, et al. O-RADS MRI: A systematic review and meta-analysis of diagnostic performance and category-wise malignancy rates. *Radiology* 2023;307:e220795.
3. Sisodia RC, Del Carmen MG. Lesions of the ovary and fallopian tube. *N Engl J Med* 2022;387:727-736.
4. Sadowski EA, Paroder V, Patel-Lippmann K, et al. Indeterminate adnexal cysts at US: Prevalence and characteristics of ovarian cancer. *Radiology* 2018;287:1041-1049.
5. Shandley LM, Spencer JB, Kipling LM, Hussain B, Mertens AC, Howards PP. The risk of infertility after surgery for benign ovarian cysts. *J Womens Health (Larchmt)* 2023;32:574-582.
6. Yazbek J, Ameye L, Testa AC, et al. Confidence of expert ultrasound operators in making a diagnosis of adnexal tumor: Effect on diagnostic accuracy and interobserver agreement. *Ultrasound Obstet Gynecol* 2010;35:89-93.
7. Guo Y, Phillips CH, Suarez-Weiss K, et al. Interreader agreement and Intermodality concordance of O-RADS US and MRI for assessing large, complex ovarian-adnexal cysts. *Radiol Imaging Cancer* 2022;4:e220064.
8. Kaijser J, Vandecaveye V, Deroose CM, et al. Imaging techniques for the pre-surgical diagnosis of adnexal tumours. *Best Pract Res Clin Obstet Gynaecol* 2014;28:683-695.
9. Andreotti RF, Timmerman D, Benacerraf BR, et al. Ovarian-adnexal reporting lexicon for ultrasound: A white paper of the ACR ovarian-adnexal reporting and data system committee. *J Am Coll Radiol* 2018;15:1415-1429.
10. Andreotti RF, Timmerman D, Strachowski LM, et al. O-RADS US risk stratification and management system: A consensus guideline from the ACR ovarian-adnexal reporting and data system committee. *Radiology* 2020;294:168-185.
11. Jha P, Gupta A, Baran TM, et al. Diagnostic performance of the ovarian-adnexal reporting and data system (O-RADS) ultrasound risk score in women in the United States. *JAMA Netw Open* 2022;5:e2216370.
12. Timmerman D, Planchamp F, Bourne T, et al. ESGO/ISUOG/IOTA/ESGE consensus statement on pre-operative diagnosis of ovarian tumors. *Int J Gynecol Cancer* 2021;31:1396-1397.
13. Sadowski EA, Stein EB, Thomassin-Naggara I, et al. O-RADS MRI after initial ultrasound for adnexal lesions: AJR expert panel narrative review. *AJR Am J Roentgenol* 2023;220:6-15.
14. Reinhold C, Rockall A, Sadowski EA, et al. Ovarian-adnexal reporting lexicon for MRI: A white paper of the ACR ovarian-adnexal reporting and data systems MRI committee. *J Am Coll Radiol* 2021;18:713-729.
15. Thomassin-Naggara I, Belghitti M, Milon A, et al. O-RADS MRI score: Analysis of misclassified cases in a prospective multicentric European cohort. *Eur Radiol* 2021;31:9588-9599.
16. Sahin H, Panico C, Ursprung S, et al. Non-contrast MRI can accurately characterize adnexal masses: A retrospective study. *Eur Radiol* 2021;31:6962-6973.
17. Thomassin-Naggara I, Toussaint I, Perrot N, et al. Characterization of complex adnexal masses: Value of adding perfusion- and diffusion-weighted MR imaging to conventional MR imaging. *Radiology* 2011;258:793-803.
18. Wengert GJ, Dabi Y, Kermarrec E, et al. O-RADS MRI classification of indeterminate adnexal lesions: Time-intensity curve analysis is better than visual assessment. *Radiology* 2022;303:566-575.
19. Thomassin-Naggara I, Darai E, Cuenod CA, Rouzier R, Callard P, Bazot M. Dynamic contrast-enhanced magnetic resonance imaging: A useful tool for characterizing ovarian epithelial tumors. *J Magn Reson Imaging* 2008;28:111-120.
20. Assouline V, Dabi Y, Jalaguier-Coudray A, et al. How to improve O-RADS MRI score for rating adnexal masses with cystic component? *Eur Radiol* 2022;32:5943-5953.
21. Jung SE, Lee JM, Rha SE, Byun JY, Jung JI, Hahn ST. CT and MR imaging of ovarian tumors with emphasis on differential diagnosis. *Radiographics* 2002;22:1305-1325.
22. Foti PV, Attinà G, Spadola S, et al. MR imaging of ovarian masses: Classification and differential diagnosis. *Insights Imaging* 2016;7:21-41.
23. Oh SN, Rha SE, Byun JY, et al. MRI features of ovarian fibromas: Emphasis on their relationship to the ovary. *Clin Radiol* 2008;63:529-535.



- Thomassin-Naggara et al.: O-RADS MRI in clinical routine
- the joint French clinical practice guidelines issued by FRANCOGYN, CNGOF, SFOG, and GINECO-ARCAGY, and endorsed by INCa. Part 1: Diagnostic exploration and staging, surgery, perioperative care, and pathology. *J Gynecol Obstet Hum Reprod* 2019;48:369-378.
24. Rockall AG, Jalaguier-Coudray A, Thomassin-Naggara I. MR imaging of the adnexa: Technique and imaging acquisition. *Magn Reson Imaging Clin N Am* 2023;31:149-161.
  25. Anthoulakis C, Nikoloudis N. Pelvic MRI as the "gold standard" in the subsequent evaluation of ultrasound-indeterminate adnexal lesions: A systematic review. *Gynecol Oncol* 2014;132:661-668.
  26. Thomassin-Naggara I, Aubert E, Rockall A, et al. Adnexal masses: Development and preliminary validation of an MR imaging scoring system. *Radiology* 2013;267:432-443.
  27. Rogers D, Menias C, Shaaban A. Malignant germ cell tumors of the ovary: Clinical and imaging features. *Radiol Clin North Am* 2023;61:579-594.
  28. Thomassin-Naggara I, Daraï E, Cuenod CA, et al. Contribution of diffusion-weighted MR imaging for predicting benignity of complex adnexal masses. *Eur Radiol* 2009;19:1544-1552.
  29. Sadowski EA, Thomassin-Naggara I, Rockall A, et al. O-RADS MRI risk stratification system: Guide for assessing adnexal lesions from the ACR O-RADS committee. *Radiology* 2022;303:35-47.
  30. Manganaro L, Ciulla S, Celli V, et al. Impact of DWI and ADC values in ovarian-adnexal reporting and data system (O-RADS) MRI score. *Radiol Med* 2023;128:565-577.
  31. Avesani G, Elia L, Anghelone AG, et al. Features of cystadenofibroma on magnetic resonance imaging: An update using the O-RADS lexicon and considering diffusion-weighted and perfusion imaging. *Eur J Radiol* 2022;154:110429.
  32. Lavoue V, Huchon C, Akladios C, et al. Management of epithelial cancer of the ovary, fallopian tube, and primary peritoneum. Long text of
  33. Babayeva A, Braicu EI, Grabowski JP, et al. Clinical outcome after completion surgery in patients with ovarian cancer: The Charite experience. *Int J Gynecol Cancer* 2018;28:1491-1497.
  34. Querleu D, Planchamp F, Chiva L, et al. European Society of Gynaecologic Oncology Quality Indicators for advanced ovarian cancer surgery. *Int J Gynecol Cancer* 2016;26:1354-1363.
  35. Bentivegna E, Gouy S, Maulard A, et al. Fertility-sparing surgery in epithelial ovarian cancer: A systematic review of oncological issues. *Ann Oncol* 2016;27:1994-2004.
  36. Colombo N, Sessa C, Bois A d, et al. ESMO-ESGO consensus conference recommendations on ovarian cancer: Pathology and molecular biology, early and advanced stages, borderline tumours and recurrent disease. *Int J Gynecol Cancer* 2019;29:728-760.
  37. Outwater EK, Huang AB, Dunton CJ, Talerman A, Capuzzi DM. Papillary projections in ovarian neoplasms: Appearance on MRI. *J Magn Reson Imaging* 1997;7:689-695.
  38. Bazot M, Daraï E, Nassar-Slaba J, Lafont C, Thomassin-Naggara I. Value of magnetic resonance imaging for the diagnosis of ovarian tumors: A review. *J Comput Assist Tomogr* 2008;32:712-723.
  39. Bent CL, Sahdev A, Rockall AG, Singh N, Sohaib SA, Reznick RH. MRI appearances of borderline ovarian tumours. *Clin Radiol* 2009;64:430-438.