

About the Author

Dr. Guidoum is a researcher at the Ibn Khaldoun University, Zaârour, Algeria. His current research focuses on emerging infectious diseases in the livestock/wildlife interface in desertic areas in North Africa.

References

1. Estrada-Peña A, de la Fuente J. The ecology of ticks and epidemiology of tick-borne viral diseases. *Antiviral Res.* 2014;108:104–28. <https://doi.org/10.1016/j.antiviral.2014.05.016>
2. Temur AI, Kuhn JH, Pecor DB, Apanaskevich DA, Keshitkar-Jahromi M. Epidemiology of Crimean-Congo hemorrhagic fever (CCHF) in Africa – underestimated for decades. *Am J Trop Med Hyg.* 2021;104:1978–90. <https://doi.org/10.4269/ajtmh.20-1413>
3. Kautman M, Tiar G, Papa A, Široký P. AP92-like Crimean-Congo hemorrhagic fever virus in *Hyalomma aegyptium* ticks, Algeria. *Emerg Infect Dis.* 2016;22:354–6. <https://doi.org/10.3201/eid2202.151528>
4. Faye B. How many large camelids in the world? A synthetic analysis of the world camel demographic changes. *Pastoralism.* 2020;10:25. <https://doi.org/10.1186/s13570-020-00176-z>
5. Arino O, Gross D, Ranera F, Leroy M, Bicheron P, Brockman C, et al. GlobCover: ESA service for global land cover from MERIS. 2007 IEEE Int Geosci Remote Sens Symp. 2007;2412–5. <https://doi.org/10.1109/IGARSS.2007.4423328>
6. Schulz A, Barry Y, Stoek F, Ba A, Schulz J, Haki ML, et al. Crimean-Congo hemorrhagic fever virus antibody prevalence in Mauritanian livestock (cattle, goats, sheep and camels) is stratified by the animal's age. *PLoS Negl Trop Dis.* 2021;15:e0009228. <https://doi.org/10.1371/journal.pntd.0009228>
7. Bouaicha F, Eisenbarth A, Elati K, Schulz A, Ben Smida B, Bouajila M, et al. Epidemiological investigation of Crimean-Congo haemorrhagic fever virus infection among the one-humped camels (*Camelus dromedarius*) in southern Tunisia. *Ticks Tick Borne Dis.* 2021;12:101601. <https://doi.org/10.1016/j.ttbdis.2020.101601>
8. Bedda H, Adamou A, Bouammar B, Babelhadj B. The decline of camel production systems in Algerian Northern Sahara – case of the basin of Ouargla, the M'zab and the Ziban [in French]. *Livest Res Rural Dev.* 2019;31:44.
9. Messina JP, Pigott DM, Golding N, Duda KA, Brownstein JS, Weiss DJ, et al. The global distribution of Crimean-Congo hemorrhagic fever. *Trans R Soc Trop Med Hyg.* 2015;109:503–13. <https://doi.org/10.1093/trstmh/trv050>
10. Mammeri A, Kayoueche FZ, Benmakhlof A. Peri-urban breeding practice of one-humped camel (*Camelus Dromedarius*) in the Governorate of Biskra (Algeria); a new option. *Journal of Animal Production Advances.* 2014;4:403–15.

Address for correspondence: Oscar Cabezon, Departament de Medicina i Cirurgia Animals, Universitat Autònoma de Barcelona, Edifici V, 08193 Bellaterra, Spain; email: oscar.cabezon@uab.cat

Microfilaremic *Dirofilaria repens* Infection in Patient from Serbia

Suzana Tasić-Otasevic, Milan Golubović, Simone Trichei, Dragan Zdravkovic, Radojičić Jordan, Simona Gabrielli

Author affiliations: University of Niš, Niš, Serbia (S. Tasić-Otasevic, M. Golubović); Public Health Institute, Niš (S. Tasić-Otasevic, D. Zdravkovic); University Clinical Center of Niš, Niš (M. Golubović); Sapienza University of Rome, Rome, Italy (S. Trichei, S. Gabrielli); Niš Military Hospital, Niš (R. Jordan)

DOI: <https://doi.org/10.3201/eid2912.230796>

We report a case of *Dirofilaria repens* infection causing microfilaremia in a patient from Serbia. Serum samples tested positive for *D. repens* IgG by ELISA. Our findings and those of others suggest the parasite's progressive adaptation to humans. Clinicians should be aware that microfilaremia can develop during *Dirofilaria* spp. infections.

Dirofilaria repens is a vectorborne filarial helminth of carnivores, mainly domesticated dogs (1). Humans are considered accidental hosts, in which the parasite induces local inflammation causing granulomatous reactions primarily detected in subcutaneous and ocular tissues. Because humans are not natural hosts, microfilariae are typically absent from peripheral blood; thus, diagnostic procedures require morphologic and molecular analyses of removed worms (2). Immunodiagnostic tests are being designed as potential alternatives to invasive diagnostic procedures (3). This parasite rarely evades the human host's immune system to reach sexual maturity. The literature reports 22 cases of human *D. repens* microfilaremia, of which several have been confirmed through molecular examination (3,4). We describe a case of human dirofilariasis with circulating microfilariae in a patient from Serbia.

A 43-year-old professional soldier in the army of Serbia was first seen for a walnut-sized swelling accompanied by itching on the inner side of his thigh, which we promptly treated with ciprofloxacin (1 g/d) for 14 days. Two months after the initial swelling, the patient noted another similar protuberance on his inner thigh that migrated toward the back of the thigh every 2–3 days. An ultrasound detected a 13.5 × 8 mm subcutaneous nodule. Biochemical analyses of the patient's blood and blood cell counts were within reference ranges,

including eosinophil levels; however, surgical intervention was required 1 month after the ultrasound to excise the nodule and investigate its origin. Examination of the removed nodule revealed a *Dirofilaria repens*-like specimen. Twenty days after nodule removal, the percentage of eosinophils in the patient's peripheral blood increased to 14%. We performed a modified Knotts test on EDTA blood, which revealed the presence of 2 microfilariae/mL. The mean microfilaria body length was 377–378 μm and mean width was 7.35–7.6 μm ; they had no sheath but had obtuse cervical ends, 2–3 separate nuclei in the head space, and nuclei-free filiform tails (Figure).

We used species-specific PCR that amplified a portion of the cytochrome oxidase subunit 1 gene, *cox1*, to confirm the microfilariae were *D. repens* (Appendix, <https://wwwnc.cdc.gov/EID/article/29/12/23-0796-App1.pdf>). BLAST (<https://blast.ncbi.nlm.nih.gov>) analysis of the nucleotide sequence revealed a 97%–100% identity with published sequences of *D. repens* (Appendix Figure). We deposited the sequence in GenBank (accession no. OR426928.1). We constructed a maximum-likelihood phylogenetic tree of *cox1* sequences from this study and representative *D. repens* isolates from animals and humans in Europe by using MEGA version 11 software (5) and the Kimura 2-parameter distance model. We assessed the robustness of nodes by using 500 bootstrap replicates; *Ascaris lumbricoides* (GenBank accession no. AB591801.1) was the outgroup (Appendix Figure).

We used ELISAs to detect *Dirofilaria* spp. IgG. Cutoff optical densities were 1.8 for the commercial *Acanthocheilonema viteae* IgG ELISA kit (Bordier, <http://www.bordier.ch>), which detects IgG against various filarial nematodes in human serum, and 2.3 for an in-house ELISA (Appendix).

Two months after the *D. repens* diagnosis, the patient had an eosinophil count within reference ranges. No further microfilariae were detected in peripheral blood smears during monitoring.

Dirofilaria spp. infections are increasing globally, posing a substantial threat to pets, particularly dogs (1). The rising number of human dirofilariasis cases underscores the need for large-scale epidemiologic studies to establish effective preventive measures (1,4). Although humans are generally regarded as unsuitable hosts for *D. repens*, detection of single subadult or adult worms in humans is not uncommon (3). The worms can infrequently develop into mature adults, mate, and produce microfilariae, which can potentially enter the bloodstream in human hosts. Diagnosis involves morphologic and molecular analyses,

but surgical removal of the worm and specialized equipment are required (2). Serologic tests detect specific antibodies, providing a more reliable epidemiologic picture of the zoonosis within a study area (3).

Several protocols are available to investigate seroreactivity in humans (6,7), but antibody responses might not be detected until the nematode has migrated internally from subcutaneous tissue (8). Localization of larvae in ocular tissue might confer greater protection for the parasite, leading to a low predictive positive value for diagnosing *Dirofilaria* spp. infection (9).

No established treatment protocols exist for dirofilariasis or microfilaremia, leaving therapeutic decisions to physicians. Surgery is the primary treatment, accompanied by adjuvant therapy options, such as ivermectin, albendazole, or diethylcarbamazine. Doxycycline, a treatment for *Wolbachia* endosymbionts, has been used (9). In this case, we considered anthelmintics after surgical removal and microfilariae detection but chose continuous monitoring. Two months after diagnosis, the patient's health was satisfactory, and he had no symptoms or complications from the infection.

In conclusion, we report a case of *D. repens* microfilaremia in a professional soldier frequently exposed to vector biting because of prolonged outdoor activities during military training in northern Serbia, a dirofilariasis-endemic area (10). The presence of circulating microfilariae highlighted by this and previous studies shows the parasite's progressive adaptation to humans and suggests a potential role for humans as a definitive *D. repens* host. Although a role for humans as an infection reservoir remains to be clarified, clinicians should be aware that microfilaremia can develop during *Dirofilaria* spp. infections.

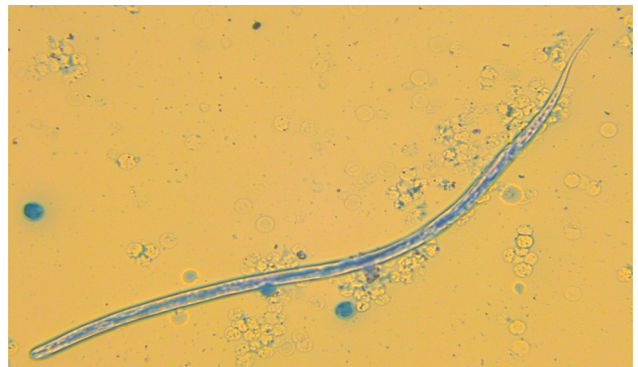


Figure. Microscopic image of *Dirofilaria repens* microfilaria in case study of microfilaremic *D. repens* infection in patient from Serbia. A blood sample from the patient was processed and stained with methylene blue. Scale bar indicates 200 μm .

About the Author

Dr. Tasić-Otasevic is a professor in the Department of Microbiology and Immunology, University of Niš, and Department of Microbiology and Parasitology, Public Health Institute. Her research interests are clinical and diagnostic microbiology, skin and genital infections, antimicrobial resistance, fungal pathogens, vectorborne zoonosis, and health promotion.

References

1. Genchi C, Kramer LH. The prevalence of *Dirofilaria immitis* and *D. repens* in the Old World. *Vet Parasitol.* 2020;280:108995. <https://doi.org/10.1016/j.vetpar.2019.108995>
2. Gabrielli S, Mangano V, Furzi F, Oliva A, Vita S, Poscia R, et al. Molecular identification of new cases of human dirofilariasis (*Dirofilaria repens*) in Italy. *Pathogens.* 2021;10:251. <https://doi.org/10.3390/pathogens10020251>
3. Simón F, Diosdado A, Siles-Lucas M, Kartashev V, González-Miguel J. Human dirofilariasis in the 21st century: a scoping review of clinical cases reported in the literature. *Transbound Emerg Dis.* 2022;69:2424–39. <https://doi.org/10.1111/tbed.14210>
4. Pupiĉ-Bakraĉ A, Pupiĉ-Bakraĉ J, Beck A, Jurković D, Polkinghorne A, Beck R. *Dirofilaria repens* microfilaremia in humans: case description and literature review. *One Health.* 2021;13:100306. <https://doi.org/10.1016/j.onehlt.2021.100306>
5. Tamura K, Stecher G, Kumar S. MEGA11: molecular evolutionary genetics analysis version 11. *Mol Biol Evol.* 2021;38:3022–7. <https://doi.org/10.1093/molbev/msab120>
6. Ciuca L, Simón F, Rinaldi L, Kramer L, Genchi M, Cringoli G, et al. Seroepidemiological survey of human exposure to *Dirofilaria* spp. in Romania and Moldova. *Acta Trop.* 2018;187:169–74. <https://doi.org/10.1016/j.actatropica.2018.07.012>
7. Savić S, Stosic MZ, Marcic D, Hernández I, Potkonjak A, Otasevic S, et al. Seroepidemiological study of canine and human dirofilariasis in the endemic region of northern Serbia. *Front Vet Sci.* 2020;7:571. <https://doi.org/10.3389/fvets.2020.00571>
8. Otranto D, Eberhard ML. Zoonotic helminths affecting the human eye. *Parasit Vectors.* 2011;4:41. <https://doi.org/10.1186/1756-3305-4-41>
9. Simón F, Siles-Lucas M, Morchón R, González-Miguel J, Mellado I, Carretón E, et al. Human and animal dirofilariasis: the emergence of a zoonotic mosaic. *Clin Microbiol Rev.* 2012;25:507–44. <https://doi.org/10.1128/CMR.00012-12>
10. Tasić-Otašević S, Savić S, Jurhar-Pavlova M, Stefanovska J, Stalević M, Ignjatović A, et al. Molecular survey of *Dirofilaria* and *Leishmania* species in dogs from central Balkan. *Animals (Basel).* 2022;12:911. <https://doi.org/10.3390/ani12070911>

Address for correspondence: Simona Gabrielli, Department of Public Health and Infectious Diseases, Sapienza University of Rome, Piazzale Aldo Moro 5, Rome 00185, Italy; email: simona.gabrielli@uniroma1.it

Anthropogenic Transmission of SARS-CoV-2 from Humans to Lions, Singapore, 2021

Yin Cheong Aden Ip, Adrian Tan, Jasmine Ong, Charlene Judith Fernandez, Clara Lau, Wai Kwan Wong, Siow Foong Chang, Him Hoo Yap, Kenneth B.H. Er

Author affiliation: National Parks Board, Singapore

DOI: <https://doi.org/10.3201/eid2912.221916>

In Singapore, 10 captive lions tested positive for SARS-CoV-2 by real-time PCR. Genomic analyses of nanopore sequencing confirmed human-to-animal transmission of the SARS-CoV-2 Delta variant. Viral genomes from the lions and zookeeper shared a unique spike protein substitution, S:A1016V. Widespread SARS-CoV-2 transmission among humans can increase the likelihood of anthroponosis.

We investigated natural SARS-CoV-2 infection in captive African (*Panthera leo*) and Asiatic (*Panthera leo persica*) lions at a zoo in Singapore during increased Delta variant community infections. Understanding virus dynamics in different hosts is crucial for preventing interspecies transmission and protecting endangered species (1,2).

We studied 14 lions, 9 Asiatic and 5 African, that were housed in separate enclosures. On November 6, 2021, respiratory signs developed in a male Asiatic lion (AS-M1) (Appendix 1, <https://wwwnc.cdc.gov/EID/article/29/12/22-1916-App1.pdf>). On November 7, three Asiatic lionesses (AS-F1, AS-F2, and AS-F3) in the same enclosure exhibited similar clinical signs. A male African lion (AF-M3) in a separate enclosure developed clinical signs on November 8.

Eighteen zookeepers cared for and had close (within ≈1 m) but not direct contact with the lions. Six zookeepers tested COVID-19–positive beginning November 1, 2021, and 4 experienced mild respiratory symptoms starting on November 2.

To minimize stress on the animals, only 2 lions that had more severe signs, AS-M1 and AS-F1, were anesthetized for nasal and oropharyngeal sample collection on November 8. On November 9, we confirmed SARS-CoV-2 infection in the lions by real-time reverse transcription PCR (rRT-PCR); cycle quantitation (Cq) values were <40. Nasal swab samples from AS-M1 and AS-F1 had the highest viral loads (Cq 23.05 for AS-M1, 24.47 AS-F1). We conducted noninvasive infection monitoring for 3 weeks by collecting