

Review

Parkinson's Disease: What Can Retinal Imaging Tell Us?

Mariachiara Di Pippo¹, Sergio d'Agostino¹, Francesco Ruggeri¹, Chiara Carrozzi¹,
Davide Fasciolo¹, Solmaz Abdolrahimzadeh^{1,2,*}

¹Ophthalmology Unit, Neurosciences, Mental Health, and Sense Organs (NESMOS) Department, Faculty of Medicine and Psychology, University of Rome Sapienza, 00189 Rome, Italy

²Ophthalmology Unit, Sant'Andrea hospital, 00189 Rome, Italy

*Correspondence: solmaz.abdolrahimzadeh@uniroma1.it (Solmaz Abdolrahimzadeh)

Academic Editor: Gernot Riedel

Submitted: 8 August 2023 Revised: 27 August 2023 Accepted: 31 August 2023 Published: 22 January 2024

Abstract

Parkinson's disease (PD) is a neurodegenerative disorder characterized by motor symptoms such as tremors, rigidity, and bradykinesia. While the diagnosis of PD primarily relies on clinical assessments and neurological examination, there has been growing interest in exploring non-invasive imaging techniques to aid in early detection and monitoring of the disease. In recent years, retinal imaging has emerged as a promising tool for studying PD due to the close anatomical and functional similarities between the retina and the brain. Retinal imaging methods, such as spectral domain optical coherence tomography and optical coherence tomography angiography, enable non-intrusive visualization and measurement of retinal structures and blood vessels. These techniques hold the promise of capturing alterations in retinal structure and function that could potentially mirror the underlying pathological mechanisms in PD. This review article aims to provide an overview of the current understanding of retinal changes in PD and the potential utility of retinal imaging as a diagnostic and monitoring tool.

Keywords: Parkinson's disease; retinal imaging; spectral-domain optical coherence tomography; optical coherence tomography angiography; neurodegenerative disorders; α -synuclein

1. Introduction

Parkinson's disease (PD) is a progressive and chronic neurodegenerative condition characterized by the degeneration of dopaminergic neurons in the midbrain substantia nigra pars compacta. Additionally, it is marked by the presence of abnormal protein aggregates called Lewy bodies and Lewy neurites, mainly composed of misfolded α -synuclein (α -syn) [1,2]. These protein aggregates lead to a gradual loss of neurons and a decrease in dopamine levels, a crucial neurotransmitter responsible for regulating smooth and coordinated motor function. Consequently, individuals with PD experience a range of motor symptoms, including tremors, rigidity, bradykinesia, and postural instability [2,3].

The etiology of PD remains largely unknown, with both genetic and environmental factors implicated in its pathogenesis [1]. Approximately 5–10% of PD cases are attributed to monogenic forms of the disease, with mutations in genes such as *SNCA*, *LRRK2*, and *PARKIN* identified [1]. However, most PD cases are idiopathic, with no identifiable genetic etiology. Diagnosing PD is primarily based on recognizing its characteristic motor symptoms [3]. However, accurately diagnosing PD, especially during the early stages, can be challenging due to the subtle nature of the symptoms and potential overlap with other neurological disorders. As a result, misdiagnoses are not uncommon, leading to delays in appropriate treatment and management [2,4].

In addition to motor symptoms, PD is now recognized as a complex and heterogeneous disorder with various non-motor manifestations. These non-motor symptoms encompass cognitive impairment, mood disorders like depression and anxiety, sleep disturbances, autonomic dysfunction, visual changes, and sensory abnormalities [5]. The presence of non-motor symptoms further complicates the diagnostic process, as they may precede the onset of motor symptoms or occur independently, leading to a broader clinical spectrum of PD [5,6].

Given the challenges in diagnosing PD and the importance of early detection, there has been a growing interest in exploring alternative diagnostic approaches to complement standard clinical assessments. One emerging area of research focuses on retinal imaging techniques to better understand the pathophysiological changes associated with PD [7–9].

Retinal imaging has recently emerged as a promising technique for investigating neurodegenerative conditions, including PD [9–11]. The retina possesses remarkable similarities in embryological development, anatomy, and function with the brain. It consists of diverse cell types, including retinal ganglion cells (RGCs), which act as the primary output neurons of the retina, transmitting their axons through the optic nerve to the brain. Due to the shared embryological origin and the close anatomical relationship between the retina and the brain, there is a hypothesis that reti-



nal changes might reflect alterations in the central nervous system in neurodegenerative diseases and systemic disease [12–17].

Retinal imaging techniques, such as spectral domain optical coherence tomography (SD-OCT) and optical coherence tomography angiography (OCTA), allow for non-invasive visualization and quantification of retinal structures and vasculature [18,19]. These techniques offer the potential to capture structural and functional changes in the retina that may reflect the underlying pathological processes in PD. Consequently, there has been growing interest in exploring the utility of retinal imaging as a diagnostic and monitoring tool in PD [20–22].

The objective of this review is to provide a comprehensive overview of the current knowledge regarding retinal changes in PD and to assess the potential of retinal imaging as a valuable approach for diagnosing and monitoring the disease. The aim is to contribute to the advancement of more precise diagnostic methods and monitoring strategies, ultimately enhancing patient outcomes and facilitating the development of novel therapies for PD.

2. Retinal Anatomy and Pathophysiology in Parkinson's Disease

The retina is an extension of the central nervous system and consists of several layers, including from inside to outside: the retinal nerve fiber layer (RNFL), the ganglion cell layer (GCL), the inner plexiform layer (IPL), the inner nuclear layer (INL), the outer plexiform layer (OPL), the outer nuclear layer (ONL), the photoreceptor layer, and the retinal pigmented epithelium (RPE) (Fig. 1, Ref. [8]).

These layers are analogous to specific regions of the brain, allowing for comparative analysis between retinal and brain pathologies [7,23,24]. In PD there are numerous observed retinal pathophysiological changes, making it highly intriguing to explore the connection between these retinal alterations and the underlying PD pathology. Extensive research on retinal changes in PD has provided compelling evidence of α -syn accumulation in various retinal regions [8]. Studies in animal models and PD patients have explored the distribution pattern of α -syn in the retina, with early findings indicating its accumulation in the outer segments of photoreceptors, in axonal terminals in the OPL, and in amacrine and bipolar cells in the IPL [25]. However, some studies have reported contrasting results, identifying α -syn accumulation in the IPL but not in the OPL [26]. The potential involvement of α -syn in neurotransmission between photoreceptors and bipolar and amacrine cells, as well as in the synaptic-vesicular cycle, has been proposed, drawing parallels with processes in the brain [25].

Further investigations have revealed α -syn deposits in the intracytoplasmic spaces of the INL, increasing with age [27]. Additionally, a positive correlation has been established between intracytoplasmic α -syn inclusions and ubiquitin inclusions, implying analogous mechanisms in

the brain and retina [27]. The phosphorylated form of α -syn (p-syn) has also been a focus of research in the retina. Retinal samples from PD patients have shown α -synuclein-immunoreactive phosphorylated nerve fibers (phosphorylated α -synuclein-immunoreactive [p-syn IR]) within the RNFL, GCL, and inner layers of the IPL [28]. Discrepancies in findings have been attributed to methodological differences, including sample size and specific anti-phosphorylated α -syn antibodies [28]. Further studies using mouse models of PD have confirmed retinal damage from p-syn accumulation [29].

Notably, intraneuronal globular Lewy bodies have been observed in the INL and diffuse α -syn in the IPL, along with intra- and extra-cellular α -syn inclusions in the GCL [30]. These retinal dopaminergic amacrine cells exhibited reduced tyrosine hydroxylase immunoreactivity, similar to what is observed in PD [30]. Moreover, inclusions at the GCL level have been hypothesized to result from either α -syn gene overexpression or propagation from neurons of the INL and IPL via vesicular mechanisms like endosomes and exosomes [31]. Interestingly, Price *et al.* [32] showed in animal models the presence of α -syn along the wall of arterial vessels in the superficial retinal circulation. Characterizing p-syn accumulation in retinal cells and structures has shed light on the disease progression, showing a positive correlation between p-syn density in the retina and the brain of PD subjects, with associations to motor scores and disease stage. These findings suggest a synchronized disease progression in both tissues, enhancing the significance of the retina as a potential biomarker for brain disease in PD [33].

3. Retinal Imaging Techniques

Retinal imaging techniques have emerged as potentially valuable means in PD research, offering promising avenues for non-invasive and comprehensive exploration of the neurodegenerative processes associated with the condition. Among the advanced methods employed in this field are SD-OCT and OCTA. Although their full recognition and integration into PD diagnosis and monitoring are still evolving, these techniques show significant potential in unraveling the complexities of the disease and may eventually play a crucial role in enhancing our understanding and management of PD [10].

3.1 Spectral Domain-Optical Coherence Tomography (SD-OCT)

SD-OCT is a cutting-edge imaging technique widely employed in ophthalmology and medical research to non-invasively visualize and analyze ocular structures, particularly the retina, with exceptional resolution [34–36]. By utilizing low-coherence interferometry principles, SD-OCT enables high-definition cross-sectional imaging of tissue microstructures at the micrometer level.

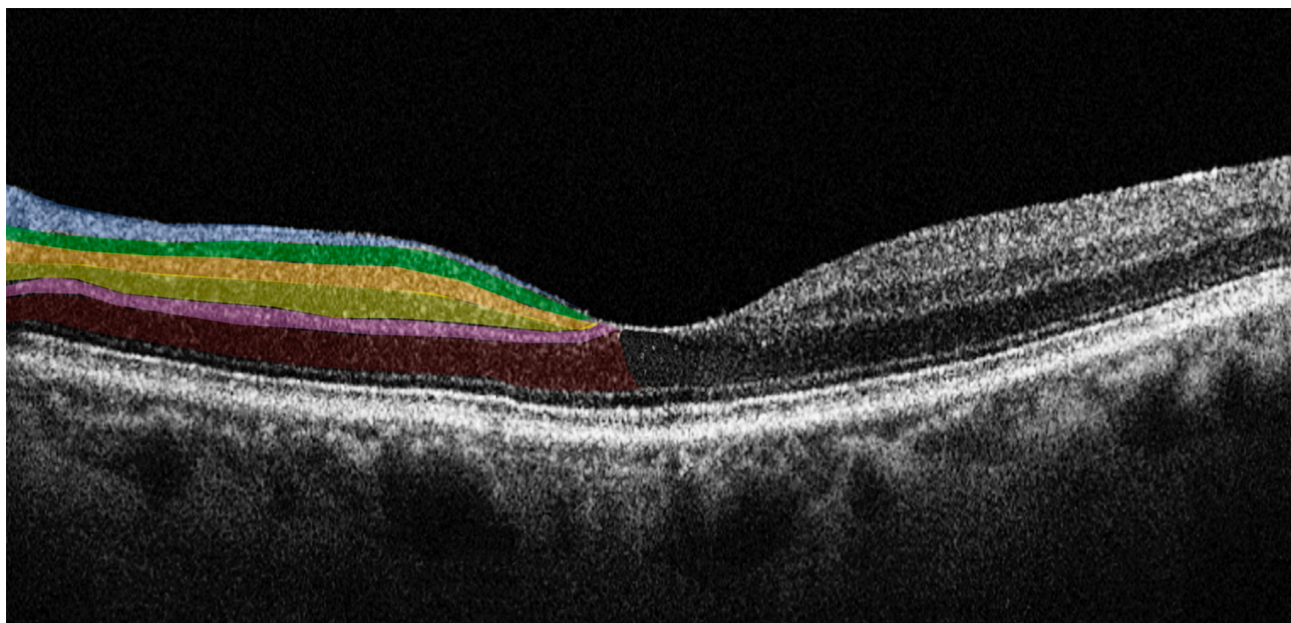


Fig. 1. Horizontal spectral domain optical coherence tomography (SD-OCT) cross-sectional scan passing through the fovea. The various retinal layers are shown with added color overlays on the left side as follows: blue: retinal nerve fiber layer; green: ganglion cell layer; orange: inner plexiform layer; yellow: inner nuclear layer; pink: outer plexiform layer; red: outer nuclear layer. The right side shows original SD-OCT output in scales of grey. Reproduced with permission from Di Pippo M, Fragiotta S, Di Staso F, Scuderi L, Abdolrahimzadeh S. The Role of Alpha-Synuclein Deposits in Parkinson's Disease: A Focus on the Human Retina. *International Journal of Molecular Sciences* 2023; 24: 4391 [8].

In SD-OCT, a broad-spectrum light source is divided into sample and reference arms. The sample arm directs near-infrared light onto the target tissue, while the reference arm establishes a mirrored path [18,37]. The interference between the light from both arms creates an interference pattern, from which time-delay information at various depths within the tissue is extracted. This data is Fourier-transformed to generate depth-resolved A-scans, providing detailed reflectivity profiles of the retinal layers and structures. With its exceptional resolution, SD-OCT allows *in vivo* evaluation of the retina, allowing for the analysis of individual retinal layer thickness and morphology, facilitating the assessment of subtle changes in retinal thickness, detection of abnormalities, and monitoring of disease progression [18,34,38,39].

As for its application in PD research, SD-OCT shows potential in investigating retinal alterations associated with the condition [8]. Some studies reported a reduction in mean RNFL and retinal thickness, particularly in the nasal sector [40]. Additionally, thinning of macular and peripapillary RNFL and diminished macular volumes in para- and perifoveal regions were observed, indicating potential ganglion cell loss and dopaminergic depletion [41,42].

However, not all studies found significant differences in SD-OCT parameters between PD patients and controls. Some studies reported no changes in RNFL and ganglion cell complex (GCC) thickness, suggesting that retinal damage in PD may be challenging to detect with current instru-

mentation [43,44]. In contrast, other studies highlighted thinning of retinal layers and GCC thickness in PD patients [45]. Some discrepancies might be attributed to the varying disease stages of the PD patients included in the studies [45]. Moreover, the presence of α -syn accumulation within the retina and its impact on retinal layers may account for the observed differences [46,47].

It is important to acknowledge that while SD-OCT holds promise as a means to study PD-related retinal changes, its definitive recognition as a diagnostic tool for PD remains an area of active investigation. Continued research and exploration of SD-OCT's capabilities may ultimately lead to its broader integration as a valuable adjunctive method for diagnosing and managing PD and other neurodegenerative conditions.

3.2 Optical Coherence Tomography Angiography (OCTA)

OCTA represents a groundbreaking extension of SD-OCT, allowing non-invasive visualization of the retinal vasculature without needing contrast agents. OCTA leverages the motion contrast of red blood cells to create high-resolution three-dimensional angiograms of the retinal microvasculature. This technique enables the assessment of blood flow within the different retinal layers, including the superficial and deep capillary plexuses, and the choriocapillaris, and may offer insight into the pathophysiological processes of neurodegenerative conditions [19,48–51].

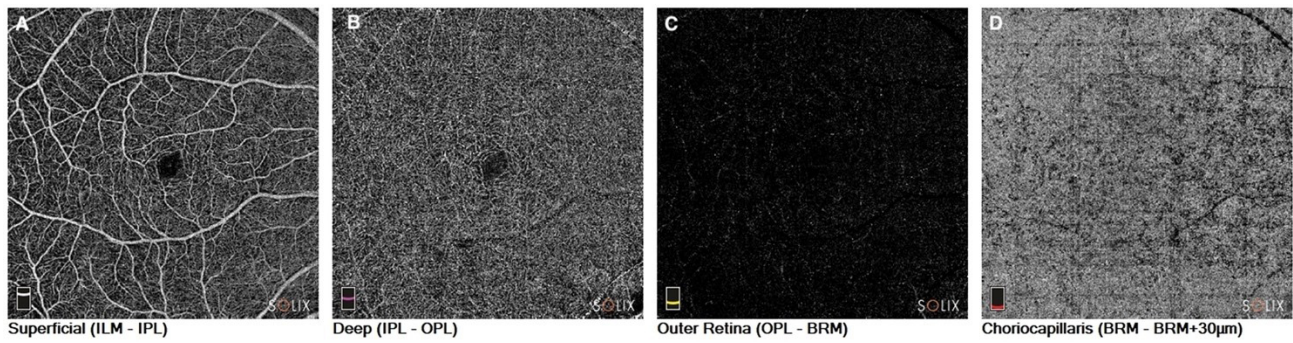


Fig. 2. Optical coherence tomography angiography in a patient with Parkinson's disease. En-face images of the (A). Superficial capillary plexus of the retina. (B) Deep capillary plexus of the retina. (C) Outer retina; and (D) Choriocapillaris. ILM, internal limiting membrane; IPL, inner plexiform layer; OPL, outer plexiform layer; BRM, Bruch's membrane.

OCTA has been instrumental in identifying microvascular changes associated with PD. Studies have reported alterations in retinal vessel density, perfusion, and vascular flow in individuals with PD, suggesting the presence of retinal microvascular abnormalities. This non-invasive imaging method offers advantages in detecting early vascular changes that might be linked to PD pathology, allowing researchers to investigate the potential of retinal vasculature as a biomarker for the disease [20] (Fig. 2).

The first OCTA study in PD patients was carried out by Kwapong *et al.* [52] in 2018. The authors showed a reduction in the retinal vascular density (VD) of the superficial capillary plexus (SCP) and the deep capillary plexus (DCP) compared to healthy subjects, with greater involvement of the SCP than the DCP. Kwapong *et al.* [52] speculated that their results may be justified by the increased accumulation of α -syn in the retinal arterial vessels, which are more represented in the superficial vascular networks [32,52]. In addition, the authors found no correlation between retinal microvascular changes and the disease stage [52]. These results were successively confirmed by Robbins *et al.* [43], who observed a reduction in VD and retinal perfusion density (PFD) in the foveal region in PD patients compared to a control group. The authors also studied the choroid calculating the choroidal vascularity index and observed a statistically significant reduction of this parameter in affected subjects compared to a control group. However, the area under the receiver operating characteristic (AU-ROC) analysis carried out by the authors did not show sufficient discriminatory capacity of the individual parameters to make them independent biomarkers with clear threshold values to diagnose the disease [43].

Shi *et al.* [53] conducted a study of retinal capillary complexity by analyzing the fractal dimension of OCTA images. The authors reported a reduction of the capillary retinal VD, a reduction in the PFD, and a reduction in the complexity of the capillary network in both the SCP and the DCP, with an inverse correlation between the complexity of the SCP and the thickness of the GCL. They also showed a progressive reduction in the complexity of the DCP as the

duration of the disease progressed. The authors highlighted how the loss of capillary complexity, although present in both plexuses, was more represented in the SCP, suggesting that retinal microvascularization in the inner layers of the retina is particularly susceptible and closely related to retinal structural changes due to disease [53].

Xu *et al.* [54] explored the VD of the SCP and the foveal avascular zone (FAZ) in PD patients, dividing them into subgroups according to the Hoehn-Yahr disease stage (H-Y). The authors showed, in line with previous studies, an overall reduction of VD of the SCP in PD patients compared to healthy controls, and a negative correlation between VD and H-Y stage. As for the FAZ, the authors found a significant reduction in patients with stage H-Y I versus healthy controls, suggesting that this parameter could be a more reliable biomarker in identifying early-stage disease [54]. Berkowitz and Patel, and Murueta-Goyena *et al.* [55] also found the same results on the FAZ [56].

From a physiopathological point of view, the mechanism by which intraretinal vascular changes arise has not yet been well clarified. It is known that at cerebral level, together with neuronal degeneration, there is also a degeneration of vascularity, evident in particular at the level of the endothelium of the vessels [57]. Zhang *et al.* [58] evaluated the macular density of the SCP and the thickness of the GCC in patients with PD by comparing it with healthy subjects. The authors showed a reduction of both parameters in affected subjects and a correlation between the two, suggesting a relationship between vascular damage and neuronal damage.

Given the homology between retinal and cerebral microvascularization, concurrent cerebral angiopathy in PD may extend to the retina, resulting in changes to the microvascular network [52]. As for the FAZ, its involvement in PD may be related to its anatomical structure. It is known that the FAZ is an avascular region surrounded by a continuous capillary network. This area is rich in dopaminergic neurons, whose ongoing depletion of PD could stimulate the vasculogenesis of the surrounding continuous capillary network by reducing the size of the FAZ [59].

4. Diagnostic Potential of Retinal Imaging in Parkinson's Disease

The diagnostic potential of retinal imaging in PD has gained significant attention in recent years due to its non-invasive nature and the potential to capture disease-specific retinal changes. Several studies have been conducted to investigate the diagnostic accuracy of various retinal imaging techniques for PD, shedding light on their sensitivity and specificity in distinguishing PD patients from healthy individuals or other neurodegenerative disorders.

SD-OCT has shown findings of thinning in the RNFL and GCL in PD patients compared to healthy controls. The thinning of these layers appears to correlate with disease severity and duration, making SD-OCT a potential tool for monitoring disease progression [60,61].

OCTA studies have revealed alterations in the retinal microvasculature of PD patients, including reduced VD and changes in perfusion patterns. These vascular changes may reflect underlying neurovascular dysfunction in PD and could serve as valuable biomarkers for the disease [52–54].

The sensitivity and specificity of retinal imaging techniques in differentiating PD patients from healthy individuals or other neurodegenerative disorders have varied across studies. While some investigations have reported high sensitivity and specificity, others have shown more modest results [43,62]. SD-OCT has demonstrated relatively good sensitivity and specificity in distinguishing PD patients from healthy controls. The thinning of the RNFL and GCL appears to be a useful marker, although its specificity may be limited by similar findings in other neurodegenerative conditions [63–65]. OCTA sensitivity and specificity in PD diagnosis are still under investigation. While changes in retinal vasculature have been linked to PD, standardization of OCTA protocols and rigorous validation in large and diverse populations are required to establish its diagnostic accuracy conclusively [20,43]. As OCTA is an evolving technology, analysis of images should be performed by expert ophthalmologists in imaging owing to the possible sources of artifacts such as projection artifacts, shadowing artifacts, segmentation errors, and motion artifacts [66–68]. In the context of performing OCTA in PD patients, it is crucial to account for motion artifacts as they can affect image quality. A study by Lauer mann *et al.* [67] shed light on the impact of artifacts and revealed that their frequency is comparable between PD patients and healthy controls. However, within the PD group, longer disease duration and more severe motor symptoms were associated with a higher occurrence of movement artifacts [67]. It is essential to recognize that even in healthy individuals, OCTA imaging can be susceptible to artifacts, including those caused by motion, as supported by this study. Nonetheless, PD is characterized by distinctive motor symptoms like tremors, bradykinesia, and stiffness, along with neuropsychiatric symptoms such as reduced attention control, worsening progressively

as the disease progresses [69]. These factors can significantly impact the quality of OCTA images, making it critical to carefully consider their influence during the analysis and interpretation of results in PD patients.

One of the most promising aspects of retinal imaging in PD is its potential for early detection of the disease. As PD-related retinal changes may precede clinical motor symptoms, retinal imaging could serve as a non-invasive and cost-effective screening tool. Early detection could facilitate timely interventions and possibly slow disease progression [70,71]. Despite the encouraging findings, challenges remain in establishing retinal imaging as a standalone diagnostic tool for PD. Standardization of imaging protocols, large-scale multicenter studies, and validation in diverse populations are essential for establishing robust diagnostic criteria. Moreover, longitudinal studies are needed to evaluate the stability of retinal changes over time and their correlation with disease progression.

Within the realm of PD detection strategies, a salient emphasis rests on the non-motor symptoms, which are progressively being acknowledged as pivotal indicators of the condition. These symptoms often unveil themselves before the overt motor manifestations, carrying paramount diagnostic value. These include mood disorders, such as anxiety and depression; sleep irregularities, especially of the rapid eye movement (REM) phase; cognitive impairment; autonomic dysfunctions; and visual disturbances, particularly changes in contrast sensitivity and in color discrimination [72]. Timely recognition of these symptoms could potentially serve as a formidable arsenal for the early diagnosis of PD.

Diederich *et al.* [73] conducted a study aimed at unraveling the discriminative potential of these non-motor symptoms in identifying incipient forms of PD. Among the diverse parameters scrutinized, the visual deficits, assessed via the Farnsworth-Munsell test for color discrimination and the Pelli-Robson test for contrast sensitivity, emerged as preeminent entities. These visual metrics demonstrated substantial discriminatory ability, characterized by an area under the receiver operating characteristic (ROC) curve of 0.83. Notably, this discrimination efficacy augmented when synergized with the dysautonomia questionnaire scores. Their deduction posited these visual assessments as expeditious screening tools for early PD diagnosis [73].

Subsequent corroboration was provided by Hannaway *et al.* [74] through a prospective study encompassing a 3-year follow-up of 100 PD subjects. Their investigation illuminated the predictive role of the alteration of higher-order visual function in foreseeing outcomes such as dementia onset, mortality, and frailty in PD patients. Intriguingly, a parallel analysis of variations in retinal thicknesses yielded non-statistically significant results. This discrepancy was rationalized by invoking the retrograde propagation model of PD damage, whereby cortical neurodegeneration out-

paces retinal neurodegeneration. While these results offer interesting insights, further in-depth investigations are warranted to unravel the intricate pathogenic underpinnings of this phenomenon [74].

In recent years, retinal imaging has emerged as a promising tool also for monitoring PD progression and evaluating treatment responses. Longitudinal studies utilizing various retinal imaging techniques have provided valuable insights into the dynamic retinal changes associated with PD over time. Additionally, the potential of retinal imaging to assess treatment response and the effectiveness of therapeutic interventions in PD patients has been explored. Longitudinal studies involving retinal imaging have revealed that retinal changes in PD may evolve over time and correlate with disease severity and duration [75,76]. Garcia-Martin *et al.* [75] in a longitudinal SD-OCT study demonstrated progressive thinning of the RNFL and GCL in PD patients, suggesting ongoing neurodegeneration. However, challenges remain, and further research is needed to fully utilize retinal imaging as a reliable monitoring tool in PD.

Assessing treatment response is crucial for evaluating the efficacy of therapeutic interventions in PD. Longitudinal studies using retinal imaging have explored the impact of dopaminergic medications on retinal changes in PD. In a research endeavor by Normando *et al.* [77], an investigation was undertaken into the retinal and cerebral modifications in rodent models of PD induced by rotenone. The study traced the changes in the retina and brain, employing sophisticated imaging techniques encompassing detection of retinal cells in apoptosis (DARC) and OCT. The findings revealed that the alterations in the retina, as discerned through these imaging modalities, manifested approximately 40 days prior to the histological transformations observed in the cerebral region. Subsequent therapeutic intervention employing the liposomal formulation of prolonged-release rosiglitazone yielded noteworthy outcomes. The neuroprotective effects of this therapy manifested initially in retinal cells and subsequently extended to impact the nigrostriatal neurons [77].

However, the long-term effects of dopaminergic therapy on retinal changes are still under investigation [62,76,78].

5. Limitations and Considerations

The incorporation of retinal imaging in PD, both regarding research and clinical evaluation, is a burgeoning field with significant potential, yet it is crucial to acknowledge and address the inherent limitations and challenges of this methodology. Ensuring the reliability and validity of retinal imaging findings in PD necessitates a thorough understanding of the factors influencing data acquisition, analysis, and interpretation of its use as a diagnostic and monitoring instrument [8,43,79].

A significant obstacle in retinal imaging research is the heterogeneity in image acquisition protocols and analysis techniques across different studies and imaging platforms. This lack of standardization can result in inconsistent findings and impede direct comparisons between studies. Factors such as imaging device settings, operator expertise, and patient cooperation during image capture can introduce variability [80]. Efforts are being made to establish standardized imaging protocols and develop automated image analysis algorithms to reduce inter-operator variability. Collaborative initiatives among research centers can facilitate the sharing of imaging data and validate findings across diverse patient populations[80].

Furthermore, it is crucial to emphasize that PD diagnosis currently relies on clinical criteria established by the International Parkinson Disease and Movement Disorder Society, exhibiting an accuracy surpassing 90%. Within this context, retinal imaging does not confer supplementary diagnostic insights compared to the existing gold standard. Conversely, its potential utility emerges in the early diagnostic phase, prior to the complete manifestation of all distinctive symptoms [81].

In PD research, it is imperative to account for confounding factors that may influence retinal imaging outcomes. Age, for instance, can affect various retinal parameters, and given that PD is predominantly a disease of the elderly, age-related changes are an important consideration. Additionally, the presence of other systemic comorbidities, such as hypertension or diabetes, or ocular comorbidity, such as age-related macular degeneration and glaucoma, can influence retinal vasculature and thickness measurements [35,82–85].

6. Conclusions

In recent years, retinal imaging has emerged as a promising non-invasive tool for investigating PD. Studies utilizing various retinal imaging techniques, such as SD-OCT and OCTA, have provided valuable insights into the structural and functional changes that occur in the retina in PD.

Key findings include thinning of the RNFL, alterations in retinal vasculature, and changes in RGCs. These retinal changes show correlations with disease severity and motor symptoms, suggesting the potential of retinal imaging as a biomarker for PD.

The future potential of retinal imaging in PD research and clinical practice is significant. Incorporating retinal imaging into routine assessments could aid in early PD detection, differential diagnosis from other neurodegenerative disorders, and monitoring disease progression. Moreover, retinal imaging may also facilitate the evaluation of treatment responses and the effectiveness of therapeutic interventions. This non-invasive and accessible approach to PD assessment could offer several advantages, including cost-effectiveness, patient acceptance, and the possibility of re-

mote monitoring through telemedicine platforms. With the potential to identify retinal biomarkers and enable personalized medicine, retinal imaging holds promise for transforming PD management in the coming years.

While retinal imaging shows great promise, further research is essential to validate and establish standardized protocols for its clinical utility in PD management. Collaborative efforts among researchers, clinicians, and technologists are crucial to refine imaging techniques, optimize data analysis, and ensure reproducibility of results.

Longitudinal studies are needed to better understand the temporal relationship between retinal changes and PD progression. Additionally, large-scale multi-center trials should be conducted to validate the sensitivity and specificity of retinal imaging in distinguishing PD from other conditions and to identify its potential in tracking disease progression. With continued advancements in imaging technology and data analysis, retinal imaging may soon become an integral part of comprehensive PD assessment, offering improved patient outcomes and enhancing our understanding of this complex neurodegenerative disorder.

Author Contributions

MDP and SA designed the research study. MDP, SDA, FR, CC, DF and SA performed the research. MDP, SDA, FR, CC, DF and SA analyzed the data. MDP, SDA, FR, CC, DF and SA drafted the manuscript. MDP and SA prepared the final version of the manuscript. MDP and SA carried out the review for critical intellectual content. All authors contributed to editorial changes in the manuscript. All authors read and approved the final manuscript. All authors have participated sufficiently in the work and agreed to be accountable for all aspects of the work.

Ethics Approval and Consent to Participate

Not applicable.

Acknowledgment

Not applicable.

Funding

This research received no external funding.

Conflict of Interest

The authors declare no conflict of interest.

References

- [1] Lees AJ, Hardy J, Revesz T. Parkinson's disease. *Lancet*. 2009; 373: 2055–2066.
- [2] Tolosa E, Garrido A, Scholz SW, Poewe W. Challenges in the diagnosis of Parkinson's disease. *The Lancet. Neurology*. 2021; 20: 385–397.
- [3] Jankovic J. Parkinson's disease: clinical features and diagnosis. *Journal of Neurology, Neurosurgery, and Psychiatry*. 2008; 79: 368–376.
- [4] Li T, Le W. Biomarkers for Parkinson's Disease: How Good Are They? *Neuroscience Bulletin*. 2020; 36: 183–194.
- [5] Chaudhuri KR, Odin P, Antonini A, Martinez-Martin P. Parkinson's disease: the non-motor issues. *Parkinsonism & Related Disorders*. 2011; 17: 717–723.
- [6] Goldman JG, Postuma R. Premotor and nonmotor features of Parkinson's disease. *Current Opinion in Neurology*. 2014; 27: 434–441.
- [7] Alves JN, Westner BU, Højlund A, Weil RS, Dalal SS. Structural and functional changes in the retina in Parkinson's disease. *Journal of Neurology, Neurosurgery, and Psychiatry*. 2023; 94: 448–456.
- [8] Di Pippo M, Fragiotta S, Di Staso F, Scuderi L, Abdolrahimzadeh S. The Role of Alpha-Synuclein Deposits in Parkinson's Disease: A Focus on the Human Retina. *International Journal of Molecular Sciences*. 2023; 24: 4391.
- [9] Silverstein SM, Demmin DL, Schallek JB, Fradkin SI. Measures of Retinal Structure and Function as Biomarkers in Neurology and Psychiatry. *Biomarkers in Neuropsychiatry*. 2020; 2: 100018.
- [10] Kashani AH, Asanad S, Chan JW, Singer MB, Zhang J, Sharifi M, *et al.* Past, present and future role of retinal imaging in neurodegenerative disease. *Progress in Retinal and Eye Research*. 2021; 83: 100938.
- [11] Snyder PJ, Alber J, Alt C, Bain LJ, Bouma BE, Bouwman FH, *et al.* Retinal imaging in Alzheimer's and neurodegenerative diseases. *Alzheimer's & Dementia: the Journal of the Alzheimer's Association*. 2021; 17: 103–111.
- [12] London A, Benhar I, Schwartz M. The retina as a window to the brain—from eye research to CNS disorders. *Nature Reviews. Neurology*. 2013; 9: 44–53.
- [13] Pless ML. The eye as a window to the brain. *Annals of the Academy of Medicine, Singapore*. 2023; 52: 60–61.
- [14] Srinivasan S, Efron N. Optical coherence tomography in the investigation of systemic neurologic disease. *Clinical & Experimental Optometry*. 2019; 102: 309–319.
- [15] Abdolrahimzadeh S, Felli L, Plateroti AM, Perdicchi A, Contestabile MT, Recupero SM. SPECTRAL DOMAIN OPTICAL COHERENCE TOMOGRAPHY EVIDENCE OF RETINAL NERVE FIBER LAYER AND GANGLION CELL LOSS IN ADULT PATIENTS WITH NEUROFIBROMATOSIS TYPE 1. *Retina*. 2016; 36: 75–81.
- [16] Wang F, Zhong W, Yang Q, Zhao W, Liu X, Rao B, *et al.* Distribution and synaptic organization of substance P-like immunoreactive neurons in the mouse retina. *Brain Structure & Function*. 2023. (online ahead of print)
- [17] Móvio MI, de Lima-Vasconcellos TH, Dos Santos GB, Echeverry MB, Colombo E, Mattos LS, *et al.* Retinal organoids from human-induced pluripotent stem cells: From studying retinal dystrophies to early diagnosis of Alzheimer's and Parkinson's disease. *Seminars in Cell & Developmental Biology*. 2023; 144: 77–86.
- [18] Spaide RF, Koizumi H, Pozzoni MC. Enhanced depth imaging spectral-domain optical coherence tomography. *American Journal of Ophthalmology*. 2008; 146: 496–500.
- [19] Spaide RF, Fujimoto JG, Waheed NK, Sadda SR, Staurengi G. Optical coherence tomography angiography. *Progress in Retinal and Eye Research*. 2018; 64: 1–55.
- [20] Zou J, Liu K, Li F, Xu Y, Shen L, Xu H. Combination of optical coherence tomography (OCT) and OCT angiography increases diagnostic efficacy of Parkinson's disease. *Quantitative Imaging in Medicine and Surgery*. 2020; 10: 1930–1939.
- [21] Zhang Y, Zhang X, Yue Y, Tian T. Retinal Degeneration: A Window to Understand the Origin and Progression of Parkinson's Disease? *Frontiers in Neuroscience*. 2022; 15: 799526.
- [22] Mohana Devi S, Mahalaxmi I, Aswathy NP, Dhivya V, Bal-

- achandar V. Does retina play a role in Parkinson's Disease? *Acta Neurologica Belgica*. 2020; 120: 257–265.
- [23] Mahabadi N, Al Khalili Y. *Neuroanatomy, Retina*. StatPearls Publishing: StatPearls, Treasure Island (FL). 2023.
- [24] López-Cuenca I, Marcos-Dolado A, Yus-Fuertes M, Salobar-García E, Elvira-Hurtado L, Fernández-Albarral JA, *et al*. The relationship between retinal layers and brain areas in asymptomatic first-degree relatives of sporadic forms of Alzheimer's disease: an exploratory analysis. *Alzheimer's Research & Therapy*. 2022; 14: 79.
- [25] Martínez-Navarrete GC, Martín-Nieto J, Esteve-Rudd J, Angulo A, Cuenca N. Alpha synuclein gene expression profile in the retina of vertebrates. *Molecular Vision*. 2007; 13: 949–961.
- [26] Surguchov A, McMahan B, Masliah E, Surgucheva I. Synucleins in ocular tissues. *Journal of Neuroscience Research*. 2001; 65: 68–77.
- [27] Lewy Bodies. StatPearls - NCBI Bookshelf n.d. Available at: <https://www.ncbi.nlm.nih.gov/books/NBK536956/> (Accessed: 1 August 2023).
- [28] Beach TG, Carew J, Serrano G, Adler CH, Shill HA, Sue LI, *et al*. Phosphorylated α -synuclein-immunoreactive retinal neuronal elements in Parkinson's disease subjects. *Neuroscience Letters*. 2014; 571: 34–38.
- [29] Mammadova N, Summers CM, Kokemuller RD, He Q, Ding S, Baron T, *et al*. Accelerated accumulation of retinal α -synuclein (pSer129) and tau, neuroinflammation, and autophagic dysregulation in a seeded mouse model of Parkinson's disease. *Neurobiology of Disease*. 2019; 121: 1–16.
- [30] Peng X, Tehrani R, Dietrich P, Stefanis L, Perez RG. Alpha-synuclein activation of protein phosphatase 2A reduces tyrosine hydroxylase phosphorylation in dopaminergic cells. *Journal of Cell Science*. 2005; 118: 3523–3530.
- [31] Bodis-Wollner I, Kozlowski PB, Glazman S, Miri S. α -synuclein in the inner retina in parkinson disease. *Annals of Neurology*. 2014; 75: 964–966.
- [32] Price DL, Rockenstein E, Mante M, Adame A, Overk C, Spencer B, *et al*. Longitudinal live imaging of retinal α -synuclein::GFP deposits in a transgenic mouse model of Parkinson's Disease/Dementia with Lewy Bodies. *Scientific Reports*. 2016; 6: 29523.
- [33] Ortuño-Lizarán I, Beach TG, Serrano GE, Walker DG, Adler CH, Cuenca N. Phosphorylated α -synuclein in the retina is a biomarker of Parkinson's disease pathology severity. *Movement Disorders: Official Journal of the Movement Disorder Society*. 2018; 33: 1315–1324.
- [34] Staurengi G, Sada S, Chakravarthy U, Spaide RF. International Nomenclature for Optical Coherence Tomography (IN•OCT) Panel. Proposed lexicon for anatomic landmarks in normal posterior segment spectral-domain optical coherence tomography: the IN•OCT consensus. *Ophthalmology*. 2014; 121: 1572–1578.
- [35] Castillo MM, Mowatt G, Lois N, Elders A, Fraser C, Amoaku W, *et al*. Optical coherence tomography for the diagnosis of neovascular age-related macular degeneration: a systematic review. *Eye (London, England)*. 2014; 28: 1399–1406.
- [36] Abdolrahimzadeh S, Di Pippo M, Sordi E, Zweifel SA. Inner Retinal Layer Thickness Alterations in Early Age Related Macular Degeneration in Eyes with Subretinal Drusenoid Deposits or Conventional Drusen. *Journal of Clinical Medicine*. 2021; 10: 5136.
- [37] Aumann S, Donner S, Fischer J, Müller F. Optical Coherence Tomography (OCT): Principle and Technical Realization. *High Resolution Imaging in Microscopy and Ophthalmology: New Frontiers in Biomedical Optics*. 2019; 59–85.
- [38] Mrejen S, Spaide RF. Optical coherence tomography: imaging of the choroid and beyond. *Survey of Ophthalmology*. 2013; 58: 387–429.
- [39] Abdolrahimzadeh S, Fragiotta S, Ciacimino C, Di Pippo M, Scuderi G. Choroidal Vascularity Index in Adult-Onset Foveomacular Vitelliform Dystrophy: A Pilot Study. *Applied Sciences*. 2021; 11: 10487.
- [40] Aydin TS, Umit D, Nur OM, Fatih U, Asena K, Nefise OY, *et al*. Optical coherence tomography findings in Parkinson's disease. *The Kaohsiung Journal of Medical Sciences*. 2018; 34: 166–171.
- [41] Sengupta P, Dutta K, Ghosh S, Mukherjee A, Pal S, Basu D. Optical Coherence Tomography Findings in Patients of Parkinson's Disease: An Indian Perspective. *Annals of Indian Academy of Neurology*. 2018; 21: 150–155.
- [42] Rascunà C, Russo A, Terravecchia C, Castellino N, Avitabile T, Bonfiglio V, *et al*. Retinal Thickness and Microvascular Pattern in Early Parkinson's Disease. *Frontiers in Neurology*. 2020; 11: 533375.
- [43] Robbins CB, Thompson AC, Bhullar PK, Koo HY, Agrawal R, Soundararajan S, *et al*. Characterization of Retinal Microvascular and Choroidal Structural Changes in Parkinson Disease. *JAMA Ophthalmology*. 2021; 139: 182–188.
- [44] Yıldız D, Pekel NB, Yener NP, Seferoğlu M, Günes A, Sığırlı D. Assessment of Neurodegeneration by Optical Coherence Tomography and Mini-Mental Test in Parkinson's Disease. *Annals of Indian Academy of Neurology*. 2019; 22: 212–216.
- [45] Batum M, Ak AK, Ari MS, Mayali H, Kurt E, Selçuki D. Evaluation of the visual system with visual evoked potential and optical coherence tomography in patients with idiopathic Parkinson's disease and with multiple system atrophy. *Documenta Ophthalmologica. Advances in Ophthalmology*. 2022; 145: 99–112.
- [46] Unlu M, Gulmez Sevim D, Gultekin M, Karaca C. Correlations among multifocal electroretinography and optical coherence tomography findings in patients with Parkinson's disease. *Neurological Sciences: Official Journal of the Italian Neurological Society and of the Italian Society of Clinical Neurophysiology*. 2018; 39: 533–541.
- [47] Chorostecki J, Seraji-Bozorgzad N, Shah A, Bao F, Bao G, George E, *et al*. Characterization of retinal architecture in Parkinson's disease. *Journal of the Neurological Sciences*. 2015; 355: 44–48.
- [48] Jia Y, Tan O, Tokayer J, Potsaid B, Wang Y, Liu JJ, *et al*. Split-spectrum amplitude-decorrelation angiography with optical coherence tomography. *Optics Express*. 2012; 20: 4710–4725.
- [49] Spaide RF, Klancnik JM, Jr, Cooney MJ. Retinal vascular layers imaged by fluorescein angiography and optical coherence tomography angiography. *JAMA Ophthalmology*. 2015; 133: 45–50.
- [50] Pellegrini M, Vagge A, Ferro Desideri LF, Bernabei F, Triolo G, Mastropasqua R, *et al*. Optical Coherence Tomography Angiography in Neurodegenerative Disorders. *Journal of Clinical Medicine*. 2020; 9: 1706.
- [51] Di Pippo M, Cipollini V, Giubilei F, Scuderi G, Abdolrahimzadeh S. Retinal and Choriocapillaris Vascular Changes in Early Alzheimer Disease Patients Using Optical Coherence Tomography Angiography. *Journal of Neuro-ophthalmology: the Official Journal of the North American Neuro-Ophthalmology Society*. 2023. (online ahead of print)
- [52] Kwapong WR, Ye H, Peng C, Zhuang X, Wang J, Shen M, *et al*. Retinal Microvascular Impairment in the Early Stages of Parkinson's Disease. *Investigative Ophthalmology & Visual Science*. 2018; 59: 4115–4122.
- [53] Shi C, Chen Y, Kwapong WR, Tong Q, Wu S, Zhou Y, *et al*. CHARACTERIZATION BY FRACTAL DIMENSION ANALYSIS OF THE RETINAL CAPILLARY NETWORK IN PARKINSON DISEASE. *Retina (Philadelphia, Pa.)*. 2020; 40: 1483–1491.
- [54] Xu B, Wang X, Guo J, Xu H, Tang B, Jiao B, *et al*. Retinal Mi-

crovascular Density Was Associated With the Clinical Progression of Parkinson's Disease. *Frontiers in Aging Neuroscience*. 2022; 14: 818597.

- [55] Murueta-Goyena A, Barrenechea M, Erramuzpe A, Teijeira-Portas S, Pengo M, Ayala U, *et al*. Foveal Remodeling of Retinal Microvasculature in Parkinson's Disease. *Frontiers in Neuroscience*. 2021; 15: 708700.
- [56] Berkowitz S, Patel S. Pilot study for neurological and retinal imaging as biomarkers for Parkinson's disease using optical coherence tomography-angiography. *Investigative Ophthalmology & Visual Science*. 2020; 61: 4831.
- [57] Guan J, Pavlovic D, Dalkie N, Waldvogel HJ, O'Carroll SJ, Green CR, *et al*. Vascular degeneration in Parkinson's disease. *Brain Pathology (Zurich, Switzerland)*. 2013; 23: 154–164.
- [58] Zhang L, Zhuang C, Wang Y, Wang H, Cui G, Guo J. Clinical Observation of Macular Superficial Capillary Plexus and Ganglion Cell Complex in Patients with Parkinson's Disease. *Ophthalmic Research*. 2023. (online ahead of print)
- [59] Miri S, Shrier EM, Glazman S, Ding Y, Selesnick I, Kozlowski PB, *et al*. The avascular zone and neuronal remodeling of the fovea in Parkinson disease. *Annals of Clinical and Translational Neurology*. 2015; 2: 196–201.
- [60] Satue M, Obis J, Alarcia R, Orduna E, Rodrigo MJ, Vilades E, *et al*. Retinal and Choroidal Changes in Patients with Parkinson's Disease Detected by Swept-Source Optical Coherence Tomography. *Current Eye Research*. 2018; 43: 109–115.
- [61] Polo V, Satue M, Rodrigo MJ, Otin S, Alarcia R, Bambo MP, *et al*. Visual dysfunction and its correlation with retinal changes in patients with Parkinson's disease: an observational cross-sectional study. *BMJ Open*. 2016; 6: e009658.
- [62] Young JB, Godara P, Williams V, Summerfelt P, Connor TB, Tarima S, *et al*. Assessing Retinal Structure in Patients with Parkinson's Disease. *Journal of Neurology & Neurophysiology*. 2019; 10: 485.
- [63] Cipollini V, Abdolrahimzadeh S, Troili F, De Carolis A, Calafiore S, Scuderi L, *et al*. Neurocognitive Assessment and Retinal Thickness Alterations in Alzheimer Disease: Is There a Correlation? *Journal of Neuro-ophthalmology: the Official Journal of the North American Neuro-Ophthalmology Society*. 2020; 40: 370–377.
- [64] Hajee ME, March WF, Lazzaro DR, Wolintz AH, Shrier EM, Glazman S, *et al*. Inner retinal layer thinning in Parkinson disease. *Archives of Ophthalmology (Chicago, Ill.: 1960)*. 2009; 127: 737–741.
- [65] Mwanza JC, Oakley JD, Budenz DL, Chang RT, Knight OJ, Feuer WJ. Macular ganglion cell-inner plexiform layer: automated detection and thickness reproducibility with spectral domain-optical coherence tomography in glaucoma. *Investigative Ophthalmology & Visual Science*. 2011; 52: 8323–8329.
- [66] Borrelli E, Sarraf D, Freund KB, Sadda SR. OCT angiography and evaluation of the choroid and choroidal vascular disorders. *Progress in Retinal and Eye Research*. 2018; 67: 30–55.
- [67] Lauermann JL, Sochurek JAM, Plöttner P, Alten F, Kasten M, Prasuhn J, *et al*. Applicability of optical coherence tomography angiography (OCTA) imaging in Parkinson's disease. *Scientific Reports*. 2021; 11: 5520.
- [68] Abdolrahimzadeh S, Zweifel SA, Di Pippo M, Bajka A, Scuderi G, Lotery AJ. Central macular choriocapillaris impairment as a manifestation of microvascular disease in eyes with subretinal drusenoid deposits. *Eye (London, England)*. 2023. (online ahead of print)
- [69] Xia R, Mao ZH. Progression of motor symptoms in Parkinson's disease. *Neuroscience Bulletin*. 2012; 28: 39–48.
- [70] Archibald NK, Clarke MP, Mosimann UP, Burn DJ. Visual symptoms in Parkinson's disease and Parkinson's disease dementia. *Movement Disorders: Official Journal of the Movement Disorder Society*. 2011; 26: 2387–2395.
- [71] Shafiee K, Iranmanesh F, Sharifi A, Saliminy N, Dehesh T. The Retinal Nerve Fiber Layer Thickness is Related to Severity of Parkinson's Disease. *Journal of Kerman University of Medical Sciences*. 2019; 26: 479–487.
- [72] Chaudhuri KR, Schapira AHV. Non-motor symptoms of Parkinson's disease: dopaminergic pathophysiology and treatment. *The Lancet. Neurology*. 2009; 8: 464–474.
- [73] Diederich NJ, Pieri V, Hipp G, Rufra O, Blyth S, Vaillant M. Discriminative power of different nonmotor signs in early Parkinson's disease. A case-control study. *Movement Disorders: Official Journal of the Movement Disorder Society*. 2010; 25: 882–887.
- [74] Hannaway N, Zarkali A, Leyland LA, Bremner F, Nicholas JM, Wagner SK, *et al*. Visual dysfunction is a better predictor than retinal thickness for dementia in Parkinson's disease. *Journal of Neurology, Neurosurgery, and Psychiatry*. 2023; 94: 742–750.
- [75] Garcia-Martin E, Larrosa JM, Polo V, Satue M, Marques ML, Alarcia R, *et al*. Distribution of retinal layer atrophy in patients with Parkinson disease and association with disease severity and duration. *American Journal of Ophthalmology*. 2014; 157: 470–478.e2.
- [76] Mailankody P, Battu R, Lenka A, Mohammed Shereef PM, Thennarasu K, Yadav R, *et al*. Retinal Changes in Parkinson's Disease: A Longitudinal Follow-up Study. *Neurology India*. 2022; 70: 1149–1153.
- [77] Normando EM, Davis BM, De Groef L, Nizari S, Turner LA, Ravindran N, *et al*. The retina as an early biomarker of neurodegeneration in a rotenone-induced model of Parkinson's disease: evidence for a neuroprotective effect of rosiglitazone in the eye and brain. *Acta Neuropathologica Communications*. 2016; 4: 86.
- [78] MacGillivray TJ, Trucco E, Cameron JR, Dhillon B, Houston JG, van Beek EJR. Retinal imaging as a source of biomarkers for diagnosis, characterization and prognosis of chronic illness or long-term conditions. *The British Journal of Radiology*. 2014; 87: 20130832.
- [79] Deng Y, Jie C, Wang J, Liu Z, Li Y, Hou X. Evaluation of retina and microvascular changes in the patient with Parkinson's disease: A systematic review and meta-analysis. *Frontiers in Medicine*. 2022; 9: 957700.
- [80] Sampson DM, Dubis AM, Chen FK, Zawadzki RJ, Sampson DD. Towards standardizing retinal optical coherence tomography angiography: a review. *Light, Science & Applications*. 2022; 11: 63.
- [81] Hamedani AG. Deep Learning, the Retina, and Parkinson Disease. *JAMA Ophthalmology*. 2023. (online ahead of print)
- [82] Sun Z, Yang D, Tang Z, Ng DS, Cheung CY. Optical coherence tomography angiography in diabetic retinopathy: an updated review. *Eye (London, England)*. 2021; 35: 149–161.
- [83] Bussel II, Wollstein G, Schuman JS. OCT for glaucoma diagnosis, screening and detection of glaucoma progression. *The British Journal of Ophthalmology*. 2014; 98: ii15–ii19.
- [84] Di Pippo M, Ciancimino C, Scuderi L, Perdicchi A. An Iconic Case of Pigmentary Glaucoma: Brief Review of the Literature. *Case Reports in Ophthalmology*. 2020; 11: 377–384.
- [85] Perdicchi A, Peluso G, Iacovello D, Balestrieri M, Delle Fave M, Abdolrahimzadeh S, *et al*. Ganglion Cell Complex Evaluation in Exudative Age-Related Macular Degeneration after Repeated Intravitreal Injections of Ranibizumab. *BioMed Research International*. 2015; 2015: 268796.