

Laparoscopic appendectomy, stump closure and endoloops: A meta-analysis

Noemi Zorzetti, Augusto Lauro, Maria Irene Bellini, Samuele Vaccari, Barbara Dalla Via, Maurizio Cervellera, Roberto Cirocchi, Salvatore Sorrenti, Vito D'Andrea, Valeria Tonini

Specialty type: Gastroenterology and hepatology

Provenance and peer review: Invited article; Externally peer reviewed

Peer-review model: Single blind

Peer-review report's scientific quality classification

Grade A (Excellent): A
Grade B (Very good): B
Grade C (Good): C
Grade D (Fair): D, D
Grade E (Poor): 0

P-Reviewer: Hori T, Japan; Li J, China; Ni X, China; Saif U, China

Received: April 21, 2022

Peer-review started: April 21, 2022

First decision: July 14, 2022

Revised: July 22, 2022

Accepted: August 19, 2022

Article in press: August 19, 2022

Published online: September 27, 2022



Noemi Zorzetti, Department of General Surgery, Ospedale Civile A Costa, Porretta Terme 40046, Italy

Noemi Zorzetti, Augusto Lauro, Maria Irene Bellini, Samuele Vaccari, Salvatore Sorrenti, Vito D'Andrea, Department of Surgical Sciences, Sapienza University, Rome 00161, Italy

Samuele Vaccari, Department of General Surgery, Ospedale di Bentivoglio, Bologna 40010, Italy

Barbara Dalla Via, Valeria Tonini, Department of Emergency Surgery, St Orsola University Hospital, Bologna 40138, Italy

Maurizio Cervellera, Department of General Surgery, Ospedale Santissima Annunziata, Taranto 74121, Italy

Roberto Cirocchi, Department of General Surgery, Ospedale di Terni, Università di Perugia, Terni 05100, Italy

Corresponding author: Maria Irene Bellini, MD, PhD, Assistant Professor, Senior Lecturer, Department of Surgical Sciences, Sapienza University, Viale Regina Elena, Rome 00161, Italy. mariairene.bellini@uniroma1.it

Abstract

BACKGROUND

Acute appendicitis (AA) is one of the main indications for urgent surgery. Laparoscopic appendectomy (LA) has shown advantages in terms of clinical results and cost-effectiveness, even if there is still controversy about different devices to utilize, especially with regards to the endloop (EL) *vs* endostapler (ES) when it comes to stump closure.

AIM

To compare safety and cost-effectiveness of EL *vs* ES.

METHODS

From a prospectively maintained database, data of 996 consecutive patients treated by LA with a 3 years-follow up in the department of Emergency General Surgery - St Orsola University Hospital, Bologna (Italy) were retrieved. A meta-analysis was performed in terms of surgical complications, in comparison to the

international literature published from 1995 to 2021.

RESULTS

The meta-analysis showed no evidence regarding wound infections, abdominal abscesses, and total post-operative complications, in terms of superiority of a surgical technique for the stump closure in LA.

CONCLUSION

Even when AA is complicated, the routine use of EL is safe in most patients.

Key Words: Acute appendicitis; Laparoscopic appendectomy; Endoloops; Stapler; Post-operative complications

©The Author(s) 2022. Published by Baishideng Publishing Group Inc. All rights reserved.

Core Tip: Stump closure in the acute appendectomy setting could be performed *via* endoloop (EL) or endostapler use. The present meta-analysis assesses the experience of 996 patients consecutively treated in the department of Emergency General Surgery - St Orsola University Hospital, Bologna (Italy) and the evidence published in literature, confirming there is no superiority of a surgical method on how to perform the stump closure, with regards to wound infections, abdominal abscess, and total post-operative complications. Even when acute appendicitis is complicated, the routine use of EL is safe in most patients.

Citation: Zorzetti N, Lauro A, Bellini MI, Vaccari S, Dalla Via B, Cervellera M, Ciocchi R, Sorrenti S, D'Andrea V, Tonini V. Laparoscopic appendectomy, stump closure and endoloops: A meta-analysis. *World J Gastrointest Surg* 2022; 14(9): 1060-1071

URL: <https://www.wjgnet.com/1948-9366/full/v14/i9/1060.htm>

DOI: <https://dx.doi.org/10.4240/wjgs.v14.i9.1060>

INTRODUCTION

Acute appendicitis (AA) is one of the most frequent causes of acute abdominal pain and access to emergency care department. The lifetime chance of developing AA is lower in women, and the risk of being subject to surgery is higher in males[1], representing in fact one of the main indications for an urgent operation. Surgery is generally performed *via* a laparoscopic approach, and given the high volume of AA procedures worldwide, it represents a training operation as well[2].

Laparoscopic appendectomy (LA)[3,4] is demonstrated to be superior in terms of clinical results[5-9] and cost-effectiveness[10-14], even if there is still controversy[15-19] about the use of different devices during the operation[20-24]. Currently, it is still debated the use of endostapler (ES) *vs* endoloop (EL) in appendiceal stump closure[25-28]. The routine use of EL is safe in most patients affected by AA, also when it is complicated[29-32], representing a cost-effective device when taking into consideration the additional costs of potential post-operative complications, too[33-37]. We have previously shown money saving as well as the safety of the routine use of ELs[38]. The aim of this study is to meta-analyze the international literature, to compare the outcome of the patients laparoscopically treated in Bologna *via* EL to the data from the international literature.

MATERIALS AND METHODS

Between November 2011 and January 2018, a total of 1045 LAs were performed in the department of Emergency General Surgery - St Orsola University Hospital, Bologna (Italy). Patients who undergone LA until January 2018 were identified retrospectively from a prospectively maintained database, so that a 3-year follow-up was achieved[39,40]. All grades of post-operative complications were collected and examined. Institutional review board for this study was not required, as this is a meta-analysis of already previous published data. At Bologna centre, patients were initially evaluated by a general surgeon, then underwent laboratory tests, and Alvarado or appendicitis inflammatory response (AIR) score (Table 1) were calculated in females and in males respectively[41,42].

Surgery

Surgical procedures were performed by attendants or supervised trainees. Written informed consent

Table 1 Alvarado and appendicitis inflammatory response score

	Alvarado score	AIR score
Likely appendicitis	7-10	9-12
Probably appendicitis	5-6	5-8
Unlikely appendicitis	0-4	0-4

AIR: Appendicitis inflammatory response.

was signed by all the patients before the procedures. Antibiotic prophylaxis was always administered. A supraumbilical 12 mm-Hasson trocar with an open approach was adopted to induce pneumoperitoneum and initiate laparoscopy. Then, 2 other operative trocars were placed in the left flank (10 mm) and suprapubic position (5 mm), with identification of the appendix, cut and coagulation of the mesoappendix.

EL or ES use

The choice of EL *vs* ES to close the base of the appendiceal stump was made by the operating surgeon, after evaluating the inflammatory infiltration of the appendicular base[43]. If an EL was used, the appendicular stump was cut 3-5 mm away from cecum. The surgical specimen was then removed in an endobag through the 12 mm trocar.

Bologna cohort

Patients were divided in two groups (EL and ES) and in three categories (edematous, phlegmonous and gangrenous appendicitis) based on the severity of the histological examination. Cases requiring conversion to open appendectomy were excluded, while 996 LA (95.3%) were included in the meta-analysis.

Meta-analysis

A meta-analysis was performed in terms of surgical complications, comparing the clinical data of the EL group (821 patients) to the international literature retrieved by Pubmed (Figure 1), according to the PRISMA principles[44].

Inclusion and exclusion criteria

Manuscripts were excluded from the analysis if they dealt with pediatric patients (< 15 years of age) or were published before 1995.

Statistical analysis

Data were collected and analyzed with MedCalc software. Statistical expertise was available to the authors. MedCalc 13.0.6.0 (MedCalc Software bvba, Østend, Belgium) was used for the meta-analysis. MedCalc uses a Freeman-Tukey transformation (arcsine square root transformation) to calculate the weighted summary proportion under the fixed and random effects model. The program lists the proportions (expressed as a percentage), with their 95% confidence interval (CI), found in the individual studies included in the meta-analysis. The heterogeneity was evaluated by means of statistics Cochran's Q and I². The results of the different studies, with 95%CI, and the pooled proportions with 95%CI are shown in a forest plot. Bias was detected using a funnel plot. Publication bias results in asymmetry of the funnel plot. $P < 0.05$ was considered statistically significant.

RESULTS

Meta-analysis of clinical outcome in EL patients and comparative results

The sample of our study consisted of all our patients treated with EL for a total of eight hundred twenty-one patients (Table 2), corresponding to the 78.5% of all LAs. Post-operative complications in this group of interest were collected (Table 3) and reported according to the Clavien-Dindo classification [45,46] (Table 4). These data were then compared to those retrieved from the manuscripts finally considered in the analysis[9,19,26,29-31,47] (Table 5), in fact other four papers that were initially assessed and that were from the last 3 years[48-51], were not included, because of the lack of information and partial numbers and percentages of patients with wound infections, abdominal abscesses and total post-operative complications.

Table 2 Groups and categories of severity of Bologna patients

	EL (n = 821)	ES (n = 175)	P values
Age (yr)	35 (14-94) ± 18	36 (14-91) ± 17	0.50
Male:Female	425:396	111:64	< 0.05
BMI	23.85 (14-44) ± 4.4	24 (17-42) ± 4.5	0.68
CV comorbidities	7.6%	24%	< 0.05
Other comorbidities	13.9%	31.4%	< 0.05
Edematous AA	251	5	0.18
Phlegmonous AA	410	59	0.05
Gangrenous AA	160	111	0.05

EL: Endoloop; ES: Endostapler; BMI: Body mass index; CV: Cardiovascular; AA: Acute appendicitis.

Table 3 Post-operative complications in Bologna endoloop group

	EL (n = 821)
Wound infections	2 (0.3%)
Abdominal abscesses	12 (1.5%)
Post-op complications IIIa/IIIb Clavien-Dindo	17 (2%)
Total post-op complications	35 (4.3%)

EL: Endoloop.

Table 4 Post-operative complications in Bologna 996 laparoscopic appendectomy patients

Clavien-Dindo	Number of patients (% of total cohort)
I	3 (0.3)
II	24 (2.4)
IIIa	7 (0.7)
IIIb	16 (1.6)
IVa	0 (0)
IVb	0 (0)
V	0 (0)
Total	50 (5)

Examination of the seven papers involved in the meta-analysis[9,19,26,29-31,47] showed that only Beldi *et al*[26] were in favor of application of an ES for transection and closure of the appendiceal stump in patients with AA. In their report it lowered the risk of postoperative intra-abdominal surgical-site infection and the need for readmission to hospital. All the other 6 papers didn't find a statistically significant difference for intra or postsurgical complications, length of stay (LOS), wound infections, and abdominal abscesses among different groups of patients. Sahm *et al*[29] and Van Rossem *et al*[30] clearly stated that infectious complication rate is not influenced by the type of appendicular stump closure, either if performed by EL or ES, and routine stump closure using an EL is an easy, safe, and cost-effective procedure. Finally, it is important to mention the retrospective cohort study conducted by Swank *et al*[31] that compares the two strategies for closure of the appendiceal stump. The routine use of the ES showed no clinical advantages over the use of ELs.

Statistical data and results showed that our experience followed the trend of the evidence in literature in terms of wound infections (Figure 2 and Table 6), abdominal abscesses (Figure 3 and Table 7) and total post-operative complications (Figure 4 and Table 8). The meta-analysis proved a wide heterogeneity among analyzed groups, as the funnel plots and the forest plots confirmed. Tables 6-8 report

Table 5 Complete data to meta-analyse

Ref.	Number of patients (% of EL)	Wound infection	Abdominal abscesses	Post-op complications
Bologna experience	821 (78.5)	2 (0.3%)	12 (1.5%)	26 (3.2%)
Ortega <i>et al</i> [9], 1995	89	4 (4.5%)	4 (4.5%)	14 (15.7%)
Sadat-Safavi <i>et al</i> [19], 2016	38 (50)	1 (2.6%)	0 (0%)	0 (0%)
Beldi <i>et al</i> [26], 2006	2565 (39.5)	12 (0.5%)	41 (1.6%)	37 (1.4%)
Sahm <i>et al</i> [29], 2011	1670 (97.3)	34 (2%)	27 (1.6%)	48 (2.9%)
Van Rossem <i>et al</i> [30], 2017	1050 (76.7)	16 (1.5%)	48 (4.5%)	20 (1.9%)
Swank <i>et al</i> [31], 2014	465 (44.9)	7 (1.5%)	20 (4.3%)	14 (3.1%)
Klima <i>et al</i> [47], 1998	100	3 (3%)	4 (4%)	4 (4%)

EL: Endoloop.

Table 6 Wound infection: Data standard deviation in the meta-analysis

Ref.	Standard deviation	Proportion (%)	95%CI
Our experience	821	0.244	0.0295-0.877
Van Rossem <i>et al</i> [30], 2017	1050	1.524	0.873-2.463
Sadat-Safavi <i>et al</i> [19], 2016	38	2.632	0.0666-13.810
Swank <i>et al</i> [31], 2014	465	1.505	0.607-3.077
Sahm <i>et al</i> [29], 2011	1670	2.036	1.414-2.833
Beldi <i>et al</i> [26], 2006	2565	0.468	0.242-0.816
Klima <i>et al</i> [47], 1998	100	3.000	0.623-8.518
Ortega <i>et al</i> [9], 1995	89	4.494	1.238-11.109
Total (fixed effects)	6798	1.064	0.834-1.337
Total (random effects)	6798	1.496	0.759-2.475

CI: Confidence interval.

data related to the standard deviation of wound infection, abdominal abscesses, and post-operative complications, respectively. Figures 2A, 3A and 4A are Funnel Plots showing an asymmetrical distribution of the articles (*dot*) among both sides indicating that bias can be present. In Figures 2A and 4A, few papers are near the middle solid line, indicating the overall effect from the meta-analysis, possibly in relation to the limited size of the samples. Figures 2B, 3B and 4B Forrest Plots prove there is no statistically significant result in favor of ES or EL for the overall incidence of wound infections, abdominal abscess, or post-operative complications.

DISCUSSION

Appendectomy is one of the most performed emergency surgery procedures. The laparoscopic approach is recognized and recommended internationally, but a matter of debate during the operation is the choice of the different available devices to close the appendicular stump, in consideration of the possible consequent leak leading to infection and postoperative complications.

Already previously[38], we evidenced that the routine use of EL is safe in most patients affected by AA, including cases with signs of complications. Furthermore, it is a cost-effective device, even when possible additional costs secondary to the occurrence of adverse events in the post-operative course are included. Conversely, Lasek *et al*[48] assessed *via* a multicenter observational study the stump closure only in patients affected by complicated AA. Their results highlighted some clinical benefits of ES use, but EL was superior in terms of overall morbidity and LOS, with no statistically significant difference in major complication rates and postoperative intra-abdominal abscess formation.

Table 7 Abdominal abscess: Data standard deviation in the meta-analysis

Ref.	Standard deviation	Proportion (%)	95%CI
Our experience	821	1.462	0.757-2.539
Van Rossem <i>et al</i> [30], 2017	1050	4.571	3.390-6.016
Sadat-Safavi <i>et al</i> [19], 2016	38	0.000	0.000-9.251
Swank <i>et al</i> [31], 2014	465	4.301	2.647-6.565
Sahm <i>et al</i> [29], 2011	1670	1.617	1.068-2.344
Beldi <i>et al</i> [26], 2006	2565	1.598	1.149-2.162
Klima <i>et al</i> [47], 1998	100	4.000	1.100-9.926
Ortega <i>et al</i> [9], 1995	89	4.494	1.238-11.109
Total (fixed effects)	6798	2.206	1.870-2.583
Total (random effects)	6798	2.699	1.697-3.924

CI: Confidence interval.

Table 8 Post-operative complications: Data standard deviation in the meta-analysis

Ref.	Standard deviation	Proportion (%)	95%CI
Our experience	821	3.167	2.079-4.606
Van Rossem <i>et al</i> [30], 2017	1050	1.905	1.167-2.926
Sadat-Safavi <i>et al</i> [19], 2016	38	0.000	0.000-9.251
Swank <i>et al</i> [31], 2014	465	3.011	1.656-5.000
Sahm <i>et al</i> [29], 2011	1670	2.874	2.127-3.793
Beldi <i>et al</i> [26], 2006	2565	1.442	1.018-1.983
Klima <i>et al</i> [47], 1998	100	4.000	1.100-9.926
Ortega <i>et al</i> [9], 1995	89	15.730	8.875-24.982
Total (fixed effects)	6798	2.304	1.961-2.689
Total (random effects)	6798	3.089	1.979-4.437

CI: Confidence interval.

In literature, two papers systematically analyzed the techniques for appendiceal stump closure during LA[49,50]. Ceresoli *et al*[49] meta-analysed randomized trials and cohort studies comparing ES with endoscopic loop ties for the closure of the appendicular stump in LA, including pediatric patients and complicated AA, such as gangrenous/necrotic appendix or the perforated ones. In their analysis, ES was associated with a similar intra-abdominal abscess rate, but a lower incidence of wound infection, while LOS, readmission and reoperation rates were similar. In a subgroup analysis ES significantly reduced the wound infection rate in pediatric patients, while no difference in the main outcomes was observed in patients with complicated AA.

Makaram *et al*[50] performed a systematic review evaluating all methods of stump closure (ELs, polymeric endoclips, metallic endoclips, endosuture and ES). In this study[50], no difference in complication rate, LOS or cost was found. According to their analysis, endoclips provide the most time-efficient method of closure, although not statistically significant; closure by endosuture, represents the cheapest method, but it is hindered by a high complication rate. Current evidence suggests endosuture should then be avoided. ESs appear very safe and effective for stump closure, however they seem to be associated with high postoperative complication rates; furthermore, the consequent cost limits their use to the most severe cases of appendicitis, while instead EL provides a valuable alternative for closure, with a risk of intraoperative complications of 4.61%.

Another recent retrospective cohort study[51], whose subject was to determine the safety and efficiency of the use of EL and ES in complicated and uncomplicated AA, concluded that the systematic use of EL could reduce costs in uncomplicated appendicitis, while in complicated cases both options

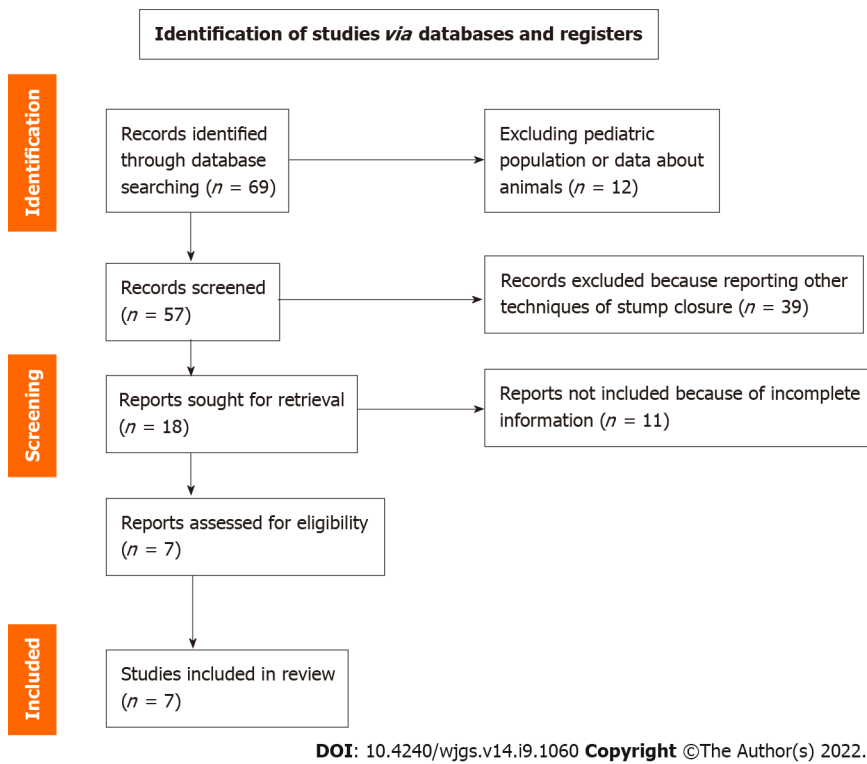


Figure 1 PRISMA diagram.

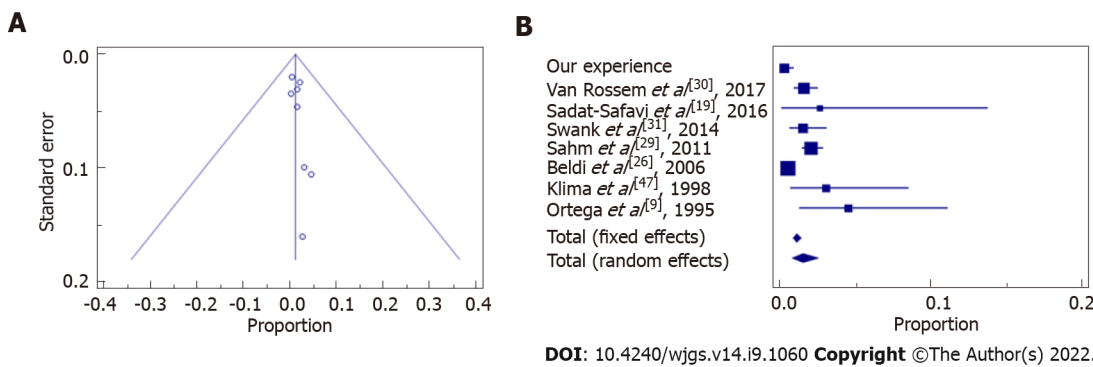


Figure 2 Wound infection Funnel plot. A: Asymmetrical distribution among both sides indicates that bias can be present; B: The confidence interval (diamond) confirms there is no statistically significant result.

(loop and stapler) are valid. Also a prospective randomized clinical trial[52] and a retrospective study [53] recently analyzed the technical aspects of appendix stump closure: Ihnát *et al*[52] reported similar postoperative morbidity and safety following the use of EL, ES or hem-o-lok and even White *et al*[53] demonstrated non univocal superiority of one technique over the others, too.

Another point indeed to be considered is LA availability together with the fact that the different devices rely upon the resources of the hospital and the country where surgery is performed, pending possible spending reviews carried out by the government. It has been demonstrated that LA is performed more frequently in high-income countries in comparison to low-income countries (67.7% vs 8.1%), with better postoperative outcomes[54]. The difference in the costs of the used surgical devices (above all stapler) represented a principal determinant for the overall economic impact of the surgical procedure in some recent reports[33,36,38,50,51], to highlight how important is the cost-effectiveness in the measured outcomes. The medium saving reported in the present paper is relevant, varying from around approximately 300 € to more than 500 € just for the device, which then must be multiplied for the many LA conducted worldwide; further cost-analysis including operative time and LOS could reach major savings.

Our study presents some limitations: The design is a retrospective analysis to investigate the safety of ELs, then the results are pooled with other reports; the comparison between studies is difficult due to heterogenous patient selection and outcomes measured. However, EL seems to have the potential for

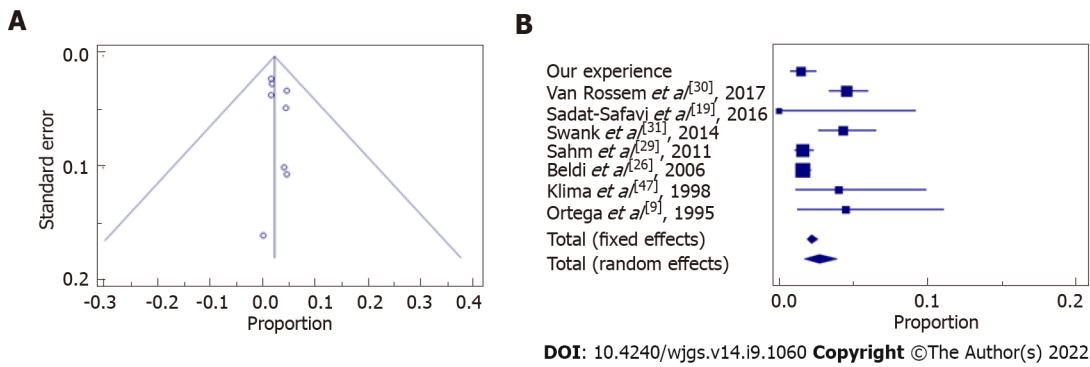


Figure 3 Abdominal abscess Funnel plot. A: With asymmetrical distribution among both sides, indicating that bias can be present; B: The confidence interval (diamond) confirms there is no statistically significant result favoring endloop or endostapler.

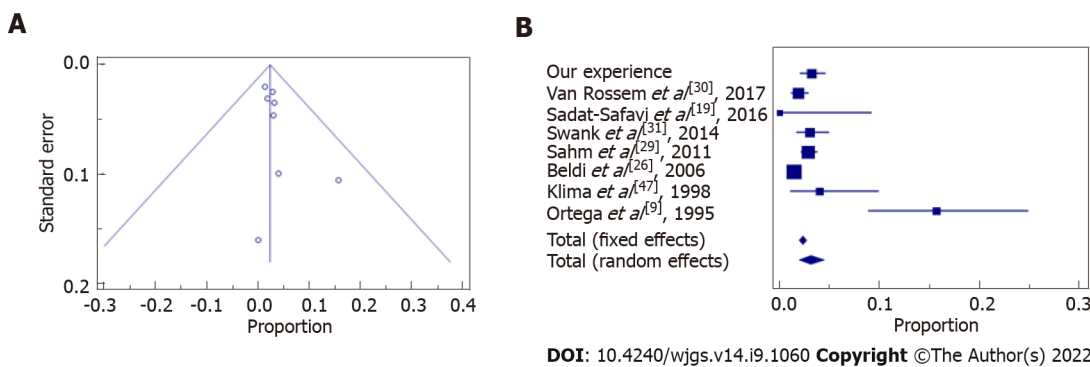


Figure 4 Post-operative complications Funnel plot. A: Asymmetrical distribution among both sides indicates that bias can be present; B: The confidence interval (diamond) confirms there is not statistically significant difference between endloop vs endostapler.

being a safe and cost-effective device.

CONCLUSION

In conclusion, there is no evidence clearly illustrating a superior surgical method for performing stump closure in LA. Given that comparison between studies is difficult due to heterogeneous patient selection and measured outcomes, our meta-analysis shows that the data of our sample, related to wound infections, post-operative abdominal abscesses, and total post-operative complications, mirror current literature trend. The routine use of EL is safe in most patients affected by AA, even when complicated, and these findings could have above all more relevance in lower resource environments that may not have easy access to ES. Prospective studies are needed to analyze a greater number of patients and taking into account an accurate grading system for AA severity such as Disease Severity Score[55], Alvarado Score[41], AIR Score[42] or imaging severity scoring, such as the CT-Determined Severity Score[56]. Their aim should be first to stratify preoperatively the grade of AA and secondly to observe differences in postoperative complications. Finally, studies aiming at an accurate cost analysis are required, ideally in the form of randomized controlled trials comparing EL to polymeric clips, as both techniques are safe and effective, with favorable outcomes[50,52].

ARTICLE HIGHLIGHTS

Research background

Laparoscopic appendectomy (LA) has shown advantages in terms of clinical results and cost-effectiveness, even if there is still controversy about which surgical device should be preferred to perform it.

Research motivation

To evaluate the safety cost-effectiveness of surgical devices in LA stump closure.

Research objectives

Incidence of wound infections, abdominal abscesses and total post-operative complications according to the Dindo-Clavien classification in LA stump closure with endoloop (EL) or endostapler.

Research methods

A meta-analysis was performed in terms of surgical complications, comparing the clinical data of the EL group (821 patients) to the international literature retrieved by Pubmed, according to the PRISMA principles.

Research results

There is no superiority of one or another technique in terms of surgical complications for LA stump closure.

Research conclusions

Routine use of EL is safe in most patients affected by acute appendectomy, even when complicated.

Research perspectives

Studies of EL performing accurate cost analysis are required, in addition to randomized controlled trials comparing this method to polymeric clips, as both techniques have been proved to have to be safe and effective with favorable outcomes.

FOOTNOTES

Author contributions: Zorzetti L and Bellini MI wrote and revised the article; Lauro A, Dalla Via B, Cervellera M, Tonini V, Sorrenti S, Ciocchi R and D'Andrea V designed the research study; Vaccari S, Zorzetti N, Lauro A, and Bellini MI performed the research; and all authors have read and approve the final manuscript.

Conflict-of-interest statement: All the authors report no relevant conflicts of interest for this article.

PRISMA 2009 Checklist statement: The authors have read the PRISMA 2009 Checklist, and the manuscript was prepared and revised according to the PRISMA 2009 Checklist.

Open-Access: This article is an open-access article that was selected by an in-house editor and fully peer-reviewed by external reviewers. It is distributed in accordance with the Creative Commons Attribution NonCommercial (CC BY-NC 4.0) license, which permits others to distribute, remix, adapt, build upon this work non-commercially, and license their derivative works on different terms, provided the original work is properly cited and the use is non-commercial. See: <https://creativecommons.org/licenses/by-nc/4.0/>

Country/Territory of origin: Italy

ORCID number: Noemi Zorzetti 0000-0002-7466-2336; Augusto Lauro 0000-0002-2292-5595; Maria Irene Bellini 0000-0003-0730-4923; Samuele Vaccari 0000-0001-9741-4303; Barbara Dalla Via 0000-0002-7754-8387; Maurizio Cervellera 0000-0002-8885-7660; Roberto Ciocchi 0000-0002-2457-0636; Salvatore Sorrenti 0000-0003-0427-6648; Vito D'Andrea 0000-0001-5709-2530; Valeria Tonini 0000-0003-3130-2928.

S-Editor: Wang JJ

L-Editor: A

P-Editor: Wang JJ

REFERENCES

- 1 **Birnbaum BA**, Wilson SR. Appendicitis at the millennium. *Radiology* 2000; **215**: 337-348 [PMID: 10796905 DOI: 10.1148/radiology.215.2.r00ma24337]
- 2 **Ussia A**, Vaccari S, Gallo G, Grossi U, Ussia R, Sartarelli L, Minghetti M, Lauro A, Barbieri P, Di Saverio S, Cervellera M, Tonini V. Laparoscopic appendectomy as an index procedure for surgical trainees: clinical outcomes and learning curve. *Updates Surg* 2021; **73**: 187-195 [PMID: 33398773 DOI: 10.1007/s13304-020-00950-z]
- 3 **Costa-Navarro D**, Jiménez-Fuertes M, Illán-Riquelme A. Laparoscopic appendectomy: quality care and cost-effectiveness for today's economy. *World J Emerg Surg* 2013; **8**: 45 [PMID: 24180475 DOI: 10.1186/1749-7922-8-45]
- 4 **Masoomi H**, Mills S, Dolich MO, Ketana N, Carmichael JC, Nguyen NT, Stamos MJ. Comparison of outcomes of laparoscopic versus open appendectomy in adults: data from the Nationwide Inpatient Sample (NIS), 2006-2008. *J Gastrointest Surg* 2011; **15**: 2226-2231 [PMID: 21725700 DOI: 10.1007/s11605-011-1613-8]
- 5 **Sajid MS**, Rimple J, Cheek E, Baig MK. Use of endo-GIA versus endo-loop for securing the appendicular stump in laparoscopic appendectomy: a systematic review. *Surg Laparosc Endosc Percutan Tech* 2009; **19**: 11-15 [PMID:

- 19238059 DOI: [10.1097/SLE.0b013e31818a66ab](https://doi.org/10.1097/SLE.0b013e31818a66ab)]
- 6 **Coşkun H**, Hasbahçeci M, Bozkurt S, Çipe G, Malya FÜ, Memmi N, Karatepe O, Akçakaya A, Müslümanoğlu M. Is concomitant cholecystectomy with laparoscopic sleeve gastrectomy safe? *Turk J Gastroenterol* 2014; **25**: 624-627 [PMID: 25599771 DOI: [10.5152/tjg.2014.6954](https://doi.org/10.5152/tjg.2014.6954)]
 - 7 **Sohn M**, Agha A, Bremer S, Lehmann KS, Bormann M, Hochrein A. Surgical management of acute appendicitis in adults: A review of current techniques. *Int J Surg* 2017; **48**: 232-239 [PMID: 29155250 DOI: [10.1016/j.ijsu.2017.11.028](https://doi.org/10.1016/j.ijsu.2017.11.028)]
 - 8 **Di Saverio S**, Mandrioli M, Sibilio A, Smerieri N, Lombardi R, Catena F, Ansaloni L, Tugnoli G, Masetti M, Jovine E. A cost-effective technique for laparoscopic appendectomy: outcomes and costs of a case-control prospective single-operator study of 112 unselected consecutive cases of complicated acute appendicitis. *J Am Coll Surg* 2014; **218**: e51-e65 [PMID: 24559968 DOI: [10.1016/j.jamcollsurg.2013.12.003](https://doi.org/10.1016/j.jamcollsurg.2013.12.003)]
 - 9 **Ortega AE**, Hunter JG, Peters JH, Swanstrom LL, Schirmer B. A prospective, randomized comparison of laparoscopic appendectomy with open appendectomy. Laparoscopic Appendectomy Study Group. *Am J Surg* 1995; **169**: 208-12; discussion 212 [PMID: 7840381 DOI: [10.1016/s0002-9610\(99\)80138-x](https://doi.org/10.1016/s0002-9610(99)80138-x)]
 - 10 **Lucchi A**, Berti P, Grassia M, Siani LM, Gabbianelli C, Garulli G. Laparoscopic appendectomy: Hem-o-lok versus Endoloop in stump closure. *Updates Surg* 2017; **69**: 61-65 [PMID: 28013455 DOI: [10.1007/s13304-016-0413-9](https://doi.org/10.1007/s13304-016-0413-9)]
 - 11 **Takami T**, Yamaguchi T, Yoshitake H, Hatano K, Kataoka N, Tomita M, Makimoto S. A clinical comparison of laparoscopic versus open appendectomy for the treatment of complicated appendicitis: historical cohort study. *Eur J Trauma Emerg Surg* 2020; **46**: 847-851 [PMID: 30710176 DOI: [10.1007/s00068-019-01086-5](https://doi.org/10.1007/s00068-019-01086-5)]
 - 12 **Shimoda M**, Maruyama T, Nishida K, Suzuki K, Tago T, Shimazaki J, Suzuki S. Comparison of clinical outcome of laparoscopic versus open appendectomy, single center experience. *Heliyon* 2018; **4**: e00635 [PMID: 29872767 DOI: [10.1016/j.heliyon.2018.e00635](https://doi.org/10.1016/j.heliyon.2018.e00635)]
 - 13 **Guadagni S**, Cengeli I, Galatioto C, Furbetta N, Piero VL, Zocco G, Seccia M. Laparoscopic repair of perforated peptic ulcer: single-center results. *Surg Endosc* 2014; **28**: 2302-2308 [PMID: 24609709 DOI: [10.1007/s00464-014-3481-2](https://doi.org/10.1007/s00464-014-3481-2)]
 - 14 **Gorter RR**, Heij HA, Eker HH, Kazemier G. Laparoscopic appendectomy: State of the art. Tailored approach to the application of laparoscopic appendectomy? *Best Pract Res Clin Gastroenterol* 2014; **28**: 211-224 [PMID: 24485267 DOI: [10.1016/j.bpg.2013.11.016](https://doi.org/10.1016/j.bpg.2013.11.016)]
 - 15 **Antoniu SA**, Mavridis D, Hajibandeh S, Antoniou GA, Gorter R, Tenhagen M, Koutras C, Pointner R, Chalkiadakis GE, Granderath FA, Fragiadakis GF, Philalithis AE, Bonjer HJ. Optimal stump management in laparoscopic appendectomy: A network meta-analysis by the Minimally Invasive Surgery Synthesis of Interventions and Outcomes Network. *Surgery* 2017; **162**: 994-1005 [PMID: 28864100 DOI: [10.1016/j.surg.2017.07.013](https://doi.org/10.1016/j.surg.2017.07.013)]
 - 16 **Aziret M**, Çetinkünar S, Erdem H, Kahramanca Ş, Bozkurt H, Dülgeroğlu O, Yıldırım AC, İrkörücü O, Gölboyu EB. Comparison of open appendectomy and laparoscopic appendectomy with laparoscopic intracorporeal knotting and glove endobag techniques: A prospective observational study. *Turk J Surg* 2017; **33**: 258-266 [PMID: 29260130 DOI: [10.5152/turkjsurg.2017.3583](https://doi.org/10.5152/turkjsurg.2017.3583)]
 - 17 **Partecke LI**, Kessler W, von Bernstorff W, Diedrich S, Heidecke CD, Patrzyk M. Laparoscopic appendectomy using a single polymeric clip to close the appendicular stump. *Langenbecks Arch Surg* 2010; **395**: 1077-1082 [PMID: 20577759 DOI: [10.1007/s00423-010-0671-9](https://doi.org/10.1007/s00423-010-0671-9)]
 - 18 **Al-Temimi MH**, Berglin MA, Kim EG, Tessier DJ, Johna SD. Discussion of: "Endostapler versus Hem-O-Lok clip to secure the appendiceal stump and mesoappendix during laparoscopic appendectomy". *Am J Surg* 2017; **214**: 1149-1150 [PMID: 29054445 DOI: [10.1016/j.amjsurg.2017.10.006](https://doi.org/10.1016/j.amjsurg.2017.10.006)]
 - 19 **Sadat-Safavi SA**, Nasiri S, Shojaiefard A, Jafari M, Abdehghah AG, Notash AY Jr, Soroush A. Comparison the effect of stump closure by endoclips versus endoloop on the duration of surgery and complications in patients under laparoscopic appendectomy: A randomized clinical trial. *J Res Med Sci* 2016; **21**: 87 [PMID: 28163733 DOI: [10.4103/1735-1995.192503](https://doi.org/10.4103/1735-1995.192503)]
 - 20 **Delibegović S**. The use of a single Hem-o-lok clip in securing the base of the appendix during laparoscopic appendectomy. *J Laparoendosc Adv Surg Tech A* 2012; **22**: 85-87 [PMID: 22145605 DOI: [10.1089/lap.2011.0348](https://doi.org/10.1089/lap.2011.0348)]
 - 21 **Bali İ**, Karateke F, Özyazıcı S, Kuvvetli A, Oruç C, Menekşe E, Emir S, Özdoğan M. Comparison of intracorporeal knotting and endoloop for stump closure in laparoscopic appendectomy. *Ulus Travma Acil Cerrahi Derg* 2015; **21**: 446-449 [PMID: 27054634 DOI: [10.5505/tjtes.2015.56798](https://doi.org/10.5505/tjtes.2015.56798)]
 - 22 **Mayir B**, Ensari CÖ, Bilecik T, Aslaner A, Oruç MT. Methods for closure of appendix stump during laparoscopic appendectomy procedure. *Ulus Cerrahi Derg* 2015; **31**: 229-231 [PMID: 26668532 DOI: [10.5152/UCD.2015.2768](https://doi.org/10.5152/UCD.2015.2768)]
 - 23 **Yıldız I**, Koca S. Is There An Ideal Stump Closure Technique In Laparoscopic Appendectomy? *Surg Technol Int* 2016; **28**: 117-120 [PMID: 27121413]
 - 24 **Delibegović S**, Mehmedovic Z. The influence of the different forms of appendix base closure on patient outcome in laparoscopic appendectomy: a randomized trial. *Surg Endosc* 2018; **32**: 2295-2299 [PMID: 29098432 DOI: [10.1007/s00464-017-5924-z](https://doi.org/10.1007/s00464-017-5924-z)]
 - 25 **Kazemier G**, in't Hof KH, Saad S, Bonjer HJ, Sauerland S. Securing the appendiceal stump in laparoscopic appendectomy: evidence for routine stapling? *Surg Endosc* 2006; **20**: 1473-1476 [PMID: 16823654 DOI: [10.1007/s00464-005-0525-7](https://doi.org/10.1007/s00464-005-0525-7)]
 - 26 **Beldi G**, Vorburger SA, Bruegger LE, Kocher T, Inderbitzin D, Candinas D. Analysis of stapling versus endoloops in appendiceal stump closure. *Br J Surg* 2006; **93**: 1390-1393 [PMID: 16862615 DOI: [10.1002/bjs.5474](https://doi.org/10.1002/bjs.5474)]
 - 27 **Caglià P**, Tracia A, Borzi L, Amodeo L, Tracia L, Veroux M, Amodeo C. Incisional hernia in the elderly: risk factors and clinical considerations. *Int J Surg* 2014; **12** Suppl 2: S164-S169 [PMID: 25157994 DOI: [10.1016/j.ijsu.2014.08.357](https://doi.org/10.1016/j.ijsu.2014.08.357)]
 - 28 **Sohn M**, Hoffmann M, Pohlen U, Lauscher JC, Zurbuchen U, Holmer C, Buhr HJ, Lehmann KS. [Stump closure in laparoscopic appendectomy. Influence of endoloop or linear stapler on patient outcome]. *Chirurg* 2014; **85**: 46-50 [PMID: 23780410 DOI: [10.1007/s00104-013-2549-1](https://doi.org/10.1007/s00104-013-2549-1)]
 - 29 **Sahm M**, Kube R, Schmidt S, Ritter C, Pross M, Lippert H. Current analysis of endoloops in appendiceal stump closure. *Surg Endosc* 2011; **25**: 124-129 [PMID: 20552371 DOI: [10.1007/s00464-010-1144-5](https://doi.org/10.1007/s00464-010-1144-5)]
 - 30 **van Rossem CC**, van Geloven AA, Schreinemacher MH, Bemelman WA; snapshot appendicitis collaborative study group. Endoloops or endostapler use in laparoscopic appendectomy for acute uncomplicated and complicated appendicitis : No

- difference in infectious complications. *Surg Endosc* 2017; **31**: 178-184 [PMID: 27129569 DOI: 10.1007/s00464-016-4951-5]
- 31 **Swank HA**, van Rossem CC, van Geloven AA, in't Hof KH, Kazemier G, Meijerink WJ, Lange JF, Bemelman WA. Endostapler or endoloops for securing the appendiceal stump in laparoscopic appendectomy: a retrospective cohort study. *Surg Endosc* 2014; **28**: 576-583 [PMID: 24048816 DOI: 10.1007/s00464-013-3207-x]
 - 32 **Beldi G**, Muggli K, Helbling C, Schlumpf R. Laparoscopic appendectomy using endoloops: a prospective, randomized clinical trial. *Surg Endosc* 2004; **18**: 749-750 [PMID: 15026904 DOI: 10.1007/s00464-003-9156-z]
 - 33 **Mehdorn M**, Schürmann O, Mehdorn HM, Gockel I. Intended cost reduction in laparoscopic appendectomy by introducing the endoloop: a single center experience. *BMC Surg* 2017; **17**: 80 [PMID: 28693476 DOI: 10.1186/s12893-017-0277-z]
 - 34 **Rakić M**, Jukić M, Pogorelić Z, Mrklić I, Kliček R, Družijanić N, Perko Z, Patrlj L. Analysis of endoloops and endostaples for closing the appendiceal stump during laparoscopic appendectomy. *Surg Today* 2014; **44**: 1716-1722 [PMID: 24337502 DOI: 10.1007/s00595-013-0818-8]
 - 35 **Kryspin M**, Wyrzykowski D. Outcomes of Open and Laparoscopic Appendectomy With Single Endoloop Stump Closure. *JLS* 2018; **22** [PMID: 30607104 DOI: 10.4293/JLS.2018.00062]
 - 36 **Kim S**, Weireter L. Cost Effectiveness of Different Methods of Appendiceal Stump Closure during Laparoscopic Appendectomy. *Am Surg* 2018; **84**: 1329-1332 [PMID: 30185311 DOI: 10.1177/000313481808400847]
 - 37 **Granados-Romero JJ**, Valderrama-Treviño AI, Barrera-Mera B, Uriarte-Ruiz K, Banegas-Ruiz R, Ceballos-Villalva JC. [Comparación entre ligadura con lazo hemostático y engrapadora mecánica lineal para el cierre de base apendicular]. *Cir Cir* 2018; **86**: 428-431 [PMID: 30226495 DOI: 10.24875/CIRU.18000258]
 - 38 **Zorzetti N**, Lauro A, Vaccari S, Ussia A, Brighi M, D'andrea V, Cervellera M, Tonini V. A systematic review on the cost evaluation of two different laparoscopic surgical techniques among 996 appendectomies from a single center. *Updates Surg* 2020; **72**: 1167-1174 [PMID: 32474801 DOI: 10.1007/s13304-020-00817-3]
 - 39 **Antonacci N**, Ricci C, Taffurelli G, Monari F, Del Governatore M, Caira A, Leone A, Cervellera M, Minni F, Cola B. Laparoscopic appendectomy: Which factors are predictors of conversion? *Int J Surg* 2015; **21**: 103-107 [PMID: 26231996 DOI: 10.1016/j.ijso.2015.06.089]
 - 40 **Finnerty BM**, Wu X, Giambone GP, Gaber-Baylis LK, Zabih R, Bhat A, Zarnegar R, Pomp A, Fleischut P, Afaneh C. Conversion-to-open in laparoscopic appendectomy: A cohort analysis of risk factors and outcomes. *Int J Surg* 2017; **40**: 169-175 [PMID: 28285058 DOI: 10.1016/j.ijso.2017.03.016]
 - 41 **Alvarado A**. A practical score for the early diagnosis of acute appendicitis. *Ann Emerg Med* 1986; **15**: 557-564 [PMID: 3963537 DOI: 10.1016/s0196-0644(86)80993-3]
 - 42 **Kollár D**, McCartan DP, Bourke M, Cross KS, Dowdall J. Predicting acute appendicitis? *World J Surg* 2015; **39**: 104-109 [PMID: 25245432 DOI: 10.1007/s00268-014-2794-6]
 - 43 **Chu T**, Chandhoke RA, Smith PC, Schwaitzberg SD. The impact of surgeon choice on the cost of performing laparoscopic appendectomy. *Surg Endosc* 2011; **25**: 1187-1191 [PMID: 20835717 DOI: 10.1007/s00464-010-1342-1]
 - 44 **Page MJ**, McKenzie JE, Bossuyt PM, Boutron I, Hoffmann TC, Mulrow CD, Shamseer L, Tetzlaff JM, Akl EA, Brennan SE, Chou R, Glanville J, Grimshaw JM, Hróbjartsson A, Lalu MM, Li T, Loder EW, Mayo-Wilson E, McDonald S, McGuinness LA, Stewart LA, Thomas J, Tricco AC, Welch VA, Whiting P, Moher D. The PRISMA 2020 statement: an updated guideline for reporting systematic reviews. *BMJ* 2021; **372**: n71 [PMID: 33782057 DOI: 10.1136/bmj.n71]
 - 45 **Dindo D**, Demartines N, Clavien PA. Classification of surgical complications: a new proposal with evaluation in a cohort of 6336 patients and results of a survey. *Ann Surg* 2004; **240**: 205-213 [PMID: 15273542 DOI: 10.1097/01.sla.0000133083.54934.ae]
 - 46 **Clavien PA**, Barkun J, de Oliveira ML, Vauthey JN, Dindo D, Schulick RD, de Santibañes E, Pekolj J, Slankamenac K, Bassi C, Graf R, Vonlanthen R, Padbury R, Cameron JL, Makuuchi M. The Clavien-Dindo classification of surgical complications: five-year experience. *Ann Surg* 2009; **250**: 187-196 [PMID: 19638912 DOI: 10.1097/SLA.0b013e3181b13ca2]
 - 47 **Klima S**. [Importance of appendix stump management in laparoscopic appendectomy]. *Zentralbl Chir* 1998; **123** Suppl 4: 90-93 [PMID: 9880884]
 - 48 **Lasek A**, Wysocki M, Mavrikis J, Myśliwiec P, Bobowicz M, Dowgiałło-Wnukiewicz N, Kenig J, Stefura T, Walędziak M, Pędziwiatr M; Pol-LA (Polish Laparoscopic Appendectomy) Collaborative Study Group. Comparison of stump closure techniques during laparoscopic appendectomies for complicated appendicitis - results from Pol-LA (Polish laparoscopic appendectomy) multicenter large cohort study. *Acta Chir Belg* 2020; **120**: 116-123 [PMID: 30747049 DOI: 10.1080/00015458.2019.1573527]
 - 49 **Ceresoli M**, Tamini N, Gianotti L, Braga M, Nespoli L. Are endoscopic loop ties safe even in complicated acute appendicitis? *Int J Surg* 2019; **68**: 40-47 [PMID: 31226406 DOI: 10.1016/j.ijso.2019.06.011]
 - 50 **Makaram N**, Knight SR, Ibrahim A, Patil P, Wilson MSJ. Closure of the appendiceal stump in laparoscopic appendectomy: A systematic review of the literature. *Ann Med Surg (Lond)* 2020; **57**: 228-235 [PMID: 32802324 DOI: 10.1016/j.amsu.2020.07.058]
 - 51 **Durán Muñoz-Cruzado V**, Anguiano-Díaz G, Tallón Aguilar L, Tinoco González J, Sánchez Arteaga A, Aparicio Sánchez D, Pareja Ciuró F, Padillo Ruiz J. Is the use of endoloops safe and efficient for the closure of the appendicular stump in complicated and uncomplicated acute appendicitis? *Langenbecks Arch Surg* 2021; **406**: 1581-1589 [PMID: 33409584 DOI: 10.1007/s00423-020-02050-3]
 - 52 **Ihnát P**, Tesař M, Tulinský L, Ihnát Rudinská L, Okantey O, Durdík Š. A randomized clinical trial of technical modifications of appendix stump closure during laparoscopic appendectomy for uncomplicated acute appendicitis. *BMC Surg* 2021; **21**: 272 [PMID: 34059039 DOI: 10.1186/s12893-021-01279-z]
 - 53 **White C**, Hardman C, Parikh P, Ekeh AP. Endostapler vs Endoloop closure of the appendiceal stump in laparoscopic appendectomy: Which has better outcomes? *Am J Surg* 2021; **222**: 413-416 [PMID: 33419519 DOI: 10.1016/j.amsurg.2020.12.047]
 - 54 **GlobalSurg Collaborative**. Laparoscopy in management of appendicitis in high-, middle-, and low-income countries: a multicenter, prospective, cohort study. *Surg Endosc* 2018; **32**: 3450-3466 [PMID: 29623470 DOI: 10.1007/s00464-018-0600-0]

[10.1007/s00464-018-6064-9](https://doi.org/10.1007/s00464-018-6064-9)]

- 55 **Garst GC**, Moore EE, Banerjee MN, Leopold DK, Burlew CC, Bensard DD, Biffl WL, Barnett CC, Johnson JL, Sauaia A. Acute appendicitis: a disease severity score for the acute care surgeon. *J Trauma Acute Care Surg* 2013; **74**: 32-36 [PMID: [23271074](https://pubmed.ncbi.nlm.nih.gov/23271074/) DOI: [10.1097/TA.0b013e318278934a](https://doi.org/10.1097/TA.0b013e318278934a)]
- 56 **Kim HC**, Yang DM, Lee CM, Jin W, Nam DH, Song JY, Kim JY. Acute appendicitis: relationships between CT-determined severities and serum white blood cell counts and C-reactive protein levels. *Br J Radiol* 2011; **84**: 1115-1120 [PMID: [21123307](https://pubmed.ncbi.nlm.nih.gov/21123307/) DOI: [10.1259/bjr/47699219](https://doi.org/10.1259/bjr/47699219)]