

Received: 2016.11.13  
Accepted: 2017.01.11  
Published: 2017.03.30

# A Blast of Mistakes: Undiagnosed Cervical Spondylolisthesis Following a Bomb Explosion

Authors' Contribution:  
Study Design A  
Data Collection B  
Statistical Analysis C  
Data Interpretation D  
Manuscript Preparation E  
Literature Search F  
Funds Collection G

ABDEF 1 **Riccardo Caruso**  
B 2 **Luigi Marrocco**  
D 2 **Emanuele Piccione**  
BF 2 **Venceslao Wierzbicki**

1 Department of Neurology and Psychiatry, Sapienza University of Rome, Rome, Italy  
2 Department of Neurosurgery, Army Hospital of Rome "Celio", Rome, Italy

**Corresponding Author:** Riccardo Caruso, e-mail: [riccardo.caruso@uniroma1.it](mailto:riccardo.caruso@uniroma1.it)  
**Conflict of interest:** None declared

**Patient:** Male, 20  
**Final Diagnosis:** Cervical spondylolisthesis  
**Symptoms:** Cervical pain  
**Medication:** —  
**Clinical Procedure:** Surgery with cervical traction and circumferential arthrodesis  
**Specialty:** Neurosurgery

**Objective:** Patient complains/malpractice





**Background:** A case of spinal trauma had an unusual clinical course due to medical mistakes, from which we can learn some important lessons.

**Case Report:** We report a case of spondylolisthesis following a bomb explosion, which went undiagnosed for a long time because of a series of mistakes that are highlighted in this article. What makes this case unique is that the spondylolisthesis developed during hospital stay, but the patient had no loss of mobility, strength, or sensitivity.

**Conclusions:** This case shows that establishing the conditions of an organ or a body part upon admission to hospital may not be enough when a patient has suffered extensive and serious trauma, and that it is necessary to carry out more checkups over time, especially if there are new clues and symptoms.

**MeSH Keywords:** Arthrodesis • Cervical Vertebrae • Spinal Cord Compression • Spinal Cord Injuries • Spondylolisthesis

**Full-text PDF:** <http://www.amjcaserep.com/abstract/index/idArt/902357>

 1316  —  5  4

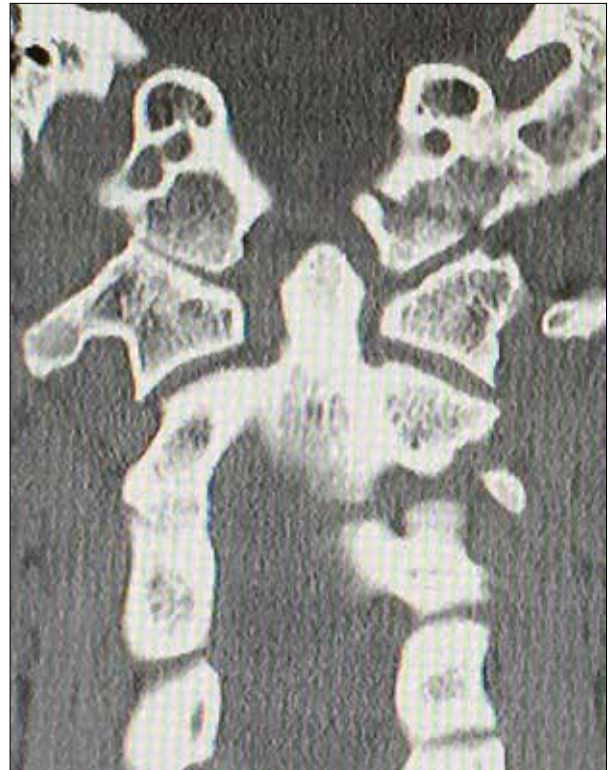

## Background

In this paper, we present a case of cervical spondylolisthesis caused by trauma. What makes this case of particular interest is not the complexity of the surgical procedure carried out, but the singular clinical history of the pathology, from which invaluable lessons can be learned.

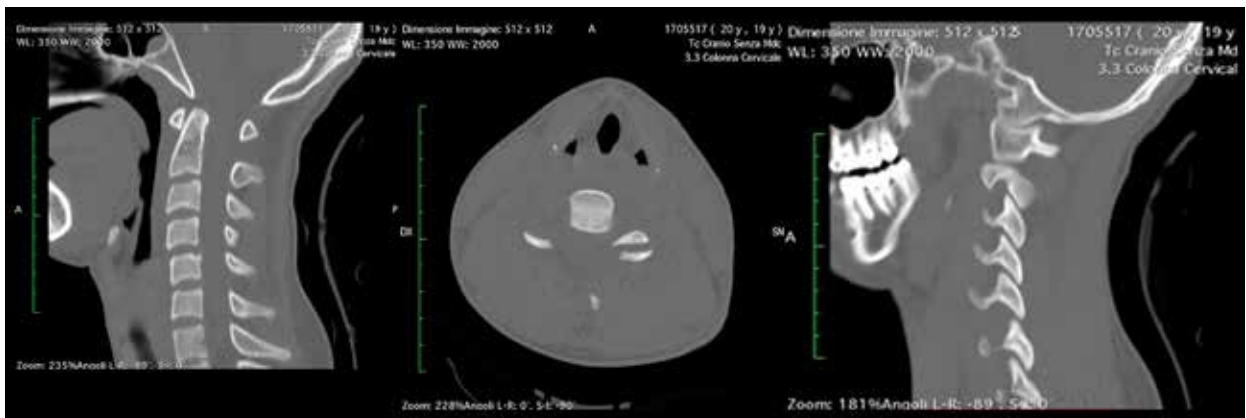
## Case Report

A 20-year-old man was wounded in a bomb explosion in Africa. Seven days after the traumatic event, when his condition was considered stable, he was transferred by airplane from Africa to Italy and was immediately admitted to a major hospital in Rome. There, the patient, who was also riddled with shrapnel in various areas of the body, was diagnosed and treated for the following traumatic lesions: right side pneumothorax, fractures to the sternum, to the left scapula, to the left wrist, and to the left side of the jaw bone. The patient underwent a CT scan of the cranium and cervical spine, which showed only a linear fracture of the left occipital condyle, without distortion or displacement of the bone (Figure 1). The cervical vertebrae appeared normal (Figure 2) and untouched by the trauma. The only noteworthy aspect of the spine was the loss of the normal lordosis. In truth, the CT scan already showed some signs of instability: the interspinous space between C5 and C6 appeared increased compared to the other interspinous spaces. Moreover, in the parasagittal and axial images, the distance between the articular facets C5–C6 was excessive, but these signs were not detected by the medical team at the hospital. The neurological examination did not show any abnormalities. It was deemed no longer necessary for the patient to wear the neck brace that had been put on him from the very beginning. A week after hospital admission in Italy, the patient began complaining more and more persistently of pronounced

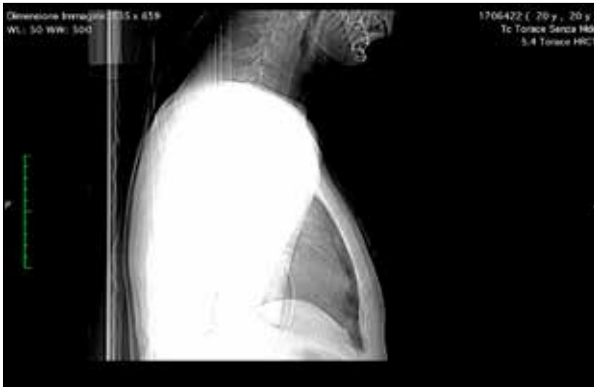

**Figure 1.** CT scan of the cranium shows a linear fracture of the left occipital condyle without distortion or displacement of the bone.

cervical pain, but considering the normal CT scan findings, the absence of any neurological impairments, and the fact that the patient walked well, the problem was ascribed to muscular tension due to cervical “whiplash” and posttraumatic stress disorder. In truth, when a chest x-ray was carried out 10 days after the patient was admitted to hospital, a preliminary scan of the whole body was also performed, which showed grade 1 C5–C6 spondylolisthesis (Figure 3), but no one noticed.



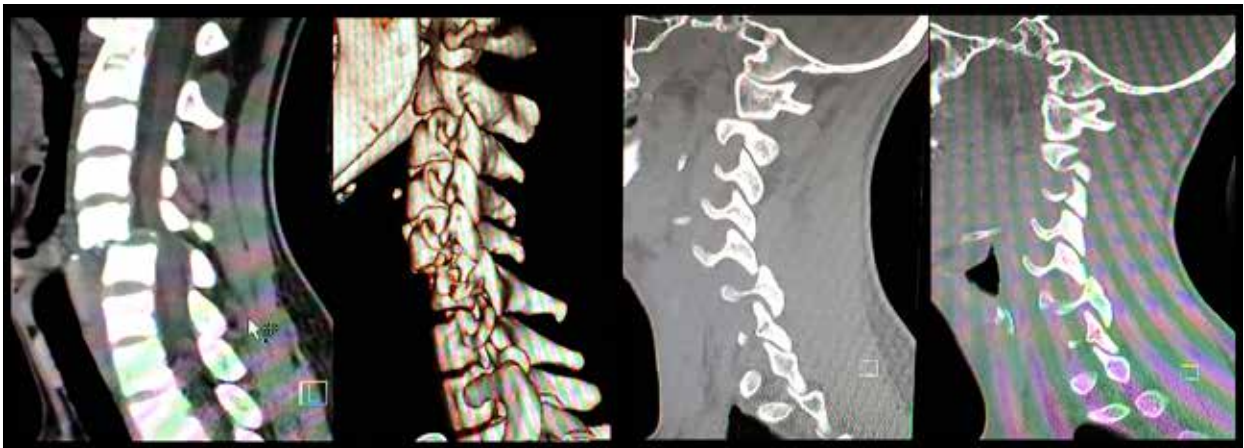
**Figure 2.** CT scan of the cervical spine shows the loss of the normal cervical curvature; otherwise, the vertebrae appear to be in perfect alignment and untouched. There are, however, occult signs of instability: increased interspinous space between C5 and C6 and increased space between the C5–C6 facets.



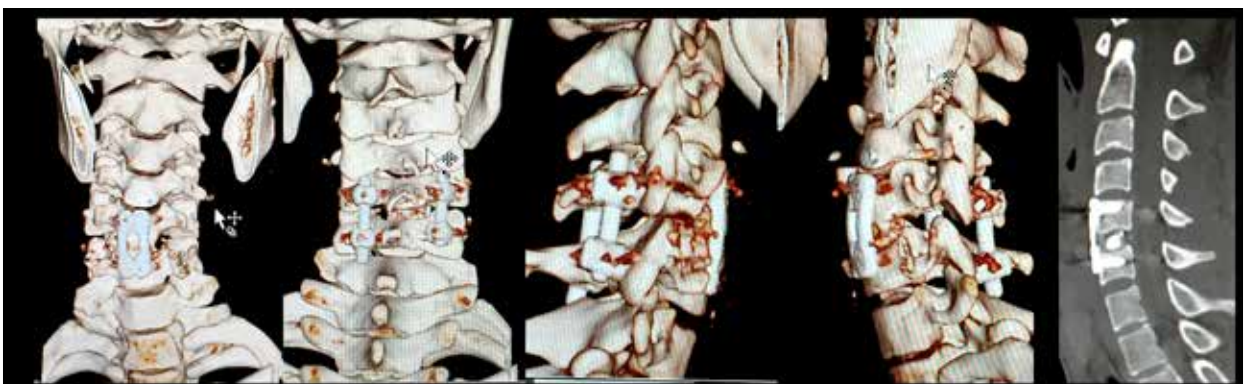
**Figure 3.** Preliminary scan for the chest x-ray shows a grade 1 C5–C6 spondylolisthesis.

Two weeks after his arrival in Italy, the patient was transferred from the civilian hospital to the military hospital of Rome. Here, he immediately underwent a CT scan of the cranium and the cervical spine to check the condition of the left occipital condyle fracture and also to ascertain the cause of the strong cervical pain. The scan showed (Figure 4) a grade 3 C5–C6 spondylolistheses with pronounced slippage and medullar compression;

the inferior C5 articular facets on both sides had suffered forward dislocation from the C6 superior articular facets. The neurological examination of the patient upon admission showed a clear hyperreflexia of the lower limbs and no plantar reflex responses on both sides, but there was no loss of strength, mobility, or sensitivity: the patient walked and moved normally. The patient was operated on; during surgery, his neurological condition was constantly assessed through intraoperative neurophysiological monitoring (IONM). The patient was put under general anesthesia and, using Crutchfield tongs, progressive cervical traction was applied to his spine until the vertebrae were re-aligned; however, it was not possible to bring the articular facets back to the right position despite several attempts. Keeping the traction, the patient was operated on from the front: a C5–C6 discectomy was carried out, a cage was inserted in the intervertebral space, and a titanium plate applied to hold the vertebrae in place. During this phase of the operation, it was possible to ascertain that the anterior and posterior longitudinal ligaments were completely damaged. The patient was then turned around and arthrodesis was carried out posteriorly with screws in the lateral masses. The supraspinal and intraspinal ligaments of C5–C6 were also damaged.



**Figure 4.** CT scan shows a grade 3 C5–C6 spondylolistheses with pronounced slippage and medullar compression; the inferior C5 articular facets on both sides had suffered forward dislocation from the C6 superior articular facets.



**Figure 5.** Post-operative CT scan confirmed the perfect vertebral re-alignment and the success of the circumferential arthrodesis.

When the patient woke up, he showed no neurological impairments. A post-operative CT scan (Figure 5) confirmed the perfect vertebral re-alignment and the success of the circumferential arthrodesis. The post-operative course was normal and, since all the other lesions had healed, 20 days after the cervical surgery, the patient was released.

## Discussion

What makes this case singular and noteworthy is that the progressive process of cervical spondylolisthesis, with the complete dislocation of the articular facets (until they were completely stuck), took place in hospital and, despite its seriousness, the spondylolisthesis did not cause any loss of strength, mobility, or sensitivity. It is obvious that mistakes were made in managing this case, which were all understandable yet avoidable, and some valuable lessons can be learned from them.

The first cervical CT scan showed no vertebral fractures or misalignments, but the scan had been performed when the patient was still wearing the neck brace. Furthermore, the fracture of the occipital condyle was a clue pointing to the severity of the trauma that had been suffered by that area of the body and, if the medical staff had been more attentive, all the other signs of instability would have been noticed too. When looking at CT sagittal scans, young surgeons with inadequate experience or 'precipitous' surgeons regard only the central cuts, bypassing or skimming through the parasagittal cuts, which, as in our case, show signs of an unstable condition. Ignoring these signs can lead to serious consequences. It is in fact very important to carefully study parasagittal cuts, paying attention to the articular facets, especially their shape, interfacial space, and orientation. It is also important to observe the peduncles and the shape and dimension of the intervertebral foramina.

A dynamic radiological investigation of the cervical spine should have been carried out, taking all necessary precautions. This would have certainly shown the instability between C5 and C6, pointing to the damage of the ligaments. This type of examination would have been particularly helpful because, due

to the presence of shrapnel in the body, it was not possible to carry out an MRI scan, which, unlike a CT scan, would have highlighted ligament alterations [1–3]. As a general rule, this occurrence underlines a common mistake made by doctors when studying trauma to the vertebral column, which is to give too much importance to the appearance of the bone and disregard the intervertebral ligaments.

Neurological checkups upon admission and release from hospital never showed loss of strength, mobility, or sensitivity, and this is one of the main reasons mistakes were made. During his hospital stay, the patient began complaining of progressively worsening pain to the neck; this fact, because the CT scan showed nothing out of the ordinary and because the patient's neurological conditions were good, was severely underestimated and it was deemed to be mainly linked to psychological trauma. The old saying in medicine that "a patient is always right" was not heeded: an extra follow-up x-ray would have shown the spondylolisthesis.

The causes of the error in diagnostics are manifold: the normal results of neurological examination, the normal alignment of the vertebral bodies in the first cervical CT scan, and the presence of other injuries. But there is another reason that we consider very important and that might explain such occurrences: medical team overwork. As recorded in a recent article of the influential British newspaper *The Guardian*: "The unprecedented strain on hospitals – created by rising demand for care, shortages of doctors and nurses, and the need to save money – is making staff more likely to make errors" [4].

## Conclusion

This case reminds us that establishing the conditions of an organ or a body part upon admission to hospital may not be enough when a patient has suffered extensive and serious trauma, in this instance caused by the explosion of a bomb, and that it is necessary to carry out more checkups over time, especially if there are new clues and symptoms.

## References:

1. Como JJ, Leukhardt WH, Anderson JS et al: Computed tomography alone may clear the cervical spine in obtunded blunt trauma patients: A prospective evaluation of a revised protocol. *J Trauma*, 2011; 70(2): 345–49; discussion 349–51
2. Wu X, Kalra VB, Forman HP, Malhotra A: Letter to the Editor regarding "is magnetic resonance imaging in addition to a computed tomographic scan necessary to identify clinically significant cervical spine injuries in obtunded blunt trauma patients?". *Am J Surg*, 2016; 211(4): 825–26
3. Erwood AM, Abel TJ, Grossbach AJ et al: Acutely unstable cervical spine injury with normal CT scan findings: MRI detects ligamentous injury. *J Clin Neurosci*, 2016; 24: 165–67
4. Campbell D: Serious mistakes in NHS patient care are on the rise, figures reveal. *The Guardian* [online] 2016 December 31. Available from: <https://www.theguardian.com/society/2016/dec/31/serious-mistakes-nhs-patient-care-rising-figures-reveal-hospitals>