

# Effect of corneal light scatter on vision: a review of the literature

Leopoldo Spadea<sup>1</sup>, Giorgia Maraone<sup>1</sup>, Francesca Verboschi<sup>1</sup>, Enzo Maria Vingolo<sup>1</sup>, Daniele Tognetto<sup>2</sup>

<sup>1</sup>Department of Biotechnology and Medical-Surgical Sciences, "Sapienza" University of Rome, Latina 04100, Italy

<sup>2</sup>Eye Clinic, Ospedale Maggiore, University of Trieste, Trieste 34010, Italy

**Correspondence to:** Leopoldo Spadea. Via Benozzo Gozzoli 34, Rome 00142, Italy.leopoldo.spadea@uniroma1.it

Received: 2014-12-27 Accepted: 2015-06-08

## Abstract

• The cornea is the transparent connective tissue window at the front of the eye. The physiological role of the cornea is to conduct external light into the eye, focus it, together with the lens, onto the retina, and to provide rigidity to the entire eyeball. Therefore, good vision requires maintenance of the transparency and proper refractive shape of the cornea. The surface structures irregularities can be associated with wavefront aberrations and scattering errors. Light scattering in the human cornea causes a reduction of visual quality. In fact, the cornea must be transparent and maintain a smooth and stable curvature since it contributes to the major part of the focusing power of the eye. In most cases, a simple examination of visual acuity cannot demonstrate the reduction of visual quality secondary light scattering. In fact, clinical techniques for examining the human cornea *in vivo* have greatly expanded over the last few decades. The measurement of corneal back scattering qualifies the degree of corneal transparency. The measurement of corneal forward -scattering quantifies the amount of visual impairment that is produced by the alteration of transparency. The aim of this study was to review scattering in the human cornea and methods of measuring it.

• **KEYWORDS:** cornea; haze; light; photorefractive keratectomy; scattering; vision

**DOI:10.18240/ijo.2016.03.24**

Spadea L, Maraone G, Verboschi F, Vingolo EM, Tognetto D. Effect of corneal light scatter on vision: a review of the literature. *Int J Ophthalmol* 2016;9(3):459-464

## INTRODUCTION

The cornea is the transparent connective tissue window at the front of the eye<sup>[1]</sup>. The physiological role of the

cornea is to conduct external light into the eye, focus it, together with the lens, onto the retina and to provide rigidity to the entire eyeball. Therefore, good vision requires maintenance of the transparency and proper refractive shape of the cornea<sup>[2]</sup>. The cornea consists primarily of three cellular layers: an outer layer containing an epithelium, a middle stromal layer consisting of a collagen-rich extracellular matrix (ECM) interspersed with keratocytes and an inner layer of endothelial cells<sup>[3]</sup> and two interface (Bowman's layer and Descemet membrane). Bowman's layer is classically described as an acellular condensation of the anterior stroma of the cornea. It is positioned between the epithelial basement membrane and the anterior stroma populated with keratocytes<sup>[4]</sup>. The Descemet membrane is located between the posterior aspect of the corneal stroma and the endothelium<sup>[5]</sup>. The stroma is formed by keratoblasts. The keratoblasts differentiate into keratocytes which synthesize high levels of collagens and keratan sulfate proteoglycans that replace the hyaluronan/water-rich ECM with the densely packed collagen fibril-type ECM seen in transparent adult corneas<sup>[6]</sup>. Keratocytes are a population of cells sandwiched between the corneal stromal collagen scaffold<sup>[7]</sup>. The collagen fibers are arranged in parallel bundles called fibrils, and these fibrils are packed in parallel arranged layers or lamellae<sup>[8]</sup>. Collagen type I and type V are the predominant forms in mammalian corneas<sup>[5]</sup>. These collagen fibrils have a diameter of approximately 10-20 nm<sup>[9]</sup>. Each collagen fibril lies at a fixed distance from the other (20 nm) and fibril density within the lamellae increases in the center of the stroma relative to the periphery<sup>[10]</sup>. These collagen types are relevant to corneal transparency, which is based on their regular interfibril distance and the uniform diameter of the striated stromal collagen fibrils<sup>[11]</sup>. The surface structures irregularities can be associated with wavefront aberrations and scattering errors<sup>[12]</sup>. After the collagens, the second major group of the extracellular proteins in the stroma is proteoglycans. Lumican is believed to be essential to the transparency of the cornea in that it regulates the uniform diameter of the collagen fibrils<sup>[13]</sup>. Retinal image quality is degraded by scatter, diffraction, and wavefront aberrations (better known as wavefront errors)<sup>[14]</sup>. Studies have focused on the investigation of ocular aberrations, which are measured using various approaches

such as Hartmann-Shack wavefront sensing, Tscherning aberrosopy, optical path difference scan, and ray-tracing refractometry. Computerized video keratoscopes (CVK) have enabled measurement of corneal shape, and corneal height maps and polynomial decomposition have been used to determine corneal aberrations<sup>[15]</sup>.

Besides higher-order aberrations, changes in the transparency of the cornea could also impact on visual performance. The transparency of the cornea is related to its highly organised structure, and when this complex configuration becomes altered light scatter is increased. Scattered light which is deviated more than 90° (referred to as backward light scatter) mainly results in a reduction of the amount of light reaching the retina. On the contrary, scattered light deviated less than 90° (referred to as forward light scatter or straylight) results in a changing luminance superimposed upon the retinal image, leading to a reduction in retinal image contrast and possible disability glare<sup>[16]</sup>. Changes in the ultrastructure of the cornea induced by inflammation, swelling, postsurgical, wound healing processes can lead to loss of transparency of the cornea, corneal haze, and increased scattering of light<sup>[17]</sup>. The object of this review is to illustrate scattering in the human cornea and methods of measuring it.

### PHYSICAL PRINCIPLES OF SCATTERING

The cornea is the clear front covering of the eye through which we see and is composed of collagen fibrils embedded in an optically homogeneous ground substance. It has long been recognized that these fibrils scatter light and that transparency results from interference effects due to an ordering in the spatial arrangement of the fibrils around one another. The refractive index of these fibrils is similar to but differs from that of the ground substance and so they scatter light<sup>[18]</sup>. Maurice<sup>[19]</sup> was the first to show that although these fibrils are inefficient scatterers, they are so numerous that the cornea would be non transparent if they were randomly arranged around one another, concluding that transparency must be a consequence of destructive interference among the waves scattered by different fibrils, proposing the "lattice theory". This was a theory of transparency in which the fibrils were located at the positions of an ideal crystalline lattice. Stromal collagen fibrils are not arranged in a perfect crystallographic lattice, but there is sufficient order to render the stroma transparent to visible light due to interference effects<sup>[20]</sup>. In 1967, Goldman and Benedek<sup>[21]</sup> stated that corneal transparency depends on the fluctuations of the index of refraction that occur within very small distances. The refractive index difference between the fibrils and interfibrillar matrix means that each fibril scatters a small amount of light. However, if the fibrils are packed in a lattice arrangement, correlation in their relative positions leads to destructive interference of light scattered away from the forward direction, all the light energy going into the constructive interference in the forward direction<sup>[22]</sup>.

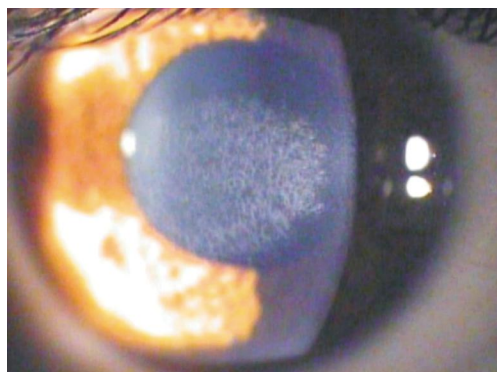
Recent studies in the last decade have suggested that the intrinsic transparency of the corneal fibroblast also plays a role. One theory implicates the involvement of intracellular keratocyte crystalline proteins, which are analogous to the water-soluble crystalline proteins of the lens. The keratocyte crystalline proteins are found in abundant amounts in quiescent keratocytes. In several mouse, rabbit and human studies, when the quiescent keratocyte transforms into an activated fibroblast, the expression of these proteins is markedly reduced, and this is associated with increased reflectivity of the keratocyte, and thus increased corneal opacity. In the human cornea, corneal crystalline proteins that appear to be relevant to corneal haze include aldehyde dehydrogenase (ALDH) and transketolase (TKT)<sup>[23]</sup>.

Despite the number of models proposed to explain corneal transparency, all the currently recognized paradigms accept that the crucial parameters affecting corneal transparency are: 1) number density of collagen fibrils; 2) collagen fibril diameter; 3) refractive index differential between the interfibrillar or ground substance and the fibrils; 4) stromal thickness; 5) spatial ordering of the fibrillary array<sup>[24]</sup>.

The literature has shown that several of the listed parameters do not stay constant across the cornea in relation to translational position from the central cornea to the limbus. Both interfibrillar spacing and fibril diameter show variation approaching the limbus and the cornea thickens in the same region<sup>[25]</sup>. Light entering into the eye is refracted by cornea and lens until it produces an image on the retina. Depending on the clarity of the ocular media, a portion of this passing light may be scattered, forming haze that is superimposed on the retinal image. This causes a glare effect that reduces contrast sensitivity (CS) and in more severe cases, leads to a loss of visual acuity. Such scattering can occur in the forward direction (*i.e.* toward the retina, also called stray light) or in the backward direction (*i.e.* out of the eye, also called backscatter). Both types of light scatter can occur in any part of the optical media, although the largest portion usually comes from the crystalline lens and the cornea<sup>[26]</sup>.

### BACK -SCATTERING MEASUREMENT AND QUANTITATIVE EVALUATION OF HAZE

Haze leads to loss of corneal transparency, which can deteriorate patients' visual function by causing glare, loss of CS and decrease visual acuity<sup>[27]</sup>. This induces increased corneal light back-scatter, which is estimated in many clinical conditions even with different approaches<sup>[28]</sup> (Figure 1). Assessment of corneal haze development and modulation, in most studies, has been hampered by the use of subjective methods to grade haze severity. The most commonly used method grades subepithelial haze in increments of 0.5 on a scale from 0 (no detectable haze) to +4 (all of the anterior chamber detail is obscured by the scar). This subjective grading method is rapid and simple, but it lacks reproducibility and sensitivity<sup>[29]</sup>. Usually the extent of haze is

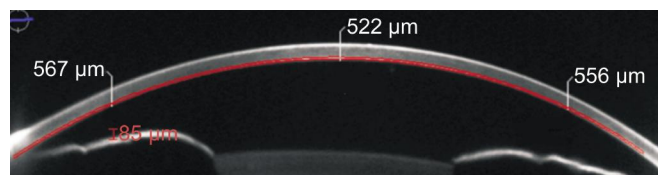


**Figure 1** Clinical image of a corneal reticular haze (+2) after 18mo from a -6 D PRK.

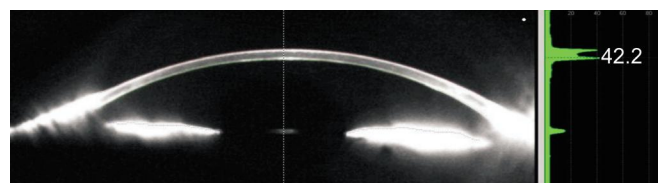
evaluated using a slit lamp biomicroscope. The slit-lamp biomicroscope is a versatile device that is the primary diagnostic instrument used during the clinical examination of the cornea and the external structures of the eye and adnexa. It has two primary components mounted on a common axis, the slit illuminator and the biomicroscope. Video camera and polarized filters are associated with slit-lamp. The images are scanned in grayscale with a resolution of  $256 \times 256$  pixels. The light intensity is measured in grayscale [30]. To have objective and reproducible results a scatterometer can be used based on a simple adaption of a slit-lamp biomicroscope, with a fiber optic pickup (550 nm), a band pass filter for wavelength selection and a photomultiplier detector [31].

The Scheimpflug camera was developed according to the Scheimpflug principle. This principle states that the image of an obliquely positioned object is formed such that the planes of the object, image and objective, intersect. This allows for the sagittal image of the anterior segment of the eye to be photographed such that it is in focus from the anterior surface of the cornea to the posterior surface of the lens. The camera can be rotated  $180^\circ$  along the visual axis, so that the entire anterior segment can be photographed. In addition, it has two important features: 1) an internal standard, a gray scale of five steps, which is incorporated in the photograph allowing for standardization of film image; 2) a photo acoustical fixation device allowing for precise alignment of the patient's eye (in the presence of reasonably good visual acuity) [32]. The use of Scheimpflug imaging was first reported by Smith *et al* [33] although at the time the applications were limited. Modern devices employ charge-coupled device (CCD) chips that facilitate rapid data acquisition and analysis [34].

Noninvasive Scheimpflug analysis of the anterior segment simultaneously detects backscattered light, from which a deeper optical analysis can be performed to generate maps of corneal topography, pachymetry, and anterior chamber depth. (Figure 2) It is also possible to compose a map of the amount of backscattered light in the different regions of the cornea, called a corneal densitometry map [35]. The densitometry program allows quantitative, objective measurement of



**Figure 2** Corneal sub-epithelial haze after 8mo from a -3 D PRK. The Scheimpflug camera measures the intensity enhancement of scanned images to grayscale. Sirius Scheimpflug Analyzer (CSO, Costruzione Strumenti Oftalmici, Florence, Italy).



**Figure 3** Scheimpflug analysis of backscattered light. The densitometry program allows quantitative, objective measurement of opacities within the eye's anterior segment by scattering light. Pentacam (Oculus, Wetzlar, Germany).

opacities within the eye's anterior segment by scattering light [36] (Figure 3). Although corneal light backscatter is unclearly correlated with forward light scatter, corneal densitometry may play a valuable role in characterizing keratoconic corneas [37]. Corneal densitometry has been also described in corneal dystrophies [38-39], post-LASIK [40], and corneal graft surgeries [41-42].

The confocal microscope overcomes the problem of defocused light by using the confocal principle. In its simplest form, a point-source of light, created by a pinhole aperture, is focused by an objective lens on the tissue. The light reflected by the specimen at this focal point is collected by a parallel objective lens and focused onto a separate duplicate pinhole aperture. Light that passes this second aperture is collected by a detector. Both the illuminating point source and the observation aperture of the detector are conjugate with the same point in the tissue, and are said to be confocal. A high-numeric-aperture lens is used as an objective lens. With this optical system, illumination is brightest at the focal point (image of the illumination aperture) and decreases rapidly in front of and behind the focus. Light that originates at the focal point will be detected efficiently, because the image of this point is focused on the detection aperture. However, only a small amount of light that originates a small distance in front of or behind the focal plane is detected, because it is imaged behind or in front of the detection aperture. This confocal design provides two important features for imaging the cornea: reduced depth of field (improving axial resolution) and improved lateral resolution as compared to conventional microscopes. Clinical confocal microscopes typically have a depth of field of 10 to 26 μm, depending on the design of the microscope, and lateral resolution of 1 to 2 μm [1,11]. By nature, the confocal principle is limited to 1 point, or in some designs to a slit, in


the focal plane. In practice, an array of apertures is used to examine many points simultaneously, and this array is scanned across the field fast enough to create an image that can be recorded<sup>[38]</sup>. The principle of confocal microscopy was initially utilized to study neural networks of the living brain<sup>[43-44]</sup>. The *ex vivo* cornea was first examined with confocal microscopy by Lemp *et al*<sup>[45]</sup> in 1985 and the first *in vivo* images of the human cornea were published by Cavanagh *et al*<sup>[46]</sup> in 1990. During slit-lamp examination, normal corneas scatter and reflect light back toward the observer, and this effect provides a means of identifying structures, such as the epithelium, keratocytes, stroma, and surgical interfaces. Corneal haze is an elevation of this background scatter and is usually considered an indicator of disease. The use of a properly standardized confocal microscope or other device for measuring this haze will allow clinicians to compare the brightness of the haze with that of normal corneas, to identify sources of the elevated haze within the cornea, and to follow progression or regression of haze in patients<sup>[47]</sup> (Figure 4).

A technique called optical coherence tomography (OCT) has been developed for noninvasive cross-sectional imaging in biological systems<sup>[48]</sup>. It has been widely applied for imaging both the anterior and posterior segments of the eye using different system designs, such as anterior segment OCT and posterior segment OCT<sup>[49]</sup>. OCT systems are designed to detect usually faint back-scattered light from tissue. However, both backscattered as well as back-reflected (from directional and specular reflections) light is detected, particularly for surfaces normal to the optical axis of the instrument, such as the corneal apex in anterior corneal imaging. The presence of back-reflected light results in saturation of the A-scan signals. Upon Fourier transform, fully saturated A-scans appear as completely modulated white lines, whereas partially saturated A-scans give rise to replications and ghost signals<sup>[50]</sup>. OCT provides the possibility of whole cornea assessment, however, with much less magnification in comparison to confocal microscopy<sup>[51]</sup> (Figure 5).

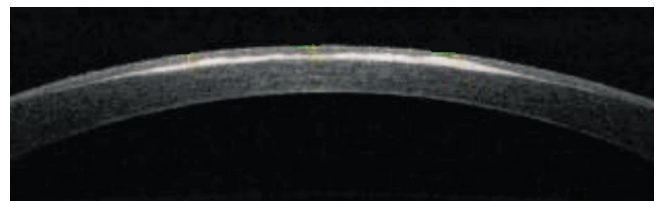
#### FORWARD-SCATTERING

The transparency of the cornea is related to its highly organized structure, and when this complex configuration becomes altered, with penetrating keratoplasty<sup>[52]</sup> or after corneal refractive surgery<sup>[53]</sup>, light scatter is increased. Scattered light which is deviated more than 90° (referred to as backward light scatter) mainly results in a reduction of the amount of light reaching the retina. On the contrary, scattered light deviated less than 90° (referred to as forward light scatter or stray light) results in a veiling luminance superimposed upon the retinal image, leading to a reduction in retinal image contrast and possible disability glare<sup>[16]</sup> (Figure 6).

Glare is generally assumed to be the direct result of forward



**Figure 4** Confocal microscopy image of a sub-epithelial haze after 6mo from a -6 D PRK Confoscan 4 (Nidek Technologies, Gamagori, Japan).



**Figure 5** Corneal haze after 12mo from a -5 D PRK The AS-OCT analyzing the light reflectivity profile evaluates the intensity of back scattering.



**Figure 6** The Pelli -Robson letters analyze the contrast sensitivity decay of patient's vision caused by forward - scattering produced by the diffraction of light within the eye.

scatter, but the relation has not been studied<sup>[54]</sup>. Glare is traditionally divided into disability glare, causing a reduction of visual performance, and discomforting glare, which is the discomfort caused by the glare light without any measurable effect on the visual function. Disability glare caused by media opacities can be explained as a real luminous veil at the fovea arising from scattering of the glare light within the media of the eye<sup>[55]</sup>.

The forward scattering can be calculated by the van den Berg Straylightmeter. Subjects position their eye against a cup at the top of a viewing tube. They view a 1° circular target, surrounded by an annulus with an outer radius of 2° of steady luminance of 30 cd/m<sup>2</sup>. Concentric with this target and positioned along the inside of the viewing tube are three rings of yellow (lambda max 570 nm) light-emitting diodes. They are positioned at angular distances of 3.5°, 10°, and 28° from the subject's eye. The LED sources flicker sinusoidally at 8 Hz. The three rings can be illuminated separately to allow measurement of light scatter at each of the three angular positions. The subject is instructed to observe the central target, and one of the three glare rings is switched on.

Because of forward light scatter within the eye, a visible flicker is seen on the central target. The investigator then slowly increases the luminance modulation of the central target, which flickers in counterphase to the LED sources. The depth of modulation of this counterphase light that produces zero perceived flicker corresponds directly to the amount of forward light scatter.

CS and glare tests are being used more frequently to clinically evaluate patients with media opacities, such as after refractive surgery and in patients with corneal edema, cataract, and capsular opacification. The Pelli-Robson chart is a 86×63 cm chart that contains 16 triplets of 4.9×4.9 cm letters. At a test distance of 1 m, these letters correspond to spatial frequencies of about 1-2 cycles/degree. Within each triplet, the letters have the same contrast, and the contrast in each successive triplet decreases by a factor of 0.15 log units. A by-letter scoring system that gives credit (0.05 log units) for each letter read correctly was used. This has been shown to provide more reliable test scores than the originally recommended scoring rule. The chart was illuminated to 100 cd/m<sup>2</sup> and the recommended viewing distance of 1m was used. CS was measured with and without the brightness acuity tester (BAT). The BAT is a hand-held instrument that consists of a hemispheric bowl with an internally illuminated surface<sup>[56]</sup>.

## CONCLUSION

Optical clarity is one of the fundamental properties of the cornea. An understanding of the physical basis of corneal transparency has been a subject of interest among physicists, basic scientists and ophthalmologists. Impairment of corneal clarity is a significant cause of visual morbidity worldwide. Several highly mathematical treatises have been presented in support of different theories of corneal transparency in the normal cornea relating structure to function. Changes in the transparency of the cornea could also impact on visual performance.

The transparency of a normal cornea results directly from the fact that the cornea does not absorb visible light, and the light that it scatters is minimal. The small amount of scattered light, however, carries information about the internal structural elements from which the light is scattered. Light scattering in the human cornea causes a reduction of visual quality affecting day to day life. In fact, the cornea must be transparent and maintain a smooth and stable curvature since it contributes to the major part of focusing power of the eye<sup>[56]</sup>. The measurement of corneal back-scattering qualifies the degree of corneal transparency. The measurement of corneal forward-scattering quantifies the amount of visual impairment that is produced by the alteration of transparency. There is not a precise relation between the level of back-scattering and the level of forward-scattering in the cornea. This deficit may manifest itself only under specific environmental conditions of illumination, especially in some work places. In most cases a simple examination of visual

acuity can not demonstrate this alteration. Until a few years ago no quantitative method have been described for living human cornea. In fact clinical techniques for examining the human cornea in vivo have greatly expanded over the last several decades. Clinician's armamentarium has been enhanced, and in addition to the slit lamp biomicroscopy, a lot of market available machines such as specular microscopy of the endothelium, computed corneal topography, high-frequency ultrasound, anterior segment OCT and confocal microscopy were introduced. Tests such as CS and glare sensitivity investigate the functional aspects of corneal scattering and evaluate the patient's visual deficit.

In conclusion the effect of corneal light scatter on vision is rather worthy of note and its knowledge is taking on increasing relevance in ophthalmology.

## ACKNOWLEDGEMENTS

**Conflicts of Interest:** Spadea L, None; Maraone G, None; Verboschi F, None; Vingolo EM, None; Tognetto D, None.

## REFERENCES

- 1 Liang J, Williams DR. Aberrations and retinal image quality of the normal eye. *J Opt Soc Am A Opt Image Sci Vis* 1997;11(14):2873-2883.
- 2 Nishida T. The cornea: stasis and dynamics. *Nihon Ganka Gakkai Zasshi* 2008;112(3):179-212; discussion 213.
- 3 Knupp C, Pinali C, Lewis PN, Parfitt GJ, Young RD, Meek KM, Quantock AJ. The architecture of the cornea and structural basis of its transparency. *Adv Protein Chem Struct Biol* 2009;78:25-49.
- 4 Wilson SE, Hong JW. Bowman's layer structure and function: critical or dispensable to corneal function? A hypothesis. *Cornea* 2000;19 (4): 417-420.
- 5 DelMonte DW, Kim T. Anatomy and physiology of the cornea. *J Cataract Refract Surg* 2011;37(3):588-598.
- 6 Hassell JR, Birk DE. The molecular basis of corneal transparency. *Exp Eye Res* 2010;91(3):326-335.
- 7 Almutrad T, Akhtar S. Structure of corneal layers, collagen fibrils, and proteoglycans of tree shrew cornea. *Mol Vis* 2011;17:2283-2291.
- 8 Qazi Y, Wong G, Monson B, Stringham J, Ambati BK. Corneal transparency: genesis, maintenance and dysfunction. *Brain Res Bull* 2010; 81(2-3):198-210.
- 9 Quantock AJ, Young RD. Development of the corneal stroma, and the collagen-proteoglycan associations that help define its structure and function. *Dev Dyn* 2008;237(10):2607-2621.
- 10 Ihanamaki T, Pelliniemi LJ, Vuorio E. Collagens and collagen-related matrix components in the human and mouse eye. *Prog Retin Eye Res* 2004;23(4):403-434.
- 11 Marshall GE, Konstas AG, Lee WR. Immunogold fine structural localization of extracellular matrix components in aged human cornea. II. Collagen types V and VI. *Graefes Arch Clin Exp Ophthalmol* 1991;29(2): 164-171.
- 12 Semchishen V, Mrokhen M. From scattering to wavefront. Healing optics. *Vestn Oftalmol* 2004;120(1):42-45.
- 13 Muller LJ, Pels E, Schurmans LR, Vrensen GF. A new three-dimensional model of the organization of proteoglycans and collagen fibrils in the human corneal stroma. *Exp Eye Res* 2004;78(3):493-501.
- 14 Applegate RA, Marsack JD, Ramos R, Sarver EJ. Interaction between aberrations to improve or reduce visual performance. *J Cataract Refract Surg* 2003;29(8):1487-1495.



- 15 Wang L, Dai E, Koch DD, Nathoo A. Optical aberrations of the human anterior cornea. *J Cataract Refract Surg* 2003;29(8):1514–1521.
- 16 Jinabhai A, O'Donnell C, Radhakrishnan H, Nourrit V. Forward light scatter and contrast sensitivity in keratoconic patients. *Cont Lens Anterior Eye* 2012;35(1):22–27.
- 17 Hindman HB, McCally RL, Myrowitz E, Terry MA, Stark WJ, Weinberg RS, Jun AS. Evaluation of deep lamellar endothelial keratoplasty surgery using scatterometry and wavefront analyses. *Ophthalmology* 2007;114(11):2006–2012.
- 18 Patel DV, McKelvie J, Sherwin T, McGhee C. Keratocyte progenitor cell transplantation: a novel therapeutic strategy for corneal disease. *Med Hypotheses* 2013;80(2):122–124.
- 19 Maurice DM. The structure and transparency of the cornea. *J Physiol* 1957;136(2):263–286.
- 20 Farrell RA, McCally RL. On corneal transparency and its loss with swelling. *J Opt Soc Am* 1976;66(4):342.
- 21 Goldman JN, Benedek GB. The relationship between morphology and transparency in the nonswelling corneal stroma of the shark. *Invest Ophthalmol Vis Sci* 1967;6(6):574–600.
- 22 Feuk T. On the transparency of the stroma in the mammalian cornea. *IEEE Trans Biomed Eng* 1970;17(3):186–190.
- 23 Meek KM, Meek KM, Leonard DW, Connon CJ, Dennis S, Khan S. Transparency, swelling and scarring in the corneal stroma. *Eye (Lond)* 2003;17(8):927–936.
- 24 Jester JV, Moller-Pedersen T, Huang J, Sax CM, Kays WT, Cavanagh HD, Petroll WM, Piatigorsky J. The cellular basis of corneal transparency: evidence for 'corneal crystallins'. *J Cell Sci* 1999;112(5):613–622.
- 25 Douth J, Quantock AJ, Smith VA, Meek KM. Light transmission in the human cornea as a function of position across the ocular surface: theoretical and experimental aspects. *Biophys J* 2008;95(11):5092–5099.
- 26 Boote C, Dennis S, Newton RH, Puri H, Meek KM. Collagen fibrils appear more closely packed in the prepupillary cornea: optical and biomechanical implications. *Invest Ophthalmol Vis Sci* 2003;44 (7):2941–2948.
- 27 Rozema JJ, Trau R, Verbruggen KH, Tassignon MJ. Backscattered light from the cornea before and after laser-assisted subepithelial keratectomy for myopia. *J Cataract Refract Surg* 2011;37(9):1648–1654.
- 28 Olsen T. Light scattering from the human cornea. *Invest Ophthalmol Vis Sci* 1982;23(1):81–86.
- 29 Wang J, Simpson TL, Fonn D. Objective measurements of corneal light-backscatter during corneal swelling, by optical coherence tomography. *Invest Ophthalmol Vis Sci* 2004;45(10):3493–3498.
- 30 Soya K, Amano S, Oshika T. Quantification of simulated corneal haze by measuring back-scattered light. *Ophthalmic Res* 2002;34(6):380–388.
- 31 Lohmann CP, Gartry DS, Muir MK, Timberlake G, Fitzke F, Marshall J. Corneal opacity after photorefractive keratectomy with an excimer laser. Cause, objective measurement and functional consequences. *Ophthalmology* 1992;89(6):498–504.
- 32 Braunstein RE, Jain S, McCally RL, Stark WJ, Connolly PJ, Azar DT. Objective measurement of corneal light scattering after excimer laser keratectomy. *Ophthalmology* 1996;103(3):439–443.
- 33 Smith GT, Brown NA, Shun-Shin GA. Light scatter from the central human cornea. *Eye (Lond)* 1990;4 (Pt 4):584–588.
- 34 Wegener A, Laser-Junga H. Photography of the anterior eye segment according to Scheimpflug's principle: options and limitations—a review. *Clin Exp Ophthalmol* 2009;37(1):144–154.
- 35 Ni Dhubhghaill S, Rozema JJ, Jongenelen S, Ruiz Hidalgo I, Zakaria N, Tassignon MJ. Normative values for corneal densitometry analysis by Scheimpflug optical assessment. *Invest Ophthalmol Vis Sci* 2014;55 (1):162–168.
- 36 Datiles MB, Edwards PA, Trus BL, Green SB. In vivo studies on cataracts using the Scheimpflug slit lamp camera. *Invest Ophthalmol Vis Sci* 1987;28(10):1707–1710.
- 37 Lopes B, Ramos I, Ambrosio R Jr. Corneal densitometry in keratoconus. *Cornea* 2014;33(12):1282–1286.
- 38 Elflein HM, Hofherr T, Berisha-Ramadani F, Wevyer V, Lampe C, Beck M, Pitz S. Measuring corneal clouding in patients suffering from mucopolysaccharidosis with the Pentacam densitometry programme. *Br J Ophthalmol* 2013;97(7):829–833.
- 39 Ha B, Kim TI, Choi SI, Stulting RD, Lee DH, Cho HS, Kim EK. Mitomycin C does not inhibit exacerbation of granular corneal dystrophy type II induced by refractive surface ablation. *Cornea* 2010;29(5):490–496.
- 40 Fares U, Otri AM, Al-Aqaba MA, Faraj L, Dua HS. Wavefront-optimized excimer laser in situ keratomileusis for myopia and myopic astigmatism: refractive outcomes and corneal densitometry. *J Cataract Refract Surg* 2012;38(12):2131–2138.
- 41 Takacs AI, Mihaltz K, Nagy ZZ. Corneal density with the Pentacam after photorefractive keratectomy. *J Refract Surg* 2011;27(4):269–277.
- 42 Bhatt UK, Fares U, Rahman I, Said DG, Maharajan SV, Dua HS. Outcomes of deep anterior lamellar keratoplasty following successful and failed 'big bubble'. *Br J Ophthalmol* 2012;96(4):564–569.
- 43 Erie JC, McLaren JW, Patel SV. Confocal microscopy in ophthalmology. *Am J Ophthalmol* 2009;148(5):639–646.
- 44 Petroll WM, Jester JV, Cavanagh HD. In vivo confocal imaging. *Int Rev Exp Pathol* 1996;36:93–129.
- 45 Lemp MA, Dilly PN, Boyde A. Tandem-scanning (confocal) microscopy of the full-thickness cornea. *Cornea* 1985–1986;4(4):205–209.
- 46 Cavanagh HD, Jester JV, Essepian J, Shields W, Lemp MA. Confocal microscopy of the living eye. *CLAO J* 1990;16(1):65–73.
- 47 McLaren JW, Bourne WM, Patel SV. Standardization of corneal haze measurement in confocal microscopy. *Invest Ophthalmol Vis Sci* 2010;51 (11):5610–5616.
- 48 Huang D, Swanson EA, Lin CP, Schuman JS, Stinson WG, Chang W, Hee MR, Flotte T, Gregory K, Puliafito CA, *et al*. Optical coherence tomography. *Science* 1991;22:254(5035):1178–1181.
- 49 Tao A, Shao Y, Zhong J, Jiang H, Shen M, Wang J. Versatile optical coherence tomography for imaging the human eye. *Biomed Opt Express* 2013;4(7):1031–1044.
- 50 Ortiz S, Siedlecki D, Pérez-Merino P, Chia N, de Castro A, Szkulmowski M, Wojtkowski M, Marcos S. Corneal topography from spectral optical coherence tomography (sOCT). *Biomed Opt Express* 2011; 2(12):3232–3247.
- 51 Avetisov SE, Egorova GB, Kobzova MV, Mitichkina TS, Rogova Ala. Clinical significance of modern methods of corneal assessment. *Vestn Oftalmol* 2013;129(5):22–31.
- 52 Patel SV, McLaren JW, Hodge DO, Bourne WM. The effect of corneal light scatter on vision after penetrating keratoplasty. *Am J Ophthalmol* 2008;146(6):913–919.
- 53 Li J, Wang Y, Zuo T, Liu LQ, Hou J, Xie LL, Yang XY, Li ZM. Analysis of light scatter changes and relevant factors after laser refractive surgery. *Zhonghua Yan Ke Za Zhi* 2011;47(7):589–595.
- 54 de Waard PW, Ijspeert JK, van den Berg TJ, de Jong PT. Intraocular light scattering in age-related cataracts. *Invest Ophthalmol Vis Sci* 1992; 33(3):618–625.
- 55 Abrahamsson M, Sjostrand J. Impairment of contrast sensitivity function (CSF) as a measure of disability glare. *Invest Ophthalmol Vis Sci* 1986;27 (7):1131–1136.
- 56 Elliott DB, Bullimore MA. Assessing the reliability, discriminative ability, and validity of disability glare tests. *Invest Ophthalmol Vis Sci* 1993;34(1):108–119.